This is a digital copy of a book that was preserved for generations on library shelves before it was carefully scanned by Google as part of a project to make the world's books discoverable online.

It has survived long enough for the copyright to expire and the book to enter the public domain. A public domain book is one that was never subject to copyright or whose legal copyright term has expired. Whether a book is in the public domain may vary country to country. Public domain books are our gateways to the past, representing a wealth of history, culture and knowledge that's often difficult to discover.

Marks, notations and other marginalia present in the original volume will appear in this file - a reminder of this book's long journey from the publisher to a library and finally to you.

Usage guidelines

Google is proud to partner with libraries to digitize public domain materials and make them widely accessible. Public domain books belong to the public and we are merely their custodians. Nevertheless, this work is expensive, so in order to keep providing this resource, we have taken steps to prevent abuse by commercial parties, including placing technical restrictions on automated querying.

We also ask that you:

+ *Make non-commercial use of the files* We designed Google Book Search for use by individuals, and we request that you use these files for personal, non-commercial purposes.
+ *Refrain from automated querying* Do not send automated queries of any sort to Google's system: If you are conducting research on machine translation, optical character recognition or other areas where access to a large amount of text is helpful, please contact us. We encourage the use of public domain materials for these purposes and may be able to help.
+ *Maintain attribution* The Google "watermark" you see on each file is essential for informing people about this project and helping them find additional materials through Google Book Search. Please do not remove it.
+ *Keep it legal* Whatever your use, remember that you are responsible for ensuring that what you are doing is legal. Do not assume that just because we believe a book is in the public domain for users in the United States, that the work is also in the public domain for users in other countries. Whether a book is still in copyright varies from country to country, and we can't offer guidance on whether any specific use of any specific book is allowed. Please do not assume that a book's appearance in Google Book Search means it can be used in any manner anywhere in the world. Copyright infringement liability can be quite severe.

About Google Book Search

Google's mission is to organize the world's information and to make it universally accessible and useful. Google Book Search helps readers discover the world's books while helping authors and publishers reach new audiences. You can search through the full text of this book on the web at `http://books.google.com/`

BOSTON
MEDICAL LIBRARY

IN THE
Francis A. Countway
Library of Medicine
BOSTON

THE

JOURNAL

OF

ANATOMY AND PHYSIOLOGY

NORMAL AND PATHOLOGICAL.

THE

JOURNAL

OF

ANATOMY AND PHYSIOLOGY

NORMAL AND PATHOLOGICAL.

EDINBURGH:
PRINTED BY NEILL AND COMPANY.

THE

JOURNAL

OF

ANATOMY AND PHYSIOLOGY

NORMAL AND PATHOLOGICAL.

CONDUCTED BY

SIR GEORGE MURRAY HUMPHRY, M.D., LL.D., F.R.S.,
PROFESSOR OF SURGERY, LATE PROFESSOR OF ANATOMY IN THE UNIVERSITY OF CAMBRIDGE.

SIR WILLIAM TURNER, M.B., LL.D., D.C.L., F.R.S.,
PROFESSOR OF ANATOMY IN THE UNIVERSITY OF EDINBURGH;

AND

J. G. M'KENDRICK, M.D., F.R.S.,
PROFESSOR OF THE INSTITUTES OF MEDICINE IN THE UNIVERSITY OF GLASGOW.

VOL. XXVII.

NEW SERIES.—VOLUME VII.

WITH XXVIII. PLATES AND NUMEROUS WOODCUTS

INDEX, PAGE 567.

LONDON:
CHARLES GRIFFIN AND COMPANY, LD.
EXETER STREET, STRAND.
1893.

CATALOGUED
DEC 21 1894
E. H. B.

CONTENTS.

FIRST PART—OCTOBER 1892.

PAGE

THE COSTO-STERNAL ARTICULATIONS. By JAMES MUSGROVE, M.D., F.R.C.S. 1

CONTRIBUTIONS TO THE CRANIOLOGY AND CRANIOMETRY OF PANJAB TRIBES. By R. HAVELOCK CHARLES, M.D., M.Ch., F.R.C.S.I., F.Z.S. 5

THE BRAIN OF THE LATE GEORGE GROTE, F.R.S., WITH COMMENTS AND OBSERVATIONS ON THE HUMAN BRAIN AND ITS PARTS GENERALLY. By the late Professor JOHN MARSHALL, LL.D., F.R.S. (Plates I., II., III.) 21

THE CEREBRAL COMMISSURES IN THE MARSUPIALIA AND MONOTREMATA. By JOHNSON SYMINGTON, M.D., F.Z.S., F.R.S.E. 69

CONTRIBUTIONS TO THE HISTOLOGY OF THE HEDGEHOG (*Erinaceus europæus*). By E. W. CARLIER, M.D., B.Sc., F.R.M.S. (Plates IV., V., VI.) 85

THE INTEGUMENTARY GROOVES ON THE PALM OF THE HAND AND SOLE OF THE FOOT OF MAN AND THE ANTHROPOID APES. By DAVID HEPBURN, M.D., C.M., F.R.S.E. (Plates VII., VIII., IX.) 112

THE ARTICULAR PROCESSES OF THE VERTEBRÆ IN THE GORILLA COMPARED WITH THOSE IN MAN, AND ON COSTO-VERTEBRAL VARIATION IN THE GORILLA. By JOHN STRUTHERS, M.D., LL.D. 131

EXTREME ANOMALY OF THE HEART AND GREAT VESSELS. By AMBROSE BIRMINGHAM, M.D. 139

PROCEEDINGS OF THE ANATOMICAL SOCIETY OF GREAT BRITAIN AND IRELAND ..... 151 (i)

SECOND PART—JANUARY 1893.

ON THE OCCURRENCE OF A JACOBSON'S ORGAN, WITH NOTES ON DEVELOPMENT OF NASAL CAVITY, LACHRYMAL DUCT, AND HARDERIAN GLAND IN *Crocodilus porosus*. By ALEXANDER MEEK, B.Sc. (Plate X.) 151

PAGE

COLLOID IN LYMPHATICS AND BLOOD-VESSELS OF THYROID IN GOITRE. By R. M. HORNE, M.B., C.M. Edin. 161

HISTOLOGY OF THE HEDGEHOG (*Erinaceus europæus*). By E. W. CARLIER, M.D., B.Sc., F.R.M.S. (Plate XI.) 169

RELATION OF DURA MATER SURROUNDING INFERIOR MAXILLARY NERVE TO TEMPORO-MAXILLARY ARTICULATION. By EDWARD FAWCETT, M.B. Edin. 177

UNNAMED SUPERNUMERARY NASAL CARTILAGES. By WALKER DOWNIE, M.B., F.F.P. and S. 181

THIRD ANNUAL REPORT OF COMMITTEE OF COLLECTIVE INVESTIGATION OF ANATOMICAL SOCIETY OF GREAT BRITAIN AND IRELAND FOR THE YEAR 1891-92. By ARTHUR THOMSON, M.A., M.B. 183

GASTRIC DIGESTION OF PROTEIDS. By A. L. GILLESPIE, M.D., F.R.C.P.E. 195

FORKED NERVE ENDINGS ON HAIRS. By the late GEORGE HOGGAN, M.B., and by FRANCES E. HOGGAN, M.D. (Plate XII.) 224

THE SUPRASTERNAL BONES IN MAN. By THOMAS CARWARDINE, M.R.C.S., L.R.C.P. (Plate XIII.) 232

FUNCTION OF URETHRAL BULB. By F. J. ALLEN, M.A., M.B. 235

ABSENCE OF MALE REPRODUCTIVE ORGANS IN TWO HERMAPHRODITE MOLLUSCS. By WALTER E. COLLINGE 237

CONGENITAL ABSENCE OF BOTH ULNÆ. By J. HOGARTH PRINGLE, M.B. Edin., F.R.C.S. Eng. 239

NOTES ON ACROMION. By Professor MACALISTER, M.D., F.R.S. (Plates XIV., XV.) 245

FIRST COSTO-VERTEBRAL JOINT. By Professor MACALISTER, M.D., F.R.S. (Plate XVI.) 252

DELIMITATION OF REGIONS OF ABDOMEN. By Professor D. J. CUNNINGHAM, M.D., D.C.L., F.R.S. (Plates XVII., XVIII.) 257

ORIGIN OF OPHTHALMIC ARTERY FROM MIDDLE MENINGEAL. By JAMES MUSGROVE, M.D., F.R.C.S. 279

COMPLETE SEPARATION OF TWO HEADS OF BICEPS FLEXOR CRURIS MUSCLE. By DAVID HEPBURN, M.D., F.R.S.E. 282

DELIMITATION OF REGIONS OF ABDOMEN. By W. WILBERFORCE SMITH, M.D., M.R.C.P. Lond. 285

NOTICES OF NEW BOOKS 286

PROCEEDINGS OF THE ANATOMICAL SOCIETY OF GREAT BRITAIN AND IRELAND .... 291 (xi)

PAGE

THIRD PART—APRIL 1893.

On the Rudimentary Hind-Limb of a Great Fin-Whale (*Balænoptera musculus*) in Comparison with those of the Humpback Whale and the Greenland Right-Whale. By John Struthers, M.D., LL.D. (Plates XVII.–XX.) 291

Comparative Osteological Notes on the Extinct Bird Ichthyornis. By Dr R. W. Shufeldt. 336

A Note on the Anatomy of the Hymen and on that of the "Posterior Commissure of the Vulva." By Charles J. Cullingworth, M.D., F.R.C.P. 343

The Myology of the Anencephalous Fœtus. By Professor Bertram C. A. Windle, M.A., M.D., D.Sc. 348

Contributions to the Histology of the Hedgehog. By E. W. Carlier, M.D., B.Sc., F.R.M.S. (Plate XXI.) 354

The Anatomy of Advanced Pregnancy in *Macacus rhesus* studied by Frozen Sections, by Casts and Microscopically. By D. Berry Hart, M.D., F.R.C.P.E., F.R.S.E.; and G. Lovell Gulland, M.D., F.R.C.P.E. (Plate XXII.) 361

Morphology of Limb Arteries in Vertebrates, with Especial Reference to the Disposition in the Human Subject. By Alfred Eichholz, B.A. 377

On an Arrow-Poison from New Granada, and on its Botanical Source. By Joseph Tillie, M.D. 402

The Adductor Muscles of the Thumb and Great Toe. By David Hepburn, M.D., F.R.S.E. 408

Some Observations on the Temporal Bone, chiefly in Childhood. By J. Jackson Clarke, M.B. 411

Report on Recent Teratological Literature. By Professor Bertram C. A. Windle, M.A., M.D., D.Sc. 415

A Phrenic Nerve receiving a Root of Origin from the Descendens Hypoglossi. By Professor Sir W. Turner. 427

Notices of New Books 428

Proceedings of the Anatomical Society of Great Britain and Ireland ..... 431 (xix)

PAGE

FOURTH PART—JULY 1893.

LAW OF TRANSVERSE VIBRATIONS OF STRINGS APPLIED TO THE HUMAN LARYNX. By ROBERT H. WOODS, M.B. 431

ON CERTAIN EARLY MALFORMATIONS OF THE EMBRYO. By Professor BERTRAM C. A. WINDLE, D.Sc., M.D., M.A. 436

CYSTIC DEGENERATION OF THE HEART, SPLEEN, LIVER, AND KIDNEYS. By ARTHUR V. MEIGS, M.D. 454

CASE OF CONGENITAL MALFORMATION OF THE HEART; WITH TRANSPOSITION OF THE AORTA AND PULMONARY ARTERY. By GORDON SANDERS, M.B., M.R.C.P. Ed. 464

THE STRUCTURAL CHANGES OBSERVED IN THE TESTICLES OF AGED PERSONS. By JOSEPH GRIFFITHS, M.A., M.D., F.R.C.S. (Plate XXIII.) 474

THE STRUCTURAL CHANGES IN THE TESTICLE OF THE DOG WHEN IT IS REPLACED WITHIN THE ABDOMINAL CAVITY. By JOSEPH GRIFFITHS, M.A. Cantab., M.D. Edin., F.R.C.S. Eng. (Plates XXIV. and XXV.) 483

SYMMETRICAL DEPRESSIONS ON THE EXTERIOR SURFACE OF THE PARIETAL BONES (WITH NOTES OF THREE CASES). By FRANCIS J. SHEPHERD, M.D. 501

ON THE MORPHOLOGY OF THE MUSCULUS STERNALIS. By F. G. PARSONS, F.R.C.S. 505

CONTRIBUTIONS TO THE HISTOLOGY OF THE HEDGEHOG. By E. W. CARLIER, M.D., B.Sc., F.R.M.S. (Plates XXVI., XXVII.) 508

NOTES ON THE DEVELOPMENT AND VARIATIONS OF THE ATLAS. By Professor A. MACALISTER, M.D., LL.D., D.Sc. 519

ON THE MAMMALIAN PELVIS, WITH ESPECIAL REFERENCE TO THE YOUNG OF ORNITHORHYNCHUS ANATINUS. By G. B. HOWES, F.L.S., F.Z.S. 543

TWO CASES OF SUBDIVISION OF THE POUCH OF DOUGLAS IN THE HUMAN FEMALE INTO THREE FOSSÆ. By O. J. KAUFFMANN 557

DIVERTICULUM (MECKEL'S) OF SMALL INTESTINE. By A. M. BUCHANAN, M.D. 559

NOTICES OF NEW BOOKS 564

INDEX 567

PROCEEDINGS OF THE ANATOMICAL SOCIETY OF GREAT BRITAIN AND IRELAND (WITH INDEX) ..... (xxxv) 569

3240.

Journal of Anatomy and Physiology.

THE COSTO-STERNAL ARTICULATIONS.[1]

By JAMES MUSGROVE, M.D., M.R.C.S., *Demonstrator of Anatomy Edinburgh University.*

IT must often have been observed that there is a great want of uniformity in the statements in the text-books regarding the presence of synovial cavities in the costo-sternal articulations. All are agreed that there is usually no synovial cavity at the junction of the first costal cartilage with the sternum, but regarding the rest, the statements differ considerably.

In order to ascertain the reason of this diversity of opinion, I made an examination of the joints in eighteen subjects, by making longitudinal transverse sections of the sternum, and thus exposing the joints. The most convenient way of doing this is by removing the whole sternum along with the costal cartilages, fixing the specimen in a vice, and making the section from above downwards with a bow-saw, which readily follows the curve of the sternum.

In every instance the cartilage of the first rib was joined directly to the sternum without the presence of a synovial cavity, as shown in the uppermost row (see Table, p. 4).

In connection with the second costal cartilage, there were in eleven cases on the right side, and ten on the left, two synovial cavities, separated from one another by a band, which in some cases was easily torn. This band was found, on microscopic examination, to be composed, not of fibrous tissue, but of fibro-cartilage—indeed, the dividing band in all costo-sternal joints which present two cavities seems to be composed of fibro-cartilage. Of the remaining second costo-sternal joints of the

[1] Read before the Anatomical Society, August 2, 1892.

right side, one presented no cavity, and six had one synovial cavity only, and this, in every case, was in the lower half of the joint—the part formed by the meso-sternum. On the right side one joint had no cavity, and the other seven had one, which in six cases was in the lower half of the joint, and in the seventh case it was difficult to decide whether it should be considered as belonging to the lower part only or to the middle.

In the third joint on the right side, twelve cases had one joint cavity, five had two, and one had no cavity at all; while in the corresponding articulation on the left side, ten had one cavity, seven had two, and there was one case in which the cartilage was directly in contact with the sternum.

The fourth joint on the right side presented in every case one or two cavities: in sixteen there was one, and in the other two cases there were two cavities, upper and lower, separated from one another by a band of fibro-cartilage. But on the left side this joint was in three cases without any synovial cavity, in thirteen there was one, and in two (the second and third cases in the list) there were two cavities in each.

The fifth joint also showed the predominance of a single synovial cavity on both sides, thirteen on the right and fourteen on the left having this character. Of the remaining five on the right side, three had no cavity, and the others had two; while on the left side, one had a double cavity, and in three the cartilage was directly joined to the sternum.

Passing down the list to the sixth joint, we observe a change. In no case is there a double cavity. On the right side five, and on the left seven, have no cavity at all. In the other cases there is a single cavity to each joint.

In the seventh there was a still further absence of diarthrodial joints. In ten cases out of eighteen on the right side, and in half the cases on the left, there was no cavity, and in the remainder there was only one.

Looking at these tables, one is struck with the fact that, passing from above downwards, there is a diminution in the number of synovial cavities. This is remarkable, considering the free movement of the lower part of the chest.

For comparison, I have represented the results in percentages, taking the highest figure in each case. Thus, in 100 per cent.

the first costo-sternal joint has no synovial cavity. In 61 per cent. on the right side and 55 per cent. on the left, the second presents two cavities. The third joint has one cavity in 67 per cent. on the right side and 55 on the left. The fourth shows one cavity in 89 per cent. on the right side and 72 per cent. on the left. The fifth, one in 72 per cent. on the right and 77 per cent. on the left. The sixth, one cavity in 72 per cent. on the right and 61 per cent. on the left. The seventh, on the right side, has no cavity in 55 per cent., while on the left side the number is only 50 per cent.

The tables further show that while in the case of the second joint, when one cavity only exists, it is the lower of the two, in most of the other joints it is in the upper part that the cavity is found. In many instances, however, the cavity was not distinctly to the upper or lower part of the joint, but in the middle. In such cases no letter *u* or *l* follows the figure 1 in the tables.

We see, then, that it is not difficult to account for the diversity of opinion in regard to the presence of synovial cavities in these joints, for the variation is considerable; and this variation is not due, so far as I have been able to make out, to sex or age. For in one instance—the case of a newly-born child, not included in the list—there were two cavities in the second joint of the left side and one in that of the right, one on each side in the third, and a trace of a cavity in the fourth, fifth, and sixth on each side, with a distinct cavity in connection with the seventh. (It may be mentioned that in this case there was a distinct cavity at the first costo-sternal articulation, but only on the left side.) But besides the actual variations which do exist to account for the difference of statement, two other causes have to be taken into consideration: first, the difficulty of finding the cavity when small, being placed sometimes at the upper part, sometimes at the lower, and again in front or behind; and second, the danger of artificially making a cavity by tearing the soft fibro-cartilage which unites the cartilage to the sternum. This is best avoided by using a finely-toothed saw, and thus preventing the tearing which might otherwise occur.

Case . .	1	2	3	4	5	6	7	8	9	10	11	12	13	14	15	16	17	18	*Results.*	
Right Side.																				
First Joint, . . .	0	0	0	0	0	0	0	0	0	0	0	0	0	0	0	0	0	0	18 no cavity.	100 per cent. have no cavity.
Second ,, . . .	2	2	2	2	2	1*l*	2	2	1*l*	1*l*	1*l*	0	1*l*	2	1*l*	2	2	2	1 no cavity, 11 two cavities, 6 one cavity.	61 ,, ,, two ,,
Third ,, . . .	1	2	1	1	1	1	1*u*	1*u*	1	2	2	0	1	2	2	1	1	1	1 ,, 5 ,, 12 ,,	67 ,, ,, one ,,
Fourth ,, . . .	1	2	2	1	1*u*	1	1*u*	1*u*	1	1	1*u*	1*u*	1	1*u*	1*u*	1	1	1	... 2 ,, 16 ,,	89 ,, ,, one ,,
Fifth ,, . . .	1	1*u*	1*u*	1	1*u*	1*u*	2	0	0	1	1	0	1	2	1*u*	1	1	1	3 ,, 2 ,, 13 ,,	73 ,, ,, one ,,
Sixth ,, . . .	1	1*u*	1*u*	1*u*	1	1*u*	1	0	0	1	1	0	1	0	1	0	1	1	5 ,, ... 13 ,,	72 ,, ,, one ,,
Seventh ,, . . .	1	1	0	1	0	0	0	0	1	1	0	0	1	0	1	0	0	1	10 ,, ... 8 ,,	55 ,, ,, no ,,
Left Side.																				
First Joint, . . .	0	0	0	0	0	0	0	0	0	0	0	0	0	0	0	0	0	0	18 ,, ...	100 ,, ,, no ,,
Second ,, . . .	2	2	2	2	2	1*l*	2	1	1*l*	1*l*	0	1*l*	2	1*l*	1*l*	2	2	2	1 ,, 10 ,, 7 ,,	55 ,, ,, two ,,
Third ,, . . .	1	2	1	2	2	1	1*u*	1*u*	1	2	2	0	1	2	2	1	1	1	1 ,, 7 ,, 10 ,,	55 ,, ,, one ,,
Fourth ,, . . .	1	2	2	1*u*	1	1	1*u*	0	0	1	0	1*u*	1	1*u*	1*u*	1	1	1	3 ,, 2 ,, 13 ,,	72 ,, ,, one ,,
Fifth ,, . . .	1	1*u*	1*u*	2	1*u*	1*u*	1	0	0	1	0	1*u*	1	1*l*	1*u*	1	1	1	3 ,, 1 ,, 14 ,,	77 ,, ,, one ,,
Sixth ,, . . .	1	1*u*	1*u*	1	1	0	1	1	0	1	0	0	1	0	1	0	0	1	7 ,, ... 11 ,,	61 ,, ,, one ,,
Seventh ,, . . .	1	1	0	1	1	0	0	0	1	1	0	0	1	0	1	0	0	1	9 ,, ... 9 ,,	50 ,, ,, no ,,

CONTRIBUTIONS TO THE CRANIOLOGY AND CRANIOMETRY OF PANJAB TRIBES.[1]

By R. HAVELOCK CHARLES, M.D., M.Ch., F.R.C.S.I., F.Z.S., *Surgeon-Captain Bengal Medical Service, Professor of Anatomy, Medical College, Lahore; Surgeon, Mayo Hospital, Lahore; Fellow of the Panjab University.*

IN the October number of vol. xxvi. of the *Jour. of Anat. and Phys.*, I brought for consideration some investigations I had made on the Craniometry of the Outcaste Tribes of the Panjab.

In that paper I stated some of the peculiar customs and habits of these peoples, and pointed out the ample field there was for the determination of race differences amongst them.

Many of the inhabitants of the Panjab give for themselves high-sounding and long genealogies. To quote one out of many instances:—It has been customary to admit as good the claims of various communities, whether Musalmán or Hindu, to origin from the blue blood of the Rajputs. These people testify for themselves, and having acquired a share of this world's goods, desire, like many in Europe, to have an ancestral tree as long as that of their proud neighbours of undoubted Rajput descent. Out of the mouth proceedeth many things! and there are just grounds for suspicion that unless there be added the testimony of scientific truth, which craniometry affords, to the folk-lore stories and paper pedigrees advanced by these tribes in proof of their pure descent, it is more than likely the genealogies in question have been fabricated to suit the snobbish aspirations of rising gentility fostered by the cupidity of a Brahman priesthood. If a tribe testifies of itself, its testimony is vain; but if craniometrical measurements bear out the testimony, it is

[1] In skull No. 40, Table I. in October number of the *Jour. of Anat. and Phys.*, owing to an error in copying the original, the Gnathic Index is wrongfully given as 50·9, instead of 93·3. A correction must also be made on page 25 in the average Gnathic Index, which will be 92·5, instead of 82 as there given.

of effect. As Sir William Turner well says, "by taking a combination of cranial characters we can lay down certain propositions as regards unmixed races of men which will be as distinctive as those afforded by the study of any other series of physical characters." Folk-lore is very well in its way, and interesting at times as illustrating the imitative and plagiaristic faculties of the natural man; but, like language, it should be taken more as denoting affinity in domicile, and not consanguinity in descent, unless backed by the unerring proofs afforded by craniometry and anthropometry.

Pure Rajput blood is admittedly found in Rajputana. Tribes of admitted Rajput descent are found in Himalayan hill states. People that claim Rajput consanguinity, but with suspicious right, are the Gourwa Rajputs, many Panjab Jats, certain Bhuta, Sial, and Panwar tribes, and many of the inhabitants of the Salt Range, &c., &c. Some think the distinction between Rajput and Jat social and not ethnic, others deny this. In this case, as in all others where there is doubt as to the ethnic position of any people, what is wanted is to establish from a considerable number of measurements of individuals of the true blood, a type, and from this judge the claims of tribes of doubtful lineage. It is to be hoped that, at a near future, much in this direction may be done, and if so, the information acquired will vivify the dry bones of the reports of settlement officers, whose opportunities for such investigations are unlimited. It is a pity that dissertations upon tribal origin in these reports should merely have their basis upon the idle boasting of garrulous village greybeards. It is also a pity that in successive reports on such subjects there should be merely a *réchauffé* of previous inquiries, carried out in the same unscientific manner.

The subject of the present paper is a sequel to that in the October number of the *Journal* of last year. It is a report upon an examination of 46 skulls from men and women who belonged most of them to the outcaste tribes of the Panjab. These, as also the previous 50, were collected by me in the Anatomical Museum of this College. The sex and age are authentic, as the individuals died in Lahore. Certain data can now be drawn from this series of 96 skulls, which may be taken as fairly representing the type of skill possessed by the lower

class Panjabi. The measurements, which are in the metric system, are more extensive than in the former paper.

The cranial capacity has, as before, been taken with mustard seed. Of the 46 skulls, 33 belonged to Musalmáns, and of these 6 were females (Nos. 28, 29, 30, 31, 32, and 33). The remaining 13 skulls were those of individuals calling themselves Hindus. Of the 13, only one was that of a female (No. 34). All are adult skulls, and they are, with the exception of 5, all dolichocephalic. Does this point to purity of race? Personally, I am of the opinion that the purity of the blood of these tribes is very doubtful. This may be considered in reading Sir William Turner's observation in his valuable *Report on the Crania*, p. 130 (Reports of H.M.S. "Challenger"):—"I am not disposed, therefore, to limit the unmixed races to those which are either dolichocephalic or brachycephalic in their cranial proportions."

Characters of the Skull Arch.—The arch was in some wide and full, in others narrow and irregular. The two sides were generally developed to an unequal extent, as shown by measuring the distance from the temporal ridge to the median line on either side. It is to be noted that the measurement was taken from the superior temporal line, not the inferior temporal line. In 25 skulls the right side was larger than the left. In 11 skulls the left was larger than the right, whilst in only 11 crania were the right and left sides symmetrically developed. In 4 skulls the sagittal suture stood strongly in relief—keeled. In a few the suture was depressed. The skulls, which were narrow and high, or narrow and keeled, were generally of low cranial capacity, save No. 20, which, although high and narrow, had a capacity of 1640 cb. cts. I have never heretofore met with a skull in the Panjab measuring so much. It is quite exceptional.

The temporal ridge is mostly remarkably well developed—strikingly so. The curve is long, and is always double, showing an upper and a lower line, separated by an interval which is broadest posteriorly. The interval may be as much as 25 mm. The lower of the two lines (muscular attachment) is the better marked, and is occasionally developed into a crest of considerable prominence (Nos. 5 and 6). The upper line (fascial attachment), though marked, cannot bear comparison with the lower. After

gradually approaching each other from behind forwards, they coalesce behind the ext. ang. process of the frontal. In Nos. 9, 18, 26, and 41 the superior temporal line extended as far back as the lambdoid suture, touching it 25 mm. above the asterion. In No. 9 the superior and inferior lines are separated posteriorly by a space of 20 mm., and where they cross the coronal suture by an interval of 11 mm. In No. 18 the respective intervals are 25 mm. and 13 mm. In No. 26 the intervals are 18 mm. and 12 mm. respectively. The teeth in these three skulls are quite worn down.

It is to be noted here that the usual definition of the term Stephanion, as being that point in the coronal suture where the temporal ridge crosses it, requires a rider on it to the effect that it is the point where the superior or inferior (according as may be determined) temporal line crosses the suture in such cases where the superior and inferior lines are separate at the crossing. I have taken it in the former sense, and so it has occurred that the *maximum* frontal diameter in Nos. 9, 18, and 26 is *less* than the minimum frontal, and the Stephanic index is therefore 100 or over. The term superior and inferior frontal would be better for description than maximum and minimum frontal, especially for such cases. There is indeed a marked difference in the development of this temporal ridge in the skulls under consideration and in those of Europeans. The ordinary, or rather exclusive, diet of the people whose skulls these were was *dàl* and *roti*. *Dàl* is the Hindustani word for the dried split peas of the pulses, or a food prepared from them. The *roti* or *chupathi* is an unleavened cake (like a Scotch pancake in shape, but *not* in consistence), made with barley or the lesser millets.

It can be understood that the jaw muscles have considerable exercise in the mastication of such food, and hence it happens that in most skulls over thirty-five years of age the cusps have vanished from the teeth—incisors to wisdoms—and there remain the flat and smooth crowns of the well-worn grinders. This may explain the superior development of the temporal muscle, and consequently the presence of a temporal ridge longer in extent, and with its superior and inferior temporal lines more prominent than in skulls whose owners lived on food

easier of mastication. It is an interesting example of excess of function leading to increase of development.

The Pterion.—In 17 per cent. epipteric bones were present. In my former series of 50 skulls epipteric bones were present in 32 per cent. In the total of 96 skulls, therefore, the percentage will be 25 per cent.

In Nos. 5, 10, 13, and 31 the pterion was fully obliterated and non-apparent. In one of these (31) a portion of the lambdoid was persistent, though the remaining sutures were fused. In no skull was there a direct articulation between the squamosal and frontal. In the greater number the size of the parieto-sphenoidal suture varied on the two sides—indeed, it was rather the exception to find these sutures of right and left sides of equal length.

The length of the pterion varied from only 1 mm. to 29 mm. In one skull alone did it occur that an epipteric bone was present without, at the same time, Wormian bones being found in some of the other sutures, lambdoid or sagittal.

It is exceptional to find the epipteric bones symmetrical on the two sides. A portion of the ant. inf. angle of the parietal may articulate with an epipteric bone, and a part with the great wing of sphenoid. The varieties found in the several skulls are so many and varied that it is evident they are due merely to individual peculiarity, and that differences in the shape of the pterion are not racial characteristics.

Wormian Bones.—There is nothing ethnologically important as regards these. I have carefully noted their presence, and found them at times of great size—skulls Nos. 7 and 12. In these there is a regular inter-parietal bone in place of the upper part of the supra-occipital. The os incae is not confined to Peru! Wormian bones are more frequent in the occipital region of these skulls, but they are to be found in all the sutures of the cranium; and I noted the presence of them even in the fronto-nasal suture of skulls Nos. 34 and 35, and a few in the fronto-malar suture of No. 8, though, in the skulls in question, there was not a single other of these *ossa triquetra* in any of the cranial or facial sutures. Generally the Wormian bones varied in number from 1 to 47, and in size from that of a pin's head to 6 centimetres in diameter. None of the crania were from hydrocephalic individuals.

Condition of Sutures.—In 60 per cent. Wormian bones were found in the cranial sutures. In only one instance (No. 45) was it found that the sagittal fused from before back; in all the others the fusion was from behind forwards. This is to be borne in mind in considering the supposed rule that in white races the fusion is from behind forwards, whereas in the black it is from before back.

As regards the serrations of the sutures, these were generally more intricate in the skulls of a high cranial capacity than those of low cubic measurement, though exceptions were found where a skull of 1110 cb. ct. had intricate sutures; whereas a skull of 1470 cb. ct. had sutures exceedingly simple in the arrangements of the serrations. As in the former series of skulls, I have again amongst these noted that frequently the lambdoid suture was very complex, while the sagittal and coronal were simple in their arrangement.

The metopic suture was present, complete, in No. 24, and existed at the glabella in 12 other skulls. Some of these had the remaining sutures intricate and partly fused, others had them simple and persistent.

The nasal bones were fused in four instances, and the inter-nasal suture was partially obliterated in five other examples. In one instance, whilst the inter-nasal suture was simple, the left nasal bone was anchylosed to the left superior maxilla.

Traces of the suture uniting the premaxillæ with the maxillæ were frequently found—in 15 instances. It was always posteriorly in the neighbourhood of the anterior palatine canal that these traces remained. In only one skull did the suture completely extend across the alveolar process—in No. 1. In this the suture was wholly persistent on left side; on the right side it was partially fused.

In no skull was there a trace of a suture dividing the malar bones.

I would wish here to comment upon the attempt made to deduce the age from the condition of the sutures, as set forth in a paragraph on page 134 of M. Topinard's *Anthropology* (English trans., 1890). The deductions there drawn are founded on the "Recherches sur l'état Senile du Crane," by E. Sauvage, Paris, 1870, and I quote them here:—"In a word, if the suture

is entire, the individual is about 35 years of age or less. If the posterior sagittal point is commencing to close, he is about 40 years. The ossification of the coronal suture close to the bregna would show that he was 50 or more. If the temporal suture is closed he would be 66 or more."

A reference to Nos. 9, 13, 19, and 26 will show that the sutures were either fused or fusing, although the ages of the individuals from whom the specimens were collected at death varied only between 31 and 35 years! In No. 31 even the parieto-sphenoidal was fused, though the age was but 40. Again, note skulls Nos. 6, 15, and 36, and it will be seen that the sutures were persistent, though the age in no case was under 50 years! Take, again, skull No. 7: the old man whose shoulders bore that skull had seen 70 summers and 70 winters pass, and yet his sagittal suture was only fused at the obelion, and his lambdoid at the lambda!

Is it possible, with this evidence before one, to draw any deductions, from the sutures alone, of the least scientific accuracy, which might be utilised in a medico-legal case as regards the age of the original owner of any particular skull?

It seems to me that the period at which fusion of the sutures commences, as well as the order in which it proceeds, is subject to such variations as to make speculations regarding age extremely hazardous when based only on evidence drawn from the persistence or non-persistence of the cranial sutures.

I have entered into this point the more fully as the skulls under observation were taken from bodies of a known age. The accuracy of the age is as great as it is possible to attain, save when it is taken from the evidence of a birth-certificate. The patients died in hospital, with a registered caste and age. The heads on removal had a numbered tin label fixed to each before being placed in the macerator. Any mixing of skulls was thus prevented. Criticism as to the value of the evidence of age, afforded by the sutures, conducted on this series of skulls, is not devoid of weight when it is seen that the collection has neither been grouped at random, nor brought together promiscuously.

If it be granted that the higher the cranial capacity is, the higher will have probably been the degree of exercise of the

brain, then it will be noted that in those skulls of highest capacity (1500 cb. cts. and over), the sutures have been longer in fusing than in other skulls of a lower capacity, though these latter were of lesser age! M. Broca's observations would thus be borne out. I may say that the probability is that none of the individuals whose skulls are under examination could read or write during life. There are, however, other methods than literary for obtaining mental exercise.

Jugular Foramen.—In about 71 per cent. the right is larger than the left. In upwards of 17 per cent. the reverse is the case, and in only 10 per cent. are the two foramina symmetrical. The greatest difference in the measurements is in skull No. 22, where there is as much as 10 mm. between the diameters of right and left foramina.

In two crania the left ant. condyloid foramen opens into the foramen lacerum posterius of same side.

The intra-jugular processes were very various in their development. They might be present on both sides, or on one side only (generally the left). They were oftener absent than present. In one skull the process bridged across the foramen on the left side.

Parietal Foramina.—Both were absent in 30 per cent. Frequently the foramen was absent on one side, and small or minute on the other. In less than 9 per cent. were the foramina large or of the normal size on both sides.

Post-Condyloid Foramina.—In upwards of 10 per cent. both foramina are completely absent. In upwards of 28 per cent. the foramina were very large on one side or the other, though not symmetrically so. It occasionally is found that the foramen on one side is larger than the ant. condyloid foramen of same side.

Ant. Condyloid Foramina.—In 1 skull the foramen is divided into two, and in 2 skulls the foramen of one side opens into the for. lac. post. of same side.

The Glabella.—The glabella is prominent in 50 per cent. Its size varied inversely to the cranial capacity. Amongst the 7 female crania it is prominent in 3 and flat in 4. I cannot say, therefore, that it is "scarcely perceptible in women."

Inion.—The inion is often small or faint, and very frequently

absent. Taken as a fixed measuring-point, the inion in many cases would be misleading, for its whereabouts could not be made out by palpation through the scalp in any of those instances where I have noted "small," or "faint," or "absent," which was as often as upwards of 63 per cent.

The Par-Occipital Process.—The par-occipital process is large or prominent in 28 per cent. In some skulls the process is large on one side, but small or absent on the opposite.

Where I have noted large or prominent, it is a *process*, and not merely the tubercular elevation more frequently seen at the outer extremity of the jugular ridge. To it in many of the skulls is attached the remains of a cord-like ligament. This was the upper part of the lateral occipito-atloid lig. which maceration had not altogether removed.

Cannot the frequency of the presence of this process in a state of considerable development be explained on the same grounds as I have stated in my remarks on the Foramen Magnum and Third Condyle?—that is, that it is large when the lateral occipito-atloid lig. and occ. lateralis muscle are well developed. That these are proportionately strong in individuals who are accustomed to carry loads upon their heads, the size being in correlation to the strain thrown upon the cervical joints.

Foramen Magnum.—In skull No. 43 the plane of the foramen looks very much forwards. The basion is on a higher plane than the vaginal process of the vomer! Owing to this, there was considerable difficulty in getting the compasses in position when taking the basi-alveolar diameter. The condyles in this skull are very small, and look as if they correspond only to that portion which is developed from the basi-occipital. The cerebellar fossæ are very deep, so much so that the outer portion of the occipital bone must have been almost in apposition with the spine of the axis. The inion and curved lines are absent, and the bone is quite smooth. The skull has the appearance as if the basi-occipital had been pushed inwards, and the skull drawn downwards in front and behind it. In No. 43 there is a tendency to the same deformity: here the plane of the basion is 5 mm. above that of the post. nasal spine. The condyles, though, are normal.

TABLE I.—*Showing the Average Measurements of the* S OF FORT
in each Group.

ments are in

Number of Skulls and Caste.	Circumferences.															
	Transverse.		Horizontal.			Saggital.						Inst Nasal.	Cephalic.	Gnathic.	Nasal.	Trans. Arch.
	Total.	Supra-Auricular.	Total.	Pre-Auricular.	Post-Auricular.	Total.	Sub-Cerebral.	Frontal.	Parietal.	Occipital (Cerebral).	Inio-Opisthion (Cerebellar).					
27 Musalmán (Male).	437	298	500	272	302	507	20	112	129	68	44	104	73·5	84·6	43·6	
6 Musalmán (Female).	413	275	477	218	259	473	19	100	117	64	43	104	71·2	94·2	50	
1 Hindu (Female).	440	281	520	248	272	525	21	113	130	64	55					
12 Hindu (Male).	434	291	504	230	265	505	20	107	123	73	46	101	69·5	92	47	

Number of Skulls and Caste.	Diameters.															
	For. Mag.	Skull.					Face.									
	Transverse.	Ant.-Post.	Long. Metopic.	Long. Iniac.	Transverse.	Alt. tud.	Ophryo Alveolar.	Bi-Ligomatic.	Inferior Frontal.	Superior Frontal.	Inter-Dacrya.					
27 Musalmán (Male).	30	182	180	175	128	132	61	126	93	104	19	52	91	73·5	91	
6 Musalmán (Female).	35	172	171	163	126	120	78	115	88	97	20	48	96	74·1	96·6	
1 Hindu (Female).	29	193	193	187	128	128	93	132	98	103	19	54	102	71·1	90	
12 Hindu (Male).	30	182	182	174	129	129	84	123	93	103	21	48				

Number of Skulls and Caste.	Indices.										Cranial Cap in Cb. Cm
	Cephalic.	Gnathic.	Nasal.	Orbital.	Palatal.	Altitudinal.	Facial.	Stephanic.	Frontal.	Foramen Magnum.	
27 Musalmán (Male).	70	91	48	81	74	73	66	90	75	85	1251
6 Musalmán (Female).	73	96	46	85	78	70	68	91	70	84	1150
1 Hindu (Female).	66	91	40	84	78	66	70	95	76	74	1360
12 Hindu (Male).	70	93	47	85	77	70	76	90	72	79	1356

S OF FORT

ıents are in .

Basi-Nasal.	Cephalic.	Gnathic.	Nasal.	Trans. Arch.	Temporal Ridge. R.	Temporal Ridge. L.
104	72·5	84·6	43·6		67	65
104	71·2	94·2	50		61	56
101	63·3	92	47		55	54
91	73·5	91	42·8		64	66
96	74·4	95·8	46		Very prominent. 49	50
102	68·8	89	50	the middle over Sagittal S.	Prominent. 62	55
102	71·4	80	50	Keel.	Faint. 54	55
103	73·8	98·5	42·3		63	65
99	70	96	66·6		50	47
97	77	89·7	50	over Sagittal.	70	70
99	67·5	90	46		74	73

LE II—

| | | |

LE II.—*co*

| late. | | |

—*continued.*

	Indic			
	Gnathic.	Nasal.	Orbital.	Palatal.
	90·3	54	82	38·3
	92	60	82	76·4
	93·4	51	72·5	71
	93·5	47	79·4	
	96·9	54		90·4
	98·9	47·8		85
	93·4	43		8
	94·6	47		
	91			42·1
		105·9		4
		91·2		
				92

continued.

Indices.								Character of Trans. Arch.	Temporal Ridge.	
Gnathic.	Nasal.	Orbital.	Palatal.	Alti-tudinal.	Facial.	Stephanic.	Frontal.		R.	L.
90·3	54	83	59·3	71·7	65·6	95·3	79	Broad and wide.	63	60
92	60	82	76·4	76·9	67	93·7	70	Narrow and high.	51	63
93·4	51	72·5	71·6	74·8	69·4	100	64	High and narrow.	41	38
93·5	47	79·4	66·6	73	69	83	68	Wide and rounded.	66	64
96·9	54	86·4	77	69	81	87	69	Wide and round.	64	65
98·9	47·8	85	73·4	71·7	66	86	68	Wide and flat.	64	68
93·4	43	84	86·3	69·7	60·6	95	71	Wide; keeled over Sagittal.	53	54
94·6	47	92·3	82	70·9	62	92	75	Very irregular.	58	55
91	42·8	85	76·4	72	65	98·8	72	Narrow and high.	53	50
105·9	43	78·9	72·7	65	72	86·7	63	Wide and full.	61	61
91·2	40·7	84	78·4	66·3	70·4	95	76	Narrow.	49	52
92	48	87	79·5	75·5	69	99	75	Narrow and high.	53	45

TABLE III.—*Analysis of Forty-six Skulls.*

Number of Skulls.	Average Cranial Capacity in cb. ct.	Average Indices.					Average Diameters in Millimetres.		
		Cephalic.	Altitudinal.	Gnathic.	Nasal.	Orbital.	Long.	Altitudinal.	Trans.
27 Skulls. Male Musalmán.	1351 = Mesocephalic. (Meg. = 6 Skulls, Mes. = 10 ,, Mi. = 11 ,,)	70 = Dolichocephalic. (Do. = 24 Skulls, Me. = 3 ,, Br. = 0 ,,)	= 73	91 = Orthognathous. (O. = 25 Skulls, M. = 2 ,, P. = 0 ,,)	48 = Mesorhine. (L. = 14 Skulls, M. = 9 ,, P. = 4 ,,)	81 = Microseme. (Mg. = 6 Skulls, Me. = 6 ,, Mi. = 15 ,,)	182	132	128
6 Skulls. Female Musalmán.	1150 = Microcephalic. (Meg. = 0 Skulls, Mes. = 0 ,, Mi. = 6 ,,)	73 = Dolichocephalic. (Do. = 5 Skulls, Me. = 0 ,, Br. = 1 ,,)	= 70	96 = Orthognathous. (O. = 4 Skulls, M. = 1 ,, P. = 1 ,,)	46. = Leptorhine. (L. = 5 Skulls, M. = 0 ,, P. = 1 ,,)	85 = Mesoseme. (Mg. = 1 Skull, Me. = 4 ,, Mi. = 1 ,,)	172	120	126
12 Skulls. Male Hindu.	1356 = Mesocephalic. (Meg. = 3 Skulls, Mes. = 3 ,, Mi. = 6 ,,)	70 = Dolichocephalic. (Do. = 11 Skulls, Me. = 1 ,, Br. = 0 ,,)	= 70	93 = Orthognathous. (O. = 11 Skulls, M. = 1 ,, P. = 0 ,,)	47 = Leptorhine. (L. = 5 Skulls, M. = 5 ,, P. = 2 ,,)	85 = Mesoseme. (Mg. = 2 Skulls, Me. = 6 ,, Mi. = 4 ,,)	182	129	129
1 Skull. Female Hindu.	1360 (Meg. = 0 Skulls, Mes. = 1 ,, Mi. = 0 ,,)	66 = Dolichocephalic.	= 66	91 = Orthognathous.	40 = Leptorhine.	84 = Mesoseme.	193	128	128
Total Average of 46 Skulls,	1304 = Microcephalic.	69·7 = Dolichocephalic.	= 69·7	92·7 = Orthognathous.	45·2 = Leptorhine.	83·7 = Microseme.			
Analysis of 46 Skulls,	(Meg. = 9 Skulls, Mes. = 14 ,, Mi. = 23 ,,)	Do. = 41 Skulls, Me. = 4 ,, Br. = 1 ,,		O. = 41 Skulls, M. = 4 ,, P. = 1 ,,	L. = 25 Skulls, M. = 14 ,, P. = 7 ,,	Mg = 9 Skulls, Me. = 17 ,, Mi. = 20 ,,			

TABLE IV.—(TABLE III. = *Analysis of 50 Skulls—taken from former Paper in October number of the "Journal of Anat. and Phys.,"—for comparison with preceding*).

Number of Skulls.	Average Cranial Capacity in cb. ct.	Average Indices.					Average Diameters in Millimetres.		
		Cephalic.	Altitudinal.	Gnathic.	Nasal.	Orbital.	Long.	Altitudinal.	Trans.
36 Skulls. Male Musalmán.	1375 = Mesocephalic. (Meg. = 9 Skulls, Mes. = 12 ,, Mi. = 15 ,,)	70 = Dolichocephalic. (Do. = 36 Skulls, Me. = 0 ,, Br. = 0 ,,)	= 72	92 = Orthognathous. (O. = 31 Skulls, M. = 5 ,, P. = 0 ,,)	49·6 = Mesorhine. (M. = 21 Skulls, P. = 5 ,, L. = 10 ,,)	88·8 = Mesoseme. (Mg. = 16 Skulls, Me. = 11 ,, Mi. = 9 ,,)	183	132	129·5
9 Skulls. Female Musalmán.	1226 = Microcephalic. (Meg. = 0 Skulls, Mes. = 1 ,, Mi. = 8 ,,)	71·7 = Dolichocephalic. (Do. = 9 Skulls, Me. = 0 ,, Br. = 0 ,,)	= 73	94 = Orthognathous. (O. = 7 Skulls, M. = 2 ,, P. = 0 ,,)	51·4 = Mesorhine. (M. = 4 Skulls, P. = 3 ,, L. = 2 ,,)	89·8 = Megaseme. (Mg. = 4 Skulls, Me. = 3 ,, Mi. = 2 ,,)	172·3	127	122·3
4 Skulls. Male Hindu.	1298 = Microcephalic. (Meg. = 0 Skulls, Mes. = 2 ,, Mi. = 2 ,,)	70 = Dolichocephalic. (Do. = 4 Skulls, Me. = 0 ,, Br. = 0 ,,)	= 71·6	92·5 = Orthognathous. (O. = 4 Skulls, M. = 0 ,, P. = 0 ,,)	47·6 = Leptorhine. (M. = 1 Skull, P. = 1 ,, L. = 2 ,,)	88·9 = Mesoseme. (Mg. = 2 Skulls, Me. = 1 ,, Mi. = 1 ,,)	180·5	127	124·8
1 Skull. Female Hindu.	1290 = Microcephalic.	68·6 = Dolichocephalic.	= 70·4	90·3 = Orthognathous.	53·3 = Platyrhine.	84 = Mesoseme.	180·5	127	124·8
Total Average of 50 Skulls,	1340 = Microcephalic.	70·6 = Dolichocephalic.	= 71	91·5 = Orthognathous.	49·8 = Mesorhine.	88·9 = Mesoseme.			
Analysis of 50 Skulls,	Meg. = 9 Skulls. Mes. = 15 ,, Mi. = 26 ,,	Do. = 50 Skulls. Me. = 0 ,, Br. = 0 ,,		O. = 43 Skulls. M. = 7 ,, P. = 0 ,,	M. = 26 Skulls, P. = 10 ,, L. = 14 ,,	Mg. = 22 Skulls, Me. = 16 ,, Mi. = 12 ,,			

TABLE V.—*Table compiled from the two preceding (Tables III. and IV.), showing the Indices and Cranial Capacity of a Panjab Skull of a Low Caste individual, as deduced from the Examination of 96 specimens.*

	Cranial Capacity in Cb. Cts.	Cephalic.	Average Indices.			
			Altitudinal.	Gnathic.	Nasal.	Orbital.
Total Average of 96 Skulls, . .	1340 = Microcephalic.	70·1 = Dolichocephalic.	70·3	92·1 = Orthognathous.	47·5 = Leptorhine.	86·3 = Mesoseme.
Analysis of 96 Skulls, . . .	Meg. = 18 Mes. = 29 Mi. = 49	Do. = 91 Me. = 4 Br. = 1	——	O. = 84 M. = 11 P. = 1	L. = 51 M. = 24 P. = 21	Mg. = 31 Me. = 33 Mi. = 32

TABLE VI.—*Table of Comparison of Measurements of Heads of live Chuhras of the Panjab with measurements taken on the Skulls of Panjabi Chuhras. The former are from Mr Risley's Tables—pages* 830 *and* 836, *Vol. II., "Tribes and Castes of Bengal." The latter have been recorded by myself from specimens now in my possession.*

	Indices.		Diameters.					
			Nose.		Skull.		Face.	
	Nasal.	Cephalic.	H.	Br.	L.	Br.	Inferior Frontal.	Bi-Zigomatic.
80 Chuhras—taken during life, ... (Risley.)	75·2	73·4	48	36·1	186·7	137·1	108·2	132
70 Chuhra Skulls, Adult Males, ... (Havelock Charles.)	48	70	51	25	182	128	93	126·5

A comparison of Craniometrical Measurements on the live subject with those carried out on the macerated skull will not be without interest. In both instances the Caste was alike. The chief discrepancy is in the Nasal Measurements—especially the transverse. The breadth, taken at the widest portions of the Alae, does not seem to correspond to the greatest transverse diameter of the Anterior Nares measured on the skull. There is a greater similarity in the vertical measurements of the Nose. It will be noted, though, that, contrary to expectation, the height is greater on the skull than on the live subject. I do not attempt to explain this. I am not aware whether M. Broca, in his discovery that the Nasal Index is one of the best for the purpose of distinguishing the various races of mankind, would expect his observations on particular tribe, taken on the live subject, to correspond to observations taken on the *skulls* of members of the same tribe.

ON THE BRAIN OF THE LATE GEORGE GROTE, F.R.S., WITH COMMENTS AND OBSERVATIONS ON THE HUMAN BRAIN AND ITS PARTS GENERALLY.

By the late Professor JOHN MARSHALL, LL.D., F.R.S., *Professor of Surgery in University College, London, President of the General Medical Council.* (PLATES I., II., III.)

THE late Mr Grote, the distinguished Historian of Greece, expressed in writing, eight years before his death, the following wish :—

"I desire that after my decease my cranium shall be opened by the Professor of Anatomy in University College, London, or by some other competent Anatomist.

"I desire that my brain shall be carefully weighed and examined, and that the weight thereof shall be communicated to Professor Bain, together with any other peculiarities which may be found, especially whether the cerebellum is deficient as compared with the cerebrum. "GEORGE GROTE.

"*July 7th*, 1863."

Mr Grote died in June 1871; and, at the request of Professor Sharpey, with whom Professor Bain had previously communicated, but who desired to be relieved from the proposed task, I duly examined the cranium and brain. The results of this examination, together with certain comments and observations suggested and made during the prosecution of the inquiry, are recorded in the following report :—

1. *Weight and General Appearance of the Brain.*

The entire brain, when removed from the cranium in the usual manner, was found to weigh, with its coverings of arachnoid and pia mater, but drained of the cerebro-spinal fluid which it contained, exactly 49¾ ozs. avoirdupois. About 12 drachms of such fluid were collected. The bones of the skull,

along the line of section, were of unusual thickness. The dura mater adhered strongly at the vertex, and the Pacchionian glands were large. The cerebral arachnoid presented a few faint traces of opacity. The vessels of the pia mater were collapsed, whilst the veins traversing the cerebrum and the several cranial sinuses contained a reddish serum with narrow soft coagula. The cerebrum and cerebellum, still invested by their membranes, were soft and flaccid, and *easily fell out of shape;* and the cerebral convolutions, so far as they could be observed, appeared to be very broad. When, afterwards, the membranes were removed, this breadth of the convolutions became, as will hereafter be particularly mentioned, still more obvious.

The cerebrum, cerebellum, and pons, with the medulla oblongata, were weighed separately, after the brain had been partly hardened in spirit, and after the complete removal of the membranes and blood-vessels. For purposes of comparison, several male brains were prepared in a similar manner. The specific gravity of the grey and white substance of the brain was not ascertained; but the appearance and texture of both were natural, if we except the pallor of the former and the flaccidity of both.

2. *Weight of the Brain, as compared with the Average Brain-Weight.*

Taking the absolute brain-weight above recorded, viz., 49·75 ozs. av., and comparing it with the average weight of the adult male European brain in persons of the prime of life, say from 30 to 40 years old, we find that Mr Grote's brain was ·75 oz. heavier than the average standard adopted by Welcker, which is 49 ozs. av., but 1·55 oz. heavier than the average weight of English male brains, deduced from the extensive Tables of Dr Boyd, which is 48·2 ozs.

3. *Weight of the Brain as modified by Age.*

It is now well established that, at whatever period of life the brain may attain its maximum size, a period differing per-

haps according to the use made of the organ, its weight usually begins to decrease, though very slowly, between 40 and 50 years of age, and then goes on diminishing with progressively increasing rapidity up to the end of life. It would seem probable, indeed, that in this way the brain may undergo a loss of more than 3 ozs., between the ages of 40 and 80 years. Dr Boyd's Tables, as investigated by Dr Thurnam, appear to show that, whilst the average brain-weight of males between the ages of 30 and 40 is 48·2 ozs., between 60 and 70 it is 46·4 ozs., and between 70 and 80 only 45·5 ozs. We may therefore, on these data, take 46 ozs. as the average male brain-weight at 75 years of age, that is to say, 2·2 ozs. less than the average brain-weight of males between 30 and 40, which, as already stated, appears to be 48·2 ozs.

Now, Mr Grote died in the 76th year of his age; and, accordingly, it is not unreasonable to assume that between the age of 30 and 40 his brain may have weighed 2·2 ozs. more than at the time of his death, that is to say, about 52 ozs. When thus corrected for the effects of age, the weight of Mr Grote's brain during early manhood may have been from 3 ozs. to 3·8 ozs. above the average or standard weight, according as we accept the estimate of Welcker (49 ozs.), or the figures of Dr Boyd (48·2 ozs.). Or, putting the case in another way, if the average weight of the brain at 75 years of age is, according to Dr Boyd's Tables, 46 ozs., then the brain of Mr Grote weighed at that age 49·75 ozs.,—that is, 3·75 ozs. above the average. Even if we accept the higher standard of early manhood adopted by Welcker, we still find that Mr Grote's brain was about three oz. above the expected average weight at the age at which he died.

That Mr Grote's brain had really wasted from the effects of age is certain. The accumulation of 1½ oz. of fluid in the cavity of the cranium, and the unusual thickness of its walls, are conditions indicative of such wasting.

The external form of Mr Grote's head was good; and those who were acquainted with him, would, I think, admit that he had a large and well-developed cranium, and would have anticipated, accordingly, that his brain would be above the average in size. I took the precaution, at the time of the examination, to

measure a hat recently worn by the deceased, and also to ascertain the circumference of the head over the hair, before any steps were taken for the removal of the brain. The interior of the hat measured $8\frac{3}{8}$ inches from front to back, and $6\frac{3}{4}$ inches in breadth; its circumference inside was $23\frac{3}{4}$ inches. This is a large-sized hat; and, even allowing for the space occupied by the hair during life, it would indicate a more than ordinary size of head. Mr Galton informs us that the "average circumference of the English gentleman's head is from $22\frac{1}{4}$ to $22\frac{1}{2}$ inches." Moreover, whilst out of 99 cases[1] he "met with 13 under 22 inches, he found only 8 instances in which the head was 24 inches or upwards in circumference."

The sizes of hats, however, are obviously modified by individual peculiarities, quite irrespective of the actual dimensions of the heads to which they are adapted: first, in accordance with the quantity and character of the hair, which takes up more room in some cases than in others; and secondly, on account of the mode in which the hat is worn, whether high or low upon the head. Besides this, the measurement around the inside of a man's hat is half an inch, more or less, in excess of the measurement around his head; for the head being of irregular and the hat of regular outline, the former is received into the latter, in the same way as an angular figure of smaller dimensions can only be inscribed in an ellipsoid of larger dimensions. Again, the margin of a hat, which is the part actually measured, is often slightly everted, so that the part a little deeper in, which holds on to the head, is a trifle less in circumference than the actual margin. These apparently unimportant details may help to explain the remarkable difference which I found between the internal circumference of the hat worn by Mr Grote, and the external circumference of the head taken after death. As already mentioned, the hat measured $23\frac{3}{4}$ inches, whilst, to my surprise, the head measured only $22\frac{1}{4}$ inches. This difference of $1\frac{1}{2}$ inch may perhaps be partly accounted for by the mode in which Mr Grote wore his hat, which was, I believe, rather low on the back of the head. Something also may be due to differences in the quantity and relative stiffness of the hair during life and after death. But

[1] It should stand, "99 cases of distinguished scientific men."—*F. Galton.*

chiefly, it must doubtless be attributed to the wasting of the soft tissues of the scalp during the progress of an exhausting disease, and to the exsanguine condition of those tissues when life was extinct. I have myself observed that, after a severe illness, my own hat fitted so loosely as to descend lower than usual upon the head.

It is probable, that had Mr Galton measured the hat of the deceased Historian, he would have been led to regard the head which had worn it as amongst those above the average in size. It is evident, however, that too much value may be attached to measurements of hats, as the conditions indicated above are in themselves so variable. It must also be pointed out that such measurements, or even those of the circumference of the head, afford but very imperfect data upon which to infer the size of the cranial cavity and its contained brain; for neither measurement takes into account the height of the skull, and the thickness of its walls. Nor do they indicate other points of interest, such as the relative length and breadth of the cranium, and the dimensions of the portions devoted respectively to the lodgment of the cerebrum and the cerebellum.

4. *Weight of the Brain as modified by Disease.*

The question may here be put, whether, besides the diminution in Mr Grote's brain due to age, there might not also have been wasting of that organ during the last months of his life, attributable to the renal disease, accompanied by albuminuria, from which he suffered. Most probably some abnormal wasting really occurred during the six months, for which, in Dr George Johnson's opinion, that disease had lasted. We possess, however, no precise information concerning the effects of that or of other diseases on the nutrition of the nervous centres. It is well known that the brain resists the wasting due to starvation more persistently than any other of the soft tissues or organs of the body. It may also be admitted, that the Tables which serve us at present as the basis of comparison of one brain with others, are founded on the weights of brains which have themselves been modified by, or at least subjected to the influence of, various diseases. But one disease may affect the

nervous centres more than others—head diseases, heart diseases, lung disease, and stomach disease, may each be supposed to affect them differently; and renal disease, associated with albuminuria, may have a decided atrophic influence over them. The attention of Pathologists may be called to this question. At my suggestion, Dr Boyd undertook to reduce the very large number of data which he possessed, calculated to throw light on the influence of the cause of death, on the nutrition of the brain and its several parts.

5. *Weight of the Brain as compared with the Weight and Height of the Body.*

I am informed, by Mr Arthur Grote, that of late years his brother's weight fluctuated between 11 stone 7 lbs. and 11 stone 10 lbs.—*i.e.*, between 161 and 164 lbs. av. Assuming 162 lbs. as the approximate weight of the body, the ratio of the weight of the brain to that weight would be as 49·75 ozs. to 2592 ozs., or as 1 to 52; or, if we correct the brain-weight for the effects of age, the ratio would be as 52 to 2592, or nearly as 1 to 50. This, even, is an unusually low ratio, and points to the occurrence of considerable wasting of the brain from age or disease, or from both causes combined. Tiedemann arrived at the conclusion, that in adult males the weight of the brain to that of the body varied from 1 to 38 to 1 to 45. According to Dr Peacock's Tables, the average in the adult is about as 1 to 37·2; and from Dr Boyd's Tables, as analysed by Dr Thurnam, the average in males between 60 and 70 years of age is as 1 to 36, and between 70 and 80 years as 1 to 37·3. In the very fat and in the very lean, the proportion may vary from 1 to 100, to 1 to 27; but these sources of deviation may both be excluded in the present case, for Mr Grote was neither stout nor thin. In what way, therefore, can we account for the ratio being so low as 1 to 50 or 52, except on the supposition of the effects of disease being superadded to those of age?

The relation between the weight of the brain generally to the stature, has not, so far as I am aware, been hitherto sufficiently well studied, to enable it to be expressed in definite terms or numbers; but an opinion has been advanced by

Parchappe that tall persons have not only absolutely but relatively larger brains than short ones. This, however, is more than doubtful, as will presently be shown in discussing the influence of stature on the weights of the cerebrum and cerebellum respectively.

6. *Weight of the Brain as compared with the Brains of Other Eminent Men.*

Notwithstanding the limited information conveyed in the record of the mere weight of any given brain, a legitimate interest will always be attached to the determination of even this insufficient datum in the cases of men of eminent ability. At present, however, we possess a very brief list of such observations, and it is in every way desirable that it should be extended. It is probable that many of the examples which have been recorded, owe that distinction to the fact that they are cases of brains of unusual weight; and we must certainly be cautious before we conclude that remarkable intellectual capacity and ability can only be exhibited by those who have very large brains, or that those qualities are exhibited in strict accord with the mere size of the encephalon.

In the instances of Cromwell, Pascal, Byron, and the first Napoleon, there can be no reason to doubt that the size of the brain was unusually great, but reliance cannot be placed on the exact weight assigned to each brain. In regard to more recent examples, in which the weight of the brain has been accurately noted and recorded, certain corrections are evidently needed, before we can justly estimate the influence of the weight of the brain on the intellectual endowments of any given person.

Dr Thurnam collected the weights of the brains of fifteen eminent and cultivated men. He showed that, supposing we take Welcker's standard of 49 ozs. as the average or mean weight of the brain in the fully-developed European male, 11 brains were above that standard, 1 brain equalled it, and 3 were below it. The late Dr Whewell, who was an intellectual giant, and whose death was caused by accident, and not disease, had a brain only just of the average size; Tiedemann, a learned and distinguished Anatomist and Physiologist, died possessed of a brain weighing only 44·2 ozs., or 4¾ ozs.

below the average; whilst, at the other end of the scale, Cuvier and Abercrombie (if we may accept the records of these as accurate) had brains weighing 64·3 ozs. and 63 ozs. respectively. Cuvier's brain therefore showed an excess over Welcker's standard of 15 ozs., and over Tiedemann's brain of no less than 20 ozs.; in other words, it was nearly 1 lb. heavier than the standard, and $1\frac{1}{4}$ lb. heavier than Tiedemann's brain; or again, about $\frac{5}{15}$ or nearly $\frac{1}{3}$ larger than the former, and $\frac{5}{11}$ or nearly $\frac{1}{2}$ as large again as the latter!

But the weights, as severally recorded, require both correction and extension to be really valuable. They take no account of that important factor, the internal organisation and special quality of the brain, and its grey and white substance; though the age at death is stated, no allowance is made for its undoubted effects; the influence of disease is ignored, although it is obvious that this may have been such as either to raise or lower the specific gravity of the brain substance, or to cause either enlargement or wasting in different cases; in Cuvier's brain, for example, there was on one hemisphere a large mass which might have been the result of some abnormal condition. Again, no note is taken of the weight or height of the body as influencing the size of the encephalon; and lastly, the relation between the size of the cerebrum and cerebellum is in no instance set forth. Moreover, we possess no observations on the brain-weights of distinguished women; and in regard to men, it has been chiefly those who have been devoted to science whose brains have hitherto been weighed, whilst the weight of the brain in literary men, poets, artists, and musicians has not been ascertained or published. Further and varied examples, accompanied by many collateral data, are accordingly much needed in connection with this inquiry.

As the effects of age are, at all events, undoubted, and capable of tolerably exact recognition, I may venture, by way of illustration, to submit, side by side with a Table copied from Dr Thurnam (I.), another (II.) in which the weights of the brains are corrected for age, on the calculation, based on Dr Boyd's extensive researches, that the encephalon may suffer a loss of 3 ozs. and a fraction between the ages of 40 and 80 years.

Table I. Recorded Brain-weights.			Table II. Brain-weights corrected for age.		
Names.	Ages.	Weight in ounces.	Names.	Ages.	Weight in ounces.
Cuvier . . .	63	64·3	Cuvier . . .	40?	65·9
Abercrombie . .	64	63	Abercrombie . .	—	64·7
Spurzheim . .	56	55	Campbell . .	—	56·7
Dirichlet . .	54	53·6	Spurzheim . .	—	56
De Morny . .	50	53·6	Webster . . .	—	55·5
Webster, D. . .	70	53·5	Gauss . . .	—	55·3
Campbell, Lord .	80	53·5	Chalmers . .	—	54·8
Chalmers . .	67	53	Dirichlet . .	—	54·3
Fuchs . . .	52	52·9	De Morny . .	—	54
Gauss . . .	78	52·6	Fuchs . . .	—	53·5
Dupuytren . .	58	50·7	Dupuytren . .	—	51·9
Whewell . .	71	49	Whewell . .	—	51·2
Hermann . .	51	47·9	Hermann . .	—	48·4
Tiedemann . .	80	44·2	Tiedemann . .	—	47·4
Hausmann . .	76	43·2	Hausmann . .	—	45·4
Average of 10 persons from 50 to 70 years . .		54·7	Average of 10 persons from 50 to 70 years . .		56·2
Average of 15 persons from 50 to 80 years . .		52·7	Average of 15 persons from 50 to 80 years . .		54·3

The influence of age alone is such that Lord Campbell's position is raised from the 7th to the 3rd place in the series; that Gauss the Mathematician ascends from the 10th to the 6th place; that Spurzheim loses one place; that not only Campbell and Gauss, but also Webster and Chalmers take precedence of Dirichlet (Mathematician) and De Morny (Politician); and lastly, that the relative position of the names from Fuchs (Pathologist) downwards, with the exception of Gauss, remains unaltered. In spite of the considerable additions made to the weights of Tiedemann's and Hausmann's brains, owing to their advanced age, their positions in the two Tables remain the same.

The weights of the brains of 5 eminent men, comparatively recently dead, are here shown, first, as recorded, and secondly, as corrected for age.

TABLE III. Brain-weights as recorded.			TABLE IV. Brain-weights as corrected for age.		
Names.	Ages.	Weight in ounces.	Names.	Ages.	Weight in ounces.
Thackeray . .	52	58·5	Thackeray . .	40?	59
De Morgan . .	65	52·75	De Morgan . .	—	54·5
Grote . . .	75	49·75	Babbage . . .	—	52·5
Babbage . . .	79	49·5	Grote . . .	—	52
Grant . . .	80	45·5	Grant . . .	—	48·75
Average of 5 persons from 50 to 80 years . .		51·2	Average of 5 persons from 50 to 80 years . .		53·35

The high weight of the late Mr Thackeray's brain will not escape attention. It will be noticed that, when corrected for age, Mr Babbage's brain requires to be moved up one place, interchanging with Mr Grote's. The size of Mr Grote's brain, whether taken as recorded, or as corrected for age, places it 7th from the bottom in the total number of 20 brains here tabulated, coming near to the brains of Babbage, Dupuytren, and Whewell. Judged by the 19 examples with which it is here grouped, it cannot be said to have been a very large brain. It did not reach the macrocephalic standard of Welcker, 53 ozs. Nevertheless, it was a *large* brain; its actual weight, 49·75 ozs., is within 2·55 ozs. of the mean weight of the above-named 20 brains, viz., 52·3 ozs.; and if we exclude the very exceptional brains of Cuvier and Abercrombie (the former of which had something abnormal about it), the mean weight of the remaining 18 examples is 50·6 ozs., showing a relative deficiency in reference to this mean, on the part of Mr Grote's brain, of only 1 oz. In proof of the very exceptional character of Cuvier's and Abercrombie's brains, it may here be stated, that in about 700 brains of males recorded in Dr Boyd's Tables relating to the sane, at all ages from 20 to 80, the maximum weight was 60¾ ozs.; whilst amongst 295 insane males, from 30 to 80 years of age, the maximum was 58¾ ozs.: it must be remarked, however, that these cases are all derived from the poorer classes. Again, out of 964 male and female brains, at all ages, collected by R. Wagner, only 13 weighed 60 ozs. and upwards.

The necessary data for forming a critical estimate of the respective influence of stature, bulk of body, and disease, on the brain-weights of the above-mentioned eminent men, cannot now be sufficiently accurately determined. Some at least of those persons were of lofty stature and of good muscular development, as for example Thackeray, De Morgan, Grant, and Dirichlet; and it might be held that this would, in part, explain the large size of their brains, for the brain is absolutely larger in tall and muscular men, on the same grounds probably as it is larger in men than in women, viz., as a consequence of the greater bulk of the volitional, emotional, and purely reflex nervous apparatus, required to control or excite their larger muscular system. It is possible, indeed, that persons of great stature may, by virtue of their large nervous centres, be endowed with certain peculiarities of mental constitution, such, for example, as endurance and application, as well as of rare or exceptional bodily power. But the size of the brain is not entirely dependent on the stature, for Tiedemann was a tall and well-developed man, and yet he is low in the preceding list. Hausmann was also tall, and yet his brain was the smallest of the 20 examples collected. On the other hand, of those mentioned some were only of average height, though in some of these the brain was above the average weight. If it were possible, it would certainly be right to take into consideration the stature of distinguished men, whilst endeavouring to set a proper value on their cerebral development. This would be of even more importance, as will immediately appear, in reference to the relative volumes of the cerebrum and cerebellum, a subject concerning which we have little or no information in the case of eminent men.

7. *Weights of the Cerebrum and Cerebellum, absolute and relative.*

The special wish expressed by Mr Grote, that it should be observed in his case "whether the cerebellum was deficient as compared with the cerebrum," was not at first known to me; but I had fortunately weighed these parts soon after the brain had been partly hardened in spirit, and its membranes had been removed. The entire brain in that state weighed 39 ozs., of

which the cerebrum contained 34·25 ozs., the cerebellum 4 ozs. and the pons with the medulla oblongata ·75 ozs. By calculation, as the recent brain weighed 49·75 ozs., we obtain 43·7 ozs. for the cerebrum, 5·1 ozs. for the cerebellum, and ·95 oz. for the pons and medulla oblongata. Now, this would give a ratio of 8·57 to 1 for the relative weights of the cerebrum and cerebellum. According to the calculations of Dr Reid and Huschke, the average ratio between these parts in the adult male varies from 8·57 to 1, to about 8 to 1; and since, further, it appears that the weights of these organs, as recorded in Dr Boyd's Tables (*op. cit.*, 253), in 95 males, aged between 70–80 years, and of various heights, furnish an average ratio to each other also of nearly 8 to 1, it would seem that in Mr Grote's case, the proportionate weights of the cerebrum and cerebellum to each other were, as compared with male adults generally, nearly normal, and as compared with those of his own decade of existence, absolutely normal. But a closer consideration of the facts shows that this was not really the case, and serves to illustrate the fallacy of relying unreservedly on numerical averages. For, as already mentioned, the influence of stature on the relative size of the encephalon, as compared with that of the body, requires further investigation; so that we may be able, not only to compare both the absolute and the relative weights of the cerebrum and cerebellum in individuals of high or low stature, with the *average* absolute and relative sizes of those organs in persons of *average* stature, but to compare, in these respects, tall persons with tall persons, and short ones with short ones. In this way alone—that is, by contrasting persons of corresponding or approximative stature, as well as of corresponding or approximative age—can, not merely the weights of the cerebrum and cerebellum as compared with the body, but their relative weight as regards each other, be estimated truly.

Reverting now to the proper subject of this paper, and applying the result of the preceding conclusions to the inquiry concerning the relative weights of Mr Grote's brain as compared with the stature, and of the parts to the stature and the weight, we find that, whereas the average proportion between the encephalon and the height of the body, from 70 to 80 years of age, is ·6925 oz. to every inch of height, in Mr Grote it was ·6958 oz. to every inch. Moreover,

of the several parts of the encephalon, the average proportion of cerebrum to the height of the body is as 1 oz. to 1·66, or ·6027 oz. to each inch, whilst in Mr Grote it was 1 oz. to 1·605 inches and ·605 oz. to an inch. The average cerebellar ratio is 1 oz. to 13·3 inches, or ·0736 oz. to 1 inch, whereas in Mr Grote it was 1 oz. to 13·8 inches, or ·07608. Furthermore, the average proportion of the cerebrum to the cerebellum, between 70 and 80 years of age, is 7·96 to 1, whereas, as already stated, in Mr Grote it was 7·95 to 1.

The due appraising of these calculations is evident, and, as I have already stated, would confirm the conclusion that Mr Grote's brain possesses a relative development of cerebrum and cerebellum in very strict comparison with the average proportions. But if we next proceed, as it is evident we should do, to compare the encephalon and its parts in Mr Grote, who was a tall man, viz., 71·5 inches in height, with the same parts in similarly tall persons, *i.e.*, in those who reached 70 and 72 inches of stature, we find the several quantities and proportions are very different. Thus, the figures and proportions recorded show that in 67 persons, varying in height from 70 to 72 inches, the average weights of their encephalon, cerebrum, cerebellum, and pons were 48·18, 41·6, 5·47, and 1·11, whereas in Mr Grote their comparative weights were 49·75, 43·7, 5·1, and ·95. Again, the proportions of these several figures to the stature, instead of being 1 oz. to 1·47, to 1·7, to 13, and to 64, were 1 to 1·43, to 1·65, to 13·8, and to 68 inches; or, as otherwise expressed, the average growth of these several organs in persons of 70 to 72 inches in height, in proportion to their height, is found to be ·678, ·586, ·077, and ·015 oz. to each inch of stature, whilst in Mr Grote they were ·695, ·611, ·071, and ·013 respectively. Hence, it seems to be firmly established that if we allow for age alone, Mr Grote's cerebrum and cerebellum closely approximate to the usual size, but that if we also take stature into account, the cerebrum was somewhat above and the cerebellum very little below the usual size of these organs in persons of corresponding height; the difference of increase in the former amounts to $\frac{1}{25}$ and that of diminution in the latter to about $\frac{1}{180}$ of the average size of these parts respectively; and that, whereas the average proportions of the cerebrum to the cerebellum, in persons of 70 to 72 inches in height has been found to be 7·6 to 1, in the case of Mr Grote it was 8·57 to 1.

The final answer, therefore, to the question which Mr Grote desired should be especially replied to, "whether" in his case "the cerebellum was deficient as compared with the cerebrum," is that it was so deficient; but this relative deficiency was due to an absolute increase of the cerebrum, rather than to any important diminution of the cerebellum. Indeed, as observed by the eye alone, this latter organ appeared to be relatively below the average size; for it was overlapped largely, both at

the sides and behind, by the cerebrum, and this although it seemed as broad as usual. It remains to be added, that in Mr Grote's case the pons and medulla followed the cerebellum, being below, and even much more markedly below, the average size and proportional size to the body. The pons Varolii was rather flat in shape; whilst, on the contrary, the medulla oblongata appeared to be wide and large.

So confessedly obscure is the physiological action of the cerebellum, that it is not possible, with certainty, to associate a deficiency in the development of that part of the encephalon with any recognised peculiarity in the living habits of its possessor. The well-known hypothesis of its connection with the manifestation of certain desires or attachments receives no confirmation, but, on the contrary, is weakened by every impartial investigation; it is therefore superfluous to raise this view of the question. But if we assume that, directly or indirectly, the cerebellum has some controlling or co-ordinating power over the movements of the body, it may be that the slight relative deficiency in the cerebellum, which is to be construed rather into a relative preponderance of the cerebrum, has reference merely to the greater use which the late Historian made of his cerebrum, as compared with his cerebellum.

But in reference to any perfection or deficiency in regard to the habitual concerted movements of the body, I must defer to those who have had a more intimate acquaintance with him than that to which I can lay claim.

General Form of the Cerebrum.

The general form of a given cerebrum must depend greatly on the form of the cranium, or at least must correspond with it. Now, the dimensions of Mr Grote's hat already given, viz., 8¾ inches by 6¾ inches, give a ratio of length to breadth of 100 to 80·6. The actual measurement of the head furnished nearly similar results, viz., 100 to 80·9. The cranium, therefore, was on the verge between the dolichocephalic and the brachycephalic type, but slightly inclined to the latter. The cerebrum, when removed from the cranium, appeared also to be broad in proportion to its length. Those who remember Mr Grote well

will admit, however, that his head was characterised by great *height*, and a measurement which I took, from one external auditory meatus to the other, over the highest part of the vertex, shows that this was the fact, and that the cranial cavity, and consequently the cerebrum, were unusually lofty.

The several measurements taken of the head, still covered by the soft parts, were as follows:—

Length (extreme)	8·1 inches.
Breadth (extreme)	6·5 „
Circumference (extreme)	22·25 „
From root of nose to occipital protuberance, over the vertex	13·5 „
From one auditory opening to the other, over the vertex	15·75 „

Dr J. Barnard Davis gives, as one of the cranial measurements, an *intermastoid arch*, extending from the tip of one mastoid process over the vertex of the dried skull to the tip of the other: in some English skulls, with an average circumference of 20·6 inches, this arch measured 14·4 inches; in certain French skulls, the two measurements were 20·1 inches and 14·3; and in a German skull, they were respectively 19·7 inches and 14·2 inches. Allowing only ¼ inch on each side for the projection downwards of the mastoid process below the auditory meatus, and neglecting the thickness of the soft coverings of the head, which, indeed, would increase the circumference more than the vertical measurement, we have in Mr Grote's case a proportion of 22·25 inches to 16·25 inches; whereas, with a circumference of 22·25 inches, the intermastoid arch would be on the English scale about 15·4 inches, on the French 15·6 inches, and on the German 15·8 inches. Thus the relative height of Mr Grote's head was unusual, and in this respect his cranium resembled the German type. This may be interesting, seeing that his paternal grandfather was pure German from Bremen, but was married to an Englishwoman. His maternal grandfather was English, but was married to a Frenchwoman, whose ancestry, however, was also partially English. Mr Grote's descent was accordingly more than half English, one-fourth German, and less than one-fourth French.

As a further illustration of the unusual height of Mr Grote's head, it may be added that in a series of adult male heads measured by Dr Boyd, with a mean circumference of 22·24 inches, the mean measurements from the opening of one ear to that of the other over the vertex was 13·28 inches; and in even the larger measurements, with an average circumference of 23·64 inches, the transverse measurements over the head from ear-opening to ear-opening was only 14·9 inches,—the corresponding measures on Mr Grote's head being 22·25 inches and 15·75 inches.

An interesting question here arises as to whether, not only in Mr Grote's case, but usually, an unusual height of the cranium is not associated with a relatively large cerebrum, or small cerebellum, or rather with a diminished size of the lower occipital fossæ of the skull. For, supposing that portion of the occipital bone which lodges the cerebellum to be in accordance with the size of its contained organ, deficient in length or width, there would not be the same antero-posterior or lateral space above the tentorium for the lodgment of the hinder part of the cerebrum; in which case, that portion of the encephalon might have to find room, partly at least, in an increased vertical development of the cranium. On studying the Tables given at the end of Dr Davis's *Thesaurus*, founded on extensive observations, it certainly appears that in dolichocephalic or long skulls the intermastoid arch is, as a rule, proportionally to the circumference, low; whilst brachycephalism, or breadth of head, is usually accompanied with a more highly-vaulted intermastoid measurement. There are, however, occasional exceptions, which a more careful analysis as to the influence of partial synostosis, or other causes, might serve to explain. On the whole, however, long heads appear to have a tendency to be low, and broad heads have a disposition to be high, as if, when the cerebrum did not find room backwards and forwards, it must obtain accommodation upwards.

Whether, moreover, dolichocephalism is generally, or more or less frequently, associated with a relatively large cerebellum, and brachycephalism with a relatively small one, is a further question not devoid of interest. The influence of stature, which, as we have seen, is greater on the cerebellum than the cere-

brum, could not be here neglected; and it is tolerably certain the dolichocephalic are taller than the brachycephalic men and women.

Precise data by which this question could be solved—and, in any direction in which the truth may lie, the solution of it would be valuable—do not appear to me to exist.

Dr Davis furnishes the dimensions of a *fronto-occipital arch*, extending from the fronto-nasal suture along the vertex to the posterior border of the foramen magnum, and he also gives the length of the frontal, parietal, and occipital portions of this arch; but what is required is an additional measurement from the *occipital protuberance to the hinder edge of the foramen magnum*, supplemented, if practicable, by a *transverse* and a *vertical* measurement of the lower occipital fossæ, so as to enable one to estimate the size of the *cerebellar* as distinguished from the *cerebral* space or chamber of the cranial cavity. It is certainly desirable to have some knowledge of the *cerebral* and *cerebellar capacity*, as well as of the general cranial capacity of national, racial, and remarkable individual skulls, both male and female. Such information might be particularly interesting in reference to archaic or inferior modern types of human skulls. I have made a few observations, but they are at present insufficient in number to lead to any important conclusions.

8. *Proportions of the Chief Subdivisions or Lobes of the Cerebrum.*

Whoever is most familiar with the complex characters of the human cerebral surface, or rather, I would say, whoever has endeavoured carefully to compare the greatest number of brains, one with another, can best appreciate the extreme difficulty of defining and expressing, from observations however close, the relative size or extent of the several regions or areas of the cerebrum known as the lobes, in different healthy individuals, except, indeed, in cases of strongly-marked national peculiarities, or in instances of defective development. In the first place, we have no recognised or ascertained standard of

normal proportion between the several so-called lobes; secondly, the very boundaries of these lobes, though obvious enough in some parts, are not precise in other parts; and thirdly, there are the inherent difficulties of actually measuring such complex surfaces. Rudolph Wagner, and subsequently his son, have entered upon this inquiry, and have measured, by a most elaborate process, the convoluted surfaces of the several cerebral lobes. But the method pursued by them is too laborious to be very widely followed.

I will here first state the conclusions at which I arrived in regard to the lobes of Mr Grote's cerebrum from ocular inspection only, aided by comparisons of it with other cerebra, and judged of by some considerable experience in this subject; and secondly, I will give the results of a method of examination which I subsequently adopted.

The *frontal* lobes, defined as the parts lying in each hemisphere, in front of the fissures of Rolando above, and the entrance of the Sylvian fissures below, appeared decidedly large in every direction, *i.e.*, height and breadth and length; but in particular, the median portions, placed on each side of the longitudinal fissure, extended very far backwards between the parietal lobes. As to the inferior or orbital surfaces of the frontal lobes, they were both very long and very broad. They were as wide at the base as they were long; they reached further forwards than usual beyond the olfactory bulbs, and projected remarkably at their outer and posterior angles, in front of the Sylvian fissures. The *parietal* lobes seemed to be proportionally short, near the middle line from before backwards, and moreover, somewhat displaced backwards by the long median portion of the frontal lobes; but this local deficiency was compensated for by their being very wide and full on the lateral aspects of the cerebrum. The *temporal* lobes, whether viewed from the sides or from below, seemed short from before backwards, but very broad laterally, and of good depth; their apices were much incurved behind the commencement of the Sylvian fissure. The *occipital* lobes were very short and shallow, but were very wide. On the whole, these last-named lobes seemed to be the most defective; whilst of the others, all of which seemed large, the parietals appeared to

be the least in excess, the temporals more so, and the frontals the most. Viewed generally, the cerebral hemispheres would be said to have a very long, wide, deep, and therefore ample frontal development, a wide parietal and temporal development, and a short and thin occipital region. On the internal surface of the hemispheres, within the longitudinal fissure, the frontal portion also extended very far back; the square parietal portion was short from front to back, and was pushed obliquely backwards; the internal perpendicular fissure was much inclined in the same direction; and the triangular occipital portion behind it was very small. The temporal portions overhung the cerebellum at least half an inch on each side; and the occipital portion, pushed back, as it were, by the parietal, and that by the frontal, projected three-quarters of an inch beyond the cerebellum behind. Of the two hemispheres, the right was rather the longer, both in front and behind, which is unusual; and, contrary to Dr Boyd's general experience, with which, however, that of other observers has not been always conformable, it proved to be somewhat the heavier of the two,—their respective weights differing by, however, only 25 grs. when acted on by the preserving alcohol.

Not satisfied with the preceding estimate from inspection only of the relative proportions between the several lobes, I proceeded, in the manner described below, to subdivide the left hemisphere into its component parts; and, having done the same with three other male cerebra, I weighed all the parts in each case, and obtained the subjoined results.

The fissure of Rolando was first opened out along its whole length with the fingers, and the substance of the hemisphere was then torn in the direction of its radiating fibres, as these would permit, gradually down through the short attached piece of the cerebral peduncle; in doing this, the narrow convolutions which surround the two ends of the fissure in question, and separate it from the longitudinal and Sylvian fissures, were necessarily torn across, and, on the inner surface of the hemisphere, the process of laceration had to be continued downwards through the middle of the convolution of the corpus callosum, and through that commissure itself. The portion of the hemisphere thus removed from the rest might be called

the *fronto-insular* lobe, for it, of course, includes the Island of Reil; but as this last-named part, when pared off from the rest, weighed only 135 grains out of 6 or 8 ozs., it was thought better to reckon the whole as the *frontal* lobe. With this lobe, also, there remained connected about $\frac{4}{5}$ of the corpus striatum, about $\frac{1}{3}$ of the optic thalamus, nearly $\frac{1}{2}$ of the cerebral peduncle, nearly $\frac{1}{2}$ of the corpus callosum and its convolution, and a mere fragment of the forepart of the fornix.

The internal perpendicular fissure, between the parietal and the occipital lobes, and the hinder part of the horizontal fissure between the occipital and temporal lobes, being next followed by deeper and deeper separation in the direction of the white fibres, the *occipital lobe* was set free, as a wedge-shaped mass, —a few convolutions, the so-called connecting ones, having been necessarily torn across on the upper, outer, and under aspects of the hemisphere. With this lobe, some of the thickened hinder part of the corpus callosum came away, but no portion of the cerebral peduncle was reached.

By next following the direction of the bottom of the recess, from which the occipital lobe had been removed, and by tearing across the continuation of the so-called bent convolution with the superior temporal, below the hinder end of the Sylvian fissure, the *parietal* and *temporal* lobes were readily separated, the process of tearing being here also carried through that part of the cerebral peduncle which was left after the removal of the fronto-insular mass. With the parietal lobe, there were connected, besides one-third of the short piece of the cerebral peduncle, about one-fifth of the corpus striatum, nearly half of the optic thalamus, and at least one-third of the corpus callosum, of its convolution, and of the fornix, all of which had been torn across. With the temporal lobe, besides a small portion only of the cerebral peduncle, a mere strip of the corpus callosum, the descending portion of the fornix, and, it may be added, the anterior commissure.

To test the method thus employed, especially as to uniformity of result, the right hemispheres were afterwards separated in the same manner, with results as nearly similar as could be expected, so far as the topographical lines of separation were concerned. I have since also examined and weighed the corre-

sponding separated parts of the cerebrum of some of the higher Mammalia; but the results of these latter researches I reserve, as beside the present inquiry.

The actual and the proportional weights of the four lobes of the left hemisphere, in the four preserved human cerebra, were as follows:—

TABLE No. V.

Designation.	Ages.	Entire Hemisphere.		Frontal Lobe.		Parietal Lobe.		Temporal Lobe.		Occipital Lobe.	
a. Weights in ounces and grains.											
		ozs.	grs.	ozs.	grs.	ozs.	grs.	ozs.	grs.	ozs.	grs.
A's . .	62	18	40	8	100	3	297·5	4	80	2	50
B's . .	64	14	325	6	275	3	27·5	3	142·5	1	317·5
C's . .	68	14	25	6	125	2	420	3	67	1	287·5
Average .	62–68	15	276	7	21	3	103	3	193	1	364
Mr Grote's	75	14	410	6	320	3	82·5	3	132·5	1	312·5
b. Weights in grains.											
		grs.		grs.		grs.		grs.		grs.	
A's . .	62	7915		3600		1610		1780		925	
B's . .	64	6450		2900		1340		1455		755	
C's . .	68	6150		2750		1295		1380		725	
Average .	62–68	6838		3083		1415		1505		801	
Mr Grote's	75	6535		2945		1395		1445		750	
c. Ratios of the Lobes to the Hemisphere.											
A's . .	62	100		45·46		20·34		22·50		11·69	
B's . .	64	100		44·94		20·78		22·56		11·71	
C's . .	68	100		44·72		21·06		22·44		11·78	
Average .	62–68	100		45·04		20·73		22·50		11·72	
Mr Grote's	75	100		45·06		21·35		22·11		11·47	

It is obvious enough, on looking at the preceding Table, that although the actual weights of the left hemisphere and of its component lobes, as shown in sections *a* and *b*, differed more or less in the four brains examined,—the excess of weight in one case, A, that of a very large-brained and distin-

guished member of his profession, being very considerable, —nevertheless the proportional weights of the several lobes in all the cerebra, as shown in section *c*, were nearly uniform, or differed very slightly from some common measure of uniformity. From this we may conclude, speaking generally, that however much different healthy brains may differ from one another in size, the relations of their several parts or lobes to each other, observe very closely a certain standard or normal ratio as to size.

Furthermore, we cannot fail to notice that such differences as do exist in the relative sizes of the several lobes, as compared with the entire hemisphere in the different brains, are in themselves very slight; and, accordingly, they must not be expected, in ordinary conditions of development, ever to be very great. It might, indeed, be argued that they are so small, that they have little or no real significance; but it is perhaps nearer the truth to say that, at present, their meaning is unknown to us, and that further observations, probably modified in certain ways, and more numerous than I can hope myself to supply, require to be made in this direction.

Taking, however, the evidence now before us, it is plain that the frontal, parietal, temporal, and occipital lobes stand very nearly, as regards their weights, in the proportion to each other of the numbers 4, 2, 2, and 1. The frontal lobe is, in other words, four times as large as the occipital lobe, is equal to the parietal and temporal lobes together, and forms four-ninths of the entire hemisphere. The great relative importance of the frontal region of the cerebrum in Man, as compared with even the highest animals, thus receives a very decided and definite expression; and, indeed, its preponderance is not only made more manifest than by mere ocular observation, but it exceeds in amount that which would usually be attributed to it. The near approach in weight of the parietal and temporal lobes, and the constant superiority of the latter, are also facts which have doubtless a physiological explanation yet impossible to state.

If, next, we venture to scan more closely the proportions of the several lobes to the entire hemisphere and to each other, in the different cerebra examined, we find that, whereas the greatest proportionate size of the frontal lobe occurs in the

largest brain, A, this is not the case in regard to any of the other lobes; for the parietal and the occipital lobes are relatively the largest in the smallest brain, C; whilst the temporal is proportionally the largest in the medium-sized brain, B. Again, if we contrast the amount of variation in the relative sizes of the different lobes, in the four brains, we perceive that the parietal lobe varies the most, *i.e.*, to the extent of $\frac{1}{30}$th of its highest ratio; the frontal lobe stands next, varying about $\frac{1}{60}$th part of its greatest relative weight; then follows the occipital lobe, with a variability of only $\frac{1}{130}$th; whilst the temporal shows the most constant weight, fluctuating to the extent of $\frac{1}{180}$th part. Does the greater range of variation in size of the parietal and frontal regions—though in itself of slight amount—imply any functional superiority over the less variable occipital and temporal lobes?

Lastly, if we seek, in the numbers recorded in Table V., for the means of correcting the estimate already given from observation only of the relative size of the several lobes in Mr Grote's cerebrum, we find that the frontal lobe, though inferior to the same part in the very large brain, A, is at least equal to the average ratio of A, B, and C, and is even relatively larger than in B, which brain most nearly resembled Mr Grote's in actual weight. As to the parietal lobe, it is relatively larger in Mr Grote's cerebrum than in any of the other three. If we take the fronto-parietal lobe, this is a larger mass in Mr Grote than the average, and larger than the largest brains, by 66·41, the average 65·77, and the largest 65·8.

The temporal and occipital lobes are, on the other hand, both smaller proportionally than in the other cases, the occipital lobe being in this respect the smallest lobe. The correction necessary, therefore, consists in placing the parietal lobe first, the frontal next, the temporal next, and the occipital last in the descending order of relative developments.

In concluding these remarks, I would, however, again draw attention to the small amount of the differences with which we have here had to deal.

9. *Characters of the Convolutions and of the intermediate Sulci.*

Were I asked to indicate the most striking external characteristic of Mr Grote's cerebrum, I should reply, the great breadth, distinctness, and volume of the convolutions generally. Some of the larger convolutions reached as much as ·7 of an inch, whilst the usual maximum is about ½ inch; the sulci are never so narrow as ·2, which is the usual minimum.

I have seen brains with much more minute intricacy of surface, but then the chief convolutions, those in fact which bear definite names, were relatively small; but in this particular cerebrum, all these convolutions are so *massive* that they seem simple, though in reality they are highly configured with secondary grooves and markings. It is possible, however, that earlier in life, and previous to the presumable effects of disease as well as of age, these latter markings were somewhat deeper, so as to have rendered the general surface of the cerebrum still more intricate. It is further possible that this most remarkable general feature of the cerebral hemispheres may be associated with the large commissural endowments of this particular brain, and therefore with the abundance of white fibres passing into the convolutions themselves.

I distrust very much, or rather I disregard altogether, the common statements so generally made as to the great depth of the sulci in brains which are being specially examined with the view of determining their relative superiority of organisation. In ordinary observations on the brain, the depth of these sulci is not carefully estimated; and I have found in every brain which I have systematically investigated that the depth of the sulci generally, and of certain sulci especially, was quite a subject of surprise. Moreover, unless the same sulci are, if not measured, at least *simultaneously* contrasted in different brains, any observation is valueless for comparative purposes. These considerations being borne in mind, it appears to me most desirable to discontinue statements concerning the depth of the sulci, or at least to attach but little special significance to them in individual cases, excepting in reference to such marked deviations as occur in the inferior races of Man, in idiots, and in

the higher animals as compared with Man. Thus, for example, they merely vary from ¼ inch in the occipital region to ½ inch on the inner surface and 1 inch on the outer surface; but these are the mean depths, and in the idiots the maximum depth was of ½ an inch. My own impression, after repeated observations, is, that like the main fissures between the lobes, so the primary sulci between the rows of convolutions are always deepest in the largest brains; and that their depth depends rather on the size than on the complexity of a given cerebrum, which latter character is entirely dependent on the number of secondary windings and grooves which are well marked. Hence, if the characters of the several rows of the convolutions themselves be accurately recorded, the sulci may be neglected; for it may safely be asserted that these latter are relatively deepest and most marked in those very regions in which the convolutions are most pronounced.

In Mr Grote's cerebrum, the *frontal* convolutions are not only bold in mass, but by far more complex than those of the parietal or temporal lobes, being particularly rich in their numerous windings, in their lateral flexuosities which fit into each other, and in their surface undulations. Of course, speaking now in comparison with other brains, the superior row of frontal convolutions on both hemispheres is very large, on the left hemisphere extremely large; on both sides this row is double and very complex, and extends very far backwards. The middle row is narrower on both sides, but complicated. The outer or inferior row is broad, but much more simple. The three rows are more regularly divided longitudinally from each other, especially on the upper aspect of the cerebrum, on the right than on the left side, which I find is a common arrangement. On the orbital surface of the frontal lobe, the outer border is formed by a remarkably bold convolution, which indeed largely contributes towards the great breadth of this region already mentioned; but the innermost convolution, inside the olfactory sulcus, is also larger than usual. The so-called central lobe, the insular lobe, or Island of Reil, is both small and simple in its configuration.

As to the two oblique ascending convolutions which lie in front of and behind the fissure of Rolando, and form its anterior

and posterior margins, they are both very long and much folded on both hemispheres, but they are very unsymmetrical, as usual. The anterior or frontal one is more simple than the posterior or parietal one, on each side. Again, on the left side, the anterior one is suddenly interrupted about its middle, and then becomes very narrow as it passes outwards and forwards, whilst the posterior one is exceedingly large. On the right side, the two convolutions are of equal and uniform breadth, and follow each other more uniformly in their foldings. Of the other parietal convolutions, the parietal lobule lying next to the middle line is more defined on the left side than on the right, which is usual; but the former is also larger than the latter, the deficiency in which corresponds but inversely with the excessive width of the posterior ascending parietal convolution of the left side. On neither side is the parietal lobule complex, but is short, and seems pushed back by the extremely long superior frontal row. On the other hand, convolutions on the lateral aspects of the parietal lobes are decidedly fuller and more complex, the bent convolution, and especially its supramarginal foldings, being massive and deeply grooved. All three rows of the *temporal* convolutions, except the upper, are very bold and massive, though rather short and much curved, with an outward convexity towards the sides; the superior convolution is narrow in front, but very broad behind; the middle one is simple, but the superior one especially, and the inner or inferior one to a less degree, is crossed by numerous secondary depressions or grooves. The *occipital* convolutions, always smaller, shallower, and more intricately involved than those of the other lobes, are here also comparatively broad, deep, and somewhat less complex; they are widest on the outer side, narrowest at the tip of the lobe, and most complex on the under surface. The minor connecting or bridging convolutions are all well developed. The flat opposed surfaces of the hemispheres, seen within, and forming the sides of the longitudinal fissure, are also characterised by the boldness and apparent simplicity of their convolutions. The great *frontal* convolution, on the anterior and upper border of the hemisphere, is very large and long, reaching very far back; it is also much folded, especially on the right side. The convolution of the corpus

callosum is narrow. The *quadrate parietal* lobule is likewise narrow, much inclined backwards, and more simple than usual. The triangular occipital lobule is small and simple.

Finally, as regards richness of convolutional development, this so far corresponds with the regional development that it is most evident in the frontal, next so in the lateral parietal, then in the temporal, and least so in the occipital lobe. Nevertheless, in all the several lobes the convolutions are strongly pronounced, and the cerebrum, as already stated, has a boldly-modelled surface.

Notwithstanding the extremely interesting and important researches of Dr Ferrier "On the localisation of function in the brain," I fear we are not yet in a condition of knowledge to justify any close application of his facts and inferences to the explanation of personal peculiarities found in any individual cerebrum. Thus, according to Dr Ferrier, certain parts only of the frontal and parietal lobes, viz., the upper and outer regions, appear to be concerned in the production of purposive movements; other parts of the frontal lobes, viz., the anterior and under surfaces, give no definite results on irritation; the occipital lobes also do not react on stimulation; nothing is ascertained concerning the function of the insular lobe; and there are parts of the cerebral surface which seem not yet to have been examined, such as the internal flat surface of the hemispheres, the under surface of the temporal and occipital lobes, and, it may be added, the hidden surfaces at the *bottom* of the chief fissures and sulci in all the curves of the cerebrum. Moreover, quite contiguous and connected with the apparently motor regions of the parietal lobe, lies, in the bent convolution, a supposed seat of visual perception; near it, in the superior temporal convolution, is an auditory centre; and in the uncinate convolution of the temporal lobe is localised the sense of smell. Finally, destruction or removal of the anterior frontal and orbital convolutions and of the occipital lobe, appears to be followed by some interference with special mental processes, causing, on the one hand, in regard to the frontal lobe, a condition resembling dementia, and on the other, upon removal of the occipital, an apparent abolition of the instincts of self-preservation.

Incomplete as these researches at present are, and irreconcilable as some of them seem to be with the known anatomical connections of at least certain parts of the cerebral hemispheres, it is only by the criticism of repeated and extended observations and experiments, whether on men or animals, that they ought to be met. No amount of mere argument can touch the facts, however difficult some of them may be to understand. It is obvious, on the other hand, that any use to be made of these facts must be cautious, reserved, and even hypothetical.

Supposing, therefore, that we assume size and complexity of convolutions to be evidence of superior functional capacity, might we credit the very large orbital and anterior frontal regions of Mr Grote's cerebrum with the active and able exercise of proper mental processes; and the relatively small occipital lobe with a comparative deficiency of conduct, or carelessness as to personal interests and safety? May we associate the relatively large convolutions in the frontal and parietal regions, before and behind the fissure of Rolando, with the large upper and lower limbs of a person nearly six feet, even though the purposive movements of those limbs are held in but moderate equilibrium or control by a comparatively small cerebellum? How shall the great breadth, yet comparative simplicity, of the inferior frontal convolution, be interpreted in reference to any peculiarities as to verbal expression or lingual utterance? Was the bold development of the back convolution associated with any great activity of visual perception, or the relatively full development of the superior temporal convolution with any special appreciation of a love of sounds?

Not caring to press these or other similar queries as to individual or personal peculiarities further, I would rather draw attention to a general question, viz., that of the existence of *symmetry* and *asymmetry* in the cerebral convolutions, the prevalence of the former in animals, and of the latter in Man, and the significance of this undoubted and remarkable difference between them. I had long dwelt, doubtless in common with others, but as a mere speculation, on the idea that there might be, in the superficial grey matter of the cerebral hemispheres, regions or areas containing certain structural

arrangements for the excitation of movements, highly intricate, yet orderly, and destined to carry out certain acts, which, viewed in their totality by other persons, are interpreted by them as the outward expressions of certain definite mental states. In the lectures on the nervous system which I, as Fullerian Professor, gave many years since at the Royal Institution, I drew attention to this idea, and expressly showed how, on my hypothesis of the nature of sensation and consciousness, and its relation to matter or to an immaterial entity, it was absolutely necessary that somewhere or other the cerebral mechanism really exists for the perfect combination of such movements, in all their variations, as to direction, force, and duration; and that this material aspect of the question must some day or other be inquired into. I had also, in my own mind, endeavoured to trace possible lines of action, or combinations of actions, to or from certain parts, lobes, lobules, or convolutions of the cerebrum, taking as starting-points the supposed motor function of the corpora striata and sensory offices of the thalami, and the various courses and connections of the radiating fibres of the hemisphere, from, to, and with those masses, and then comparing the relative development of the different parts of the hemispheres in animals having very different sized limbs before and behind, such as the kangaroo for example. But no system of supposed localisation seemed tenable; my favourite idea was to imagine that the frontal lobes governed such definite and complex movements in the head, face, and neck, the parietal lobes those of the upper limbs, the occipital lobes those of the trunk proper, and the temporal lobes those of the lower limbs. I supposed that all the lobes received or imparted impressions from or to the thalami or corpora striata. But I could not establish these notions; and, as it were, longed for more facts. One point, however, always came uppermost during these thoughts, and that was the obvious asymmetry of the convolutions in the human cerebrum. It did not seem explicable that this want of lateral uniformity could be associated with the performance of higher intellectual processes, or with the more perfect performance of these; for it was difficult to find any good reason or detect any obvious advantage in purely intellectual operations, being, as it were, hampered by

an asymmetrical apparatus. But if the conditions of physical movements, that is, of combined muscular actions, in an animal frame be considered, it was easy to see a possible connection between symmetry or asymmetry of construction, and symmetry or asymmetry of work. It was difficult to conceive of an intellectual superiority linked necessarily with a defect of balance in structure; but the *right-handedness* of man, coupled with his bipedal mode of standing and locomotion, seemed to suggest at once that if in any volitional and purposive acts one upper limb, or in different ways one lower one, was essentially and habitually put into use, then an asymmetrical governing apparatus might either exist, or, as we should now say, would be gradually evolved in his nervous centres, and be continued as an inheritance amongst the race. Ignorant, however, of the real connection between certain parts of the cerebral surface, and certain parts of the muscular apparatus of the body, one could neither test nor illustrate the generalisation just expressd; but, assuming Dr Ferrier's conclusions to be at least approximations to the truth, we may try and employ them as temporary guides in an endeavour to explain the asymmetry of the cerebral convolutions in man.

That, in a general sense, symmetry of the nervous apparatus, and symmetry of muscular movement, prevail and coexist in the lower invertebrate animals, is of course well understood; but so also, on consideration, will it be admitted, that in all the vertebrata, even in the quadrumanous group, this common rule as to structure and action holds good. It is also well known that the cerebral surface becomes particularly complicated, involved, or convoluted in the *larger* species of any given genus, or higher group, as compared with the smaller allied species; and it is certain that such complexity causes a minor or subordinate kind of asymmetry in the convolutions. But it may be safely asserted that even in the complex brain of an elephant or a cetacean, symmetry, both of size and form, may be recognised as a rule, even in the smallest and most intricate windings of the two hemispheres of the brain. But in the human cerebrum, with an homology which coincides with the due performance of symmetrical purposive acts common to all men, and often to the animals nearest to him in structure as

well, there exists an asymmetry in the weights of the two hemispheres, in the ratios of size and weight in the different lobes, in the arrangement of particular rows of convolutions, and in the size and form of particular convolutions themselves; and, side by side with these conditions, we have the right-handedness (or it may be the left-handedness), at all events the one-handedness of man, and all the other manifestations of one-sided action, dependent upon this, and upon his strictly biped mode of standing and locomotion. It is impossible to overlook the possible connection between this marked and constant asymmetry of structure and the special functional activity of the two hemispheres of the human cerebrum.

Now, the selection of one upper limb, which, as a rule, is the right one, for such varied purposes, necessitates the one-sided employment of the head and neck and eyes so as to watch and guide that hand, as in writing, or painting, and so on; also, very usually, a one-sided action of the trunk, so as to afford a due basis of movement for the arm, and, lastly, even of the lower limbs, so as to gain or give some advantage of position or support to the trunk itself. Moreover, although in ordinary circumstances we advance the right foot first in walking, and employ it as the acting agent in kicking, and rely more on the right lower limb than on the left for commencing either an upward or downward difficult act of locomotion, this assuredly implies a greater confidence in the left leg for purposes of equilibrium; and again, there are other cases in which the left leg is preferentially used.

It would be out of place here, if it could be done, to investigate the conditions of symmetry or asymmetry of the entire system of the cerebral convolutions in Man, in connection with Dr Ferrier's present determinations as to their functions, for these latter are avowedly incomplete. But a few points may be selected for observation and comment, partly in reference to disturbances of symmetry which seem to belong to individual cerebra, but chiefly to others of a more important kind, which I feel disposed to regard as peculiarly human, *i.e.*, as specific or generic in Man; for they prevail, more or less evidently, in a series of human cerebra, quite indifferently chosen.

(*a*) If there be one instance of asymmetry in the human

cerebrum more obvious than another, it consists in the remarkable difference which exists between the two sides in the ascending frontal and ascending parietal convolutions, lying, one in front of and the other behind, the fissure of Rolando. On the right hemisphere, these two convolutions respectively are, as a rule, not very variable in actual width, more or less evenly shaped, and similarly disposed, the one appearing to obey the form and involutions of the other, so that the intervening fissure is easily traceable, and comparatively simple throughout its course. On the left hemisphere, on the contrary, these convolutions, as a rule, show an inequality of mass, an irregularity of form, and an unevenness of direction which obscures the course of the interposed fissure, and forms a marked contrast with the more methodical arrangement of the corresponding parts on the right hemisphere. Looking more closely to the nature of the irregularity on the left hemisphere, it is seen that, as a rule, the anterior or ascending frontal convolution is suddenly interrupted about the middle of its course by a deep secondary or tertiary sulcus, so that it appears to dip down and rise again; whilst the posterior or ascending parietal convolution, as a rule narrow at its inner end, suddenly widens out, so as even to form a triangular mass, often sulcated, wedged in between the fissure of Rolando and a portion of the intraparietal fissure behind.

Now, this example of convolutional asymmetry does not affect a secondary fissure and a secondary set of convolutions, much less the tertiary forms of these parts; but it involves one of the most important intrinsic fissures of the cerebrum, and two of its most obvious primary convolutions. Moreover, it is not an individual or solitary condition; but it exists, as I will explain, more or less evidently, and with certain modifications, in every brain in which I have hitherto searched for it. Thus, it is seen very clearly in the brain of the Bushwoman formerly described by me; and it is found, though less marked, in another Bushwoman's brain, and, again very plainly, in the brain of a male Australian which I have some day to describe; it is traceable in the brain of the Hottentot Venus figured by Gauss; it is seen in the tracing of a brain published by Dr Broadbent; it is well marked in all three of the brains examined by

me concurrently with Mr Grote's, and it is most evident in his; lastly, it is recognisable in two other cerebra which I have recently procured. Furthermore, it is of great moment to add, in reference to the specially human character of this instance of convolutional asymmetry, that in both idiot brains described and figured by me, this region of the left hemisphere, and especially the anterior ascending frontal convolution, is found, when compared with the more even and regularly formed corresponding part of the right hemisphere, to be the seat of a remarkable irregularity, manifested in the shape of an *intrusive* or *interrupted* convolution in front of the left fissure of Rolando. In the quadrumanous brain, on the other hand, no such derangement of the symmetry of these or of other primary parts is met with. It may also be seen that, in the larger idiot's brain especially, this deviation is the most remarkable example of asymmetry to be detected in it.

Supposing, then, this peculiarity, traceable in human brains of various degrees of perfection as to development, to be common or general in Man, by virtue of the principle of inheritance, it seems difficult to connect it in any way with the operation of the mind only; but if this very ascending anterior frontal convolution on the left hemisphere is concerned in the government or dictation of the purposive movements of the opposite or right upper extremity, a glimmer of an explanation may dawn upon us as to the meaning of the asymmetry of this portion of the human cerebrum. The greater multiplicity and variety of combinations required for our right-hand as compared with our left-hand work, necessitates a greater complexity in the corresponding nervous apparatus; and it must be remembered, in regard to the cerebral convolutions, that simplicity is the lower, and complexity the higher grade of development and organisation.

It is quite possible that, in accordance with the great law of development of the whole body, the right hemisphere might be larger; but this need not give to the left hand more complexity, or more frequent use. There are cases in which persons are said to be left-handed, but the right hand is larger actually. A distinction might here be drawn between complexity and size, between special evolution and mere growth.

It has been shown by Dr Boyd that usually the left cerebral hemisphere is larger than the right; but the fact is not always so. Were it usual, it could still only be associated with greater frequency of action, and not with greater complexity of action; perhaps not even with the former.

(*b*) Another asymmetrical arrangement, so far as I have observed, usual if not constant in Man, consists in the fact that the frontal convolutions generally, but especially those on the upper surface of the cerebrum, are more simply marked off into rows on the right hemisphere than on the left, where the lines of demarcation are more complex. It also appears to me that, as a rule, the superior frontal row of convolutions is broader and more complex on the left side. The hinder part of this convolution is also concerned in the excitation of movements in the upper limb.

(*c*) Compensatory differences, as a rule, exist in the middle frontal row of the two sides; for it is usually larger on the right side. This and the forepart of the superior frontal are said to be concerned in movements of the head and eyes, which must often be asymmetrical, in consequence of the special use of the right hand.

(*d*) As to the inferior rows of frontal convolutions on the two hemispheres, they are, comparatively speaking, decidedly amongst the most symmetrical parts of the cerebrum; their doublings, where they overhang the insular lobe, are uniform in number and character, and their hinder end is equally enlarged as it runs into the ascending frontal. Sometimes it has an apparently deeper sulcation here, certainly usually, if not always, on the left side, as seen in Dr Broadbent's figure, and also in Mr Grote's brain; but this is not perceptible in the Bushwoman's and Australian brains, nor in the idiots' brains. Concurrently with this relative symmetry, we have the supposed regulation of the movements of speech, which are also symmetrical. Yet there seems to be some special influence of this convolution, and the adjacent parts on the left side, in regard to the faculty of language or the memory of words.

(*e*) The inferior or orbital surface of the frontal lobes presents us with another example of asymmetry, which, however, compared with that described in (*a*), is slight, but, as it seems to

me from repeated observations, is also not of an individual but of a general kind. On the left hemisphere, the surface is usually smoother, and more simple in appearance than on the right; the tri-radiate sulcus is usually more closed, and often more simple in the former than in the latter; and the meeting-point of its three rays is situated further from the median line of the cerebrum. Moreover, the olfactory sulcus is usually more closed, and does not reach so near the tip of the lobe as on the right side. This is all due to the larger size of the internal orbital convolution, which is continuous with the superior frontal, also usually larger on the left hemisphere; the external orbital is likewise larger on the left side; whilst an intermediate narrower orbital convolution, seen only in more complex brains, is smaller, and, as it were, compressed on this side; these two last-named parts correspond respectively with the inferior and middle frontal convolutions on the upper and outer surfaces of the hemisphere, which are themselves, as a rule, the former larger, and the latter smaller on the left side of the brain. The orbital convolutions are, at all events, clearly correlated with the upper, middle, and outer frontals, but their function remains in doubt.

(*f*) Returning again to the upper surface of the cerebrum, and to parts to which some special function has been assigned, I find also, as a general rule, in brains of the most varied degree of convolutional development, that the parietal lobule which extends backwards from the upper end of the ascending parietal convolution, and which is thought to be concerned in exciting combined movements of the hinder limb, is comparatively small, and is well defined along its outer and posterior borders on the left hemisphere; whilst on the right, it is larger, and its outer and anterior angle is usually blended superficially with another parietal convolution, and its outer and hinder angle with an occipital convolution. In other words, the condition of simplicity here manifests itself on the *left* side, and that of complexity on the *right* side of the cerebrum,—the reverse of what is found in the case of the ascending frontal convolution. Now, although both lower limbs are used equally, though alternately, in ordinary progression, there can be no doubt that in employing the right hand, a cross or oblique

action through the trunk from and to the opposite leg very frequently occurs, especially calling into play the muscles of that limb in the *supporting* or *balancing* the body. This is well known to artists; and instances are too common to require mention. Even in standing still, we are apt to bear more weight on the left than the right foot; and if the right lower limb is the limb of action, the left is the limb of *equilibration*. May this be associated with, or may it serve to explain, the greater complexity of the parietal lobule on the right cerebral hemisphere?

(*g*) The seats of special sensory perceptions pointed at by Dr Ferrier's experiments are those of the visual, auditory, and olfactory perceptions, viz., the bent convolution, the superior temporal convolution, and the uncinate convolution. All these parts are situated on the lower border or margin of the hemisphere, and not within its general surface, like the motor convolutions already treated of; for the Sylvian fissure is due to a bending of the entire hemisphere, and not to a folding across its substance. All the marginal convolutions are more symmetrical than those situated on the general surface; and this may be the reason why the bent, the superior temporal, and especially the uncinate convolutions are comparatively symmetrical, for they undoubtedly are so. But so also, we may perceive, is it more in harmony with their supposed *sense-perceptive* functions that they should be symmetrical rather than asymmetrical. Moreover, the more exact symmetry of the uncinate convolution coincides with the necessarily symmetrical exercise of that sense, and of the movements associated with it. In the case of the superior temporal convolution, I find the rule to be that it is broader throughout its whole course on the right than on the left hemisphere, compensation being obtained by different conditions of some of the other temporal convolutions. There is no proof that auditory impressions partially cross, like visual ones, in the nervous centres; if not, do we use the one ear, the right one, more than the other? It is interesting to find that, in Dr Broadbent's plate, which is of the brain of *a deaf-mute*, the right superior temporal convolution is, likewise, by far the larger one, the left one being unusually narrow. This latter cannot, however, be

said to be positively atrophied; and the difference in size between the two sides may be an inherited human characteristic, though occurring in unused parts. Finally, in reference to the bent convolution, and its closely connected supra-marginal lobule, the former especially designated by Dr Ferrier as the visual perceptive centre, they are very evenly balanced on the two sides of the cerebrum; but, as a rule, the left mass is rather more prominently marked, and more complex.

(*h*) On the internal surface of the hemispheres, the superior frontal convolution is usually larger, longer, and more complex on the left side; the quadrate parietal lobule is larger on the right; whilst the occipital is very equal in size on the two sides, but is a trifle more involuted on the left side. The inferior and middle temporal convolutions show, likewise, a near approach to symmetry as regards their chief fissures and the intervening masses; but the lesser sulci are variable, and the left hemisphere seems to be somewhat more simple than the right. The functions of these parts are in doubt, except that the superior frontal is probably a motor centre, and the occipital lobe is conjectured to be concerned in the instinct of self-preservation.

(*i*) The knowledge we now possess concerning the localisation of function in the brain needs great extension, and may receive some rectification; differences of explanation concerning the phenomena observed by Dr Ferrier will for a time prevail; and it is granted that any attempt to draw a parallel between local deviations from symmetry and local functional manifestations must at present be imperfect and conjectural. Sufficient facts, however, have been adduced to render it probable that the asymmetry of the human cerebral convolutions is neither accidental nor without significance, but that it runs in the same direction in many brains, whatever their degree of development, and it is correlated first as effect, and then as a continuing cause of some entirely human peculiarity of cerebral function. Beyond this, I have arrived at the more definite conclusion that the leading disturbances of symmetry are met with in those parts of the cerebral hemispheres with which Dr Ferrier associates motorial and not sensory or perceptive functions, complex motorial functions, which he regards as the expression of definite purposes or ends. Furthermore, it seems

to me that, whilst the parts concerned in exciting such movements in the unsymmetrical use of the upper and lower limbs are the seats of marked evolutional divergences from bilateral symmetry, those in particular which are connected with the exercise of the right upper limb, viz., those immediately in front of the fissure of Rolando, on the left hemisphere, exhibit a remarkable developmental cataclysm, in brains of the most varied degrees of perfection. Accordingly, I am disposed to connect the asymmetry of the human brain with Man's one-handed habit, and all its direct and indirect consequences throughout his organism.

Further observations, in which I would invite others to join, as my own leisure is quite inadequate to the undertaking, are needed to confirm or refute this view. The cases of left-handed and of ambidextrous persons, and also of those who have lost either an upper or lower limb early in life, or have one-sided palsy, atrophy, or malformation referable to early stages of growth, would be especially interesting to study. In the meantime, as the conclusions above stated have forced themselves upon me in connection with the comparison of Mr Grote's brain with others, I venture to include them in the present report.

10. *Relative Thickness and Structure of the Grey Layer of the Cerebral Convolutions.*

Unless care be taken to cut the substance of a given convolution quite perpendicularly, considerable errors may be committed in reference to the thickness of the grey matter. This has been said by good observers to range between $\frac{1}{12}$th and $\frac{1}{8}$th of an inch, but I have frequently measured it at $\frac{1}{5}$th of an inch; I have found it thicker in some small brains than in other large ones. It was as thick in one of the idiot's brains which I have described as in many full-sized cerebra. In Mr Grote's brain it varied from $\frac{1}{12}$th of an inch on the occipital lobe, to nearly $\frac{1}{5}$th on the upper part of the frontal and outer part of the parietal lobes; it was, as usual, of intermediate thickness on the inner surface of the hemisphere, on the under side of the frontal lobe, and on the temporal lobe. On the

whole, as compared with other brains, it was of more than average thickness, but not so thick as in two of the brains which I examined, in which the extreme thickness exceeded $\frac{1}{3}$th of an inch. It will be observed that, as usual, the grey matter was thickest where the convolutions are themselves the largest and the sulci deepest, viz., on the middle of the frontal and parietal regions. It is, indeed, so far as I have observed, always thickest on those parts which are now said to be the seats of motorial functions, which receive the chief part of the radiating and transverse or callosal white fibres, and which are most completely connected with the corpus striatum. On the other hand, it is thinner in those regions which are connected chiefly with the optic thalami, which receive fewer white fibres, especially transverse ones, and to which sensory perceptive functions, or instinctive or other mental processes, have been assigned, or of which the use is entirely unknown. Nevertheless, it must be understood that the depth and width of a convolution depend rather on the relative quantity of white substance which it contains than on that of the superficial grey matter; for this latter, though sometimes thicker than the central white layer, is of uniform width in neighbouring convolutions of very different breadth.

As to the structure of the grey matter of the convolutions, its many stratified layers, and the varied microscopical constituents of these, our present knowledge, though very precise, is merely sufficient to indicate its great complexity, its high refinement of organisation, and the intimate and almost infinite connections of its vesicular and fibrous elements. It is further known that it varies in different parts of the cerebrum; and it would seem that certain especially large ganglionic corpuscles exist in greater abundance in the supposed motorial than in the supposed sensorial or non-motorial regions of the convolutional substance. But after many observations, made with both moderate and high magnifying powers, I find myself quite unable to use these as grounds of comparison of *brain* with *brain*. Though certain parts of the same brain are thus readily distinguishable from one another, the corresponding regions of different healthy brains have not as yet furnished me with sought-for differential characters of a reliable nature,

whether as to the number, distinctness, or thickness of the layers, or as to the number or arrangement of their ultimate constituents. Such differences as I have detected in similar parts of different brains have been quite paralleled by those found in neighbouring parts of the same brain. I could never, after a time, decide, except from some accidental point, in a preparation, from which brain it had been obtained.

In Mr Grote's brain, the substance of the grey matter in the recent state was, as already stated, a little paler, and somewhat softer than usual; but when hardened, its laminæ were quite easily distinguishable, and, so far as I could detect, showed no peculiarities of over or under development as regards the number of layers, their order, and relative thickness; but the large-branched cells were less evident in certain sections than in others, and the whole section was more granular.

11. *Relative Quantity of the White Substance of the Cerebrum and Size of the Commissures.*

It has been already stated that the most marked peculiarity observable on the surface of Mr Grote's cerebrum was the great breadth of the convolutions generally; and attention has been just drawn to the fact that the breadth of these foldings always depends more on the quantity of central white substance, than on the thickness of the superficial grey matter. Now, the most striking internal peculiarity of Mr Grote's cerebrum, as recognised on making various sections through it, was the relatively large quantity of the white substance. This was so especially conspicuous, for example, on transverse sections of the convolutions generally, that it obviously accounted for their unusually broad and massive character. It also seemed probable that the grey matter, which is more vascular, and is composed of tissue-elements perhaps more readily influenced by de-nutrition and mal-nutrition than the white substance, might have suffered more from atrophic wasting, under the combined influence of age and disease.

But the evident superabundance of white substance led me to examine, in contrast with other brains, the relative development of the great transverse commissure between the two hemi-

spheres—the corpus callosum. I have elsewhere pointed out[1] that, in the Bushwoman's brain, not only was the corpus callosum actually but relatively small as compared with the size of the cerebral hemispheres; and I have indicated this condition as a sign of inferiority in cerebral organisation. In Mr Grote's cerebrum, on the contrary, not only must the radiating fibres passing upwards or downwards from the thalami and corpora striata have been most abundant, for these ganglia were very large, especially the latter, but the corpus callosum was unusually large. Although the entire brain was short from before backwards, measuring only 7½ inches, the corpus callosum was 4 inches long; it reached within 1¼ inch of the anterior part, and within 2¼ inches of the hinder end of the hemispheres; its extremes of thickness were $\frac{16}{30}$ths and $\frac{6}{30}$ths of an inch, but its mean thickness was $\frac{12}{30}$ths of an inch. This gives a sectional area of $\frac{1440}{1500}$ths of a square inch; which, in comparison with the total area of the inner surface of one hemisphere, is about 1 to 2,—the ordinary proportion being, as I have found, 1 to 12·5.

It is obvious that so high a ratio of white commissural or radiating substance must have great significance as regards the more effectual utilisation of the grey matter itself. If the grey matter be the source or seat of all special actions, whether original or reflex, exercised by or within the cerebral hemispheres, the white fibres must be accredited with the offices not only of bringing impressions from the confines of the human frame, and conveying impulses to its muscular apparatus, but likewise of utilising to the utmost the power of the grey matter by multiplied connections of part with part, in countless lines of combination and reflection. Just as the usefulness of the apparatus employed in telegraphy is increased according to the number of its advehent and evehent wires, so the efficacy of a certain quantity of grey matter, containing a certain number of ganglionic corpuscles, is enhanced by the multiplicity and variety of the connections and combinations of these latter. Whether for old or for recent impressions, the paths of intercourse, combination, contrast, construction, and volitional impulse would all be increased, and the efficiency of the cerebral

[1] *Phil. Trans.*, 1863.

apparatus be thus improved. Certain it is that, under normal conditions, a well-developed corpus callosum must add to the possible, if not to the actual capacity for work of a bi-lateral cerebrum; and although cases of its absence, unsuspected during life, are on record, which require further investigation, yet its relative magnitude is undoubtedly associated with varieties in intelligence or training.

In Mr Grote's brain, the smaller commissural structures, antero-posterior and transverse, presented no peculiarities, either as to size or connections.

Summary of the preceding Report and Observations.

I. *Remarks on Mr Grote's Brain.*

1. The entire encephalon was somewhat above the average in size, if compared with the adult male brain at all ages. If allowance be made for the effects of senile wasting, it must be regarded as a rather large brain, but not as an actually or especially large one. There can be no doubt, however, that it was, at death, further diminished in size and weight through the effects of disease, as shown by its marked deviation from the ordinary ratio as compared with the body-weight.

2. As tested by the standard of macrocephaly adopted by Welcker, its utmost allowable weight was below that standard; and as contrasted with the encephala of certain other eminent men, it would find its place about one-third up from the lower end of the list.

3. The cerebellum was somewhat larger than in the adult male of mean stature, but it was smaller than it usually is in persons of the same age and height. As compared with the cerebrum, it was decidedly small, regard being had to the usual effects of difference of stature and age on these two organs. The cerebellum appeared both small and flattened.

4. The general form of the cranium was rather or nearly brachycephalic, but it was decidedly higher than usual. The cerebrum itself was, in accordance with the shape of the cranium, short, broad, and deep.

5. Examined by the eye, the frontal lobes of the cerebrum appeared to be very long on their upper surface, very wide in front of the Sylvian fissure, and both long and broad on their under surface; the parietal lobes were short and wide; the temporal lobes were also wide though short; the occipital lobes were small and shallow. On being weighed, the several lobes were found to be in very nearly their usual proportion,—a chief individual distinction being that the fronto-parietal mass was somewhat heavier than usual, this superiority being mainly due to an excess in the parietal lobes; the temporal lobes, however, were a little smaller, and the occipital lobes decidedly smaller than usual.

6. The cerebral convolutions were very massive, being not only broad and deep, but well folded, and marked with secondary sulci. This condition was observable all over the cerebrum, but chiefly remarkable in the frontal and parietal regions.

7. Studied in reference to Dr Ferrier's researches into the localisation of function in the brain, the relative size of certain convolutions or groups of convolutions suggests some reflections as to individual peculiarities, which, however, are scarcely sufficiently reliable to be summarised here.

8. The condition of asymmetry of the convolutions in the two hemispheres is very pronounced, and is, moreover, quite conformable to the arrangements found in other brains generally.

9. The superficial grey layer of the cerebral hemispheres was abundant, and presented nothing remarkable. The thalami and corpora striata were large, especially the latter.

10. The central white substance of the convolutions and of the entire hemisphere was very abundant, and the corpus callosum was so long that its sectional area was unusually great.

11. From the size and richness of the convolutions, the sufficiency of the grey matter both on the surface and in the interior of the hemispheres, and from the remarkable number of the white fibres, especially of the transverse commissural ones, the brain of Mr Grote must be pronounced to have been of very perfect and high organisation.

II. *General Observations.*

1. It is obvious from the measurements taken in this particular instance that the extreme circumference of the head is an unsafe guide as regards its internal capacity, and that the height is an indispensable quantity to be known. It is further apparent that, for many reasons, measurements of hats must be accepted as subject to many grounds of error, considered as data for estimating size of brain.

2. The records of the weights of the brains of eminent men require correction before they can be used for purposes of just comparison for the effects of age, stature, and disease.

3. Owing to the individual variability in the weight of the body, owing to relative obesity or emaciation, a comparison between it and the weights of the brain and its parts is quite unsatisfactory. But if the stature be expressed in inches, and the weights of the entire encephalon, the cerebrum and cerebellum, in ozs., terms of comparison are found which reveal very interesting results. Thus, whilst both the cerebrum and cerebellum, and therefore the entire encephalon, increases, not only absolutely but relatively, with the stature, it seems that the cerebellum is more influenced by this than the cerebrum,—a result not inconsistent with the supposed controlling power of the cerebellum over certain movements of the body and limbs.

4. It appears probable that a small cerebellum, implying a small inferior occipital fossa, may be usually associated with a compensatory extra height of the cranium, to make room for the cerebrum upwards, instead of backwards. Whether, further, dolichocephalism is an accompaniment of larger cerebella, and brachycephalism of small ones, is a question for future investigation. It also seems most desirable to determine not only the general cranial capacity, but also, if possible, the relative cerebral and cerebellar capacity of all skulls, national and individual.

5. A method of estimating the preponderance of one or other lobe of the cerebral hemispheres, is suggested and carried

out by ascertaining the weights of the several lobes, parted from one another in a certain defined manner. This method, modified to meet certain contingencies, will yield fruitful results if applied to the cerebra of different races and individuals, and to those of the higher mammalia, having figured brains. Sexual distinctions may thus also perhaps be detected.

6. The relative development of the convolutions must henceforth be studied under the new light thrown upon their functions by the researches of Dr Ferrier and others. This applies not only to the cerebra of different individuals of both sexes, but it may also be of the utmost importance in other respects, especially in reference to the condition of asymmetry of the convolutions on the two sides of the same cerebrum.

7. It is shown that this asymmetry is not accidental, but follows some general plan; and an attempt is made to explain this plan by referring it to the habit, common to and inherited by the human family, of using the right hand for special purposes more than the left, generation after generation.

8. The structure of the grey matter in the different regions marked out by Dr Ferrier's investigations requires careful and special examination. No individual differences were detected in it in different healthy brains.

9. Great importance is supposed to be attached to the relative development of the white fibres in any cerebrum, especially to the size of the corpus callosum, in reference to the actual working power of any given human cerebrum.

EXPLANATION OF PLATES I.–III.

These Plates are reproductions of Photographs of the Cerebrum of Mr George Grote.

Pl. I. Vertex view of the cerebrum.
„ II. Anterior view of the frontal lobes of the cerebrum.
„ III. Profile view of the left hemisphere of the cerebrum.

PLATE I.

PLATE II.

PLATE III.

THE CEREBRAL COMMISSURES IN THE MARSUPIALIA AND MONOTREMATA.

By JOHNSON SYMINGTON, M.D., F.Z.S., F.R.S.E., *Lecturer on Anatomy, Minto House, Edinburgh.*[1]

(Read to Section D. of the British Association, in Edinburgh, August 9, 1892.)

IN 1837 Professor, now Sir Richard, Owen published in the *Philosophical Transactions* of London a memoir "On the Structure of the Brain in Marsupial Animals." In this communication it was stated that the brains of the Marsupialia differed from those of all the Placental mammals in having no corpus callosum. Professor Owen admitted that the two hippocampi majores were united by a transverse commissure representing the lyra of the fornix or hippocampal commissure; but he held that a true corpus callosum, composed of transverse fibres passing above the ventricles, and uniting the greater part of the cortex of the two cerebral hemispheres, was absent in the Marsupialia. With reference to the hippocampal commissure, he wrote:—"This commissure may, nevertheless, be regarded as representing, besides the fornix, the rudimental commencement of the corpus callosum; but this determination does not invalidate the fact that the great commissure, which unites the supra-ventricular masses of the hemispheres in the Beaver and all other placentally-developed Mammalia, and which exists in addition to the hippocampal commissure, is wanting in the brain of the Wombat; and as the same deficiency exists in the brain of the Great and Bush Kangaroos, the Vulpine Phalanger, the Ursine, and Mauge's Dasyures and the Virginian Opossum, it is most probably the characteristic of the marsupial division of Mammalia" (p. 91). Owen selected the brains of the Wombat and Beaver, as illustrating the differences in the arrangement of the cerebral commissures in the Marsupialia and the Placental Mammals.

[1] From the Embryological Laboratory, University of Edinburgh.

In the following year, 1838, Eydoux and Laurent,[1] in an account of their dissection of the brain of an Echidna, maintained that the transverse fibres crossing the mesial plane above the anterior commissure were simply the hippocampal commissure, and not a true corpus callosum. They considered that the drawings given by Meckel[2] of the brain of the Ornithorynchus admitted of a similar interpretation, and they therefore held that the corpus callosum was absent in the Monotremata as well as in the Marsupialia.

In the third edition of Cuvier's *Anatomie Comparée*, 1844, its editors, MM. F. Cuvier and Laurillard, from original dissections of several Marsupial brains, supported the views of Owen. About this time Owen wrote the articles "Marsupialia" and "Monotremata" which appeared in Todd's *Cyclopædia of Anatomy and Physiology*, vol. iii. He adhered to his previously expressed opinions regarding the Marsupial brains, and from dissections of the brains of the Echidna and Ornithorynchus, he supported the conclusions of Eydoux and Laurent as to the absence of the corpus callosum in the Monotremes also.

The views of Owen were pretty generally accepted until 1865, when Professor, now Sir William H., Flower published a memoir[3] in the *Philosophical Transactions*, in which he controverted the conclusions of Owen, and maintained that a corpus callosum was present in the Marsupialia and Monotremata. Flower's memoir was illustrated by a series of drawings of mesial and transverse vertical sections through the brains of various placental and non-placental mammals. In addition to the human subject, the Placentalia were represented by sections of the brains of the Sheep, Rabbit, Sloth, and Hedgehog, and the Non-Placentalia by the Kangaroo, Wombat, Thylacine, and Echidna. The figures given by Flower were admirably adapted to illustrate the comparative development of the commissural fibres in the series of mammals selected. In each case a mesial section was made through the cerebrum, and on one half the crus and optic

[1] "Sur l'Encephale de l'Echidna comparé de l'Ornithorhynque, et considérations générales sur l'Encephale des Mammiferes et des Oiseaux," *Mag. de Zool.*, 1838.

[2] *Descr. Anat. Ornithorhynchi paradoxi*, Lipsiæ, 1827.

[3] "On the Commissures of the Cerebral Hemispheres of the Marsupialia and Monotremata, as compared with those of the Placental Mammals."

thalamus were removed, so as to expose the ventricular aperture (great transverse fissure of Bichat), fascia dentata, and corpus fimbriatum (see fig. 2). A drawing was then made of the structures exposed. The brain was also divided by a transverse vertical section passing through the anterior commissure and corpus callosum, or the mass which was supposed to represent the latter. A figure was given to show the relative distribution, in the plane of this section, of the anterior commissure and the corpus callosum.

From this series of illustrations, Flower endeavoured to show that the Marsupialia and Monotremata possess a true, although rudimentary, corpus callosum, composed of fibres homologous with those of the corpus callosum of the placental mammals. The corpus callosum in the higher mammalia is of large size and the anterior commissure small, while in the non-placental mammals the anterior commissure is highly developed, and the corpus callosum, if present, is relatively very small. Flower stated, however, that the corpus callosum is greatly reduced in size in the lower placental mammals, such as the Hedgehog, where its length is only one-fifth of the entire hemisphere. The anterior commissure, on the other hand, is increased in bulk. In the three Marsupials, Kangaroo, Wombat, and Thylacine, Flower figures, in the mesial section of each brain, a corpus callosum distinct from, although partially united below with, what he calls the psalterial fibres of the corpus callosum. The psalterial fibres correspond to the hippocampal commissure of Owen. In the Echidna the corpus callosum and its psalterial fibres are indistinguishable, and the whole mass is figured as corpus callosum.

In addition to the series of mesial and coronal sections of the brain above described, Flower has a drawing of a dissection of the brain from above. The appearances observed in this specimen have an important bearing on the subject under discussion, and will be best described in his own words:—"On looking at the upper surface of the brain (Plate xxxvi. fig. 4), the two hemispheres being partly separated, a transverse white band (B) is seen extending across the bottom of the longitudinal fissure, roofing over the anterior portion of the third ventricle, and occupying the same general position as the corpus callosum

in the ordinary mammal, but developed to a smaller extent even than in the Hedgehog. In the brain of Macropus Bennettii it was found to cover, when still undisturbed by removal from the cranial cavity, or contracted by spirit, about half the optic thalamus, and to measure from before backwards in the middle line a quarter of an inch, or one-sixth of the entire length of the hemisphere. It is situated deeply in the great longitudinal fissure, is thickened and most elevated posteriorly, where the margin, slightly and evenly concave, crosses the cavity of the 3rd ventricle (S), the peduncles of the pineal gland (T), and the optic thalamus (U). The anterior margin is also concave, but extremely narrow, the white substance being continued on each side of a longitudinal median cleft for some distance towards the front of the cerebral hemisphere, as if in its anterior part the two lateral halves of the commissure had not been joined together in the middle line. On close examination, it is seen to be composed of fibres of which the general direction is transverse, but on its upper surface can be distinguished a longitudinal median raphé, and on each side of this a few longitudinal white fibres, corresponding to the 'striæ laterales' of other mammals.

"On either side, the transverse fibres are lost beneath the overlapping grey matter, constituting the margin of the convolution of the corpus callosum—the 'labia cerebri' of some authors. To follow them further, the last-named parts must be carefully removed with the handle of a scalpel or some similar instrument, when a delicate broad laminæ, formed by the lateral expansion of the narrow transverse band, will come into view, passing at first horizontally outwards, and then curving upward above the precommissural fibres of the fornix (I), the cavity of the lateral ventricle, and the corpus striatum (R), and finally losing themselves in the medullary substance of the upper part of the cerebral hemispheres. The fibres radiate extensively forwards and backwards, but forming a continuous lamina posteriorly conterminous with those on the surface of the hippocampus major, anteriorly becoming much more delicate, so much so, indeed, that it is not easy to make a complete dissection of them without causing some rents like that on the left side shown in the figure, through which the cavity of the ventricle

below is exposed. This expansion of the transverse commissure in the hemisphere, though described by Pappenheim in the Opossum, appears not to have been observed by Owen in any of his dissections" (p. 644).

In describing the mesial aspect of the brain of the Kangaroo, Flower refers to the fact that the upper margin of the ventricular aperture is formed by the edge of a broad white band—the corpus fimbriatum. On tracing this band forwards, he says:—"It is found to be continuous with the hinder edge of the whole of the upper transverse commissure" (p. 645). He observed the extension of the hippocampal fissure forwards above the upper transverse commissure, but he makes no reference to a corresponding forward projection of the fascia dentata (gyrus dentatus).

The appearance of Flower's memoir was followed by a somewhat animated discussion between himself and Owen, which will be found in the *Proceedings of the Royal Society of London.*[1] Since then but little original work has been done in connection with this question, but what has been published is in favour of Flower's views rather than those of Owen.

In 1868 Dr Julius Sander published a paper[2] containing an account of the dissection of the brain of Macropus major and of Didelphis. His observations agreed with those of Flower. He has a drawing (see Pl. xviii. A, fig. 2) of a transverse vertical section of the brain of Macropus made, like Flower's, through the anterior commissure and what they regarded as the corpus callosum. This figure is much more favourable to the presence of a corpus callosum than Flower's, since Sander represents the white mass of the corpus callosum as passing outwards and upwards above the lateral ventricle, directly into the corona radiata. This is certainly an error. Flower's drawings show, what can readily be made out with the naked eye, viz., that this white bundle forms a curve with its convexity directed at first

[1] "On Zoological Names of Characteristic Parts and Homological Interpretations of their Modifications and Beginnings, especially in reference to the Connecting Fibres of the Brain," by Prof. Owen. Received March 10, 1865. Reply to Prof. Owen's paper "On Zoological Names," &c., by W. H. Flower, F.R.S. Received March 28, 1865.

[2] "Ueber das Quercommissurensystem des Gehirns bei den Beutelthieren," *Arch. f. Anat.* 1868.

outwards and then upwards, and bounded on its convex side by a distinct fissure which separates it from the larger white mass lying on the other side of the fissure. This fissure is the lateral ventricle. In cases where it does not extend so far upwards, its place is taken up by a connective tissue septum.

Professor H. T. Osborn has published several papers dealing with the cerebral commissures in the vertebrata. Most of his observations were made upon fishes, amphibia, and reptilia, but one[1] of his papers deals with the commissures in the Mammalia. Osborn holds that the upper commissure of the amphibian and sauropsidan brain represents the mammalian corpus callosum, while the lower commissure represents the anterior commissure. The view formerly held was that the upper and lower commissures in submammalian brains correspond to the pars olfactoria and pars temporalis of the mammalian anterior commissure. He does not appear to have made any observations himself upon the cerebral commissures in adult marsupial or monotreme brains, but he adopts the conclusions of Flower and Sander. So far as I am aware, Osborn is the only one who has made any study of the development of the cerebral commissures in the Marsupialia. He examined several pouch specimens of Macropus major, and gives drawings of his sections (see Plate xxv. figs. 24 to 27, *Morph. Jahrb.*, vol. xii.). All these figures, with one exception, show the fibres he calls corpus callosum confined in their distribution to the part of the inner wall of the cerebral hemisphere corresponding to the hippocampus major and gyrus dentatus. In one case (see fig. 25) they seem to form a comparatively large bundle going upwards to the inner and part of the upper wall of the hemisphere. It is so different from his other figures and from what I have found in the adult, that I feel compelled to doubt its accuracy.

The most recent contribution to the anatomy of the Marsupial brain is by Professor C. L. Herrick.[2] With reference to the cerebral commissures, we have some difficulty in deciding

[1] "The Origin of the Corpus Callosum, a contribution upon the Cerebral Commissures of the Vertebrata," *Morph. Jahrb.*, vol. xii. parts 1 and 2.

[2] "The Cerebrum and Olfactories of the Opossum, Didelphys Virginica," *Journal of Comparative Neurology*" vol. ii., 1892.

as to his precise views on the question of the existence of a corpus callosum independent of the hippocampal commissure. He does not mention the papers of Owen and Flower, but says—"*Callosum and hippocampal commissure.*—It is not necessary to recount the various opinions and discussions of the callosum in the Marsupials. Until Osborn, most authors had agreed that the callosum is absent, and functionally replaced by the anterior commissure. Professor Osborn has done much to place this whole subject in its proper light; and we agree with him in respect to the essential homologies of the dorsal commissural system" (p. 8). . . . . "In the case of Didelphys, the hippocampus and related structures are strongly, not to say predominatingly developed" (p. 9). He appears to regard the cephalic portion of the dorsal commissure as the corpus callosum, and the caudal portion as the hippocampal commissure. He gives a number of figures of transverse vertical and horizontal sections of the brain of Didelphys. His drawings agree with my own specimens, but he marks as gyrus fornicatus what is generally called the hippocampus major, or cornu ammonis, and the characteristic layer of cells in the gyrus dentatus or fascia dentata he designates gyrus uncinatus (see figs. 4 and 5 on Plate A, illustrating his paper). In fig. 3 of the same plate he marks as "splenial fissure" what I believe to be the hippocampal fissure.

The material which I have used in my study of the cerebral commissures in the Monotremata and Marsupialia comprises—

1. Three brains of the Ornithorynchus paradoxus, all preserved in spirit. Two of these were used for naked-eye examination, and one was embedded in paraffin, and a complete set of coronal sections mounted serially for microscopic examination.
2. An incomplete set of microscopic sections of the brain of an Echidna.
3. The brain of an Australian Opossum hardened in spirit, embedded in paraffin, cut into a series of coronal sections, and mounted for microscopic examination.
4. The brain of a Derbian Wallaby—Halmaturus derbianus—hardened in Müller's fluid. A mesial section was

made of this brain, and from the one half several slabs were cut, embedded in collodion, stained by the Weigert-Pal method, and mounted for microscopic examination.

5. The brains of several other Marsupials—some hardened in spirit, and others in Müller. These were used for naked-eye dissection.
6. A pouch specimen of Macropus major. The brain was hardened in spirit, and mounted serially like No. 3.

I desire to express my best thanks to my friends Professor D. J. Cunningham, F.R.S., Professor G. B. Howes, Mr F. E. Beddard, F.R.S., Professor D'Arcy Thompson, and Mr Hardcastle for kindly giving me specimens.

THE ANTERIOR COMMISSURE.—Of the fibres uniting the two cerebral hemispheres in the non-placental mammals, those forming the anterior commissure are undoubtedly the most highly developed. In this respect the brains of all these animals present a very marked contrast with those of any of the placental mammals. It is undoubtedly true that the corpus callosum diminishes pretty regularly in size as we pass from the higher to the lower placental mammals, and this is probably associated with some slight compensatory increase in the size of the anterior commissure. As Professor Flower has shown, the common Hedgehog is an excellent example of an animal in which the corpus callosum is very small. Flower described its anterior commissure as increased in bulk. This increase, however, does not appear to me to be very marked. Thus, in a mesial section of the brain it was only 1·4 mm. in its longest diameter and about ·8 mm. in its narrowest, and the corpus callosum was between two and three times larger than it.

Assuming that the anterior commissure in this animal, as compared with higher mammals, is relatively large, this may be due mainly to the highly-developed condition of its olfactory apparatus, for it is well established that the anterior commissure contains fibres which turn forwards to become continuous with one of the roots of the olfactory nerve. Professor Osborn[1] recognises in the Mammalian brain three divisions of the

[1] *Op. cit.*, p. 3.

anterior commissure, viz., the olfactory, temporal, and frontal. The olfactory we have already referred to. The temporal turns backwards below the caudate and through the lenticular nucleus to the temporal, and probably the occipital, regions of the brain. The frontal, according to Osborn, supplies the ventro-lateral portion of the mantle, and is complemental in size with the corpus callosum. "Thus it is very large in the monotremes and marsupials, and gradually diminishes in the higher mammals with the increase of the corpus callosum" (p. 540). In place of a gradual, I would say that there is a very abrupt and sudden diminution in these fibres of the anterior commissures in passing from the non-placental to the lower placental mammals. In a transverse vertical section of the brain of the Hedgehog passing through the corpus callosum and anterior commissure, the fibres of the latter can be seen forming a bundle of about the same size as the corpus callosum. This bundle extends outwards on each side for about 3 mm., and then rapidly diminishes in size, to form a delicate layer, just visible to the naked eye, which goes outwards and upwards beneath the corpus striatum to join the corpus callosum. The sudden decrease in the size of the anterior commissure is due to the olfactory and temporal portions turning forwards and backwards respectively. Ganser[1] shows a similar arrangement in the Mole, although from his drawings (see figs. 10 and 11) the frontal portion of the anterior commissure appears to be larger in the Mole than my sections show it in the Hedgehog.

In all the non-placental mammals the anterior commissure is much more highly developed than in the Hedgehog or Mole. The increase in its extent is practically confined to those fibres which pass outwards and upwards towards the outer wall of the hemisphere. These fibres, the pars frontalis of Osborn, can readily be seen in a transverse vertical section of the brain of any non-placental mammal to pass first outwards and upwards, and then upwards and inwards as far as the inner wall of the hemisphere. They unite the cortex of the two hemispheres situated on the ventral, outer, and dorsal aspects, and also that on the inner walls above the hippocampal fissures. In a recent

[1] "Vergleichend-anatomische Studien über das Gehirn des Maulwurfs," *Morph. Jahrbuch*, bd. vii.

paper[1] I showed that, in regard to the organ of Jacobson, the Monotremes differed much more from the Marsupialia than the latter did from the placental mammals. Such, however, is not the case with respect to the commissural fibres of the cerebrum. In both divisions of the non-placental mammals the anterior commissure unites corresponding portions of the cortex. There are, however, certain differences in the relations of the fibres as they pass to the cortex. In a transverse vertical section of the brain of the Ornithorynchus (fig. 1), made opposite the anterior commissure, the fibres of this structure are found to extend outwards below the corpus striatum (*c. s.*), and then ascend on its outer side to come into relation with the upper part of the outer wall of the lateral ventricle. The corpus striatum is not divided into a nucleus caudatus and a nucleus lenticularis by longitudinal fibres arranged to form an internal capsule, but its grey matter is traversed by a large number of small rounded bundles of longitudinal fibres, which are pretty uniformly distributed throughout its substance.

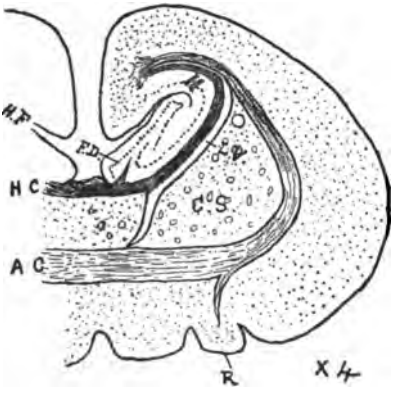

FIG. 1.—Transverse vertical section of brain of Ornithorynchus. A.C, anterior commissure; H.C, hippocampal commissure. The fibres of this commissure on the inner wall of the lateral ventricle form the alveus of the hippocampus major (H). They are drawn rather too thick. H.F, hippocampal fissure. The corresponding fissure on the other side is not lettered. R, Rhinencephalon. C.S, corpus striatum, L.V, lateral ventricle. F.D, fascia dentata.

From Flower's[2] drawing of a corresponding transverse section of the brain of the Echidna, it appears that the Echidna agrees in this respect with the Ornithorynchus.

In both the Australian Opossum and the Wallaby the corpus striatum is divided at the level of the anterior commissure into two distinct nuclei by an internal capsule; and while the lower

[1] "On the Nose, the Organ of Jacobson, and the Dumb-bell-shaped Bone in the Ornithorynchus," *Proc. Zool. Soc.*, 1891, No. xxxix.

[2] *Op. cit.*, p. 1, Plate xxxviii. fig. 8.

fibres of the commissure sweep round below and external to the lenticular nucleus, the upper ones go into the internal capsule. In my serial sections of the brain of the Australian Opossum the upper and posterior fibres of the anterior commissure form a more compact bundle than the other fibres of the commissure, and stain more deeply with carmine. These fibres turn outwards and backwards into the internal capsule, and perhaps represent the pars temporalis of the anterior commissure. In none of the non-placental mammals have I been able to recognise any clear distinction between the temporal and so-called frontal portions of the anterior commissure, and in all of them the olfactory portion is distinct.

THE HIPPOCAMPAL COMMISSURE.—The points in dispute in connection with the question of the presence or absence of a corpus callosum in the non-placental mammals are partly those of the interpretation of admitted facts and partly those connected with the actual distribution of nerve-fibres. Both Owen and Flower admit the existence of commissural fibres uniting the two hippocampi majores. Owen considers them to be the transverse fibres or lyra of the fornix or the hippocampal commissure. Flower holds that they are a part of the corpus callosum, and he names them the psalterial fibres of the corpus callosum. It seems to me that there are good reasons for distinguishing these fibres from those of the corpus callosum of the placental mammals, since they unite portions of the cortex—hippocampi majores and gyri dentati—which have a structure quite distinct from that of the rest of the cortex. Further, these fibres, although they may lie in the mesial plane, in close relation with the corpus callosum, yet in their distribution they are intimately associated with the fornix. Thus Professor Obersteiner,[1] in reference to the human brain, writes:—"The two posterior crura (pillars) of the fornix, where they lie beneath the corpus callosum, include between them a structure, triangular and equilateral, with an angle pointing forwards, psalterium (lyra Davidis). It consists of white matter exhibiting a transverse fibrillation, and is often not completely united to the corpus callosum, the space left between them being

[1] *The Anatomy of the Central Nervous System.* By Dr H. Obersteiner. Translated by Dr Alex. Hill. London, 1890.

called Verga's ventricle" (p. 74). Flower objected to the hippocampal commissure being regarded as a part of the fornix, as he considered that the fornix was a purely longitudinal commissure. Honegger,[1] however, in his elaborate study of the fornix, recognises the existence of transverse fibres; and, indeed, he figures them in his phototypes of sections of the brain of the Mouse.

From the summary of the literature which we have already given, it is evident that Professor Flower based his belief in the presence of a corpus callosum upon the existence of transverse commissural fibres uniting portions of the cortex other than the two hippocampi, although, as we have seen, he thought the hippocampal commissure ought to be regarded as a part of the corpus callosum. Indeed, it is upon the presence or absence of these additional fibres that the whole controversy really rests. We have already quoted (see page 71 *et seq.*) Flower's description of such fibres in the brain of the Great Kangaroo. It will be observed that he describes these fibres as losing themselves in the medullary substance of the upper part of the cerebral hemispheres, but forming a lamina "posteriorly conterminous with those on the surface of the hippocampus major." In his figures of the brains of the Marsupialia and the Echidna (see M, figs. 2, 4, 6, and 8), he shows the "corpus fimbriatum" or "edge of posterior crura of fornix." I am satisfied that a large number of these fibres cross the mesial plane to form the hippocampal commissure (N in Flower's figures). Above and in front of the hippocampal commissure he shows the corpus callosum (marked B). Now, these fibres are distributed, like those of the corpus fimbriatum, to the gyrus dentatus and hippocampus major, their peculiar position in these animals being due to the fact that the gyrus dentatus and hippocampus major are continued forwards and upwards on the inner aspect of the hemisphere nearly to its anterior extremity, and this causes a corresponding forward extension of their commissural fibres. Flower's drawing of a transverse vertical section of the brain of a Kangaroo (see Pl. xxxviii. fig. 2) is an excellent illustration of the naked-eye appearance of these fibres; but he gives no indication, either in

[1] "Vergleichend-anatomische Untersuchungen über den Fornix," *Recueil Zoologique Suisse*, tome v. No. 2 et 3, 1890.

the text or the figures, that he recognises the cortex in contact with these fibres as the anterior prolongation of the hippocampi majores and gyri dentati, although such they undoubtedly are. He does not label them in his drawings, but from his text he appears to regard them as the convolution of the corpus callosum. Flower's observations, made nearly thirty years ago, were apparently confined to a naked-eye examination, hence this failure to distinguish the special structures—gyrus dentatus and hippocampus major. A careful microscopic examination of a series of transverse vertical sections will show that the fibres described as the corpus callosum by Flower and others are merely commissural fibres for the anterior parts of the hippocampus major and gyrus dentatus of one side with those of the other, and that they are continuous with the hippocampal commissure and tænia hippocampi, which have a similar relation to the posterior part of these convolutions.

Fig. 2 is a view of the inner aspect of the cerebrum of a Derbian Wallaby. The line *a* shows the plane in which the

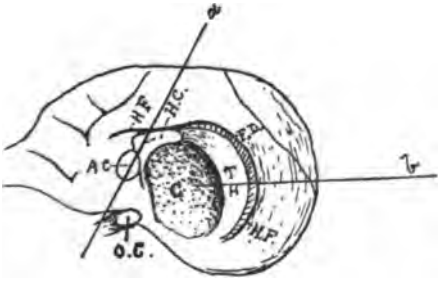

Fig. 2 (Life size).

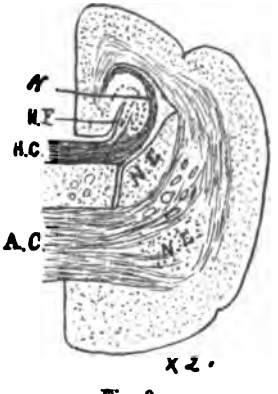

Fig. 3.

cerebrum was divided in the section represented in fig. 3, while the line *b* indicates the position of the section of which fig. 4 is a drawing.

The same lettering as for fig. 1 has been used for figs. 2, 3, and 4. In figs. 2 and 4, *T.H*, tænia hippocampi. In fig. 4, *C.R*, corona radiata.

The fibres covering the ventricular surface of the hippo-

campus major at their upper and inner extremity come into relation with the white matter from the anterior commissure which goes to the cortex on the inner aspect of the cerebrum, situated immediately above the hippocampal fissure, and in some cases it appears to the naked eye as if the fibres of the

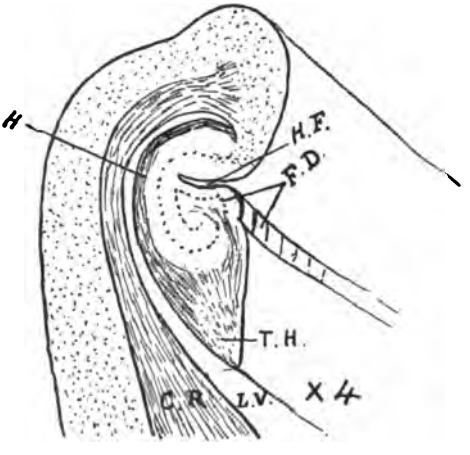

Fig. 4.

hippocampal commissure might assist to a slight extent in supplying the cortex lying above the hippocampal fissure. As a rule, the surface of the hippocampus major is bounded externally by the ventricular cavity, but in some places the ventricle does not extend so high, and then the surface of the hippocampus lies in contact with the centrum ovale of the hemisphere. In a section of this kind the mistake has sometimes been made (see Ganser) of supposing that the fibres of the hippocampal commissure go directly into the corona radiata.

In order to ascertain properly the distribution of the fibres of the hippocampal commissure, I hardened the brain of a Wallaby in Müller's fluid, and stained the fibres by the Weigert-Pal method. These specimens showed that the fibres passing from the mesial plane outwards separated into two bundles, the smaller going to the fascia dentata, and the larger to the ventricular surface of the hippocampus major. In their course they gave off fibres to the subjacent grey matter. The fibres of the hippocampus, considerably reduced in size when they reached

the upper and inner end of this structure, did not radiate toward the grey matter of the adjacent convolution, but appeared to alter their direction and run longitudinally. I made similar sections across the corpus fimbriatum and adjacent portions of the hippocampus major and fascia dentata. The fibres of the corpus fimbriatum, cut transversely, were seen to send fibres to the gyrus dentatus and hippocampus major, and these were distributed in the same way as those fibres which passed from the mesial plane transversely to the anterior part of the same convolutions.

Dr Luigi Sala [1] (1) has recently published a beautiful drawing (see Pl. iii.) of a section through the corpus fimbriatum, fascia dentata, and hippocampus major in the brain of a Rabbit. The specimen was stained by the Weigert method. It shows a distribution of the fibres to the hippocampus major and gyrus dentatus practically identical with what I have found in the Wallaby. In examining a series of sections stained by Weigert's method a few fibres of the hippocampal commissure may sometimes be seen joining those of the anterior commissure, but the vast majority of the fibres going to the cortex just above the hippocampal fissure are derived from the latter.

The hippocampal commissure in the non-placental mammals resembles the corpus callosum of the placentalia in having its fibres collected into a narrow bundle where they cross the mesial plane. On either side, however, they spread out, the anterior ones turning forwards, and the posterior backwards. Their distribution will be found to correspond with that of the hippocampus major and fascia dentata. The fibres going forwards form a much thinner layer than those turning backwards, because the greater part of these convolutions lie behind the point where the commissure crosses the mesial plane.

It appears to me, therefore, that the cerebral commissures in the Monotremata and Marsupialia present several characters by which they can be distinguished from those of the placental mammals, viz., (1) the anterior commissure is as large and generally much larger than any other transverse commissure of the cerebrum, and it unites the whole of the cortex of the two

[1] L. Sala, "Zur feineren Anatomie des grossen Seepferdefusses," *Zeitschrift für wissenschaftliche Zoologie*, 1891.

hemispheres except the gyri dentati and hippocampi majores; (2) they have no true corpus callosum; and (3) the superior transverse commissure is simply a commissure for the gyri dentati and hippocampi majores.

In the placental mammals—(1) The anterior commissure is much smaller than the other transverse commissures, and it never extends to the cortex on the upper surface of the cerebral hemisphere, or to that on the upper part of the inner surface of the hemisphere; (2) a true corpus callosum is present, as well as (3) a hippocampal commissure.

My observations on the brains of the lower placental mammals have been limited to the Hedgehog and the Mole. From Professor Flower's drawing (see Pl. xxxvii., fig. 5, *Phil. Trans.*, 1865) it appears probable that some of the Edentates may approach more nearly to the arrangement of the cerebral commissures in the Marsupialia than do the Insectivora. I hope soon to be in a position to investigate this question.

CONTRIBUTIONS TO THE HISTOLOGY OF THE HEDGEHOG (*ERINACEUS EUROPÆUS*). By E. W. CARLIER, M.D., B.Sc., F.R.M.S., &c., *Senior Assistant to the Professor of Physiology in the University of Edinburgh.* (PLATES IV., V., VI.)

PART I. THE ALIMENTARY CANAL.

As already pointed out by Prof. Flower,[1] the hedgehog possesses only three circumvallate papillæ, and the epithelium of its œsophagus terminates below in a festooned border; the stomach is simple, the pyloric sphincter well developed, the duodenum at its commencement is surrounded by a thick ring of Brunner's glands; the intestine, which is slender, and six or seven times the length of the animal, presents no sign of division into small and large gut; there is also a total absence of cæcum, ridges and valvulæ conniventes, but the villi are long, slender, cylindrical in shape, and extend to what may be looked upon as the colon, at the commencement of which they disappear, and Peyer's glands are well marked.

The Tongue.—The tongue is long and slender, and covered on its upper surface with small recurved conical papillæ, amongst which a few large fungiform papillæ may be seen; the three circumvallate papillæ are situated far back, and disposed in the usual V-shaped manner. The under surface of the organ is generally smooth, except at the tip, where it is slightly rugose.

The epithelial covering, which is thick and dense, consists of stratified squamous cells of the usual type; their protoplasmic bridges, however, are very short and inconspicuous; a few layers of cells only on the surface are keratinised. Some cells of the stratum Malpighi, scattered here and there amongst the others, present a crescentic nucleus lying at the side of a vacuole; to some of these, nerve fibrils may be traced, resembling closely those described by Haycraft[2] in the carapace of the tortoise.

[1] Lectures on the Comparative Anatomy of the Organs of Digestion of the Mammalia. Lecture vii. *Medical Times and Gazette*, vol. ii. p. 1.

[2] Terminations of Nerves in the Nuclei of the Epithelial Cells of Tortoiseshell, *Quarterly Journal of Microscopical Science*, 1890.

Longitudinal sections of the tongue cut in gum, and stained for fifteen minutes in Ehrlich's acid hæmatoxylin, washed in tap water for thirty minutes, then transferred to a 1-2000 watery solution of benzo-purpurine B for thirty minutes, decolorised in acid alcohol 70 per cent., till they assume a reddish-yellow tint, and finally mounted in balsam, show the structure of the conical and fungiform papillæ to perfection.

The conical papillæ consist entirely of epithelial cells derived from the deepest cells of the stratum Malpighi, covering a papilla of the subjacent fibrous tissue; this germinal layer forms on the anterior aspect a thick, blunt projection downwards and backwards into the fibrous papilla, converting it into a shallow cup. From this projecting mass of germinal epithelium the greater part of the cells of the papilla arise, so that it seems to be a special arrangement for the development of the epithelial part of the papilla. The fibrous tissue beneath this germinal mass is richly supplied with capillary blood-vessels (Pl. IV. fig. 1).

The epithelium of the spinous papilla may be divided into two portions—an anterior, which springs from the germinal process just alluded to, and which constitutes the greater part; and a posterior portion, which springs from the adjacent growing part of the stratum Malpighi, and of which the tip of the papilla exclusively consists.

If we follow the cells of the anterior portion as they grow outwards, we shall see that they gradually increase in size, assume an elongated shape, and that their long axes correspond with that of the papilla itself (Pl. IV. fig. 1, *e*). The cells now appear of a bright orange colour, due to their containing granules of varying size of eleidin, which stain deeply orange with benzo-purpurine; their nuclei, which have also become elongated, stain pale violet with the hæmatoxylin. These cells come to a point in the middle line of the papilla where they meet similar cells of the posterior portion, giving rise to a pointed conical mass of orange-staining cells in its interior. Above these orange cells, and apparently derived from them, are, on the anterior aspect of the papilla, a number of long spindle-shaped cells, which stain of a very pale blue, and exhibit small

rounded or oval nuclei (Pl. IV. fig. 1, *a*): they do not, however, extend as far as the point.

The orange-staining cells of the posterior portion take origin at a lower level than those of the anterior portion; they project upwards to meet them as already described, but do not present any distinct granulation, the eleidin appearing to be diffused throughout the cells (Pl. IV. fig. 1, *f*).

A citron-yellow mass, of structureless appearance, is situated above these cells, and extends downwards behind them nearly to the germinal layer of the epithelium: it presents faint striæ suggestive of cell outlines, but no nuclei, in this respect resembling the stratum corneum, and is no doubt composed of closely appressed keratinised cells derived from those immediately below. The tip of the papilla is entirely composed of this material (Pl. IV. fig. 1, *k*). The papilla is distinctly marked off from the surrounding epithelium by a structureless keratinised material, continuous on the one hand with that just described, and on the other with the stratum corneum; on section it appears as an irregular branching septum, very suggestive of solder, seeming to run in and fill up all the interstices between the cells (Pl. IV. fig. 1, *s*); beneath this the deeper layers of the epithelium are continuous with the growing part of the stratum Malpighi of the general mucous membrane, which is puckered below as if the papillæ had been violently thrust through it from within. The conical papillæ of the cat's tongue, when treated in the same manner, do not exhibit similar appearances.

The fungiform papillæ are much less numerous and far larger than those just described. They consist of a projection of the fibrous tissue of the mucous membrane, which is often carried up above the level of the tips of the spinous papillæ, covered with a thin layer of epithelium. On section each papilla presents the appearance of a thick pedestal, topped by a flat, table-like piece, flush with the anterior surface of the pillar, but projecting considerably beyond it posteriorly, forming an overhanging ledge. The epithelium which covers the surface of the papilla is uniform in thickness, and consists of three layers—an outer, of extreme thinness, composed of stratum corneum, continuous with that of the general epithelium of the tongue; a middle, much thicker, staining orange,

and containing eleidin, which gradually tapers off along the sides of the papilla; and an inner, consisting of one or two layers of germinal cells, continuous with the innermost layer of the stratum Malpighi. An occasional taste-bulb may be found in the epithelium.

The fibrous part of the papilla, which is simple, is composed of ordinary connective tissue, containing numerous corpuscles and capillary blood-vessels; sometimes a bundle of nerve fibres may be seen running up the centre towards the epithelium, where they appear to end; at other times a few fibres of the vertical muscle of the tongue project for a short distance into its interior.

The circumvallate papillæ hardly differ from those of other animals; they present a slight central depression, and the taste-bulbs are confined to the papillar side of the valleys. The epithelium is thin, and similar in structure to that covering the tongue generally. At the point where that covering the outer surface of the valleys joins the general epithelium it is extremely thin, and immediately under it a conspicuous vein is situated. The connective tissue of the papilla is very cellular, and often contains large acini of serous glands, having small ganglion cells in connection with them; their ducts open into the bottoms of the valleys with those of the serous glands situated among the muscles.

The connective tissue of the mucous membrane is thin but very dense at the tip of the tongue, becoming thicker and looser towards its attached end; it contains branched connective tissue corpuscles lying in branching cell spaces, and in the posterior third a few isolated ganglion cells of small size.

The connective tissue between the muscle-fibres is loose, cellular, and contains much fat, especially deep down in the posterior part of the tongue. It is rendered very conspicuous by the great number of coarsely-granular corpuscles which it contains. The granules of these cells stain very deeply with acid hæmatoxylin and all basic aniline dyes, and are situated entirely in the protoplasm, none being visible in the nucleus, which usually refuses to stain, and in which a single deeply-staining nucleolus may sometimes be found.

These coarsely-granular cells, "plasma cells" of Waldeyer,[1]

[1] "Ueber Bindegewebzellen," *Archiv f. Mikros. Anat.*, bd. xi.

appear to spring from small, rounded, nucleated, connective tissue corpuscles, similar to those that develop into fat cells. They may, however, even at this early stage, be readily distinguished from all other forms of connective tissue corpuscles by exhibiting one or more large granules in their protoplasm, having all the characteristics shown by those that fill the adult cells (Pl. V. fig. 1, *a*).

There seems to be no evidence of a transformation of these cells into fat cells, as was suggested by Waldeyer;[1] they seem simply to increase in size, to accumulate more granules in their protoplasm, and to accommodate themselves to the shape of any space in which they may happen to be. They may therefore be oval, round, polyhedral, or stellate in shape according to circumstances. Later they appear to spread themselves out somewhat, lose their granules, except in the neighbourhood of the nucleus, where they remain some time longer, but eventually these disappear also, and the cell then loses completely its characteristics, and cannot be distinguished from an ordinary fixed connective tissue corpuscle (Pl. V. fig. 1, *f*).

These cells are by no means confined to the connective tissue of the tongue, but are numerous all over the body, and especially so in the neighbourhood of blood-vessels, where they may often be seen in all stages of growth.

Their function is at present unknown; they appear to be more numerous in animals which have been copiously fed after having been made to fast for some time (Korybutt-Daskiewicy[2]), which has suggested that they may be merely overfed ordinary connective tissue corpuscles (Ehrlich).[3] They appear to be most numerous in this animal soon after it has begun again to feed in spring, but they never entirely disappear from the body, and in the tongue they seem to be as numerous in winter as in summer. They may possibly be of service in the nutrition of the body, as, towards the end of hibernation, no young plasma cells can be seen, only adults, and cells which have lost many of

[1] "Ueber Bindegewebzellen," *Archiv f. Mikros. Anat.*, bd. xi.

[2] "Ueber die Entwickelung der Nerven und Plasmazellen beim Frosche," *Archiv f. Mikros. Anat.*, bd. xv.

[3] "Ueber die specifischen granulationen des Blutes," *Verhdl. d. Physiol.*, 1874, No. 20.

their granules. In spring and autumn, on the other hand, many young cells may be seen, but effete ones are rare. Their large number also suggests that they must subserve nutrition. Possibly the granules they contain may be gradually used up during hibernation, the animal being thereby supplied with some material essential to its wellbeing, which, owing to the torpid condition, it is at the time unable to procure.

The muscles of the tongue resemble those of other animals in general arrangement and structure, with the exception of a few fibres deeply placed posteriorly, which present somewhat embryonic characters. The fibres of the superficial lingual muscle are worthy of special note. Three varieties may be made out:—

1. Most of the fibres consist of very fine fibrils, and possess nuclei only under the sarcolemma, and call for no further comment (Pl. V. fig. 2, *a*). 2. Coarsely-fibrillated fibres, of which a few only exist, scattered here and there among the others; their nuclei, as usual, are under the sarcolemma. 3. Curious fibres found scattered in an isolated manner or in groups all over the organ. Each consists in a central core of ordinary striped muscle, with fine fibrils, surrounded by, but slightly separated from, a tubular sheath of striped muscle, the fibres of which run at right angles to those of the core; sometimes a nucleus may be seen in the space between this sheath and the core. Outside the sheath there is a varying quantity of undifferentiated granular protoplasm containing nuclei, which are often angular in appearance (Pl. V. fig. 2, *b*). These fibres are at no time very numerous.

If the mechanism of such a fibre be studied, it will be seen that if the central core were alone to contract, the fibre as a whole would be shortened; if the sheath were alone to contract, the fibre as a whole would be lengthened; if both were to contract at the same time, no movement would probably result. The fibres appear to be too few, however, to be of much use in the movements of the tongue, and not symmetrical in position; I am rather inclined to look upon them as imperfectly developed, like those of Purkinje, in the heart, and therefore of no special significance.

The glands of v. Ebner are large, but exhibit the usual structure; the mucous glands present an extraordinary development

in the posterior ninth of the organ; where they extend among the muscles, through the whole thickness of the tongue, their ducts are slightly dilated just before reaching the surface.

During hibernation the tissues of this organ, and of the body generally, are far less readily acted upon by staining reagents than during summer, it taking twice or three times as long to produce the same intensity of stain with the same methods, and in some cases a faint coloration is all that can be obtained. The cause of this difference is rather obscure, but possibly depends on some slight alteration in the chemical characters of the tissues. Beyond the staining reaction, the changes in this organ are very slight, being mainly confined to the glands which remain inactive throughout nearly the whole period.

Œsophagus.—The œsophagus is chiefly remarkable for the thickness of its mucous membrane, and the absence of mucous glands.

The lining epithelium is very thick and of the ordinary type; it terminates below in a sharp festooned border; the connective tissue of the mucosa is dense, and contains, besides the usual elements, large numbers of plasma cells, which almost entirely disappear during hibernation. The muscularis mucosæ is greatly developed, consisting of large bundles of coarse non-striped fibres, longitudinally placed. The fibres are disposed in a single layer, differing therefore from the arrangement in the Cat, where three well-marked layers may be made out; at the junction of the œsophagus with the stomach, this mass of muscle quickly tapers down, to become continuous with the thin muscularis mucosæ of that organ.

The submucous coat is reduced to a minimum, due to the total absence of all glandular structures, mucous glands being entirely absent below the pharynx, with the exception of a few scattered acini, situated near the cardiac end, internal to the muscularis mucosæ, and therefore in the mucous membrane. There are, however, some serous glands in the submucosa of the organ, arranged in a ring round the cardiac orifice of the stomach, the long ducts of which pierce the muscle and epithelium, to open just above the festooned border. Lymph follicular tissue is also totally absent from the whole length of the tube,

with the exception of a few solitary glands in the neighbourhood of the stomach.

The muscular coat is thick, and consists throughout its whole length of striped muscle fibres of the usual type, arranged obliquely in two layers. Near the stomach, where they pass into the plain muscle fibres of that organ, some fibres of embryonic type may usually be seen. Occasionally a few adventitious striped fibres may make their appearance in the submucous coat, when they often exhibit nuclei surrounded by a little undifferentiated protoplasm situated here and there among the muscle fibrils, as well as the usual nuclei under the sarcolemma (Pl. IV. fig. 2). These fibres approximate much more closely to the amphibian than to the mammalian type of striped muscle.

Stomach.—Independently of the rugæ, sections of the mucous membrane of the stomach present an undulating appearance, which is mainly due to variation in the length of the glands.

Immediately following the abrupt termination of the œsophageal epithelium is a small area, the glands in which contain only one kind of cell, and similar to those of the pyloric end in appearance, but possessing only short ducts. These are followed by glands of the usual cardiac type. The parietal cells are at first confined to the closed ends of the cardiac glands, but quickly become more numerous as we recede from the œsophagus.

The cardiac glands extend over $\frac{9}{10}$ths of the stomach, and are of the usual type; they vary in length, including the duct, from 0·42 mm. to 0·70 mm., and have an average thickness of 0·04 mm. at their thickest part.

The ducts, which vary from 0·08 mm. to 0·20 mm. in length, are broad, and lined by the usual clear columnar cells, the appearances presented by which vary with their condition. When the cells have been active for a time—that is, when their contents have been discharged into the stomach—the cells present a finely-granular appearance, due to their fine-meshed protoplasmic network, which stains of an orange colour with benzo-purpurine B. The cells themselves appear angular, and the nucleus, which is oval and placed near the attached end, is full, and exhibits a nuclear network (Pl. IV. fig. 4, *c*). When,

however, the cell has been at rest for some time, it has a swollen appearance, the angles are to a certain extent rounded off, and the whole cell is much less granular; a fine network is visible in it, the strands of which seem stretched. This clear appearance is due, no doubt, to the cell containing a substance, mucigen, antecedent to mucin, which stains of a faint blue violet tint with acid hæmatoxylin, at the same time the nucleus recedes further into the attached end of the cell, and if the cell be very distended has the appearance of a shrivelled body, often of crescentic shape (Pl. IV. fig. 4, *d e*).

It is stated in Foster's[1] physiology that these cells burst open at their free ends, thereby allowing their contents to escape into the cavity of the stomach, as is the case with the chalice cells of the small intestine. After diligent search, I have failed to find sufficient evidence for concluding that this is the usual mode of discharge, but believe rather that the mucigen is more often, nay almost always discharged, without rupture of the cells, resembling the compound mucous glands in this respect. Between the attached ends of the cells are many replacement cells and a few leucocytes; beneath the attached ends a cribriform basement membrane is developed by a flattening of the cells of the subjacent adenoid reticulum, as is the case in other animals (Foster[2]).

The neck of the gland is short, 0·02 mm. to 0·08 mm., and contains only central cells, the protoplasmic network of which stains blue with acid hæmatoxylin. This arrangement is the opposite of that which occurs in the Rabbit, where the parietal cells are by far the most numerous in the necks of the glands.

The body of the gland is 0·32 mm. to 0·46 mm. in length, and presents both central and parietal cells, the latter so closely packed together as to entirely obscure the central cells in surface views of the acini. The parietal cells are of the usual type, each situated in a little compartment of its own, surrounded by basement membrane; they call for no further comment.

The several parts of these glands are perhaps best differentiated by staining in 1-1200 watery solution of eosine, and subsequently in 1-1200 watery solution of iodine green, and finally mounting in balsam.

[1] *Text-book of Physiology*, London, 1890. [2] *Ibid.*

At the spot where the cardiac part of the stomach passes into the pyloric, the cardiac glands suddenly cease to give place to the pyloric glands.

The ducts of the pyloric glands are long and wide, and are lined by the same mucigen, forming cells that line those of the cardiac end. The secreting part, which is very short, is lined by columnar cells that resemble very closely those found in the acini of Brunner's glands of the duodenum; they differ from the central cell of the cardiac glands in staining reactions, their protoplasm staining of a faint purple with acid hæmatoxylin, and the protoplasmic network of an orange tint with benzopurpurine B, which that of the central cells never does; the nucleus is also situated nearer the attached ends of the pyloric cells than is the case with the nucleus of the centro-acinal cells. There is a basement membrane outside the cells.

The whole mucous membrane containing the pyloric glands when measured along its folds, in hardened preparations, is only 2·1 centimetres in longitudinal extent.

According to Foster,[1] Klein,[2] Stirling,[3] and others, the epithelium covering the surface of the stomach is the same as that which lines the ducts of the various glands. On the other hand, Professor Rutherford has taught for some time that, in the Cat's stomach at any rate, this surface is lined by ordinary columnar cells similar to those of the intestine. In the Hedgehog these long columnar cells are very conspicuous, especially at the pyloric end, where they may even extend some little way into the ducts. They are of the usual type, larger than the mucigen-producing cells, exhibit a clear though narrow striated hem, a protoplasm with a fine network staining orange with benzopurpurine B, and a large oval nucleus placed near the centre of the cell (Pl. IV. fig. 4, *f*). It is no doubt through these cells that absorption takes place in the stomach.

The connective tissue of the mucous membrane is adenoid in type; an occasional solitary gland may be found in it. The muscularis mucosæ appears to be arranged in two instead of three layers, as in most other animals; it is continuous at the œsophageal end with that of that organ, and at the pyloric,

[1] *Text-book of Physiology*, London, 1890.
[2] *Atlas of Histology*, 1880. [3] *Text-book of Physiology.*

at intervals, with the inner muscular coat of the stomach, as well as with the muscularis mucosæ of the duodenum (Pl. V. fig. 4, *m m*).

The submucous coat consists of ordinary fibrous tissue, denser near the mucous, but looser near the muscular coat; it is not nearly so thick as either of the other coats, except in the folds, where it attains to a considerable thickness. The fibres are such as are found usually in ordinary connective tissue, imbedded in a matrix, but the cells, of which six kinds may be made out, require special attention:—

1. Ordinary plate-like connective tissue corpuscles, with a large oval nucleus, that stains conspicuously of a pale lilac colour with acid hæmatoxylin, the plate-like part of the cell hardly staining at all. These cells are by far the most numerous, and may often be seen clasping the fibres (Pl. IV. fig. 3, *a*).

2. A plate-like cell, slightly smaller than the above, with a conspicuous oval nucleus; the plate-like expansion is finely-granular in appearance, stains orange with benzo-purpurine B. They are far less numerous than the ordinary connective tissue corpuscles, but may sometimes be seen clasping the fibres (Pl. IV. fig. 3, *b*).

3. Plate-like cells, very few in number, smaller than the last, but like them faintly-granular, the plate-like expansion staining faintly with acid hæmatoxylin. The nucleus of these cells is smaller and more rounded than those of the other two (Pl. IV. fig. 3, *c*).

4. Plasma cells. Coarsely-granular corpuscles of irregular shape, with a small oval or rounded nucleus, staining of a faint blue colour with acid hæmatoxylin, and with a protoplasm thickly studded with large granules that stain deeply violet with the same dye; there are very few of these cells (Pl. IV. fig. 3, *d*).

5. Wandering cells. Small rounded cells, like white-blood corpuscles, with two or more nuclei, often bi-lobed; the cell substance stains deeply yellow with benzo-purpurine B (Pl. IV. fig. 3, *e*). In some cases these cells are very numerous, in others they only occur here and there.

6. In the neighbourhood of solitary glands, when these exist, both varieties of the small nucleated cells, characteristic of

lymph follicular tissue, may be seen, with their round nuclei deeply stained with acid hæmatoxylin.

Heidenhain[1] has described cells 1, 4, 5, and 6 as occurring in the connective tissue of the intestine, but does not mention 2 and 3.

THE MUSCULAR COAT consists of two layers of non-striped muscle, the inner of which is circular and thick, whilst the outer is oblique and thin. The inner coat is slightly thickened at the cardiac end to form a cardiac sphincter; but the sphincter action is here, no doubt, chiefly brought about by the greatly thickened muscularis mucosæ of the œsophagus. At the pyloric end, where the coat is very thick, the circularly-placed muscle-fibres are raised into a thick sphincter for the stomach (Pl. V. fig. 4, *p s*); they fuse more or less with the fibres of the outer coat, and are prolonged up, as a thin septum of muscle, through the submucous coat to the muscularis mucosæ (Pl. V. fig. 4, *m m*), with which they now and again become continuous. In this way both inner and outer coats participate in the formation of the pyloric sphincter. This projection has a straight wall-like surface towards the duodenum, but slopes down in a gentle curve on the stomach side.

During hibernation the whole organ stains less readily than in summer; this is most noticeable in the peripheral cells of the cardiac glands, which during activity have a very great affinity for acid anilins, but during the winter hardly stain at all, thereby appearing to have diminished in number; they are of smaller size and appear more granular. The cells lining the ducts are larger, more distended and clear, their contents stain more readily with acid hæmatoxylin, and their nuclei are pushed quite down to their attached ends (Pl. IV. fig. 4, *a b*). This deeper stain is probably produced by the accumulation of mucigen in the cells, owing to their sluggishness; in summer the mucigen, being more rapidly discharged, will not accumulate sufficiently to cause the cells to stain deeply. Many of the columnar cells of the general surface also appear to lose their clear hem, and become filled with mucigen during winter.

The surface of the stomach is covered by a thin layer of mucus, containing debris of epithelial cells, resulting from the

[1] *Pflüger's Archiv*, bd. xliii., Supplement.

natural death-rate of the tissue; in summer this layer of mucus is either very thin or absent altogether. I have never at any time seen the thick layer of mucus and other material mentioned by Valentin[1] as occurring commonly in the stomachs of Marmots during the first half of hibernation.

The most remarkable change in the stomach resulting from winter sleep in these animals is seen in the connective tissue both of the mucous and submucous coats. It consists in an extraordinary increase in the number of wandering cells, which may be seen lying in little linear groups of threes and fours between the fibres of the connective tissue. The whole tissue is crowded with them, giving it a peculiar appearance. In some situations near the larger blood-vessels these cells are so numerous and so closely packed together as to give rise to a mass of cells not unlike a solitary gland, but distinguishable from it by the larger size of the cells and the affinity which they exhibit for various acid aniline dyes. It is evident from their behaviour to staining agents, from their close relations with the blood-vessels, and from their histological characteristics, that these cells are merely migrated white-blood corpuscles. They are mostly round or oval in shape, usually exhibit two well-marked nuclei, each with a nucleolus, which stains deeply with acid hæmatoxylin.

That these cells are not identical with those of the lymph follicular tissue is evident from their larger size, and from the fact that the cells of lymph follicular tissue appear to be unaffected by acid anilins, in cases when they stain at all seeming to prefer the hæmatoxylin. Their nuclei, which are always conspicuous, filling as they do almost the whole cell, stain uniformly with hæmatoxylin or with iodine green, and other similar staining agents.

The wandering cells vary in size, and contain either a single nucleus with a nucleolus or a pair of nucleoli. The nucleus varies in shape, just as those of white-blood corpuscles do. There may be two or three or rarely more nuclei in each cell. Lastly, some appear to undergo division in the tissues.

These migrated cells may be met with in various situations:—(1) In the submucous coat, where they are very abundant,

[1] "Beiträge zur Kenntniss des Winterschlafes der Murmelthiere," *Moleschotts Untersuchungen*, bd. ii. p. 1.

usually placed in rows or groups, often in the immediate vicinity of blood-vessels. (2) In the mucous connective tissue beneath the closed ends of the cardiac glands, where they are numerous, but scattered singly (Pl. V. fig. 3, *e*). (Although the tissue between the glands is adenoid in character as in other mammals, that around and between their closed ends and the muscularis mucosæ is mucoid, consisting of a homogeneous matrix, in which are a few fibres and cells. This arrangement is seen all along the alimentary canal of the Hedgehog, wherein it differs from that of most other warm-blooded animals.) (3) In the adenoid tissue between the glands, some reaching up to the lower ends of the epithelial cells lining the surface of the organ. (4) In a few other localities, where they occur in small numbers, as in the lymph follicular tissue of solitary glands, &c.

This great migration of white-blood corpuscles from the blood-vessels occurs at the very commencement of hibernation, just at the time when the temperature of the animal is beginning to decrease. That they come from the blood rather than from the proliferation of connective tissue cells is borne out by the fact, that up to this period there are from 18,000 to 20,000 white corpuscles per cubic millimetre of blood, which number falls suddenly at the very commencement of winter sleep to 1000, 2000, or 3000 in the same volume; whereas the red corpuscles show, if anything, rather an increase in number.

Can any cause be assigned for such a curious phenomenon?

It has recently been pointed out by Bouchard[1] that if the temperature of a warm-blooded animal be artificially lowered, the micro-organisms normally present in the intestine pass through the lining epithelium and invade the blood. This being the case, it is admissible to suppose that each succeeding year hibernating animals would run a serious risk of infection during the initial stages of hibernation by the penetration of the bacteria in their alimentary canals through into the tissues. How long this risk may last would be difficult to say. Certainly during the first few days of the cooling process the risk would be very great, but after their temperature has fallen some considerable amount the risk would gradually become less and less,

[1] "Essai d'une théorie de l'infection," *Proceedings of the 10th Medical Congress*, Berlin, 1890.

for, as Professor M'Fadyean pointed out to me, it is probable that loss of heat by the animal would, when great, rather tend to prevent than to facilitate the passage of micro-organisms into the tissues. As soon as the bacteria begin to penetrate, chemotaxis will come into play, the leucocytes, rushing towards the banquet prepared for them, will leave the vessels, pass up to the attacked parts, and feed upon the invading organisms, as, from Metchnikoff's researches, they are known to do, thereby saving the animal from disease and possibly death. This seems to me to be a strong case in the support of the phagocyte as opposed to the humeral theory, as, were the body-juices sufficient to destroy the invading germs, no such sudden rush of microphages would probably occur at the exact period of invasion. The macrophages found in such large numbers in various organs, lymph glands for example, during the whole period of hibernation, would be sufficient agents for the removal of the dead, but that is not what we find; on the contrary, a sudden attack requires as surely a powerful and rapid defence, or the organism would succumb, and that defence is provided by the vast army of microphages that fly to defeat the enemy along the whole line of attack, which extends from the cardiac orifice of the stomach to the beginning of the rectum. And these localities are precisely where we find the wandering cells; for not only are they present at this period in the stomach, but occur in vast hordes all along the alimentary canal, and in the connective tissue round the bile and pancreatic ducts.

Further, this migration soon stops, and the blood ceases to become poorer in white corpuscles as the cooling process goes on—that is, as before pointed out, after the animal has become too much cooled to favour the invasion of its tissues by micro-organisms; and we find also, that soon after the cessation of the migration, the wandering cells begin to degenerate, giving with eosine and iodine green staining the typical degenerative reaction pointed out by Heidenhain. Eventually they break down altogether, and are slowly removed by macrophages. It comes also to be a question whether all the intestinal micro-organisms may not he destroyed at this time in this way—that is, whether or no the alimentary canals of hibernating animals are free from bacteria during the whole period of winter sleep, or whether

these organisms, cooled along with the body, remain very sluggish or quite inactive during the winter months. Their free development, if it occurs, would also, in the intestines, be materially retarded, no doubt, by the constant passage of bile, which is being continually secreted in small quantities during the whole period of winter sleep. This is a question the solution of which I have been unable as yet to attempt.

Steadily, though very slowly, the blood regains its normal number of colourless corpuscles, derived, no doubt, from the germinal centres of the lymph-glands, spleen, and other masses of lymph follicular tissue, and from the marrow, in which karyokenetic division may be seen slowly going on during the whole period of hibernation.

Another remarkable point is the almost total absence of plasma cells below the œsophagus; for, as already pointed out, they are few in summer, and almost entirely absent in winter; whereas, in the tongue especially, and in the œsophagus, they are very numerous. If they are overfed cells, as they would appear to be, one would have expected to find them more numerous in the stomach and intestines than elsewhere. In the mesentery, however, along the lacteals, they are very numerous.

Duodenum.—This part of the alimentary canal is of no very great extent in the Hedgehog; its submucous coat is devoid of Brunner's glands throughout its greater portion, these being confined to the immediate neighbourhood of the stomach. In longitudinal section their acini appear in a wedge-shaped mass, 8 millimetres in length, with its base at the pylorus, and its apex directed towards the small intestine. Brunner's glands are therefore arranged in the form of a truncated cone ensheathing the mucous membrane of the duodenum, and greatly increasing the thickness of its walls. The villi are smaller and less numerous, and Lieherkühn's follicles shorter than in the jejunum. The transition between the mucous membrane of the stomach and that of the duodenum is somewhat abrupt (Pl. V. fig. 4); the muscularis mucosæ arranged in a single layer only sends short processes downwards between Brunner's glands. The tissue between it and the closed ends of Lieherkühn's follicles is adenoid, not mucous, as in the stomach and intestines, this

mucous connective tissue only beginning some little distance beyond the last of Brunner's glands.

The submucous coat of the duodenum is very thick near the stomach (3·7 mm.), from which it is separated, except just under the muscularis mucosæ, by the pyloric sphincter; it gradually becomes thinner as we recede from that organ, being only 0·9 mm. in thickness at the narrow end of Brunner's glands, and gradually passing into that of the small intestine, becomes of the same size as in that organ, *i.e.*, 0·3 mm. in vertical extension.

The secreting cells of Brunner's glands very closely resemble those of the pyloric glands of the stomach, with which they are, according to Foster,[1] directly continuous. The cells stain pale blue with acid hæmatoxylin, the protoplasmic net-work orange yellow with benzo-purpurine, wherein they differ considerably from the central cells of the cardiac glands.

The inner muscular coat, the fibres of which are directly continuous with those of the pyloric sphincter, has a very irregular outline internally, as it sends prolongations up between the lobes of Brunner's glands, which are separated from it only by the basement membrane, causing it to vary in thickness considerably at short intervals, and to assume a wavy appearance on section (Pl. V. fig. 4, *c m*).

The outer layer is very thin, 0·02 mm. in thickness, its fibres are longitudinal in direction, and directly continuous with that part of the outer muscle layer of the stomach that does not enter into the formation of the pyloric sphincter (Pl. V. fig. 4, *l m*).

At the junction of the muscular coat of the duodenum with that of the stomach a triangular space is left, which extends quite round it, and contains an artery and a vein, embedded in a little loose connective tissue, and which have a circular course round the junction (Pl. V. fig. 4, *b v*). During hibernation the cells of Brunner's glands exhibit slight changes consequent upon their resting condition.

Small Intestine.—The intestine of the Hedgehog is a thin narrow tube about five feet in length, which, though of some thickness near the pylorus, that is, in the part which contains

[1] *Text-book of Physiology*, London, 1890.

Brunner's glands, quickly narrows down into a tube of uniform calibre to near the anus, where it again widens out a little. Except in the duodenum, the thickness of its walls rarely exceeds 2 millimetres; of this the mucous membrane contributes 1·1 mm., the submucous coat 0·1 mm. to 0·2 mm., and the muscular 0·25 mm. to 0·40 mm.

When the intestine is looked at from within, it presents a uniform granular appearance, there being no valvulæ conniventes in it; even in sections the mucous membrane is seen to be hardly convoluted at all, but presents numerous leaf-like villi, between which are numerous Lieberkühn's glands. The membrane is limited externally by a muscularis mucosæ, which is usually in a single layer.

THE VILLI.—The Villi are leaf-like (Klein[1]), having a broad flattened body supported on a long narrow stalk. The length of the villus varies in different specimens from 1·0 mm. to 1·8 mm., the average being about 1·5 mm.; the breadth in the widest part of the body is about 0·1 mm. The columnar cells covering the villus are of the ordinary type, and among them are numerous chalice cells with very long stalks, in which are situated wedge-shaped nuclei, that differ in staining properties from the nuclei of ordinary columnar cells, inasmuch as, in preparations treated with borax-carmine, hæmatoxylin, and eosine, they keep the red carmine stain, which is driven from the nuclei of other cells by the hæmatoxylin.

Between the attached ends of the cells are many replacement and a considerable number of wandering cells. The adenoid reticulum of the villus is of the usual type and arrangement; possibly it may resemble that of the lymph glands in consisting of connective tissue strands with clasping cells, rather than of a reticulum of branching cells; it produces a cribriform basement membrane for the epithelium, between the cells of which it sends delicate prolongations, to be lost in the cement substance (Watney, Klein,[2] and others).

In the centre of the villus, and reaching almost to its free extremity, is, as a rule, a single lacteal vessel, and not a rich plexus as described by M'William,[3] who, however, now believes

[1] *Atlas of Histology*, London 1880. [2] *Ibid.*
[3] *Transactions of British Association*, 1885, p. 1078.

this to have been an abnormal distribution, as he has never seen it since.

The lacteal is a wide lymphatic vessel situated in the centre of the villus, expanding at its free end into a rounded knob; it is lined by endothelial cells, the nuclei of which are often visible. If the tube be traced outwards it is seen to become extremely thin at the neck of the villus, and remain of this small size until, after a slightly sinuous course, it pierces obliquely the muscularis mucosæ, and opens into a wide lymphatic vessel in the submucous coat (Pl. VI. fig. 1). There appear to be no valves to prevent regurgitation taking place in this tube, but its obliquity, its tenuity, and the slanting direction it takes in passing through the muscularis mucosæ, are no doubt sufficient to prevent any backward flow, especially as contraction of the muscularis mucosæ, as a whole, would tend to close the tube at the same time as it shortens the villus; for, as Foster[1] points out, "when the muscular fibres contract they shorten the villus; in thus becoming shorter, the body of the villus becomes proportionally broader, since probably no great change of bulk in the reticulum takes place; in this broadening, the part to give way will be the lacteal vessel, which, thus made broader and larger, becomes filled with chyle; when the muscular fibres relax, the reticulum, the bars of which have been put on the stretch in a lateral direction, by elastic reaction brings back the villus to its former length, and the lacteal channel elongates, becomes narrower, and has its contents expelled." If this be true, then we can readily imagine how such an arrangement as that figured on Plate VI. fig. 1, would act. Every time the muscles contracted, the tube would be constricted below, preventing regurgitation; but dilated above, and at each relaxation, the opening below being again patent, would allow of the ready passage of the chyle into the submucous lymphatic.

Each villus possesses one main arteriole, that springs from the submucous coat, pierces the muscularis mucosæ, and breaks up into capillaries just above the narrow stalk. Lieberkühn's follicles are 0·3 mm. to 0·6 mm. in length; the epithelial cells lining them differ somewhat from those covering the villi; they

[1] *Text-book of Physiology*, London, 1890.

are shorter, narrower, clearer in appearance, and possess a much more oval nucleus, which is situated quite near their attached ends; the hem, though present, is very thin, and the protoplasmic network of the cells more open (Pl. IV. fig. 5, *b*). During the active condition both sorts of cells stain yellow with benzopurpurine B, but during the resting condition the difference between them is very conspicuous, the cells of the follicles acquiring only a faint yellow tint, whilst those of the villi stain deeply (Pl. IV. fig. 5). The cells covering the surface of the intestine between the open ends of Lieberkühn's glands resemble those covering the body of the villus, whilst those covering the stalk of the latter resemble those of Lieberkühn's crypts, and a transition which is somewhat gradual may be seen between them.

The tissue between the crypts of Lieberkühn is adenoid, and presents the same characters as that in the villi; it contains a few blood-vessels. The closed ends of the follicles are separated from the muscularis mucosæ by some considerable amount of tissue, which is not adenoid but mucoid in character, similar to that of the stomach already alluded to; it consists of a gelanimous matrix containing fibres and cells, the spindle-shaped nuclei of which might come to be mistaken for those of non-striped muscle, but the tissue is readily distinguished from muscle by its reaction with various dyes, as for example with picro-carmine it stains deeply pink like connective tissue, and not at all brownish, like muscle.

This tissue passes up some little distance between the closed ends of the follicles and into the stalks of the villi, where it soon merges into an adenoid network.

Muscularis mucosæ consists of a single layer of longitudinally placed plain muscle fibres. The submucous coat is 0·1 mm. to 0·3 mm. in thickness, and consists of a dense connective tissue, the fibres of which have a tendency to be vertically placed, many of them piercing the muscularis mucosæ along with the blood and lacteal vessels. Many connective tissue cells and some lymph corpuscles, resembling in every respect those described in the stomach, may be found in it.

There are numerous solitary glands in the intestines, both in the mucous and submucous coats. They consist in masses of

lymph corpuscles situated amongst the connective tissue, unsupported by adenoid reticulum. They present no capsule and no true lymph sinus round them, but have a diffuse margin, the corpuscles gradually diminishing in numbers towards the surface. If the development of such a gland in the submucous coat be studied, it is seen to spring from a few lymph corpuscles, which by repeated division push aside the strands of connective tissue amongst which they lie, thus producing a condensation of them into a pseudo capsule, which is wanting laterally; by further increase they press upon the muscularis mucosæ, and produce absorption of its muscle fibres. When the gland springs in the mucous membrane a similar result is obtained, only the adenoid tissue appears much more difficult to push out of the way, a few strands and cells always remaining among the lymph corpuscles, simulating an adenoid reticulum, and producing a pseudo capsule. Blood-vessels grow inwards into the gland, and their collapsed wall might possibly be mistaken for strands of a reticulum.

Their structure corresponds therefore with that of similar bodies in other mammals, as taught by Prof. Rutherford now for several years.

The muscular coat, 0·15 mm. to 0·4 mm., with an average of 0·3 mm. in thickness, consists of two layers of plain muscle fibres. The inner circular coat is 0·2 mm. in thickness, is the thicker of the two; it often exhibits near the submucous coat a semi-detached denser band, a few cells thick, separated from the general bulk by a little loose connective tissue. The outer longitudinal coat is about 0·1 mm. in thickness.

In transverse section the muscle cells have a slightly crenated outline, the projections being, however, very slight and almost imperceptible; they are also much fewer in number than those described in the cat by Barfurth.[1] Of the changes occurring during hibernation, the most obvious takes place in Lieberkühn's follicles, the cells of which become very clear, and stain hardly at all with benzo-pupurine B, whilst those of the villi stain deeply with this dye, and appear much more granular. The chalice cells seem to increase in number, possibly owing to more cells being filled with mucigen; for

[1] *Arch. f. Mikros. Anat.*, bd. 38, p. 38.

during winter their activity, like that of the body generally, will have decreased, the cells will discharge their contents less frequently, and hence the clear cells will appear more numerous, though in reality there probably is about the same number of those cells all through the year. This slowness of secretion in the mucin-forming cell is also demonstrated by the absence of mucin from the lumena of Lieberkühn's glands, and from the general surface of the villi, though Valentin[1] has said that the small intestine is lined by a skin of mucus during hibernation, of which I have failed to find a trace.

By far the most important change is the great migration of white-blood corpuscles into the tissues that occurs at the onset of hibernation, the significance of which has already been fully discussed.

Large Intestine.—The passage of the small into the large intestine appears to the unaided eye somewhat abrupt, as pointed out by M'William,[2] the hitherto smooth mucous surface suddenly presenting transverse folds that rapidly increase in size and number; they are the valvulæ conniventes of the colon, which is of scarcely larger calibre than the rest of the intestine; there is a complete absence of ileo-colic valve and cæcum. With the microscope the transition is seen to be less sudden, the muscularis mucosæ gradually becomes increased in thickness; elevations at first slight, increasing little by little in size, make their appearance, and by insensible stages pass into the valvulæ conniventes of the large intestine; they are at first covered by somewhat tall villi, between the attached ends of which are short Lieberkühn's follicles; these villi gradually shorten, and at last disappear, whilst the follicles elongate, and by insensible stages merge into those of the colon. Whilst these changes are going on in the villi, the mucous connective tissue between the closed ends of Lieberkühn's follicles and the muscularis mucosæ is becoming less and less visible, till in the large intestine it is reduced to a minimum, the closed ends of the follicles reaching down to and almost touching the muscularis mucosæ. Chalice cells also increase in number as the colon is approached. As

[1] *Moleschotts Untersuchungen*, passim.
[2] *Transactions of British Association*, 1885, p. 1078.

in the Cat, &c., the outer muscular layer forms a complete coat. The rectum requires no special notice.

I gladly take the present opportunity of thanking Professor Rutherford for his kindness and counsel, which have been unfailing, throughout this research.

Part II. The Liver.

The liver of the Hedgehog differs only slightly in structure from the usual type; the lobules are small, ill-defined, with well-marked radiating columns of cells, giving them the appearance of many-rayed stars. The cells are small, of the ordinary shape and appearance, and possess a well-marked envelope, which can be seen to the best advantage in preparation that exhibits slight shrinkage (Pl. VI. fig. 5, *s*); each cell contains either one or sometimes two well-marked nuclei, in which are one or more nucleoli. Those cells situated immediately under the capsule and around the blood-vessels, are peculiar in possessing one or two thick, short, blunt processes, by which they are firmly attached to the gelatinous connective tissue of the veins; in section they have a toothed appearance and are best seen round the large lumena of the branches of the hepatic vein, (Pl. VI. fig. 4). The bile ducts present the usual divisions and structure, the intermediate ducts being long and rather conspicuous as in the Rabbit and Guineapig (Klein[1]); there is no basement membrane between the lining epithelium and the subjacent connective tissue. No plasma cells are present in the organ.

During hibernation the cells of the liver present in the meshes of the intra-cellular network numerous golden-yellow granules, which in unstained preparations appear grouped into a broad pigmented band, running down the centre of a column of liver cells, the edges of the column appearing free from granules (Pl. VI. fig. 2). If stained sections be examined it will be seen that each column consists not of a single row of cells end to end, but of a mass of cells arranged round a minute channel, the bile capillary, and that the pigment is placed in that part of the cells nearest the channel, ready, it would seem, to be passed into it by their active secretion. Granules of this

[1] *Atlas of Histology*, London, 1880.

pigment are found scattered throughout the whole protoplasm, but are not numerous in that part of the cells turned towards the blood capillaries (Pl. VI. fig. 2).

The granules are insoluble in chromic salts, water, methylated spirit, absolute alcohol, ether, chloroform, and balsam, do not blacken with sulphide of ammonium or Barrett's reagent, and appear to give no spectrum with the micro-spectroscope; they therefore do not contain iron, though it is difficult not to associate them with blood pigment or bile pigment, or with both. A similar pigment, in which iron is however present, is found in the blood capillaries, scattered here and there in little masses. Quincke[1] says that the capillaries of the liver contain white-blood corpuscles with iron-holding granules of variable size in variable quantities, very numerous in old Marmots. The liver cells show micro-chemically no iron reaction. He further states that there is a great breaking down of red-blood corpuscles during hibernation, in the spleen, red marrow, and liver, and thinks that the iron is accumulated in these organs, to be again used in forming blood pigment on the awakening of the animals. He used sulphide of ammonium as a test for iron in the liver and elsewhere, and obtained a blackening of the granules in the capillaries. I repeated this, and can confirm his observation.

But besides these masses of pigment granules, there are large rounded or oval uninucleated cells, not unlike splenic cells, the protoplasm of which often contains granules of an iron-holding pigment; they are found in the large veins coming to the liver, and also in the lobular capillaries, but are not numerous. I believe them to be macrophages that have wandered into the blood-vessels of the liver, after absorbing the pigment of broken-down corpuscles (Pl. VI. fig. 5, *a*). They do not appear to be splenic cells, however, as in this animal these cells are of very small size.

It does not seem to me likely that this pigment is merely stored in the liver cells for future use, but that, owing to the sluggish state of the excretion, we see the pigment granules accumulating in the cells, in a way that does not occur during

[1] Ueber die Wärmeregulation beim Murmelthier, *Arch. für Exp. Pathol.*, 1882, vol. xv.

the active period. It is possible that the iron may be stored up for future use, or that it is excreted from the liver in combination, not with pigment, but with some other body, as normally occurs, which I think the more probable, as the liver cells never give the iron reaction with ammonium sulphide, &c., and that the liver does not at the resolution of hibernation perform the function of a blood-producing organ.

The liver therefore presents us during hibernation with a picture, as it were, of the changes undergone by blood-pigment carried into the blood-stream, the liver cells seizing upon the granules, depriving them of iron, and moving them towards the bile capillaries, into which they are passed as bile pigment.

Another change of minor importance may be observed in the liver during hibernation. Some cells appear to increase in size, followed by enlargement of their nuclei, which become distended, and ultimately almost fill the cells (Pl. VI. fig. 3); after a time the over-stretched nuclear network ruptures, the nucleolus disappears or becomes adherent to the side of the nuclear envelope, and the cell presents the appearance of a narrow band of granular protoplasm surrounding a thick-walled vacuole; finally the cell also ruptures and disappears. I believe this to be the normal mode of death and removal of liver cells, which, owing to its slowness during hibernation, becomes more conspicuous than during the summer.

EXPLANATION OF PLATES.

Plate IV.

All the figures in this plate, with the exception of fig. 2, are represented as double-stained with Ehrlich's acid hæmatoxylin and benzopurpurine B.

Fig. 1. Vertical section of conical or spinous papilla of tongue × 200. *a*, cells of anterior aspect of papilla; *b*, capillary blood-vessel; *c*, stratum corneum; *e*, cells of papilla containing eleidin granules; *f*, similar cells containing eleidin diffused through them; *g*, germinal part of stratum Malpighi; *h*, subepithelial connective tissue; *k*, keratinised cells of tip of papilla; *m*, stratum Malpighi; *p*, downward projection of germinal layer of stratum Malpighi, forming an epithelial papilla from which the spine springs; *s*, septum of keratinised cells.

Fig. 2. Transverse section of a striped muscle fibre of amphibian type, from the submucosa of the œsophagus. Ob. No. 7 × Oc. No. 3 Leitz. *f*, connective tissue surrounding fibre; *n*, nuclei; *o*, nucleolus; *p*, undifferentiated protoplasm; *s*, sarcolemma.

Fig. 3. Connective tissue corpuscles, from submucosa of stomach. Ob. $\frac{1}{10}$ imm. Beck. × Oc. No. 3 Hartnack. *a*, ordinary connective tissue corpuscle; *b*, finely-granular corpuscle, the protoplasm of which stains yellow with benzo-purpurine; *c*, finely-granular corpuscle, the protoplasm of which stains violet with hæmatoxylin; *d*, coarsely-granular corpuscle; *e*, wandering cells.

Fig. 4. Various appearances presented by columnar epithelial cells of mucous membrane of stomach. Ob. $\frac{1}{10}$ imm. Beck. × Oc. No. 3 Hartnack. *a*, cells lining ducts of cardiac gland, in a resting condition (from a hibernating animal); *b*, similar cells from ducts of pyloric glands during hibernation; *c*, cells lining ducts of cardiac glands after active secretion; *d*, the same cells as *c* during a period of temporary rest, the animal being active; *e*, the same cells after a still longer period of rest; *f*, columnar cells of ordinary type lining general surface of stomach; *g*, chalice cell from mucous membrane of duodenum.

Fig. 5. Columnar epithelial cells from intestine of a hibernating Hedgehog. Ob. $\frac{1}{10}$ imm. Beck. × Oc. No. 3 Hartnack. *a*, cells from surface of villus; *b*, cells lining Lieberkühn's follicles; *r*, small "replacement cell."

Plate V.

Fig. 1. Coarsely-granular cells of connective tissue of tongue. *a*, smallest cells of the kind observed—they contain granules like the larger ones; *b*, similar cells of slightly larger size and irregular shape; *c*, still larger cells; *d* and *e*, fully grown cells of various shapes; *f*, an old cell, in which a few granules only remain around the nucleus; this cell is taken from the mesentery of the same animal; *r*, red-blood corpuscles, drawn to scale.

Fig. 2. Two striped muscle fibres of tongue in transverse section. Ob. No. 7 and Oc. No. 3 Leitz. *a*, fibre composed of fine fibrils; *b*, fibre containing fibrils running in different directions; *c*, central core of *b*, consisting of longitudinally placed fibrils; *d*, circularly arranged fibrils; *e*, undifferentiated protoplasm; *f*, nuclei; *g*, sarcolemma; *h*, ordinary connective tissue.

Fig. 3. Vertical section of mucous membrane of stomach of hibernating Hedgehog, showing a number of microphages in the connective tissue becoming degenerated × 200. *b*, arteriole; *c*, nuclei of ordinary connective tissue cells; *e*, wandering cells (microphages showing granular degeneration); *g*, closed ends of cardiac glands; *l*, mass of lymph corpuscles; *m*, a microphage amongst them; *m.m*, muscularis mucosæ; *v*, vein.

Fig. 4. Vertical section of pyloro-duodenal junction, showing the whole extent of Brunner's glands. Ob. No. 1 and Oc. No. 1 Leitz. D, duodenum; S, stomach; *b*, lobules of Brunner's glands; *b.v*,

circular blood-vessel; *c.m*, circular muscular coat of duodenum, prolongations of which pass upwards between the lobules of Brunner's glands—it is continuous with the pyloric sphincter; *d*, ducts of Brunner's glands; *i.m*, inner muscular coat of stomach; *j*, junction of mucous membrane of stomach with that of duodenum; *l*, Lieberkühn's glands; *l.m*, longitudinal muscular coat of duodenum, continuous with outer coat of stomach; *m.m*, muscularis mucosæ; *n*, portions of muscularis mucosæ that pass between lobules of Brunner's glands; *o.m*, external muscular coat of stomach; *p*, pyloric glands; P.S, pyloric sphincter, into the formation of which both inner and outer muscular coats of the stomach enter—the sphincter is continuous at intervals with the muscularis mucosæ of the stomach; *s.m*, submucous coat; V, villi.

Plate VI.

Fig. 1. Vertical transverse section of small intestine. Ob. No. 7 and Oc. No. 3 Hartnack. *a*, arteriole; *b*, basement membrane of Lieberkühn's follicles; *f*, epithelium of closed ends of Lieberkühn's follicles; *g*, connective tissue, of somewhat gelatinous nature; *l*, lymphatic vessel in the submucosa; *l.a*, lacteal opening into *l*; *lu*, lumen of Lieberkühn's follicles; *m*, internal muscular coat of intestine; *m.m*, muscularis mucosæ; *s*, submucous coat.

Fig. 2. Portions of columns of liver cells from a hibernating animal, showing a band of pigment granules running down the centre of each column and surrounding the minute bile channel that exists between the cells. Ob. $\frac{1}{10}$ imm. Beck and Oc. No. 3 Hartnack. *b*, capillary bile channel; *c*, blood capillary; *g*, granules of iron-free pigment; *n*, nucleus of liver cell.

Fig. 3. Three cells of liver. *a*, normal cell; *b*, swollen cell, the nucleus of which has become much enlarged; *c*, cell about to break down and disappear, the nucleus of which has become vacuolated and lost its nucleolus—the nuclear envelope remains in a somewhat thickened condition.

Fig. 4. Wall of sublobular vein of liver, surrounded by liver cells, the blunt processes of which project into the connective tissue surrounding the vein. Ob. No. 7 and Oc. No. 3 Leitz. L, lumen of vein; *b*, capillary blood-vessel; *c*, connective tissue of vein; *e*, endothelial cells lining vein; *l*, liver cell of usual type; *n*, nucleus of connective tissue cell; *t*, toothed liver cells.

Fig. 5. Liver of hibernating Hedgehog, showing several macrophages full of granules of pigment in the blood capillaries; also granules of iron-free pigment in the liver cells. Ob. No. 7 and Oc. No. 3 Leitz. *a*, macrophages; *b*, their nuclei; *c*, blood capillary; *d*, bile capillary; *n*, nuclei of endothelial cells of blood capillaries; *p*, pigment of liver cell grouped round the bile channels; *s*, a liver cell the protoplasm of which is slightly shrunken, showing the cell envelope; *w*, colourless blood corpuscle.

THE INTEGUMENTARY GROOVES ON THE PALM OF THE HAND AND SOLE OF THE FOOT OF MAN AND THE ANTHROPOID APES.[1] By DAVID HEPBURN, M.D., C.M., F.R.S.E., *Senior Demonstrator of Anatomy, University of Edinburgh.* (With Plates.)

IN volume xxvi. of the *Jour. of Anat. and Phys.*, I gave an account of a series of dissections of the hands and feet of the Anthropoid Apes, with a view to establish their muscular homologies with the muscles of the corresponding parts in Man. Since then I have continued my observations in order to ascertain whether the integumentary folds on the flexor aspects of the hand and foot of Anthropoid Apes and of Man could be reduced to a common plan and mode of origin, seeing that the groups of muscles in them so closely correspond with each other. The material for this investigation in part consisted of a series of casts of hands and feet in the Anatomical Museum of the University of Edinburgh, and for permission to use these I have to thank Sir William Turner. I should state that attention of a general kind has already been directed to this subject by the late Professor Goodsir,[2] Sir William Turner,[3] and Dr Louis Robinson.[4]

THE HAND.

In studying this subject it will be advisable to commence with the hand, and at the outset to note the function of this organ in the Apes and in Man. In the former the hand serves the threefold function of *support*, *locomotion*, and *prehension*: of *support*, since all the Apes require the help of their hands, even when they assume the erect or semi-erect attitude; of *locomotion*, since Apes, when on the ground, constantly make frequent use of the knuckles of their hand in walking, and

[1] An abstract of this paper was read before the Anthropological Section of the British Association at its Edinburgh Meeting in August 1892.

[2] Goodsir's *Anatomical Memoirs*, edited by Turner, vol. i., Edinburgh, 1868.

[3] Turner *On Hands and Feet* (Health Lectures), Edinburgh 1884.

[4] Robinson, *Nineteenth Century*, May 1892.

while climbing, the hand is essential to progression; of *prehension*, since it is by this means that Apes grasp objects. Man, on the other hand, does not require his hand for the purposes of support or locomotion, save under exceptional circumstances, and he principally uses it as an organ of prehension. Again, the character of the prehension differs in Man and in the Apes; and the difference may be shortly expressed by saying that the hand of Man can grasp a *sphere*, while the hands of Apes can grasp a *cylinder*.[1]

It follows, therefore, that obvious differences should be found in the characters of the hands. In the Apes, the fingers are long and hook-like, the palm is narrow and elongated. The thumb of the Apes is always short in proportion to the length of the other digits, and in none of them does it extend beyond the metacarpo-phalangeal joint of the index finger. Again, in the Apes the web between the thumb and the index finger is smaller than in Man, and consequently there is more or less of a deep cleft in this position. At the same time the ball of the thumb and the ball of the little finger are feebly developed.

In Man, on the other hand, the palm has acquired considerable breadth in proportion to its length, and there is no disproportion between the length of the palm and the length of the fingers. The thumb has grown in length until it nearly reaches the articulation between the first and second phalanges of the index finger. The web has become well developed, and so the cleft between the thumb and index finger is to a great extent lost, while the thenar and hypothenar eminences are distinct features of the human palm.

Coming now to the muscles which produce the various movements of the hand, we find that these are arranged in certain definite groups, each group being capable of performing a distinct movement. These muscles are partly situated in relation to the dorsum of the hand and forearm, and partly in relation to the palm and front of the forearm. In a general way we may say that the dorsal muscles are the antagonists of the palmar set, but that the latter are slightly the more powerful, so that the natural position of the hand in the state of rest is

[1] See Goodsir's *Anatomical Memoirs*, vol. i. p. 239.

one in response to the action of the more powerful group. The different groups are:—

1. *Flexors.*—This group of muscles is situated in relation to the palmar aspect of the hand and forearm, and consists of muscles whose function is to *bend* the digits towards the palm. Each digit possesses two kinds, viz., *long* flexors and *short* flexors, the peculiarity of the latter being, that while the typical short flexor has two heads, the tendency is for certain heads to disappear, and so those which remain are usually described as palmar interosseous muscles, except in the case of the thumb and little finger.

2. *Extensors* are situated upon the dorsum of the hand and forearm. They straighten or extend the fingers, and thus they antagonise the flexors; but since the latter are the more powerful, the natural position of the fingers is slightly bent towards the palm.

3. *Lumbricales* are a small group of four muscles whose origin is in the palm, where they arise from the tendons of the deep flexors of the digits. Their insertion is into the extensor tendons on the dorsum of the fingers. Thus in their action they combine *extension* of the interphalangeal joints with *flexion* of the metacarpo-phalangeal articulation. This group of muscles is present to its full extent in the Apes as well as in Man.

4. *Abductors* are muscles whose function is to draw the digits away from the middle line of the hand, which is an imaginary line drawn from the wrist to the tip of the middle finger, so as to bisect the hand through the middle finger. They are chiefly situated between the metacarpal bones, and are hence named *dorsal interosseous muscles*, with the exception of those for the thumb and little finger, which lie on the outer and inner borders of the hand respectively, and are thus to be associated with dorsal muscles, although they have fallen somewhat towards the palm, and have thus rounded off the outer and inner borders of the palm.

5. *Adductors* (or *Contrahentes*) are muscles whose function it is to narrow or contract the palm by drawing the expanded fingers back towards the middle line of the hand. In the Gibbon this stratum is complete, and presents four muscles—for

the thumb, index, annularis, and minimus respectively. In the Chimpanzee, those for the thumb, annularis, and minimus were present, the two latter being very rudimentary. In the Orang, Gorilla, and Man, only the adductor for the thumb remains to represent this stratum. Nevertheless, the movement of adduction of the other digits is not lost, for it is performed by the palmar interosseous muscles, formerly referred to as the remnants of short flexor muscles.

6. *Opponentes* produce *opposition*, which is a movement whereby the thumb can be carried inwards across the palm, and its tip approximated to the tips of all the other digits. The little finger also possesses this movement to a limited extent, and in virtue of it the inner border of the hand can be raised so as to deepen the hollow of the palm, while at the same time the tip of the little finger is more readily brought in contact with the tip of the thumb.

From this summary it is quite clear that only three groups of muscles can leave their imprint upon the skin of the palm, viz., the flexor, adductor, and opposing muscles. As the result of flexion, the skin of the palm will be thrown into folds, whose direction will be indicated by grooves more or less transverse to the long axis of the hand. At the same time certain conditions may supervene to modify this transverse direction of the lines indicating flexion. The adductor or contracting muscles will produce narrowing of the palm, and hence the skin will be thrown into folds, indicated by grooves which run in the long axis of the hand; but since all the muscles of this group arise in relation to the middle line of the hand, it follows that the grooves will *radiate* more or less distinctly from a point in front of the wrist.

The movement of opposition will leave its traces in the form of *oblique lines* more or less distinct, according to the amount of the development of these muscles. These are usually blended with the former. In this way we may expect the palm to present three sets of lines or grooves—(1) Transverse, (2) Longitudinal or radiating, (3) Oblique.

Hand of Gibbon (Hylobates sp.?).—The palm is narrow in the region of the metacarpus, but expands slightly towards the digits, which are long and slender. The pollex is slender, but

short in comparison with the other digits. Each digit is provided with a nail.

The ball of the thumb and the ball of the little finger are of meagre development, and therefore the palm is very flat.

The thumb is much separated from the index digit by a deep cleft which extends backwards almost to the carpus, so that the web between these digits is very small. This cleft is prolonged backwards through the palm towards the wrist as a deep integumentary groove, which fades away close to the transverse line which indicates flexure of the radio-carpal joint.

The palmar aspect of each digit is crossed by transverse grooves, indicating the flexure between individual phalanges. At the level of the webs of the four inner digits the direction of the lines of flexion varies, being transverse to the long axis of the digit in the case of the medius, but somewhat oblique in the cases of the index, annularis, and minimus digits. This obliquity may be accounted for partly by reason of the metacarpal bones of these digits being shorter than the metacarpal bone of the medius, and partly by the action of the contrahentes muscles and palmar interossei which draw the digits towards the middle line during the movement of flexion.

Crossing the palm almost transversely at the level of the metacarpo-phalangeal joints, and extending from the inner to the outer border of the palm, there is a groove—the *anterior transverse line.* A short distance nearer to the wrist and also situated in the transverse direction, there is another groove—the *middle transverse line;* while yet another transverse groove—the *posterior transverse line*—may be seen in relation to the carpo-metacarpal set of articulations. This last commences at the inner border of the palm, but loses itself in the ball of the thumb. As already stated, a transverse line marks the position of flexion at the radio-carpal articulation.

An arrangement of grooves may also be seen running more or less in the long axis of the palm. These lines converge towards the wrist, and spread out in a *radiating* manner towards the digits. The number of these lines varies: their tendency is to run to the intervals between the digits. Usually those most distinct are found in the interval between the thumb and index finger, and in the *middle* of the palm, where it is nearly

longitudinal, and crosses the transverse furrows. These lines are produced by the folding of the skin as the palm is narrowed by the action of the contrahentes muscles, which take origin from an aponeurosis occupying the middle line of the palm at a deeper level. The distinctness of the line which lies in the cleft between pollex and index, points to the fact that the adductors of the thumb are more powerful than those of the other digits; and moreover, in the case of the thumb, the action of the opponens muscle would assist in intensifying this groove.

Thus in the Gibbon's hand we see in a simple form the series of furrows which the palm will show under the influence of flexor and adductor groups of muscles —transverse in the former, longitudinal or radiating in the latter. The small size of the opponens muscles, as well as of the other special muscles of the thumb and little finger, leaves the hand of the Gibbon much more fitted to grasp a cylinder, on which its digits would arrange themselves in a series of parallels, than to grasp a sphere, for which its hand would require to become cup-shaped.

Hand of Orang-utan.—The thumb is still small and feeble in proportion to the size and length of the other digits, and when laid alongside of the index finger it barely reaches as far as the head of the second metacarpal bone. The palm is more fully developed than in the Gibbon, and the thenar and hypothenar eminences have become somewhat more prominent; and in consequence the web between the thumb and index digit has filled up, so that there is no longer a deep interval between the metacarpal bones of these digits.

The grooves on the palmar surface arrange themselves as before into two groups, indicative of flexion and contraction or adduction. Thus lines indicative of flexion may be seen running transverse to the long axis of the various digits with the modification in the lines at the level of the webs of the fingers, whereby there is a certain amount of obliquity in the case of the index, annularis, and minimus, probably produced, as already noted, by the difference in the lengths of the metacarpal bones.

In the palm the *anterior*, *middle*, and *posterior* transverse lines are present as in the Gibbon. The series of *longitudinal* or radiating lines is well marked, especially those in relation to the middle line of the hand and the cleft between the thumb

and index finger. In regard to the latter, an important modification may be seen. By reason of the increase in the size of the intrinsic muscles of the thumb, the web, as already noted, has filled up, but at the same time the furrow produced by adduction and opposition has become doubled, and one part is pushed forwards so as to run out on the outer border of the palm, close to the outer end of the middle transverse line.

The main indication is therefore of a hand more fitted to grasp a cylinder than to surround a sphere.

Hand of Chimpanzee.—The thumb has undergone an increase in size, and is larger in proportion to the other digits than is the case in the Gibbon or Orang. The palm is well developed, and at the same time the thenar and hypothenar eminences are well defined, while the web between the thumb and index finger has very materially filled up.

The same series of furrows is again visible, although important modifications are present. The *lines of flexion*, so far as the digits are concerned, remain as before; but with regard to those on the palm, several variations must be noted. First, all three —anterior, middle, and posterior—have assumed a certain amount of obliquity. The *anterior* and *middle* are still parallel to each other, but their radial ends are pushed forwards, so that, instead of being transverse, they are distinctly oblique. Moreover, the ulnar end of the middle line barely reaches the inner border of the palm. The posterior transverse line has also become oblique, by reason of its ulnar end moving forwards in advance of the radial end; and in addition, its ulnar end no longer reaches the inner border of the palm. These modifications result from the increase in the size and importance of the muscles in the thenar and hypothenar eminences. Thus the obliquity of the posterior line, and the shortening of this line, as well as the middle line, are the result of the growth of the muscles of the hypothenar eminence, while the obliquity of the anterior and middle lines, as well as their forward movement, results from the increase in size of the adductor muscles of the thumb.

The lines of adduction, *i.e.*, the longitudinal and radiating lines, are well seen in this hand. Among them, the one which corresponds to adduction and opposition of the thumb, which, as

we have formerly seen, occupies the cleft between thumb and index, has now moved decidedly forwards, and runs out on the outer border of the hand close to the radial end of the middle line of flexion, a result which is likewise produced by the increase in the size and importance of the adductors of the thumb.

In this hand we have now clear indications that it is capable of more than merely grasping a cylinder, and from the disposition of the lines it is evident that the muscular mechanism has become sufficiently perfected to permit of the hand being spread over the surface of a sphere.

Hand of Gorilla.—The thumb is also well developed in proportion to the other digits, while the size of the thenar and hypothenar eminences is more remarkable than in any of the other Apes. The palm is likewise well developed. As in all the other Apes, the palmar furrows arrange themselves in two groups, indicating the general movements of flexion and adduction.

Among the lines of flexion, no change requires to be noted so far as the digits are concerned, but in the case of the palm, while we may still recognise the three original primary lines, further important variations are recognisable. Thus, the anterior and middle lines are even more oblique than in the Chimpanzee, while they are no longer parallel. The *anterior line,* instead of reaching the outer border of the palm, now fails to reach that point, and instead, it is deflected forwards to the root of the index finger. The *middle line* in its turn fails to reach the ulnar border of the palm, and on the radial side it is again considerably deflected forwards as it runs out on the outer border of the palm. The *posterior line* may still be traced, but it is no longer so definite. Among the lines which indicate adduction and opposition—*i.e.*, longitudinal and radiating—considerable modifications are visible. Their number is less numerous, and those which remain bear special reference to the middle line of the palm, the thumb, and little finger. The one associated with the thumb still commences close to the wrist, but it runs forwards with a wider curve than formerly, and in its progress to the outer border of the palm it blends for some distance with the radial end of the middle line of flexion. This result clearly follows the increase in the size of

the intrinsic muscles of the thumb. On the other hand, the increase in the size of the intrinsic muscles of the little finger has produced a furrow by which this mass of muscle is demarcated from the rest of the palm. From these markings it is evident that the hand of the Gorilla is better fitted for grasping a sphere than the hands of the other Apes, and the modification of the primary lines would seem to show that this is possible. As a matter of fact, in grasping a sphere the great part of the movement occurs in connection with the thumb, annularis, and minimus, and there is less movement at the heads of the metacarpals of index and medius, from which we may explain the alteration in the direction of the radial end of the anterior primary line of flexion.

The Human Hand.—In Man the hand is an organ whose grasping power is perfect, and which accommodates itself more easily to a sphere than a cylinder. Still, although considerably modified, the groups of muscles are the same as in the Apes, and consequently we are able to trace the series of modifications by which the integumentary furrows appear to deviate so widely from their arrangement in the Apes.

First, we observe that the lines of flexion on the palmar aspects of the digits are transverse to the long axis of the digit, except in the case of the furrows close to the web in the index, annularis, and minimus, which are oblique as in the Apes, and doubtless due to the variation in the length of the metacarpal bones and the action of the palmar interossei.

In the palm the anterior and middle lines of flexion remain, while the posterior one has vanished, owing to the increase in the size of the thenar and hypothenar eminences. The increase of the hypothenar mass has also obliterated the inner end of the middle line, so that it no longer reaches the inner border of the palm. The outer ends of these two lines have also become deflected forwards; and while the middle one still reaches the outer border of the palm, the anterior one either runs against the base of the index finger, or else runs into the web between index and medius.

The longitudinal or radiating lines of adduction and opposition still present their main features, in so far that they commence between the balls of thumb and little finger, just in front

of the wrist. Of these lines only two remain, and these lie, one in the middle of the palm, extending forwards to the middle digit, the other running forwards and outwards to reach the outer border of the palm, either alone, or by blending with the outer end of the middle line of flexion. There is thus no great amount of difference between the hand of Man and that of the Gorilla, so far as the furrows are concerned. The advantage lies with the hand of Man, by reason of the greater size of his thumb in proportion to the other digits, and in the ample development of the intrinsic muscles of his thumb and little finger, notably the muscles of opposition, in virtue of which these digits have been placed at a great advantage, both in respect of adduction and flexion, and consequently the movements of these digits have altered, and modified the simple arrangement which we see in the palm of the Gibbon.

THE FOOT.

Turning now to the consideration of the foot, it will be advisable, as in the hand, to examine the *function* of this organ in the Apes and in Man. In all, the foot serves the purpose of an organ of *support*, but it does so to a greater extent in Man than in the Apes, because whereas in the former it is practically the only organ of support, in the latter it shares this function with the hand. Similarly, it is an organ of *locomotion* in both instances, although almost to the exclusion of the hand in the case of Man, except under special circumstances. The most important difference, however, is found in its power of *prehension*. In Man this power remains to a considerable extent among the feet of savage races, and among those who, for special causes, have been under the necessity of training their feet as grasping instruments. Among the Apes, on the other hand, the power of prehension is more fully developed in their feet than in their hands, so much so that the foot in them is the better hand, and therefore they are well named *quadrumanous*.

So far as regards the power of prehension, the foot of Man may partially grasp a cylinder, according to the length and freedom of movement of the toes; but the foot of the Apes, by

reason of the position of the hallux, is well fitted to grasp a sphere, so that the hand and foot of Man have, in regard to function, changed places with the hand and foot of the Apes.

It is not necessary to rediscuss the groups of muscles in the foot, since they are homologous with those in the hand, except that in the foot there are no muscles of opposition.

Only two groups of muscles, therefore, can leave their imprint on the skin of the sole, viz., flexors and adductors; and, as in the case of the hand, these muscles produce folds in definite directions. Flexors which bend the digits towards the sole, produce furrows transverse to the long axis of the digits and the long axis of the sole; while adductors which narrow the width of the sole, produce furrows running longitudinally from heel to toes, with more or less of radiation.

A closer examination of the foot in Apes and Man will show how far this arrangement holds good, and how modifications from the type may be accounted for.

Foot of Gibbon.—The foot is long and narrow. The hallux is widely separated from the remaining digits, which are long and slender. The web between hallux and index is much fuller than in the hand of the same animal.

Lines of flexion run transversely to the long axis of the phalanges; similar lines corresponding to the webs between the toes have a certain obliquity, doubtless the result of the shortening of the metatarsal bones from the second to the fifth. On the sole, only one line indicating flexion is at all distinct. It corresponds to the metatarso-phalangeal joints of the four outer toes, and crosses the sole of the foot from inner border to outer. Instead of being distinctly transverse, it is somewhat oblique, no doubt also owing to the diminution in the length of the metatarsal bones from second to fifth. It should also be noted that the four outer phalanges are rotated inwards, so that their flexor aspects are directed slightly towards the hallux.

The heel is divided into two parts—an outer and an inner—by a groove which begins immediately inferior to the internal malleolus, and runs forwards in the middle of the sole. As this groove advances it divides into two parts, one of which gradually curves towards the cleft between the hallux and index, while the other becomes indefinite after running a little farther in the

middle of the foot. These lines represent the longitudinal or radiating lines of adduction. The division of the heel produces two eminences. The outer is associated with the os calcis and point of the heel; the inner corresponds to the abductor hallucis muscle, which is therefore in front of the heel and on the inner side of the sole.

Indefinite markings run across the sole from the outer border inwards and forwards, pointing to a certain amount of power to approximate the phalanges and the hallux, a result obtainable by the adductors of the hallux assisted by flexion and the rotated position of the other digits.

Foot of Orang-utan.—In this foot the hallux is short in proportion to the size of the foot and the length of the other digits. The cleft between the hallux and index is much less marked than in the Gibbon, and the hallux has the appearance of having moved forwards on the inner border of the foot. Hence the heel is not so markedly bifid as in the Gibbon, and thus in walking the heel and outer border of the sole are applied to the ground, while the inner border of the foot is considerably elevated above the ground. As a consequence, those parts most usually in contact with the ground are smoother and less furrowed than the rest of the sole. Still, the main features of the furrows remain distinct, and lines indicative of flexion and adduction may easily be traced.

Thus *lines of flexion* cross the plantar aspects of the toes in a direction transverse to their long axis, while on the sole itself similar lines may be seen. One of these runs from the inner to the outer border of the sole anterior to the web of the hallux. At its inner end this line is double. Moreover, the line is somewhat oblique, owing to the diminution in the length of the metatarsal bones from within outwards. Another imperfect and indefinite line of a similar nature is found in the region of the ball of the great toe, but it neither reaches the outer nor the inner borders of the foot.

The pad over the os calcis and the ball of the hallux are each well developed, but they are not separated by such a wide groove as in the Gibbon. Still, a well-marked groove commences on the inner border of the foot, behind the hallux, and running forwards; it takes its place among a number of

distinctly *radiating* lines whose main direction is forwards towards the digits. The best-marked of these is that which indicates adduction of the hallux. This groove runs out on the inner border of the foot close to the inner end of the anterior line of flexion, and by it the ball of the hallux is clearly mapped out from the remainder of the sole.

Foot of Chimpanzee.—The hallux in this foot is set almost at a right angle to the inner border of the foot. It is, moreover, the strongest of the digits, and nearly equal in length to any of the other digits. From its position, its grasping power must be very considerable. The heel is rounded, and not divided into two pads as in the Gibbon and Orang. The entire sole is capable of being applied to the ground.

Lines indicative of flexion and adduction still prevail. The former are transverse to the long axis of the digits, and this fact is particularly well seen in the case of the hallux. A flexion line corresponding to the metatarso-phalangeal joints of the four outer toes crosses the sole from the inner border to the outer with the same slight obliquity already noted in the Orang and Gibbon.

The lines of adduction appear in a simpler form, and their radiating character is to a great extent lost, while their longitudinal nature is strongly developed. They are represented by a deep groove, which commences close to the inner border of the foot, but within the sole, and just in front of the point of the heel. This line runs forwards towards the middle digit, sending one diverging line towards the fourth digit, and another to reach the inner border of the sole near the inner end of the line of flexion. The two diverging lines do not leave the main longitudinal line until well forward in the sole. The main line and the outer one both cross the line of flexion.

Foot of Gorilla.—In this we find the hallux the largest as well as the most powerful of the digits, and it is situated well forward on the inner border of the foot, so that, posterior to the great toe, the sole is broad and well developed, with the heel rounded and symmetrical, as in the human foot. The web between hallux and index is well filled, so that the hallux points more forwards than in the other Apes. Only the main lines indicating flexion and adduction now remain, since the sole can be so fully applied to the ground.

So far as the digits are concerned, the lines of flexion remain as in the other Apes, and they are very well marked on the great toe. In the sole the line of flexion persists in its somewhat oblique direction, but its outer end scarcely reaches the outer border of the sole, although its inner end reaches the inner border as formerly.

The lines of adduction are now reduced to a single groove, which commences in the middle of the sole some distance in front of the point of the heel. For some distance it runs in the direction of the second toe, towards which a faint and interrupted continuation of this line may be traced; but the main groove is deflected to the inner border of the sole, in the interval between hallux and index. There it comes into close contact with the inner end of the line of flexion, thereby producing an appearance very closely resembling that found in a hand.

The Foot of Man.—Applying the same method of examination to the human foot, we are struck with the fact that, in the adult, most of the folds have disappeared, being obliterated by the pressure on the sole, and the restriction of its various movements, when the foot becomes chiefly an organ of support. In order, therefore, to see the sole of the human foot in its primitive condition, we require to examine the foot of an infant before it has walked. Certain noteworthy features may be mentioned, *e.g.*, the hallux is the bulkiest and strongest of the digits, and although situated parallel to the index, it is as a rule longer than the index,[1] except among the lower races of mankind.

Besides, the interval between the hallux and index is greater than that between the other toes. Bearing in mind that the human foot possesses the mechanism for flexion and adduction, just as do the feet of the Apes, the lines which indicate these movements ought to be present, although in a condition modified by the position of the great toe, whose movements are thereby considerably restricted. The excellent tracings of infants' feet, illustrating an article by Dr Louis Robinson in a recent number of the *Nineteenth Century Magazine*,[2] bear out this statement.

[1] Flower, *Fashion in Deformity.* [2] *Nineteenth Century*, May 1892.

The lines of flexion, so far as the digits are concerned, are still transverse to their long axis, with the exception of the slight obliquity found in connection with the webs of the four outer digits. In the sole itself, *two* lines indicative of flexion at the metatarso-phalangeal joints are now evident. Of these, that which commences at the outer border of the foot and runs obliquely to the interval between hallux and index, is the corresponding line which has been traced through the series of Apes, and now appears in Man's foot. Its obliquity is, as hitherto, due to the gradual diminution in the length of the four outer metatarsal bones. A second line of flexion is present in the sole of Man's foot. It commences at the inner border of the foot, and runs almost transversely outwards to join or nearly join the former line. This corresponds to the metatarso-phalangeal joint of the hallux, and its presence within the sole is the result of the new position of the hallux in Man. In the Apes this line may be seen as one of those running transversely to the long axis of the hallux, but by reason of the position of this digit in these animals, it was traced from the inner border of the foot behind, to the web of the digit in front of the hallux. Sometimes a second line of flexion may be seen running across the sole of the foot.

The position of Man's digits, lying as they do, not only parallel to each other, but upon the same plane, has naturally greatly limited their power of adduction. Nevertheless, the line which indicates this movement is still present. It commences in the sole about its middle, and some distance in front of the heel. Running forwards, it is continued towards the interval between hallux and index, where it becomes blended with the lines of flexion already described in that position. Occasional short longitudinal lines may also be seen in the front part of the sole, and these remind us of the radiating series in the family of Apes.

While this is the arrangement of the grooves in a foot which has not been used for walking, it will be seen that they undergo great modifications in such a foot as that of the Australian Aboriginal. In it nearly all the primitive lines have been smoothed out, and they are replaced by others dependent on the movements of the foot. Thus we see a transverse flexion

line behind the ball of the hallux, and an indefinite longitudinal adduction line. In the foot of civilised Man a similar process of modified lines has resulted from wearing boots, and consequently very few lines appear, but those which may be present conform to the general plan.

From what has been said, it is clear that both hand and foot bear external evidence of the close muscular homologies which exist between them; and as these homologies are almost identical throughout the series of Apes and Man, so are the lines which the groups of muscles produce in the skin.

Modifications in the size of muscles and in the disposition of the digits are followed by variations in the direction of the lines, but the main facts remain constant; and while Man's hand has developed into a better grasping organ than that of the Ape, and his foot into a better organ of support, still they both retain evidence that they are both constructed upon the same plan, and that they are capable of performing the same kind of movements, subject to certain modifications and improvments fitted to the necessities of each case.

EXPLANATION OF PLATES VII., VIII., IX.

Fig. 1. Hand of Gibbon.
„ 2. „ Orang-utan.
„ 3. „ Chimpanzee.
„ 4. „ Gorilla.
„ 5. „ Man.
„ 6. Foot of Gibbon.
„ 7. „ Orang-utan.
„ 8. „ Chimpanzee.
„ 9. „ Gorilla.
„ 10. „ New-born Infant.
„ 11. „ Australian Aboriginal. From a cast presented by Professor Anderson Stuart.

Figs. 1, 2, 6, 7 are from casts prepared by Professor D. J. Cunningham.

Fig. 1.

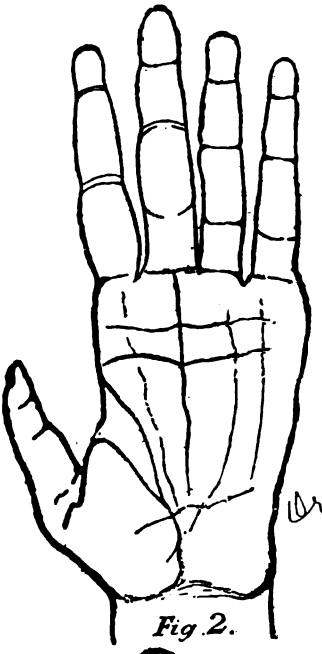

Fig 2.



Fig. 3.

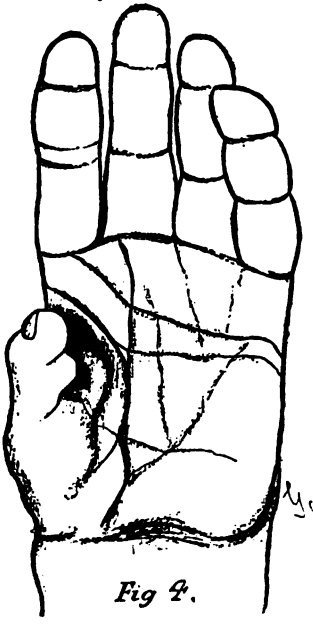

Fig 4.

D. HEPBURN, M.D. del

PLATE VII.



Fig. 5.



Fig. 6.

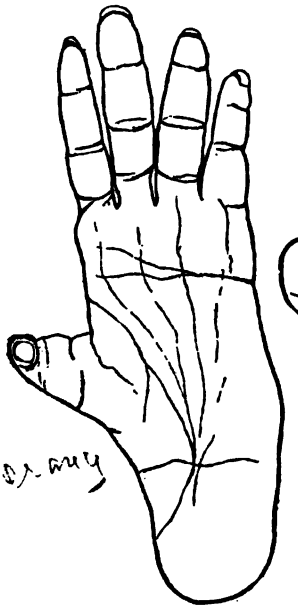

Fig. 7.

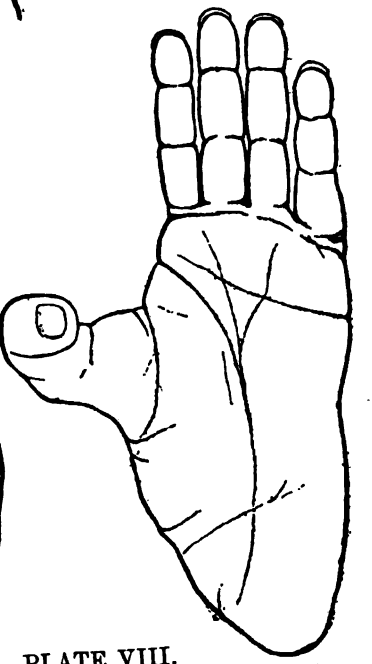

Fig. 8.

PLATE VIII.

D. HEPBURN, M.D. del

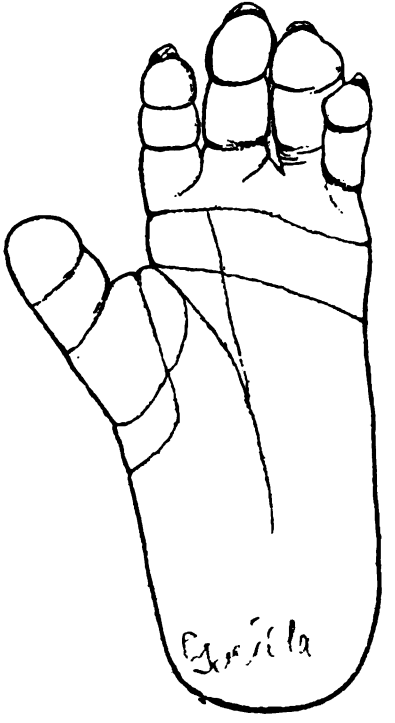

Fig 9.

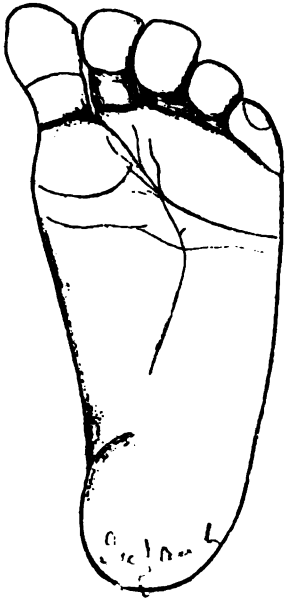

Fig. 10.

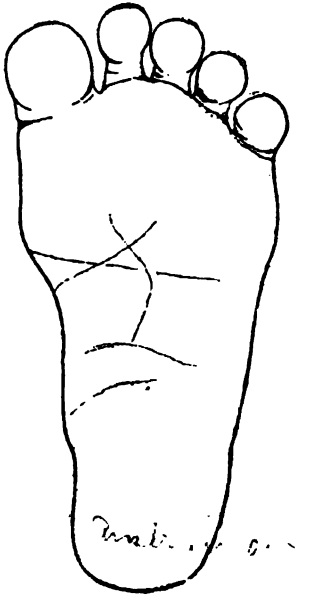

Fig II.

D. HEPBURN. M.D. del.

PLATE IX.

ON THE ARTICULAR PROCESSES OF THE VERTEBRÆ IN THE GORILLA COMPARED WITH THOSE IN MAN, AND ON COSTO-VERTEBRAL VARIATION IN THE GORILLA.

By JOHN STRUTHERS, M.D., LL.D., *Emeritus-Professor of Anatomy, Aberdeen University.*

(Read before the Anthropological Section of the British Association for the Advancement of Science, at Edinburgh, August 8, 1892.)

THE following observations are founded on the study of the skeletons of a male and a female gorilla contained in the Anatomical Museum I formed for Aberdeen University when professor there, and on notes made of other gorilla skeletons in various museums.

The skeletons to be referred to, under the subjoined Nos., are in the following museums, noted by me at the dates given.

No. 1.	Paris.	Jardin des Plantes, 1869.	Male, adult or old.
2.	„	„ „	Female, adult.
3.	London.	British Museum, 1869.	Male.
4.	„	Royal College of Surgeons, 1881.	Male, adult.
5.	„	„ „	Male, adult; bones loose.
6.	„	„ „	Female, adult.
7.	„	„ „	Young.
8.	„	Anthropological Institute, „	Male, adult.
9.	„	University College Museum, „	Male, adult.
10.	Vienna.	Public Museum, 1872.	Male, adult.
11.	Basel.	Public Museum, „	Male, adult.
12.	Louvain, 1871.	Male, nearly adult.	
13.	Montreal.	Macgill University, 1884.	Female, adult.
14.	Harvard University, U.S., 1884.	Male, adult or older.	
15.	Glasgow.	University Museum, 1874.	Female, scarcely mature.
16.	Edinburgh.	Museum of Science and Art, 1874.	Male, adult.
17.	„	University Anatomical Museum, 1892.	Male, old.

18.[1] Aberdeen University Anatomical Museum. Male, adult.
19.[1] „ „ Female, old.
20.[2] A Male, adult or older, 1882. Bones loose.

The adult state is inferred from the union of the epiphyses and the condition of the crest of the ilium. Whether adult or old is inferred as probable from the wearing of the teeth.

(A) Costo-Vertebral Variation.

Case in which the ribs are placed a vertebra lower than usual. No. 19 of the list. Vertebræ, cervical 8, costal 13, lumbar 3. The seventh cervical vertebra has the usual characters of a sixth, a very prominent anterior transverse process and a large rounded foramen. The eighth vertebra has the usual characters of a seventh, the foramen bounded in front by a narrow bar of bone. This is seen on the left side; on the right side this part of the vertebra is broken off.

Contrary to the remark of Owen (p. 96, *loc. cit. infra*) I find the "perforation" in the transverse process of the seventh vertebra to be generally present in the gorilla. It is a slender bar of bone about the thickness of a pin and liable to be broken. In the male gorilla shown to the Section (No. 18 of the list), this bar is entire on the right side; imperfect on the left side, apparently not broken but as if it had been completed by ligament.

The head of the first rib in both of these gorillæ (Nos. 19 and 18) is intervertebral in position, but connected mainly with the vertebra below, as usual in the gorilla and in quadrupeds, and as occasionally seen in man. In this female gorilla (No. 19) the thirteen ribs are well formed, the last is 6 to 7 inches in length and comes close to the iliac crest. The dorsal type of articular process begins abruptly a vertebra lower than usual. The

[1] These two skeletons were exhibited to the Section, kindly lent to me for that purpose by my successor in Aberdeen University, Professor Reid.

[2] I am not aware as to the museum in which this skeleton, submitted to me in 1882, has found a home. It may be identified thus: There is a recent bullet-hole about the middle of the left iliac crest, breaking the line of the crest; and near the sacral end of the right iliac crest, about half an inch below the crest, there is an old bullet-hole.

lumbar articular processes do not approximate till the sacro-lumbar articulation is arrived at. The last lumbar vertebra (24th vertebra) is not ossified to the sacrum. The sacro-iliac articulation is extensively anchylosed on the left side; behind, at its lowest 1½ inches; in front, for ¾ inch at both its lower and upper part. On the right side the joint is open.

Among numerous cases of costal variation in man I have not met with one similar to the above case in the gorilla, in which the whole thorax is placed a vertebra lower than usual. But, in contrast with it, I may refer to a case I have recorded (*This Journal*, 1874, "On Variations of the Vertebræ and Ribs in Man," Case 9, p. 72) in which the thorax was placed a vertebra higher than usual, giving the vertebræ, C6, D12, L6.

Increase of the Number of Ribs in the Gorilla. In three of these twenty gorillæ 14 ribs are present, and the additional rib in each of them is below. In one (No. 11 in the list) the additional rib is about 7 inches in length on both sides. In one (No. 15) the rib on the right side is about 7 inches in length, that of the left side was not present, apparently lost. In the third (No. 7, young) the rib is about 1½ inches in length. In the two first of these cases the additional rib rested on the body of the vertebra; in No. 11 there seemed to be also a costo-transverse articulation; in the third case (No. 7) the rib is articulated on a short transverse process. In neither of these three cases is the last lumbar vertebra (24th vertebra) ossified to the sacrum. Only one of them, however, was adult.

Contrasting these costal variations in the gorilla with those in man, the proportion of three cases of lumbar rib in twenty gorillæ is large, and in two of them the additional rib was long. In man the tendency rather is to diminution in size of the 12th rib, a condition which I have not seen in the 13th (the lowest normal rib) of the gorilla. The occurrence of a cervical rib, at least in a stunted form, is, in my experience, more frequent in man than that of a lumbar rib, but in none of these twenty gorillæ was there a cervical rib. If a conclusion may be drawn from so limited a number of gorillæ skeletons as twenty, it would seem that the tendency in the thorax of the gorilla is to extend downwards, either by size or number of ribs, while the tendency of the human thorax is rather to diminish below; these tenden-

cies being in accordance with the little freedom of movement of the lumbar region in the gorilla and the great freedom of movement of that region in man.

(B) The Articular Processes.

The study of the direction of the articular processes in the several regions, usually regarded as a rather dry part of human anatomy, becomes interesting on taking a wider survey. The fundamental type is seen throughout the vertebral column in reptiles and birds. The anterior pair form a trough, the posterior pair a wedge fitting into the trough; a "zygantrum" and a "zygosphene," using these convenient terms in a wider sense than that in which they are applied by Owen to the complex fitting of the ophidian vertebræ. In mammals the early type is retained in the caudal and lumbar regions and is departed from when, more or less, the thoracic region is reached, simply by rotation outwards of the processes. It is thus seen that in our human anatomy the lumbar vertebræ, not the dorsal, should be taken as the type in respect to articular processes, and that in noticing the change we should go upwards, not downwards, along the column.

The change from the lumbar type indicates adaptation to different conditions of movement. The dorsal type of process allows of greater variety of movement, flexion and extension, lateral movement, and rotation, while the lumbar type does not allow of rotation and allows of less lateral movement than the dorsal type does. It becomes of interest, therefore, to notice the locality of the change. While this is generally determined by the ribs, there are among mammals some marked exceptions (noticed in *This Journal*, 1874, p. 59), adaptations doubtless to exceptional locomotion; but the lumbar type is generally continued upon several, from one, or more usually from two, to as many even as five of the dorsal vertebræ, these generally corresponding to where the ribs are small or less firmly articulated, and the change may take place suddenly or it may be effected gradually over two or three spaces. In man the change occurs suddenly between the last two ribs, the lower articular processes of the 12th dorsal vertebra being the last to

retain the lumbar type. In the gorilla I find the change to the dorsal type to occur usually between the 12th and 13th dorsal vertebræ, that is, a vertebra lower than in man, but still, as in man, between the last two ribs. This earlier change to the dorsal type of articular process in the gorilla may fairly be inferred to be determined by the additional rib possessed by the gorilla.[1]

Cases of variation of the locality in which the articular processes change in the Gorilla. The conclusion that the usual place of commencement of the dorsal type in the gorilla is between the 12th and 13th dorsal vertebræ is founded on notes taken of this character in 13 of these gorillæ. In 9 of these it was strictly so. Of the four cases in which some change to the dorsal type occurs between the 13th and 14th dorso-lumbar vertebræ, in one it was but slight; it one (No. 13) there was a-symmetry of the processes; the remaining two (Nos. 18 and 19) are now exhibited to the Section. No. 19 is my case of the thorax placed a vertebra lower than usual, so that the change to the dorsal type of articular process, although occurring a vertebra lower than usual, is still at between the last two ribs. Of No. 11 (case of the occurrence of 14 ribs) it is noted that the dorsal type had begun between the 14th and 15th dorso-lumbar vertebræ.

In making the observation on the articulated skeleton, the processes should be viewed from the side as well as from behind. If viewed from behind only, the more inward position and the projection of the metapophysis of the 13th dorsal vertebra, con-

[1] Sir Richard Owen, in his masterly memoirs on the osteology of the anthropoid apes (*Trans. Zoo. Soc.*, vols. i. to v., 1835–1862), notices the articular processes in the orang, chimpanzee, gorilla, and in man (vol. iv., pp. 101, 108, 106), to the effect that (going downwards) modification takes place in the orang, as in man, on the lower processes of the 12th dorsal vertebra, but not on the corresponding vertebra of the gorilla and chimpanzee; that a change of position takes place on the lower processes of the 13th in the chimpanzee similar to that on the 12th of man; and that, in the gorilla, the upper processes of the 14th (1st lumbar) become more convex and oblique in position. From these passing notices of the articular processes I infer that, in the gorilla or gorillæ from which he described, he found the change from the lumbar to the dorsal type of articular process to occur in the gorilla between the 12th and 13th dorsal vertebræ, the locality which I have stated to be the usual one. But Owen's notice of the upper processes of the 14th in the gorilla leaves it somewhat uncertain whether he was not describing from a variety similar to that of No. 18 of my list, to be noted below.

cealing the true articular process behind, gives the appearance of a zygantrum and as if the lumbar type was continued a vertebra higher than it really is. This source of possible error is well illustrated in the male skeleton (No. 18) now before the Section. The view merely from behind might lead to the conclusion that the lumbar type is continued to between the 14th and 13th and even between the 13th and 12th vertebræ. But on separating the vertebræ the processes between the 13th and 14th are seen in this gorilla, as above referred to, to be mainly of the dorsal type. They differ from those of the vertebræ below in the upper processes looking backwards and being very convex from side to side, instead of being flat and a little concave, and differ from those of the dorsal vertebræ in being narrow and more elongated vertically, as well as more convex transversely. The metapophysis of the 14th quite conceals the articular process behind, coming so close in to the vertebra above that there is, on the right side, a small articular facet on the inner aspect of the metapophysis, distinct from the articular process, this facet articulating with a small facet on the outer side of the lower articular process of the vertebra above. Merely a view from behind, in the articulated skeleton, would be sure to lead to the error of concluding that the articular processes here, between the 13th and 14th dorso-lumbar vertebræ, are of the true lumbar type, and the same might be thought of those between the 12th and 13th although they are purely of the dorsal type.

Variation in the locality of change to the dorsal type of articular process occurs also occasionally in man. I have given the particulars of ten such cases (*This Journal*, 1874, pp. 57 to 59), to which only a general reference need be made here in relation to the above cases in the gorilla. In five of them the change to the dorsal type takes place a vertebra higher than usual. In three of these the 12th rib is imperfectly formed, and in two the processes were not symmetrical. In a sixth case the processes, between the 12th dorsal and 1st lumbar, are exactly intermediate between the two types. In the remaining four cases the dorsal type begins a vertebra lower than usual. In two of these there are 13 ribs; in one the processes are only mainly dorsal; and in the fourth, a robust male skeleton free

from deformity, the processes at that space (between the 12th dorsal and 1st lumbar) are quite a-symmetrical, dorsal on one side, lumbar on the other side, those of the vertebræ above and below being quite symmetrical. These cases, so far, seem to show that, in man, with imperfect 12th rib there is a tendency not to begin the dorsal type of articular process till a vertebra higher than usual, and that when a 13th rib is present the tendency is to begin the dorsal type a vertebra lower than usual. The occasional a-symmetry is interesting in its effect on the movements possible. In observing the place of change of these processes in articulated skeletons both sides should be looked to.

Approximation of the lumbar articular processes, downwards, in the Gorilla. When the lumbar region of the gorilla and that of man are viewed together from behind, the contrast at the articular processes is striking. In man the base, in the gorilla the apex, of the pyramid is below. This in man is in adaptation to the broad sacrum and the easy erect posture. A further contrast, accompanying the narrowing zygosphene in the gorilla, is the lessening slope of its sides. In man, the upper articular processes of the last lumbar vertebra and those of the sacrum face backwards as much as inwards, while in the lumbar vertebræ above the 5th the inward direction of these processes is the chief one, sloping a little more as we go downwards. In the gorilla it is the reverse. The upper processes in man are also markedly concave; in the gorilla they are nearly flat, with very little concavity till the lowest is reached.

The approximation and less inclination of the lumbar processes in the gorilla is noticed by Owen (*loc. cit.*, vol. iv. pp. 104, 105). I find, however, that this approximation is not a constant character in the gorilla. These two gorillæ (Nos. 18 and 19) present the extremes of the variation. In the female (No. 19) there is no approximation till the sacro-lumbar articulation is reached. The greatest breadth of the zygosphene on the four lumbar vertebræ respectively, from above downwards, is 11, 11, 12, and 10 lines. In the male (No. 18) the measurements at the corresponding parts are 19, 18, 15, 13 lines. In the only other female in which this observation was taken (No. 6) there is the same absence of approximation till the sacro-lumbar articulation is reached; the zygosphenes of the

three vertebræ above the lowest are of equal breadth, that of the one immediately above the lowest being, indeed, as in No. 19, slightly broader than those of the two above it. Among the seven males in which the observation was taken there was much variation, except that the approximation is always marked at the lumbo-sacral processes. It may begin from the 14th (1st lumbar, the 14th of the 17 dorso-lumbar vertebræ); or from the 15th; or not till from the 16th; and in one instance (No. 16 in the list) there is no approximation till the lumbo-sacral processes are reached.

In man, the widening between the lumbar articular processes begins generally on the 3rd; is marked on the 4th by an increase of about ¼ inch; and at the lumbo-sacral processes the increase may be as much as ¼ to ½ inch.

Ossific union of the last lumbar vertebra to the sacrum in the Gorilla. This subject belongs to a subsequent communication, but what I have found may meanwhile be shortly noted here. From the observations made by Owen before many gorilla skeletons had been obtained (1835–1862) the impression appears to exist that, in at least old males, the last lumbar vertebra (24th vertebra) usually becomes ossified to the sacrum in the gorilla. Putting aside the three in the list that were either young or not quite mature, bony union of the vertebra to the sacrum had taken place in 8, 7 males (Nos. 1, 3, 5, 9, 10, 16, 20) and one female (No. 6). Bony union had not taken place in 9, of which 6 were males (Nos. 4, 8, 11, 14, 17, 18) and 3 females (Nos. 2, 13, 19). So far as these numbers afford a basis for inference, this synostosis would seem to occur about as often as not in the male, and not to occur often in the female. It is not possible to distinguish exactly between adult and old. In this old female (No. 19) the sacro-iliac joint is, as above noted, extensively synostosed on the left side, but the 24th vertebra is free. Of the two males in the Edinburgh museums, the vertebra is free in the one considered to be "old" (No. 17), while in the one considered to be "adult" (No. 16) it is extensively ossified to the sacrum, behind as well as laterally.

EDINBURGH, *August* 1892.

EXTREME ANOMALY OF THE HEART AND GREAT VESSELS.

By AMBROSE BIRMINGHAM, M.D., *Professor of Anatomy, Catholic University, Ireland.*

(Read to the Anatomical Society, August 2, 1892.)

FOR the specimen, the description of which follows, I am indebted to my friend Dr Joseph O'Carroll, who had the case under observation for three years previous to death. Dr O'Carroll supplies the following history:—

J. H., female, aged 20 years (occupation, dealer in fish), like the other members of her family, was of small medium stature; had long but clubbed fingers; was cyanotic in appearance. On examination she presented a loud, harsh, systolic murmur, audible from the 2nd *right* intercostal space downwards for 2 inches below *right* nipple, and into the *right* axilla. The second sound was loud, sharp, and accompanied by a beat in the 2nd right interspace, easily felt by the hand. Suffered from metrorrhagia when 15; got well after a time. Suffered from occasional attacks of dyspnœa, which passed away after rest in bed. At 18 got a new attack of metrorrhagia; brought to hospital in an exhausted condition; treated by curetting and iodine injections into the uterus; four days later got right hemiplegia. Imperfect separation of cavities of heart diagnosed. Recovered from hemiplegia in a few months. Returned a year later, suffering from grave dyspnœa and pain in the left side; died in a month. *Post-mortem*:—Abdominal organs normal; pelvic viscera smaller than usual; lungs tubercular, especially left. Heart and great vessels as described below.

I received the heart and lungs, with portions of the trachea, aorta, and œsophagus.

At first sight the case seemed to be one of simple dextrocardia, or transposition of the parts of the heart, without any change in the condition of the viscera generally, for, as pointed out above in the post-mortem examination, the lungs and abdominal viscera were anatomically normal, the chief anomalies being confined to the heart and great vessels. They may be here summarised; they are described at length below.

The apex of the heart is directed to the right; the whole organ is twisted on its long axis, the left margin coming forward so that the anterior surface is formed by the two ven-

tricles in almost equal proportions. The aorta comes off from the right ventricle in the position normally occupied by the pulmonary artery; it curves over the root of the right lung, forming a right aortic arch; the pulmonary artery arises from the same ventricle, its orifice being placed midway between base and apex among the columnæ carneæ, and its lumen being reduced to a diameter of nearly quarter of an inch. There is a large aperture, admitting a thumb, in the upper and anterior part of the ventricular septum; through this the two ventricles communicate freely. No artery arises from the left ventricle. There is only a trace of the septum of the auricles; the two cavities communicate with perfect freedom; the two auricular appendices lie side by side to the left of the base of the heart, and do not embrace the arterial trunks. The left superior cava is persistent and pervious.

On looking at the heart (fig. 1), it is seen at once that the apex is directed to the right; and further, that it is formed by the tip of the right ventricle and the interventricular septum. The base is directed upwards and to the left. The left margin approaches the horizontal in position, and is apparently the margo-acutus, being much sharper than the right. The anterior interventricular groove is somewhat nearer to the left margin than to the right, while the posterior groove divides the posterior surface almost equally, lying perhaps a little nearer to the right than to the left margin. From the front, the right ventricle is the more evident; from behind, nearly equal portions of both are seen.

At the base on the right side, where the auricular appendix is normally found, no trace of an appendix can be seen; while on the left side there are apparently two appendices, placed side by side, to the left of the arterial trunks (R.A.A and L.A.A).

The aorta (A) comes off from the heart at the position usually occupied by the pulmonary artery, namely, it springs from the upper angle of the base of that ventricle which lies to the right of the interventricular groove. From its origin it arches backwards over the root of the right lung, and runs down on the right side of the vertebral column, constituting a right aortic arch. Its concavity is connected by an impervious ductus arteriosus with the pulmonary artery, to the right of the

bifurcation of that trunk. The right recurrent nerve passes backwards on the outer side of the ductus arteriosus, and, winding round the arch of the aorta, passes up to the larynx. From this it would seem that the ventricle which lies to the right of the interventricular groove is the representative of the normal left ventricle. Whether this conclusion would be correct or the reverse will be seen later.

The auricular portion of the heart is extremely irregular. On the right side there are two cavæ, inferior and superior,

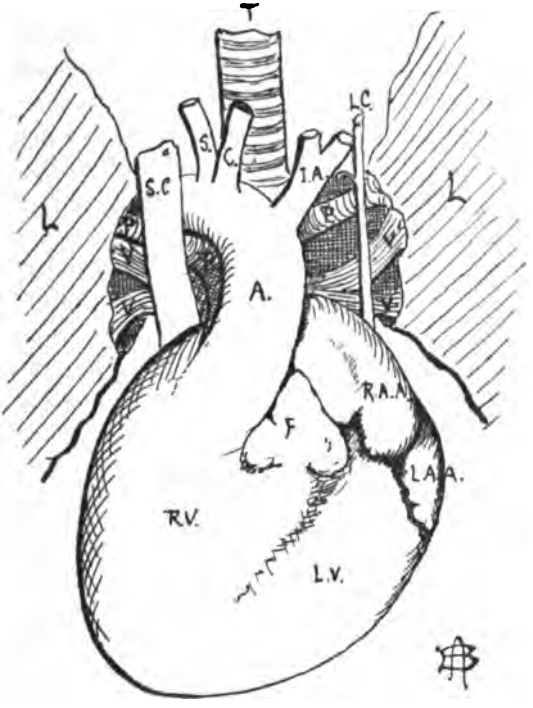

FIG. 1.—*R. V*, Right ventricle. *L. V*, Left ventricle. *R.A.A*, Right auricular appendix. *L.A.A*, Left auricular appendix. *F*, Mass of fat. *A*, Aorta. *I.A*, Left innominate artery. *C*, Right carotid. *S*, Right subclavian. *P*, Pulmonary artery and its divisions. *S.C*, Right superior cava. *L.C*, Left superior cava. *V*, Pulmonary veins. *T*, Trachea. *L*, Lungs. (*From a Photograph.*)

running normal courses; the latter receives the arch of the azygos major veins. These two cavæ open—the one below, the other above—into a cavity which occupies the position normally

occupied by the atrium of the right auricle, but here no more of the auricle is represented, there being on this side no trace of an auricular appendix.

Following the auricles round to the back, we see what appears to be the posterior surface of a normal left auricle receiving the pulmonary veins in the ordinary manner. We further see that this surface is crossed by a previous left superior cava (L.C), which is flattened out to a width of about half an inch, and is bound to the back of the auricle by epicardium. Following this auricle round to the front, we find it continued into a typical left auricular appendix (L.A.A), which is distinctly seen when the heart is viewed from the front. The pulmonary veins are quite normal.

Between the left appendix and the aorta, which it will be remembered occupies the position of the normal pulmonary artery, is a large mass (R.A.A) resembling a right auricular appendix in appearance. This can be traced to the right behind the aorta and pulmonary trunks to the atrium of the right auricle. As will be seen later, when the interior of the auricles is described, this is really the right auricular appendix which has grown across behind the arterial trunks, away from its normal position, and has reached the left appendix, by the side of which it now lies. So that the two arterial trunks are not embraced by the auricles, but lie to the right and in front of them. At this part also is seen a large triangular projection lying to the left of the first part of the aorta (F); it looks like a third auricular appendix, but on cutting into it, it proves to be a mass of fat covered with epicardium.

The pulmonary artery (P) lies at its origin behind and to the right of the aorta. It is narrower in calibre than usual, being under $\frac{3}{4}$ of an inch, while the aorta is over an inch (outside measurements). On the surface it springs from the base of the ventricular mass behind and to the right of the aorta. It runs upwards with a slight inclination to the left for about $1\frac{1}{2}$ inches, and then bifurcates into right and left branches; the left is the larger; it passes under the arch of the aorta to reach its lung. The ductus arteriosus is attached to the right branch.

The aorta, which curves to the right side of the vertebral column, gives off three branches; the first is a *left innominate*

(LA) which divides into subclavian and common carotid; the second is the right common carotid (C); the third the right subclavian (S).

There is a persistent left superior cava (LC), which is about one-third the diameter of the right superior cava; it receives the arch of a left azygos vein which comes over the root of the left lung, and then passes down in front of the pulmonary vessels, winds round to the back of the left auricle, and is finally continued into the coronary sinus, which opens in its usual position.

I opened the ventricles by anterior and posterior incisions made in each case along, and close to, the interventricular septum. The cavity of the left ventricle is somewhat smaller than that of the right; on transverse section it would be more or less circular; the right would be oval, not crescentic. The moulding of the right round the side of the left, usually seen, is not noticeable. The septum is not nearly so oblique as normal; it divides the ventricular cavity more directly than in the ordinary condition, and the bulging into the right ventricle is absent. The walls of the left ventricle are slightly stouter than those of the right, except near the base, where the thickness of the right exceeds that of the left, but this is owing to the addition of special thickening ridges at this part. In general, the difference in thickness on the two sides is not great. The wall of the right is much the more spongy in character; this is particularly the case as the cavity is approached. The general appearance of the walls of the right and left ventricles, when viewed internally, corresponds pretty closely to that of the walls of the same-named cavities of a normal heart.

The interventricular septum presents a striking anomaly—namely, it is deficient in its upper and anterior part; here there is a large aperture which admits a thumb. The aperture is placed close to the anterior wall of the heart, and is bounded below and behind by the thickened rounded margin of the septum. No artery springs from the left ventricle; and, besides the abnormal foramen in the septum, the only other opening into it is that of the left auricle, which is fairly normal, and guarded by a well-developed mitral valve, the musculi papillares of which are not as powerful as usual. This orifice is placed closer to the

interventricular septum than in the normal heart, owing to the absence of the origin of the aorta from the ventricle. It also might be noted that the large anterior flap of the mitral valve separates it, not from the aortic orifice, but from the foramen in the septum, quite close to which it is placed.

On looking into the right ventricle, the opening of the right auricle, guarded by a tricuspid valve, is a prominent object, situated at the posterior part of the base; in front, and slightly to the left of this, the aortic orifice, with its semilunar valve, is seen; and crossing between the two openings, a prominent muscular ridge of large size. This ridge springs from the septum immediately behind the foramen, it courses to the right, lying between the aortic- and auriculo-ventricular orifices, and runs down on the right side of the ventricle, where it ends midway between base and apex, by breaking up into columnæ carneæ. This ridge is highly developed, and it probably fulfils some important function—perhaps it helps to cut off from the rest of the right ventricle, during the contraction of the heart, that part with which the aorta is connected, and thus brings the aortic orifice into functional connection with the foramen in the septum, and through it with the left ventricle.

Even after a most careful search, no trace of the pulmonary orifice could be found within the ventricle until the artery was opened outside the heart and a probe passed down through it. The pulmonary orifice was then found nearly half-way between base and apex, and slightly posterior to the right margin of the heart. It is of small size, elongated oval in shape, and it looks like a rather large depression between the columnæ carneæ, two of which, strongly developed, bound it at the sides. From this obscure opening a tunnel runs up in the substance of the ventricular wall for an inch and a quarter towards its base; here, behind and a little to the right of the line of the aorta, the vessel becomes free, and appears as the pulmonary artery proper outside the heart. At this point, or immediately before it becomes free, it is guarded by a valve of an unusual shape. This valve was evidently formed originally of three semilunar flaps; these have been prolonged upwards into the vessel, and have become united by their sides, reducing the lumen to a very small size, and by their union and prolongation forming a

structure of a truncated funnel shape, with its narrow part running up for some distance into the trunk of the artery. The lumen of the valve is so much reduced that it only admits a wooden cylinder of five-sixteenths, or little more than quarter of an inch in diameter; while the aorta is fully three-quarters of an inch in diameter internally. Three sinuses of Valsalva are present above the valve.

The tricuspid valve guarding the right auriculo-ventricular orifice is well developed: one flap lies against the septum, chiefly behind but partly overlapping the foramen; a second flap is placed close to the right margin of the heart; while the third flap, which evidently corresponds to the infundibular flap of the normal valve, is of large size, and hangs down between the auricular opening and that of the aorta which lies in front of it. The segments are quite normal, except that the infundibular one separates the auriculo-ventricular orifice from the aorta instead of from the pulmonary artery; this irregularity is explained by the fact that the aorta arises from the right ventricle, at the site usually occupied by the pulmonary artery,—that is, it comes off from the upper and anterior part of the ventricle quite close to the septum. It is here guarded by a normal valve of three segments.

Below the aortic orifice there is a considerable portion of the upper and anterior part of the ventricle, which seems to be more or less distinctly marked off from the rest of the cavity, both structurally and functionally. It is bounded behind, first by the strongly developed muscular ridge which crosses the base of the ventricle between the aortic and auriculo-ventricular orifices, and more posteriorly by the large anterior flap of the tricuspid valve. In front this space is marked off from the general cavity, to some extent, by a slightly developed muscular ridge, which, beginning at the septum, crosses on the anterior wall just in front of the aortic opening. On its left side is the foramen in the septum. This portion of the ventricle just described, even in appearance, seems to differ from the rest; it looks like a separate little chamber, incompletely partitioned off from the ventricle to form a vestibule for the aortic trunk. Into this vestibule on its left side opens the left ventricle through the foramen in the septum, from it above springs the

aorta, while it itself forms the channel of communication between the two. The walls of this chamber are much thicker than those of the rest of the right ventricle.

As to the auricles:—On opening the right atrium it is seen at once that the septum auriculorum is almost completely absent, its only representative being a very thin ridge, about a quarter-inch high, which runs along the line of separation between the two auricles except above and in front; it is distinctly marked in the interval between the auriculo-ventricular openings. I do not think that this is merely a patent foramen ovale; it seems to be rather a deficiency of the primary interauricular septum. It will admit three fingers quite freely. Now it can also be seen that the cavity of the right atrium is continued to the left, behind the pulmonary artery and aorta, into the large appendix seen on the front of the heart between the aorta and the left appendix, and described above as the displaced right auricular appendix. At the lower part of the right auricle is seen the opening into the right ventricle, which appears quite normal; and between this and the aperture of the normal inferior cava, in the position usually occupied by the orifice of the coronary sinus, is found the termination of the left superior cava, opening under a well-developed single valve, the concavity of which is directed downwards. The interior of the left auricle is normal but for the absence of the interauricular septum.

In such a case as this, three questions naturally suggest themselves: First, How can the production of the abnormal conditions be explained? Secondly, How was the circulation carried on through the heart? And thirdly, What is the explanation of the physical signs observed during life? The method of production of most of the anomalies present can be readily explained by a reference to the development of the heart and great vessels; and they may all be put down as errors in development or persistence of fœtal conditions. But as to their primary cause, I fear we can say but little.

The foramen in the interventricular septum is due to the persistence of a condition which is normal in the fœtus for a short time during the development of the heart. It will be remembered that this septum ventriculorum is built up from

three sources: first, a strong ridge grows up from the bottom of the common ventricular cavity—the septum inferius; this is the chief factor. As it passes up in front of the orifice of the dividing auricle, it is joined by a prolongation forwards from the endo-cardial cushions which separate the common auricular orifice into two; this, with possibly another element added from the floor of the auricle, is the septum intermedium. When it has joined with the septum inferius, the ventricles are separated completely except above and in front; here there still exists an aperture corresponding in position to the abnormal foramen in the heart which I describe. This aperture is finally closed by the lower part of the septum which divides the aortic bulb into aorta and pulmonary artery; this, under the name of the septum superius, joins the septa inferius and intermedium, and completes the division between the two ventricles, forming the pars membranacea septi of the adult. The septum of the bulb undergoes a peculiar rotation as it descends; above it is at right angles to the septum inferius; as it grows down it twists round, and finally runs in the same plane as this latter septum. Now, a foramen in the adult ventricular septum may be due either to deficient downward growth, or to imperfect rotation of the septum bulbi. I am inclined to think that the latter is the correct explanation in this case, for the septum seems to have undergone scarcely any rotation. The absence of this rotation also explains the origin of the aorta from the right ventricle. The septum bulbi lies behind the aorta, and runs nearly transversely; had its right margin rotated forwards below, it would have pushed the aorta over to the left, throwing it into connection with the left ventricle, and at the same time, by its union with the septum inferius, it would have completed the septum ventriculorum, and cut off the aorta completely from the right ventricle, throwing the part of that cavity which I described as the aortic vestibule into the left ventricle. From this it is apparent that the right ventricle in this case is a compound cavity made up not only of right ventricle proper, but also of a portion of the left cavity, which should have been shut off from it by the descending septum bulbi.

The right aortic arch is, of course, explained by the persistence of the right instead of the left fourth arterial arch; in such

a condition the first branch of the aorta will naturally be a left innominate, developed from the ventral root of the right arches, and the right carotid and subclavian will follow in this order.

The peculiar condition and position of the internal orifice of the pulmonary artery I am at a loss to account for, unless it be due to a partial persistence of the fœtal trabecular condition of the interior of the ventricle.

The free communication between the two auricles is explained as an almost complete absence of the auricular septum. It might be unwise to suggest what part of the septum has failed, while a certain amount of doubt still exists as to its true formation; but it is perhaps worth remarking that there is complete absence of the partition above and in front, while it is best developed behind and below between the two auriculo-ventricular orifices, where His describes the growth upwards of a crescentic fold (connected with the septum intermedium), which Born has not found.

The position of the two auricular appendices lying together at the left side of the base of the heart may be explained by the failure of the developing appendices to embrace the aortic bulb,—that is, the arterial trunks,—owing to the abnormal position of these to the right of their usual site. No special reference need be made to the condition of the left superior cava.

These are the explanations of the method in which the anomalies were brought about. I wish I could give some adequate explanation of the primary cause which produced these results. This, I fear, I cannot do. To me it appears that the great error in this case must be attributed to the septum bulbi; if it had developed normally, many of the irregularities would have come right. Still, there is seen throughout the whole organ a sluggishness of development which must have had some general inherited cause.

Regarding the second question—How was the circulation carried on in the heart during life?—it should be remembered that the patient lived to the age of twenty years, and during a great portion of that time was employed in a fairly laborious occupation. To enable her to live and work up to this age, the circulation within the heart must not have been so chaotic as a look at the organ would suggest. That the blood in the two

auricles mixed to some extent I have no doubt (the hemiplegia following curetting of the uterus favours this view), but that the mixture was not very great I am strongly of opinion. I believe that the blood returned from the lungs was drawn through the left auricle by the suction of the left ventricle, and that the impure blood returned by the cavæ was similarly drawn through the right auricle without much mingling of the two floods. That all the blood which entered the left ventricle must have passed out of it through the foramen in the septum is evident, as there is no other opening into the ventricle except the

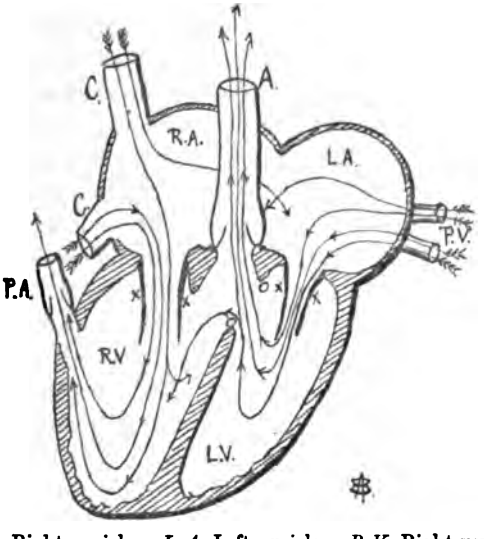

FIG. 2.—*R.A*, Right auricle. *L.A*, Left auricle. *R.V*, Right ventricle. *L.V*, Left ventricle. *A*, Aorta. *P.V*, Pulmonary veins. *C.C*, Venæ cavæ. *P.A*, Pulmonary artery. *X.X*, Tricuspid and mitral valves. Between *O* and *O* the foramen in the septum. The arrows indicate the probable course of the blood-current. The crossing of arrows indicates a mixture of currents.

valved mitral orifice. It is also probable that this blood sent through the septum into the right ventricle did not mix to any great extent with the impure blood of that cavity, but, on the contrary, that it passed direct from the foramen in the septum into the beginning of the aorta, through the special compartment of the right ventricle which I have previously described as the aortic vestibule. The blood in the two ventricles must have been under a similar pressure during the contraction of

the heart, owing to the free communication between them; and hence the fact that the wall of the right is almost as thick as that of the left ventricle.

The quantity of blood returned to the right auricle by the cavæ must, of course, have been the same as that which left the heart by the aorta. If this blood passed down to the right ventricle without much mixture with the contents of the left auricle, as I suggest, the right ventricle would have had to eject at each systole as much blood as passed through the aorta at each contraction of the ventricles. How it could do this it is difficult to see, if the aorta be filled from the left ventricle through the abnormal foramen, and if it be remembered that the orifice of the pulmonary artery was little more than ¼ of an inch in diameter, while that of the aorta was about ¾ of an inch. Still, I believe that it did get rid of this large quantity of blood by sending a small part of it into the aorta, and the greater part through the pulmonary artery, small though it be; for, as pointed out above, the pressure in both ventricles must have been equal, the resistance offered by the pulmonary circulation was very small as compared with that offered by the general circulation: as a result, I think I am correct in saying that the flow through the pulmonary orifice must have been much faster than that through the aorta, and that consequently a larger quantity of blood could be sent into the pulmonary artery than might be thought possible at first sight. Thus the greater part of the blood collected in the right ventricle was sent off to the lungs for aeration; and notwithstanding the deficiencies in the septa, and the small size of the pulmonary orifice, the circulation was kept in a condition of moderate efficiency (see fig. 2, which shows this, in diagram).

One word as to the cause of the physical signs. The loud, harsh, systolic murmur was possibly due to the rush of the blood, driven by the powerful right ventricle through the narrowed pulmonary valve, and also by the rapid flow through the foramen in the septum. The loud, sharp, second sound, accompanied by a beat felt with the hand, may have been due to the superficial position of the aorta, and to the high pressure in the pulmonary artery acting on its valve.

Journal of Anatomy and Physiology.

ON THE OCCURRENCE OF A JACOBSON'S ORGAN, WITH NOTES ON THE DEVELOPMENT OF THE NASAL CAVITY, THE LACHRYMAL DUCT, AND THE HARDERIAN GLAND IN *CROCODILUS POROSUS*.

By ALEXANDER MEEK, B.Sc., F.Z.S. (PLATE X.)

(From the Anatomical Institute, Freiburg in Baden.)[1]

IN the beginning of 1891, Professor Howes, in a communication on the nasal region of the skull of certain Crocodilia, dealing particularly with the relations of the vomers, showed good reason for supposing that two small sacs supported by cartilaginous walls and "lying within the embrace of the prepalatine foramina" in a young specimen of *Alligator mississipensis* were all that remained of Jacobson's organs. These sacs were connected to the vomers by ligament, and he pointed out that in certain other genera and species the same ligament extended forwards from the vomer to the premaxillo-maxillary suture, the cartilaginous sacs being absent. The sacs he held to be homologous to the forward enlargements of the vomers which lie in the premaxillo-maxillary sutures of the black caiman.

The occurrence of Jacobson's organ in a very young example of *Crocodilus porosus* has since been demonstrated by Dr Sluiter[2] of Amsterdam. He confesses to having experienced great difficulty in getting a stage in which it presented a typical form. Dr Beard failed to find it in an embryo that he examined,[3] and all that I can say, after examining a comparatively rich series of embryos of the same species, is that I can only find a rudimentary trace of the organ; and indeed, that had it not been for the discovery of Sluiter, I should have said it was altogether absent.

[1] *Proc. Zool. Soc.*, 1891, p. 148.
[2] *Anat. Anzeiger*, 1892, p. 540.
[3] *Zool. Jahrb.*, 1889, p. 772.

These embryos were kindly placed at my disposal by Professor Wiedersheim, along with certain preparations which had already been made by Dr Carl Röse, and I beg to take this opportunity of returning my warmest thanks to these gentlemen.

I propose in the following pages to record the notes I have made on the general changes undergone by the nasal cavity, pointing out what I take to represent Jacobson's Organ, and to add observations on the development of the Lachrymal Duct and the Harderian Gland.

I. *The Nasal Cavity and Jacobson's Organ.*

I am sorry that it is impossible for me to give other than empirical stages, as determined by the (largest) longitudinal measurement of the head; as my specimens, for the most part, consisted of heads only. But if the excellent drawings of Parker[1] be compared, it will be easy to arrive at an approximate conclusion in regard to the length of the embryo in each case. All my sections are transverse, except the very youngest, which are longitudinal.

1st Stage—5 mm.—The beak is very short, and the nasal sacs, already completely formed, correspondingly so. It will be seen from fig. 1 that the anterior and posterior nares are very close to one another. Both are narrow openings, and the sac they lead into is very simple. It extends blindly upwards, as shown in the figure, expanding laterally at the same time; and this part is provided with a thick wall of epithelium, formed of a number of columnar cells, wedged together. It is the olfactory region, and the olfactory nerves can be traced to it. The epithelium thins away in the anterior and posterior passages. The labyrinth which is seen in the older specimens, and which has been described by Gegenbaur,[2] Solger,[3] and others in adult or formed young specimens of the Crocodile, is only represented here by a shallow vertical depression of the external wall.

The head measuring 5¾ mm. answers to the above description also, and in both this and the larger ones I have looked carefully for a Jacobson's organ.

[1] *Phil. Trans.*, 1883, p. 263. [2] *Jenaische. Zeitsch.*, Bd. vii. p. 1.
[3] *Morph. Jahrb.*, Bd. i., 1876, p. 467.

In these young specimens we find on each side a shallow and wide-mouthed depression of the front wall of the posterior nares, turning slightly outwards to form a crescentic groove (J, fig. 1). A very similar depression of the posterior wall (*g*) also ends blindly, and is the section of a deep groove on the roof of the mouth into which the posterior nares opens. This groove extends from behind, across and forwards, and ends before reaching the middle line. The posterior nares opens on its external and anterior face. The depression on the front wall would appear to represent the origin of a Jacobson's organ. And if we now look at the head measuring 7 mm. (the youngest I possess in transverse section), we see a process and enclosed groove on the inner wall, which leads us further to conclude that the organ *is* represented, but in an extremely reduced condition.

2nd Stage—7 mm.—The external nasal openings are widely separated, occurring laterally near the point of the beak, and they have a slightly crescentic slit-like form. They lead into flattened cavities, which early show the thickened epithelium above named, the lower apex of the sections alone presenting a thin wall. The upper angle, as we follow the series backward, turns gently outwards and the lower one downwards. A little distance back we meet with a seeming branching-off of two canals from the thin-walled part of the cavity below (fig. 2). That outer one, opposite the lachrymal duct, does not continue to the duct at all (see description of Lachrymal Duct), but is the beginning of the simple accessory cavity of the nose (the labyrinth, or *Nebenhöhle*, before alluded to).

Comparing figs. 3 and 4, we see that the inner branch is not really a canal, but the beginning of a lip-like projection of the inner wall of the nose into the nasal cavity. It projects downwards and backwards, thus in a way shutting off a small part of the nasal cavity. This is the only structure that I can find at this stage which at all answers to a Jacobson's organ, and the disappearance of it, small as it is, must be surprisingly rapid, for there is no trace of it in my next head, measuring 7¾ mm. I have no doubt that a more minute examination of other genera and species will disclose that, in all, the organ presents a more or less varying degree of reduction. In *Caiman niger*

and in *Alligator mississipensis* a remnant may be apparently retained for life, but in *Crocodilus porosus* the history of the organ is a very fleeting one.

Turning now to the canal opposite the one we have just been considering, and which is the beginning of the lateral labyrinth of the nose, we find, on following the sections backwards, that it resembles somewhat its neighbour on the opposite side,—that is to say, it is only the section of a flattened cavity which projects laterally from that of the nose, and curves at first backwards and then forwards. The opening forms a large crescent on the side wall.

We observe, further, in following the series of sections, the appearance of two ridges (*r*)—one on each side—on the roof of the mouth. They commence near the anterior margin, and at first accompany the teeth, then they gradually approximate, becoming larger, and, by a seeming shrinking of the mesodermic elements below the ridge, a space appears in all my specimens separating the cells of the mesoderm from the epithelium of the mouth. Nearly opposite the beginning of the nasal labyrinth the inner base of the ridge deepens to form a groove, and the posterior nares—a narrow canal—is given off here, piercing the upper or inner side of the ridge to open into the mouth. The groove is the same as that described in stage 1, and, with the ridge, projects some distance backwards.

3rd Stage—7¾ *mm.*—There is little or no difference, as regards the general appearance of the nasal cavity, between this head and the preceding. There is now no trace of that internal involution of the nasal sac, which I have regarded as a vestigial Jacobson's organ. Behind the posterior nares the nasal cavity continues as before for some distance, and projects laterally from a similar crescentic opening, to form the accessory cavity. The latter is now a little more complicated, by protrusions of the side wall into its interior—two from above and one, between them, from behind.

4th Stage—9½ *mm.*—The posterior cavity here undergoes a further extension. The opening of the lateral, or accessory, cavity has become more wide below, and the cavity itself has correspondingly increased. The projections referred to now bound a slight secondary cavity opening backwards into the

parent one. At this stage, moreover, by the approximation of the two ridges on the roof of the mouth, the posterior nares now open by a single aperture behind (fig. 5). The groove mentioned above will still be seen to bear to these the relations before described.

5th Stage—12 *mm.*—The external opening is now on the top of the nasal region of the skull and is quite simple. The cavity begins at once to assume a horizontal position, becomes quite horizontal in a few sections, but only for a very little distance. The internal end of each sac begins to rise, until it attains the vertical position, where it leads off into the lachrymal duct.

Posteriorly, we see that the accessory cavity is yet in a very simple condition. It is wide behind, and presents slight irregularities of the walls on its upper and lower borders. The nasal cavity extends behind this accessory one for some distance.

The posterior nares now extend far backwards, beyond their origin from the nasal cavity, and far behind the termination of the olfactory region of the nose above them. The two ridges noted in the earlier stages have now fused together with the median downward process between the posterior nares, and the resulting ducts are thus carried backwards as separate canals for some distance, and still further so after they have run together to form a single canal, which ultimately opens into the mouth. The groove seen at the base of the ridges in the young specimens again makes its appearance at the junction of the two posterior nares, and continues backwards at the top of the single cavity and beyond its opening into the mouth. And at the latter we see the ridges which, by their fusion, ultimately carry the nostrils still further back.

6th Stage—27 *mm.*—The anterior narial openings are, as in the preceding example, on the top of the beak, but now more closely approximated. They lead directly downwards and expand into the cavity of the nose. The latter soon becomes almost rounded, and extends backwards in that form. Conspicuous at this stage is a thickening of the floor of the nasal cavity, extending, as we pass backwards, to its inner and upper surfaces, leaving the outer wall thin. This thickening alone answers to the thick-walled epithelium of the earlier stages. And the cavity retains

this condition all the way backwards. As in the preceding stage, the inner part gradually rises, giving the section of the cavity a crescentic form. Passing the opening of the lachrymal duct, and before losing sight of the long flattened part of the nasal cavity into which this opens, we see the beginning of the accessory cavities. We saw in the preceding, and very much younger, embryos that the accessory cavity was simple, and formed by a projection of the side wall and skeleton (turbinal) shutting off a space, bounded by the said process and the side wall and opening by a large crescentic aperture. We find now a series of three accessory cavities, whose relations I will attempt to describe. The first opening, which we have just seen behind the opening of the lachrymal duct, leads straight into a roundish and pretty large sac (1), and this leads downwards into a passage (2) which projects backwards parallel to the nasal cavity, gradually dwindles away, and disappears. The cavity (1) takes its origin from the nasal sac at the junction of the thin and thick-walled epithelium, and so its upper half bears the latter and its lower the former. It is from the latter that the passage is derived, and that therefore consists entirely of the thin-walled epithelium.

A good distance further back the side wall of the nose forms a depression, and near the beginning of this we find an opening into a cavity (*a*) which projects forwards, leading almost into the passage (2) above mentioned. Opposite its origin from the nose, cavity (*a*), lined wholly by thin epithelium, leads downwards into cavity (*b*), and this extends as a flat horizontal passage outwards and expands into a large and irregular sac (*c*). It is so large that it extends forwards to the outside of the passage (2), and two projections, it first narrowing and then expanding again, reach as far backwards as the nasal cavity itself. All the cavity (*c*) is lined by extremely thin membrane.

The same depression continues backwards into a crescentic cavity separated from the nose by a process projecting from the side wall. It is the simple cavity that we have seen in the earlier examples, although it now presents a large extension anteriorly and externally to those described. These latter must be looked upon as extensive neomorphs, which have taken their origin late in the history of the animal's development, and

as respiratory in character. The cartilaginous skeleton accompanies and supports their wall, as it does that of the posterior olfactory labyrinth.

The posterior nares proceed backwards for a considerable distance, at first separately, and ultimately as a single flattened horizontal canal.

The thick-walled epithelium of the nasal cavity presents throughout simple glands. A narrow duct leads through the mucous membrane and expands into a simple pocket.

The nasal cavities are now practically in the condition found in the adult. They pass backwards in the upper jaw on each side giving off the posterior nares on the lower surface, a considerable distance before they terminate blindly, in front of the eyes. We have seen that the posterior nares are to a considerable extent separate canals, but that they ultimately fuse together; there is evidence at this stage of a projecting ridge above and below in the middle line which effects a further separation. We have seen that the present condition of the nasal cavity has been arrived at through the great forward extension of the upper jaw, and that the posterior nares owe their adult condition to the gradual fusion of two ridges which early make their appearance on the roof of the mouth in relation to the palate.

To briefly recapitulate the succession of lateral openings from the nasal cavity. As we pass from before backwards the first opening we see is the one into the lachrymal duct. Two others occur behind this and *in front* of the posterior nares, and yet another occurs, which presents a very wide opening beginning just above the origin of the posterior narial passage. The first two are not at all represented in the earlier stages of development, while the latter is the orifice of the simple lateral cavity found in the younger examples.

II. *The Lachrymal Duct.*

I find that my sections show a similar development of the lachrymal duct to that described by Born.[1] In the longitudinal section of the smaller heads (5 *mm.*–5¾ *mm.*) we find no trace of the duct at all, in connection with the nose; but, as Born

[1] *Morph. Jahrb.*, Bd. v. pp. 62 and 401.

has shown for the Lizard and Chick, one can see, at the base of the groove separating the nasal passage from the folds which represent the eyelids, a rod-like thickening of the epidermis. The lower end of this has, as yet, no connection with the nose.

The transverse sections which follow bear this out. In the head measuring 7 mm. we find the duct extending inwards a short distance from the skin, but as yet failing to connect itself with the nasal cavity. One is apt to think at first sight that the lateral process from the nose, near the posterior end of the lachrymal ridge, is an outgrowth of that organ to meet it (figs. 2, 3, 4). But, as has already been shown, the former is the beginning of the olfactory labyrinth.

The ridge of cells passes forwards beyond this lateral extension of the nasal sac for a good number of sections (40 sections or so of 10 μ), leaving the skin near its front end and disappearing. There is a slight trace of extension of the nasal cavity to meet it. The posterior end as yet does not exhibit a branching into two.

In the 7¾ mm. head we find a meeting between the solid process from the nose and the solid lachrymal duct, but without fusion. This nasal process is a horizontal flat plate of cells. The fusion of the front end of the duct with the process in question is almost complete in the head measuring 9½ mm. There is now, then, a solid rod of cells extending from the skin to the nasal cavity. It extends forwards a little after leaving the nose, and then bends gently round to pass upwards and backwards. Some distance on it becomes much reduced in diameter, and, traversing the space between the nasal sac and the skin, it becomes continuous with the latter, below and in front of the eye. Here the duct becomes very indistinct, the cells not being so well differentiated from their mesodermic surroundings as in the more anterior region.

In the 12 mm. head the nasal plate of cells presents a lumen, but the duct is still solid and of small diameter. It ends in the lower eyelid, where it splits into two. The outer branch does not quite reach the epidermis, while the inner one does.

27 *mm.*—A considerable change has taken place in the history of the lachrymal duct at this stage. It has now a complete lumen, and its walls are beset with glands. It takes its

origin in front, from the lower thin-walled region of the nasal cavity; and extends blindly forwards for a short distance parallel to that cavity. The glands persist for nearly the whole length of the duct. In the lower eyelid, however, the section of the duct loses its irregular form and becomes round. At this end of it, an incomplete and thin plate of cells extends across the lumen—incomplete in the sense that it shows signs of absorption. One can trace it through a few sections, and then it disappears for a section or two, to reappear exactly in the same place—thus forming an incomplete membrane stretching up and down the canal.

An ultimate and late splitting into two takes place in the lower eyelid, where both ducts open. It is certain that the incomplete membrane just mentioned indicates the fusion of the two branches which have had, a little earlier in the history of the animal, a longer separate journey to perform.

The glands of the lachrymal duct are more complicated than those of the nasal mucous membrane. They exhibit a splitting up into tubules. In the dissected specimen one can see their openings as minute apertures on the inner face of the duct, giving it a finely dotted appearance.

III. *The Harderian and Lachrymal Glands.*

I can find no trace of either Harderian or Lachrymal glands in any but the largest head I possess, viz., that measuring 27 mm. Here the Harderian gland occupies its normal position (fig. 6); it is already well developed, and opens by several apertures into the wide extension of the conjunctiva, between the nictitating membrane and the eyeball.

It is singular that in this specimen I can find no lachrymal gland; and as I have not seen it in any of the younger ones, I am led to conclude that it is absent. I believe the College of Surgeons' Museum, London, possesses a preparation of the adult by Hunter showing its presence.[1] Some of my heads fail me in the posterior region of the eye, but in this one (27 mm.), in which at least the posterior part of the conjunctival space is complete, there is no sign either of the gland in question, or of origin of a glandular structure from its outer part.

[1] *Cf.* Owen, *Compar. Anat. of Vertebr.*

EXPLANATION OF PLATE X.

a.n, Anterior nares.
c.s, Conjunctival space.
g, Groove on the roof of the mouth and ultimately on the posterior nares.
g.t, Tubules of Harderian gland.
J, Involution of supposed Jacobson's organ.
l, Lateral cavity of the nose.
l.d, Lachrymal duct or lachrymal ridge.
n.c, Nasal cavity.
p.n, Posterior nares.
y.s, Yolk sac.
r, Ridge on the roof of the mouth ultimately forming the palate.

The sections were photographed under a Zeiss A. objective.

Fig. 1. Longitudinal section of head measuring $5\frac{3}{4}$ mm.

Figs. 2, 3, and 4. A series of transverse sections of a head measuring 7 mm., showing the apparent vestigial Jacobson's organ.

Fig. 5. Transverse section in the region of the posterior nares of a $9\frac{1}{2}$ mm. head, showing the approach of the ridges to form the palate.

Fig. 6. Transverse section through the Harderian gland of a 27 mm. head.

I desire gratefully to thank Professor Howes for much valuable advice and guidance in preparing this paper for publication.

ON COLLOID IN THE LYMPHATICS AND BLOOD-VESSELS OF THE THYROID IN GOITRE. By R. M. HORNE, M.B., C.M. Edin.

THE nature of the colloid material of the thyroid gland has been the source of much divergence of opinion in the past, and notwithstanding the researches of many inquirers, our knowledge of it is still uncertain. Of its mode of origin—whether by a secretive or by a degenerative process—we are still in doubt; of its chemical composition, and of the part it performs in the physiology of the gland, nothing definite is known; of its ultimate fate, we also know but little.

In recent years the lymphatic system has come to be regarded as the duct of the thyroid, as the channel by which the colloid material is removed. The only ground for this view lies in the presence of "colloid" in some of the lymphatics of the gland.

Baber,[1] working with dogs' thyroids; Biondi,[2] with thyroids of amphibians, birds, and reptiles; Langendorff,[3] with thyroids obtained from recently killed calves and young dogs; and Horsley, with thyroids of monkeys, all have demonstrated the presence of colloid in the lymph system of vessels. Horsley[4] has shown further that colloid is also present in those lymph glands towards which the lymphatics of the thyroid pass. It is believed by these observers that the colloid present in the lymphatics has come from the follicles of the gland. All attempts, however, to find a connection between the follicles and the lymph vascular system have failed, so that if this system really acts as the "thyroid duct," we are still in doubt how the secretion finds its way thither.

Till May of the present year no observations had been made on the behaviour of the lymphatics in the human thyroid. At that time Podbelsky[5] published a short account of his research on this subject. The examination of twenty goitrous thyroids, obtained with one exception *post-mortem*, revealed the presence of colloid in the lymphatics in five cases only. There is a wide discrepancy between this result and the statement of Langendorff that "Only seldom will one examine the thyroid gland of a calf or a dog without finding colloid in the interfollicular lymph spaces." This question

[1] *Proceedings of the Royal Society*, vol. 24.
[2] *Berliner Klinische Wochenschrift*, 1888, No. 47.
[3] *Archiv für Anatomie und Physiologie, Suppl. B.*, 1889, pp. 219-240.
[4] *British Medical Journal*, 1892, No. 1622, Jan. 30, pp. 2-7.
[5] Prager, *Medicinische Wochenschrift*, 1892, Mai 11 and 18, Nos. 19, 20.

is certainly worthy of the further inquiry which Podbelsky intends to carry out.

Gutknecht[1] has drawn attention to the presence of colloid in many of the blood-vessels of goitrous thyroids, and has attempted to trace its origin to changes induced in the red blood corpuscles by some influence exerted on them by the diseased gland; and we find Langhans[2] quoting his observations on this point as affording a possible explanation of the connection he supposes to exist between the thyroid and the series of changes in the peripheral nerves which he has recently discovered in cases of myxœdema, cretinism and cachexia thyreopriva.

The application of the word "colloid" to this substance found in the blood-vessels and lymphatics is perhaps somewhat misleading, as thereby a connection might, *a priori*, be supposed to exist between it and the "colloid" of the gland follicles. It would have been preferable either to have spoken of a "colloid-like substance," or to have discarded the word "colloid" altogether in favour of the word "hyaline": v. Recklinghausen teaches the use of the word "colloid" as a generic term for the three degenerative processes amyloid, hyaline, mucoid—including under "hyaline," among other things, the "colloid" present in the thyroid follicles. The advantage in the use of the word "hyaline," in v. Recklinghausen's sense, is that it carries with it the recognition of the existence of several substances which resemble each other in their microscopic characters and in their strong resistance to the action of chemical reagents—indistinguishable, therefore, from each other, according to our present knowledge, but which differ in situation and mode of origin. The confusion, arising from a preconceived association between "colloid" and the thyroid gland, is thereby avoided.

The word "colloid" will be used in this paper in order to keep its nomenclature in harmony with that of previous articles on the same subject, but is to be regarded, in every case, as synonymous with the "hyaline" of v. Recklinghausen.

My own observations on the presence of colloid material in the vascular systems have been made on eighteen goitrous thyroids obtained, with one exception, *post-mortem*. These were removed from individuals varying in age from six months to sixty-eight years, who had died from a variety of causes.

[1] *Die Histologie der Struma*, *Virch Archiv*, Bd. 99, 1885.
[2] *Virchow's Archiv*, June 1892.

Before giving a short account of those in which colloid was found in either vascular system, it is necessary to describe the method generally adopted in the examination of these specimens.

A piece was taken usually from the periphery of the gland, and when possible containing a goitrous nodule. This was stained *en masse* in alum carmine for two or three days, and having been washed carefully in water to remove excess of colouring matter, was subsequently hardened in absolute alcohol and imbedded in celloidin in the usual manner. The confusion which sometimes arises between colloid and celloidin is thus avoided, as the latter remains uncoloured and transparent.

Each piece was cut in series in order to permit of the accurate differentiation of arteries from veins, veins from lymphatics, and veins and lymphatics from distended follicles.

Occasionally the piece was cut with the ether freezing microtome instead of by the celloidin method.

In single sections Weigert's method for the staining of fibrin was adopted, in addition to the alum carmin stain, in order to distinguish colloid proper from mere hyalin fibrin.

All the glands except one were fixed in Müller's fluid, and subsequently hardened in alcohol. The exceptional gland was treated with alcohol only.

I shall now describe those cases in which colloid was present in the vascular system.

I. Girl aged 13 years. *Post-mortem* diagnosis: Lung infarct; tuberculosis of the kidney.

The thyroid was only slightly enlarged. No adenomatous nodules were visible to the naked eye. Distended follicles were readily made out.

One piece was examined. The greater number of follicles are slightly distended with colloid, a few are much distended, while others from their shape and size have evidently been formed by the fusion of two or more adjacent follicles. The blood corpuscles are well preserved, retaining for the most part their normal shape and size. In several of the veins round masses of colloid of various sizes lie, imbedded in the midst of normal red blood corpuscles, surrounded by them, but sharply outlined from them. These stain well, are refractile, and resemble the colloid of the follicles. No lymph vessel containing colloid has been observed.

II. Man aged 26. *Post-mortem* diagnosis: Dislocation of cervical vertebræ, the result of an accident.

Both lobes of the thyroid were small, and contained many small nodules, some of them cystic.

One piece was examined in which two adenomatous nodules were present. In the more normal tissue only a few follicles are distended, and that slightly. The nodules consist of largely distended and irregularly-shaped follicles, containing colloid, and in many cases also more or less altered blood. The fibrous tissue has in parts undergone hyaline degeneration, especially that around the nodules.

In one of the nodules a small vein completely filled in part of its course with colloid is to be seen, in a branch of which normal blood corpuscles lie.

The examination of many sections did not reveal any lymphatics, containing colloid.

III. Girl aged 16. *Post-mortem* diagnosis: Diphtheria; bronchopneumonia.

The thyroid was slightly enlarged in both lobes. There was one adenomatous nodule about the size of a cherry in the left lobe, and a smaller one in the right.

One piece was used which did not contain a nodule, or part of a nodule. The lobules are well defined by fibrous septa, in which no hyaline change has taken place. Some follicles contain no colloid, none have undergone much distension. In several of the arteries and veins fibrin coagula are present. In the larger number of the veins are seen colloid balls of various sizes, some in association with the coagula, others independent of them and surrounded by quite normal blood corpuscles. These balls resemble the colloid of the follicle in their high refractile power and depth of colour. No colloid has been observed in the arteries.

The lymphatics have also been examined for colloid, but its presence in these has not been satisfactorily demonstrated.

IV. Man aged 19. *Post-mortem* diagnosis: Labyrinthitis purulenta; meningitis. The thyroid is small; both lobes are beset with numerous nodules of various sizes, none of which are larger than a cherry. Four pieces examined.

In many of the veins colloid balls are present, lying in the midst of perfectly normal blood corpuscles.

No lymphatics containing colloid have been seen.

V. Man aged 35. *Post-mortem* diagnosis: Tuberculosis; cirrhotic and fatty liver.

Both lobes were slightly enlarged; on section, no adenomatous nodules observed.

One piece was examined. Many of the follicles are largely distended with colloid; the greater number have undergone only slight distension. In the series of sections examined, only one vein with colloid was seen. It could, however, with its colloid, be traced through most of the sections. The colloid occurs as a large irregular mass adhering by part of its margin to the wall of the vessel. At its free margin several normal blood corpuscles are observed. In its centre a fibrinous coagulum lies, from which, however, the colloid is readily distinguished. Colloid material is present also

in a small branch entering the vein, which contains no fibrinous mass.

Colloid in the lymphatic spaces has been satisfactorily made out in several of the sections of this piece.

VI. The name of the individual to whom this thyroid belonged has unfortunately been lost, so that the cause of death, &c., cannot be given.

The thyroid was only slightly enlarged; one adenomatous nodule present in the left lobe, none in the right. Two pieces were examined. The distension of follicles with colloid is well marked. The blood corpuscles have retained their normal character. Colloid material has been observed both in veins and in lymphatics. In the veins it does not exist in the form of balls already described, but as a more or less irregular mass lying in the midst of normal red blood corpuscles.

Lymphatic spaces containing colloid have been found in sections of both pieces. In one piece the adenomatous nodule was cut in section along with some thyroid tissue proper. In these sections colloid has been found in lymphatics more removed from the nodule, as well as in some nearer it. The other piece, which was cut with the freezing microtome, contained no part of a nodule.

VII. This thyroid was obtained from a man who had died with well-marked signs of tertiary syphilis. The gland was treated with alcohol only. It was slightly enlarged, and on section each lobe showed one small colloid-degenerated nodule.

One piece was examined. The follicles are not distended, only a few containing colloid. Colloid material is present in many of the blood-vessels, but as in this case the red corpuscles are not well preserved, no conclusion can safely be drawn as to its mode of origin.

Several lymphatics containing colloid are present.

VIII. Boy aged 8 years. *Post-mortem* diagnosis: Empyema and pyæmia.

Both lobes of the thyroid were much enlarged. No nodules were observed. Surface of sections showed largely distended follicles.

Two pieces were examined: one piece from a portion of the gland which had been hardened in alcohol, the other from a portion treated with Müller's fluid.

The distension of the follicles is very pronounced. The fibrous tissue of the septa has not undergone hyaline change. No blood-vessels, having colloid, have been found in the sections made from the second piece; one large vein containing many polygonal cells, some fibrin coagulum and colloid material, has been observed in several of the sections from the first piece.

No lymphatics, containing colloid, have been discovered in any of the sections from the first piece. In several of the sections from the second piece a very interesting condition exists. This is the presence of colloid in a lymph space which communicates with two of the distended follicles. The two follicles concerned are situated at the margin of their lobule, and border therefore on the interlobular septum, in which is a lymph space containing colloid. In several of the sections

the boundary between the lymph space on the one side and the two follicles on the other is complete but thin, consisting chiefly of the flattened epithelial lining of the follicles themselves. In three of the sections, and these in series, the intervening septum is incomplete, and channels of communication exist between the lymph space and each of the two follicles, the colloid in the one being directly continuous through these channels with the colloid in each of the other two. These are not artificial tears in the walls, because, apart from the tissue having been imbedded in celloidin, there is no evidence of any such tearing in the presence of loose tags of septum corresponding to the various channels, and the channels themselves are occupied by true colloid material. The condition is best explained by a giving way of the septum from over-distension, the separation of the two torn ends forming a channel into which and through which the colloid has found its way. It is a natural process, albeit a pathological one, akin to the rupture which often takes place in the septa between adjacent over-distended follicles.

The space in the septum with which the two follicles thus communicate is undoubtedly a lymph space. For, although smaller than the distended follicles, only one or two endothelial-like cells are visible on its walls, whereas in the most largely distended follicles an almost continuous lining of epithelium is still to be made out. Further, if the space be traced through a series of sections, it is found to pass into a narrow channel also containing colloid, which runs away from the follicle, into the interlobular septum.

The results of my observations on the occurrence of colloid in the lymphatic system correspond closely with those of Podbelsky. The proportion of 4 in 18 is almost identical with a proportion of 5 in 20. It is to be remarked, however, that this being merely a subsidiary point in my work, the same number of pieces from each gland have not been examined as Podbelsky used in the examination of his specimens. In one case he examined as many as five pieces from one gland, and only obtained lymphatics containing colloid in one of them. It is possible, therefore, that had more of each gland been examined, my proportion might have been higher.

Podbelsky lays much stress on the presence of adenomatous nodules as a probable factor in the occurrence of colloid in the lymphatics. He cut his pieces to contain a nodule or a portion of a nodule in each, and he found the colloid-containing lymphatics either in the nodules or in their neighbourhood, but mostly in the nodules themselves. The cases given above show that they are to be found quite independent of the nodules.

The important factor seems to lie in the distension of the

follicles with colloid. In all the nodules in Podbelsky's cases, possessing colloid-containing lymphatics, many largely distended follicles were present. In several instances he observed the endothelium of the lymphatics closely applied to the epithelium of the distended follicle. In three of my cases in which such lymphatics have been observed, distension of the follicles is well marked. The condition described in Case 8 lends confirmation to this view, and also points to a probable explanation of the manner in which the passage of colloid from the follicles into the lymphatic system is effected in these pathological specimens.

Be that as it may, these observations confirm the general conclusion of Podbelsky that lymphatics, containing colloid, do not occur so frequently in goitrous human thyroids as the observations on normal thyroids of the lower animals would lead one to expect. It is undoubtedly of great importance to determine if this is also a departure from the condition in normal human thyroids. Not till then can any sound conclusion be formed regarding any relationship which may be supposed to exist between the comparative absence of colloid-containing lymphatics and the distension of the follicles with colloid so frequent in goitre. It is to be hoped that Podbelsky's further researches will throw some light on this point.

My observations on the colloid (hyaline) masses, occurring in the blood-vessels, seem to disprove Gutknecht's theory of their origin from the red blood corpuscles. No elaborate series of changes has been observed in these such as he has described. On the contrary, it has been pointed out that this colloid material, whether in balls or in irregular masses, lies in the midst of quite normal red corpuscles, although sometimes in association with fibrinous coagula. It is highly probable that the changes in the red corpuscles which Gutknecht has described were due to his method of hardening his specimens. Most of his specimens were treated with alcohol, which assuredly is not well calculated to preserve the normal characters of red corpuscles.

Gutknecht goes farther, and would lead us to infer that these changes in the corpuscles are due to their presence in a diseased thyroid. No reasons have been adduced in support of this.

The frequency of the occurrence of this material in the veins and its absence in the arteries militates against the existence of any influence of this nature, and the presence of similar hyalin masses demonstrated by v. Recklinghausen in the veins of other organs is almost conclusive against it.

In truth, this is merely a local—the thyroid—part of the great question of "Hyalin" in general, and is to be brought in line with the observations of v. Recklinghausen on this subject.

He says,[1] "Hyalin in balls of various sizes, but also in the form of plates with curved-shaped, convoluted margins, &c., occurs also very frequently on the *post-mortem* clots in the veins, oftenest in those of the liver."

He has found these chiefly in cases of acute fever, and especially in infectious diseases and "dyscrasic blood changes."

Then he says,[2] "One may well regard these as a secretion of the liver cells proper, or of the cells lining the vessel wall, or of the leucocytes, because they are found even when the blood has been driven from the liver by the artificial filling of its vessels with salt solution, especially with sodium phosphate."

On other grounds he is inclined to the belief that they are mostly derived from the leucocytes. Against Langhans' theory, which is the one supported by Gutknecht, he points to the colourlessness of the balls, &c., which is present even if pigment, formed from the red corpuscles, be lying in the neighbourhood.

A reference to the cases above described shows the preponderance of febrile diseases as causes of death in those in which colloid (or hyaline) material has been observed in the veins of the thyroid. In other respects these observations support v. Recklinghausen's conclusions.

These observations were made—while carrying on another investigation on the thyroid—in the Laboratory of the Pathological Institute of the University of Strassburg, under the direction of Professor v. Recklinghausen, to whom I am indebted for much assistance and encouragement.

[1] V. Recklinghausen, *Handbuch der Allgemeine Pathologie des Kreislaufs und der Ernährung*, 1883, p. 409.
[2] *Op. cit.*, p. 409.

CONTRIBUTIONS TO THE HISTOLOGY OF THE HEDGEHOG (*ERINACEUS EUROPÆUS*). By E. W. CARLIER, M.D., B.Sc., F.R.M.S., *Senior Assistant to the Professor of Physiology in the University of Edinburgh.* (PLATE XI.)[1]

PART III. THE SKIN.

FOR the purpose of description it is convenient to divide the skin of the hedgehog into two regions—dorsal and ventral—since they differ from each other in appearance and structure; their hairs and spines, however, will be described by themselves.

THE DORSAL REGION.—The skin of this region is almost entirely hidden from view by the spines, but when these are snipped off near the roots rugæ of a dull leaden colour become visible. They are loosely attached to the subjacent tissues, so loosely indeed that when the animal is lifted by the skin one feels as if the creature were falling out of its coat. The spines are seen to spring from the depressions between the rugæ. The subepidermic tissue is found in section to be very thick and dense, and thrown into irregular folds over which the epidermis extends in an even layer. Beneath the fibrous tissue there is a cutaneous muscle of some thickness—the *panniculus carnosus.* Much adipose tissue is often accumulated beneath the muscle, especially during autumn. Sebaceous and sweat glands are entirely absent.

The Epidermic Covering is very thin and consists of only two layers, of which the *stratum corneum* appears the thicker owing to its outer cells being somewhat loosely attached and presenting a macerated appearance; it is, however, of no great thickness, especially over the rugæ, although it is slightly thicker in the intervening depressions.

The Stratum Malpighii consists of only two or three layers of small cells of the usual type, the protoplasmic bridges between them being extremely fine. Some cells of this layer

[1] Parts I. and II. appeared in the October number of this volume of the *Journal.*

occasionally contain a few granules of melanin. There is no *stratum granulosum* or *stratum lucidum* between the deep and superficial layers.

The Cutis Vera is very thick, and thrown into large, frequently compound elevations, which produce the rugosities already alluded to, but there are no papillæ of the fibrous layer indenting the epidermis. The greater part of the fibrous layer consists of large closely-packed bundles of coarse connective tissue fibres of the usual type, with many elastic fibres intermingled. Ordinary connective tissue cells are few in number, but several layers of pigment cells, to which the dark colour of the skin is due, are placed immediately below the epidermis. The dense fibrous tissue is almost entirely devoid of blood-vessels. The deeper part of the cutis is more open in texture, and contains numerous blood-vessels and nerve-trunks. In the neighbourhood of the spine follicles minute capillary vessels are arranged in dense plexuses forming minute patches of *rete mirabile.* Beneath this loose connective tissue there is the *panniculus carnosus*, consisting of striped muscle fibres similar in structure to those of the skeletal muscles.

Spine Follicles.—Each spine springs from a single large follicle which is almost hemispherical in outline and consists of dermic and epidermic layers (fig. 1, Pl. XI.): of these, the dermic are similar to those found in the hair follicles generally, with the exception of the hyaline layer which appears to be absent. The intra-follicular epidermic layers are divisible into an inner and an outer root sheath, but there are no subdivisions of the inner layer such as occurs in higher mammals. The closed extremity of the follicle is indented by a small vascular papilla (*p*, fig. 1, Pl. XI.), the epidermic cells covering which are larger than those of the remainder of the follicle, and give rise to the pith of the spine, while the cortex of the spine is derived from the cells of the inner root sheaths. A large somewhat fan-shaped *arrector pili* muscle is placed horizontally on one side of the follicle (*a*, fig. 1, Pl. XI.). Its fibres are non-striped and of large size, and are mostly attached to the adjacent side of the follicle, but a few fibres pass beneath the follicle and are inserted into its opposite side, thereby increasing the leverage of the muscle on the spine, by which it can be

completely erected. The greater part of the muscle arises from the deeper layers of the cutis. The *rete mirabile* of blood-vessels already alluded to (*r*, fig. 1, Pl. XI.) occurs near the base of the follicle, on the side opposite to the muscle. It does not seem to be directly continuous with the blood-vessels of the papilla. In the upper part of the follicle there is a narrow tubular space similar to that into which the secretion of the sebaceous glands is poured in ordinary hairs, but since no sebaceous or other glands are developed in relation to the spines this space is empty, except at its lower end where some epithelial *débris* is apt to accumulate.

I have been unable to trace any nerves passing either directly to the follicle or ending in its immediate neighbourhood, although nerve-trunks, often of considerable size, are found near its base; yet it seems probable that there must be some close relation between sensory nerve filaments and the spines, since a very slight pull or even a touch of a single spine is sufficient to cause an immediate reflex contraction of the adjacent skin.

THE VENTRAL REGION.—The skin of the ventral surface and limbs is densely clothed with rather stiff hairs, which on the flanks gradually pass into the spines. It is much thinner and less rugose than that of the dorsal surface, and contains both sweat and sebaceous glands; it is very vascular, and its deeper layers contain much adipose tissue, and the *panniculus carnosus* is not so well developed here as in the back. The epithelial covering is also very thin and forms only two layers; the horny layer never presents the macerated appearance commonly met with among the spines. The true skin is only about half as thick as that of the back, and consists of small bundles of fine fibres somewhat loosely interwoven, among which are many clasping cells; it contains a large number of fine elastic fibres and many blood-vessels ramifying throughout its whole extent, and especially grouped round the hair follicles and sweat glands. The pigment cells, so numerous in the dorsal skin, are here few in number.

The acini of sweat glands situated deep in the cutis vera resemble those of other mammals. The lumen is surrounded by a single layer of clear columnar cells, placed immediately on the basement membrane; the intervening layer of non-striped

muscle fibres being almost absent in this animal. The duct has a wavy course through the dermis, but, owing to the extreme thinness of the epidermis, there is no spiral arrangement of its outer part. It is lined by a single layer of clear cubical cells with large spherical nuclei, outside which is a basement membrane of varying thickness; the cuticular lining inside the cells is of extreme tenuity.

The hair follicles are similar in structure to those of other mammals such as the cat and dog, the inner root sheath being differentiated into the usual layers, while the *lamina vitrea* is of considerable thickness. The *arrector pili* muscle, which is rather large for the size of the hair, is attached to the follicle in the usual manner, but radiates outwards in many fine strands that spread out into a sort of reticulum enclosing the acini of numerous large sebaceous glands, identical in structure and arrangement with those of other animals.

The panniculus carnosus of the ventral surface generally resembles that of the dorsal region, but its fibres are remarkable for the large number of nuclei they contain. In some fibres the nuclei are arranged in four or five rows beneath the sarcolemma running either longitudinally or spirally along the fibres. In each row the nuclei are arranged end to end in single file. Such arrangement is similar to that in the muscle of the imago of the common blue butterfly (*Lycœna icarus*, Rott.). In other fibres of the *panniculus carnosus* there is a centrally placed core of undifferentiated protoplasm containing nuclei (*a*, fig. 2, Pl. XI.) similar to those beneath the sarcolemma. The tube of sarcous matter surrounding the core consists of the usual fibrillar bundles, which on transverse section present the familiar appearance of Cohnheim's areas. In place of the central core of undifferentiated protoplasm some fibres may exhibit single nuclei, each surrounded by a little undifferentiated protoplasm, and scattered amidst the fibrillar bundles, exactly resembling the arrangement met with in amphibian muscle (*b*, fig. 2, Pl. XI.). Such arrangement is by no means uncommon in the hedgehog, for, as has already been pointed out in a previous paper,[1] similar fibres are to be found at the root of the tongue and also in various parts of the œsophagus.

[1] See this *Journal*, vol. xxvii. pp. 90 and 92.

Thinking that similar fibres might be found in the homologous muscle in the human subject, I made sections of the platysma, but failed to find any. All the forms of fibres above described are no doubt to be regarded as ordinary muscle fibres arrested in various stages of development.

Certain reasons may, I think, be adduced to account for this difference between the skin of the dorsal and ventral surfaces. If we take into account the torpidity of the animal, the orbicular position assumed by it, and its low temperature during the period of hibernation, it will be seen that the toughness and non-vascularity of its exposed cutaneous surface becomes essential. In the first place, the animal passing the winter rolled into a ball, and in a perfectly torpid condition, from which it is with difficulty aroused, cannot escape by flight from its various enemies, but must trust entirely to the quality of its exposed dermal surface for protection, hence the development of the spines, and *toughness* of the true skin. Secondly, since the animal cannot, during hibernation, obtain fresh supplies of energising material from without, but has to depend entirely upon that which is stored in its body for the production of heat, it can ill afford to lose any by radiation, as would certainly occur if the skin were thin and vascular, and contained sweat glands; great advantage is therefore secured to the animal by a thick close skin, from which glands and blood-vessels are practically absent. As regards the ventral surface the case is different, for being with the head and limbs rolled up during hibernation within the dorsal skin, little heat will be lost by it, this loss being still further diminished by the habit which the animals have of lining their retreats with hay and of huddling themselves together in large numbers during the winter months.

Protection and prevention of loss of heat by radiation seem, therefore, to be the chief factors in determining the variations alluded to in the skin of the various parts of the hedgehog.

Hairs and Spines.—The hairs that clothe the abdominal surface of the animal are fibrous or fibro-cellular in character, the cortex being of considerable thickness compared with the medulla which presents vacuolated spaces separated from one another by thin transverse septa, some of which may, however, run obliquely or even vertically between the transverse ones

(fig. 3, Pl. XI.). In the cortex some remains of nuclei may often be met with, and the cuticle of the hair consists of the usual imbricated scales. Towards the flanks thicker hairs may be seen, somewhat rigid in character, which might almost be termed bristles. If these be examined they will be found to possess a wide medulla, the spaces in which are larger and wider than those of the hairs, and the septa between them instead of being simple are compound, often very thick and fenestrated; each septum branching again and again before becoming continuous with the cortex (fig. 4, Pl. XI.). The latter is comparatively thin and contains remains of nuclei. The tips of the bristles exactly resemble the shafts of the hairs in structure.

THE SPINES.—In his *Anatomy of Vertebrates*,[1] Sir R. Owen mentions the following points in connection with the quills of the hedgehog:—The spines are nearly straight, end in points, and when fully formed are smaller at the roots than in the shaft. They possess a thick, stiff, horny cortex, including a pith of cells arranged in transverse groups. The matrix is originally situated beneath the derm in contact with the panniculus carnosus. The roots and sheaths of the quills extend to different depths according to the period of growth, the newest deepest, and without a neck; when older they come near the surface, the pith at the neck is absorbed, leaving a narrow neck below which is a remnant of matrix.

The spines, which are striped transversely with black and white alternately, are fusiform in shape, the free extremity being sharp and hard; the shaft is nearly cylindrical, and presents 22 or 24 shallow longitudinal furrows. It narrows into a thin neck just before being inserted into the follicle already described (fig. 1, Pl. XI.); this neck is usually slightly bent, sometimes almost to a right angle, and is highly elastic; at the follicle it suddenly widens out into an almost hemispherical termination, the flat surface of which is external and caught beneath a little fold of skin; by this means the spine is firmly anchored in its follicle, so firmly indeed that the weight of the whole animal can be supported by one spine alone. Should an attempt be made to extract a spine from the living animal by great force, it will be found impossible to withdraw it whole; it invariably

[1] *Anatomy of Vertebrates*, Lond., 1868, vol. iii. p. 621.

snaps across at the neck. But after the animal has been dead for a day or two the spines may be easily extracted from the skin. In this condition they are soft enough to be cut with a razor, either by hand or in the freezing microtome, the indurated tip being the only portion that completely resists the knife. After the spine has been withdrawn for a few days it becomes so hard that it is quite impossible to section it. The curve on the neck of the spine is of great importance to the animal, as pointed out by Wood,[1] seeing that any violence applied vertically to the tip of the spine is expended in bending the neck, whereas if the spine were straight, the force might be sufficient to drive it through the skin into the subjacent tissues; therefore although great force is applied vertically to the spines when the animals throw themselves down steep rocks, &c., they do not appear to experience any injury.

A spine may be divided into three parts—cuticle, cortex, and medulla. The *cuticle* consists of a single layer of imbricated keratinised epidermic scales, which are large, irregular, plate-like structures devoid of nuclei, and which do not stain at all readily with either basic or acid anilin dyes. It extends from the bulb to the tip of the spine, dipping in at the longitudinal furrows to form a continuous outer coat. *The cortex* is very narrow, being reduced in the centre of the shaft to a mere shell, but becomes thicker towards the hard tip of the spine, of which it is the main constituent, but thins off considerably at the bulb (*c*, fig. 5, Pl. XI.). It is composed as in the hair of flat, narrow, epithelial scales, elongated in the long axis of the spine and giving a fibrous appearance. These cells and the small amount of cement substance between them often contain pigment of a dark colour. In transverse sections the cortex is seen to project inwards towards the centre of the spine at regular intervals, forming about 24 longitudinal ridges or septa, which extend the whole length of the shaft and tip, and correspond to the furrows already noticed on the external surface (*b*, fig. 6, Pl. XI.). These septa project inwards for about a fourth of the distance from the inner surface of the cortex to the centre of the spine. They may be regarded as internal buttresses giving additional strength to the structure, enabling it to support a greater weight applied vertically to the

[1] *Natural History* (second edition), Lond., 1864.

tip than a simple cylindrical sheath of cortical substance would admit of. They must also add greatly to the elasticity of the spine, preventing undue bending of it from lateral strain, and enabling it easily to recover its normal shape. The internal edges of the buttresses are not sharp but nicely rounded, often exhibiting a slight thickening, so that in transverse sections each buttress seems to end in a slightly thickened knob. The cortex as a whole stains differently with different anilin dyes, having a decided preference for the acid anilins, such as acid fuchsin, eosin, and acid orange, whilst it is only slightly stained with basic anilins, showing thereby its keratinised condition. At the root the cortex becomes continuous with the inner root sheath, and exhibits in this region a marked cellular structure; the nuclei of its cells being plainly visible when suitably stained.

The medulla is very large, occupying by far the greater part of the spine; it is thickest in the middle of the shaft, becoming gradually thinner towards the tip, from which it may be almost absent; in the neck and bulb it is also much narrower than in the shaft, and, as already pointed out, springs from the large columnar cells covering the fibrous papilla. The medulla is divided into narrow, somewhat lenticular chambers:—the *primary loculi* (l_1, fig. 5, Pl. XI.), by horizontal imperforate septa of delicate tissue; the *primary septa* (s, fig. 5, Pl. XI.), which may be simple or compound. There appears to be no communication between neighbouring primary loculi. The primary septa split into several layers when they reach the inner limits of the cortical buttresses, and these *secondary septa* (s_2, fig. 5, Pl. XI.) penetrate into the spaces between the buttresses, to become attached to the cortex. In this way a very firm attachment is obtained, and the space enclosed between neighbouring buttresses is divided into a large number of secondary horizontal chambers of triangular shape—the *secondary loculi* (l_2, fig. 5, Pl. XI.), much smaller than the primary. A very instructive view of the secondary loculi may be obtained by making a surface section of a spine (fig. 7, Pl. XI.), in which it will be seen that the secondary septa are again often split into smaller leaflets—the *tertiary septa* (s_3, figs. 5 and 7, Pl. XI.), producing a third set of minute chambers along the sides of the buttresses—the *tertiary loculi* (l_3, figs. 5 and 7, Pl. XI.).

The diagram on the opposite page represents what I believe

to be the arrangement of septa and loculi, reduced to its simplest expression.

In reality, however, the arrangement is never quite so simple, for the primary septa are often compound and enclose minute flattened cavities within their thickness; the secondary septa also spring from the primary in a somewhat irregular manner, the division sometimes occurring near the centre of the medulla causing great variation in the size of the secondary loculi, and rendering the whole arrangement of the pith very complicated (fig. 5, Pl. XI.). In the follicle the arrangement is much simpler, only the primary septa and primary loculi being distinctly developed. The septa have the form of inverted saucers inclosing narrow crescentic loculi; transitions between this and the

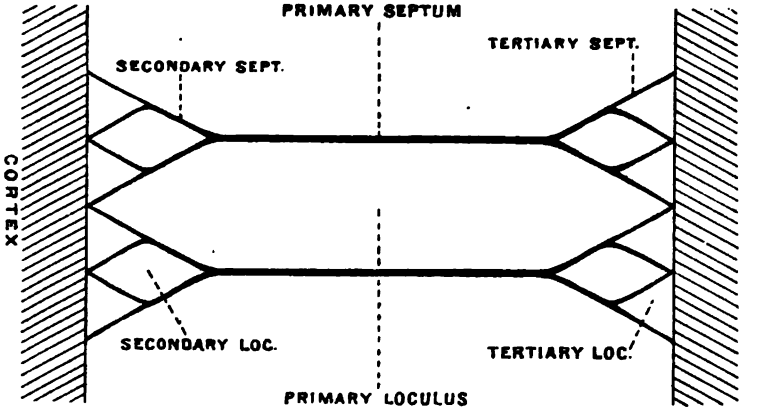

Diagrammatic representation of the arrangement of septa and loculi in the medulla of the spine.

arrangement found in the shaft may be observed where the neck widens into the body of the spine.

No doubt these strands by their numbers bind the buttresses very firmly together, and thus prevent undue separation by violent and sudden vertical strain. The septa stain deeply with basic but only feebly with acid anilin dyes. The central septa stain more deeply than the thinner marginal ones, no doubt owing to their greater thickness; their staining, however, is irregular, and thus gives a blotchy appearance (s_1, fig. 6, Pl. XI.). The secondary septa exhibit near the buttresses small deeply-stained spots,

which may possibly be the remains of nuclei (s_2, fig. 6, Pl. XI.). These spots are most conspicuously brought out by methyl blue and saffranin. All the loculi appear to contain only air.

In transverse section the centre of the spine appears either as an empty space or to be filled with a membrane, according as the section has passed through a chamber or at the level of one of the primary septa. The spaces between the buttresses always contain membrane, owing to the closeness of the tertiary septa, a portion of one or more of them always appearing in every section.

Morphology of the Spines.—From the foregoing it will be seen that the spine is morphologically a hair. Each spine springs from a simple follicle, and not from a compound or from several adjacent ones; it consists of the same elements as a hair, and is developed in a similar manner; further, a gradual transition may be traced from the hairs of the ventral surface through the bristles of the flanks to the spines of the back. For the present, owing to lack of material, I am unable to adduce any support in favour of this opinion from the embryological side, but believe that were it obtainable it would entirely confirm my view.

EXPLANATION OF PLATE XI.

FIG. 1.—Vertical section of Spine Follicle. *a*, arrector pili muscle; *c*, stratum corneum; *d*, dermis; *m*, stratum Malpighii; *n*, nerve; *p*, papilla; *p.c*, panniculus carnosus; *r*, rete mirabile; S, spine; *v*, blood-vessels.

FIG. 2.—Transverse section of two fibres of the ventral panniculus carnosus in arrested development. *a*, nuclei in tubular space in centre of fibre; *b*, nucleus amongst the fibrils; *c*, nuclei under the sarcolemma.

FIG. 3.—A hair of the ventral skin. *c*, cortex; *m*, medulla.

FIG. 4.—A bristle from the flanks. *c*, cortex; *m*, medulla divided into irregular chambers by thick vacuolated transverse septa.

FIG. 5.—Longitudinal section of Spine. *b*, buttress out of focus; *c*, cortex; *m*, medulla; l_1, primary loculus; l_2, secondary loculus; l_3, tertiary loculus; s_1, primary septum; s_2, secondary septum; s_3, tertiary septum.

FIG. 6.—Transverse section of Spine about its middle. *b*, buttress; *c*, cortex; s_1, primary septum of medulla; s_2, secondary septum.

FIG. 7.—Surface section of Spine showing the spaces between the buttresses. *b*, buttress; *c*, cortex; l_2, secondary loculus; l_3, tertiary loculus; s_2, secondary septum; s_3, tertiary septum.

FIG. 8.—Cuticle of Spine.

THE RELATION OF THE DURA MATER SURROUNDING THE INFERIOR MAXILLARY NERVE TO THE TEMPORO-MAXILLARY ARTICULATION.

By EDWARD FAWCETT, M.B. (Edin.), *Demonstrator of Anatomy, Yorkshire College, Leeds.*

THE following facts were elicited from a series of dissections of the temporo-maxillary region from above,—a method of dissection I always adopt after dissecting the orbit from the outer side.

If in the dissection the outer wall of the foramen ovale be removed, there is seen lying in the foramen a tube of dura mater, and this tube of dura mater of course contains the inferior maxillary nerve.

This dura mater having emerged from the canal, is seen to split into three parts—which may be named, from their relative position one to another, Anterior, External, and Posterior.

The *Anterior* band passes downwards and slightly forwards, and soon reaches the inner surface of the external pterygoid muscle, with whose sheath it blends and is no longer distinguishable. If this band be examined carefully and slit with a knife it will be found to contain the buccal and external pterygoidean branches of the inferior maxillary nerve.

The *External* band, when traced downwards, is seen to pass over the upper border of the outer surface of the external pterygoid muscle, and to end by sweeping round the front of the capsular ligament of the temporo-maxillary articulation and blending with it. This band contains the masseteric nerve.

The *Posterior* band passes backwards on the inner side of the condyle of the lower jaw, being directed thither by the auriculo-temporal nerve, which is seen lying in this band: having reached the inner side of the condyle this band for the most part leaves the nerve and blends with the capsular ligament of the jaw articulation.

Seeing, then, that two of these bands are attached to the capsule of the joint, we would at once suppose they would take part in any movement of that capsule, and this is the case.

The movement depends entirely on the amount of movement of the lower jaw. If the lower jaw be markedly depressed, as in yawning, the external band is carried forward with the condyle of the jaw and finally *becomes tense*, distinctly tense: elevation of the jaw following yawning consequently relaxes the band. The anterior and posterior bands also undergo considerable movement, but scarcely become tense.

UNNAMED SUPERNUMERARY NASAL CARTILAGES.

By WALKER DOWNIE, M.B., F.F.P. and S.G., *Surgeon to Department for Diseases of Throat and Nose, Western Infirmary, Glasgow, &c.*

AMONG patients who have come under my observation in hospital and elsewhere, suffering from various affections of the nose, have been three cases with a painful excoriated state of the skin around the anterior nares. The primary irritation leading to the excoriation appeared to be in each case the watery discharge accompanying an ordinary nasal catarrh, but the locality affected was in them rendered more prone to irritation than usual from a peculiar anatomical formation due to the presence of supernumerary cartilages which I have nowhere seen described. A note of their occurrence may be of interest to anatomists as well as to nasal surgeons.

The first case came under my care on 24th February 1888. Patient was a girl aged 16, who complained of pain at the inner side of each ala nasi, at which site there was a fissure a quarter of an inch in length and directed downwards, and the skin of the upper lip around the fissure was red, swollen, and tender. These parts she said were constantly tender, but the condition was greatly exaggerated during the currency of a nasal catarrh. On examination of the nose it was found that though the strip of skin dividing the two anterior nares was of an average breadth, the mucous membrane immediately within appeared greatly swollen, to such an extent in fact as to almost completely block the lower half of each anterior naris and to seriously impede nasal respiration. Each swelling, somewhat pyramidal in shape, appeared to spring from the sides of the fleshy septum in front of the anterior extremity of the cartilaginous septum, and from this base they were directed outwards and upwards towards the anterior end of the inferior turbinated bone, with which the apex of each cone-like swelling almost came into contact.

On palpation, each prominence was found to be hard, firm, and freely movable, each being separate from the other and from

the septal cartilage. The apex of each swelling was pale in colour, as if the mucous membrane was stretched over it, at which point the cartilage was most superficial. Though I had neither seen nor heard of such a deformity, I advised removal of the swellings, feeling sure that the hard bodies were cartilaginous in character and could be readily dissected out. On the 28th of the same month the patient was placed under the influence of chloroform by Dr M'Cartney, when I dissected out the hard body on either side. These proved to be two small cartilages resembling in shape, though in size somewhat smaller than the arytenoid cartilages. The base in its greatest length was ¼ of an inch, and from base to apex measured barely three lines. The parts healed satisfactorily, leaving the nasal passages free; and on seeing the patient after a considerable interval of time I learned that since the operation there had been no excoriation of the parts, even during the prevalence of a catarrhal rhinitis.

Many works containing descriptions of the anatomy of the nose were searched, but no reference to the occurrence of such supernumerary cartilages was found. Thus I was content to consider this case as an example of some very rare abnormality, and possibly due to some malformation of, probably, the inner portion of the lateral cartilage rather than of the septal cartilage. However, since the occurrence of the case described other two equally marked examples of the same condition have been under my care. One was in a woman 33 years of age, the other in a man 42 years of age. Each had excoriation of the upper lip in the neighbourhood of the nares, and there was a hack or fissure, running inwards, of the lip as it curves inwards to join the mucous membrane of the floor of the nose. On cutting down over the swellings, the hard bodies in each case proved to be cartilages very similar in form and size to those already described, and occurring in the fleshy septum, and quite apart from any of the neighbouring cartilaginous structures. In each case their removal restored free nasal respiration, and the excoriation of the skin disappeared. I have no doubt but that such cartilages occur in many cases—so small, however, as to give rise to little or no discomfort.

THIRD ANNUAL REPORT OF THE COMMITTEE OF COLLECTIVE INVESTIGATION OF THE ANATOMICAL SOCIETY OF GREAT BRITAIN AND IRELAND FOR THE YEAR 1891–92.[1] Reported by ARTHUR THOMSON, M.A., M.B., *Lecturer on Anatomy University of Oxford.*

THE following questions were issued by the Committee of Collective Investigation early in October 1891:—

1. Mode and place of origin of the middle sacral artery.
2. Frequency of the psoas parvus, and, if possible, to note the nerve-supply.
3. Arrangement of the branches arising from the arch of the aorta, with special reference to—
   (1) Origin of the brachio-cephalic and left common carotid arteries by a common trunk.
   (2) Dorsal origin of the right subclavian artery.
   (3) Origin of the left vertebral from the arch.
   (4) Other branches arising from the arch.
4. Frequency and arrangement of communication between the median (or anterior interosseous) and ulnar nerves in the forearm.

The Report compares favourably with that issued last year. Notices were sent to thirty-nine institutions, and replies have been received from nineteen. Through some mischance the notices forwarded to Charing Cross Hospital Medical School, the School of Medicine for Women, and the Middlesex Hospital Medical School were not received, and the secretary has letters from Messrs Stanley-Boyd and Gordon-Brodie, expressing regret that they have been unable to contribute to this year's report.

These facts prove that the interest in the work is still maintained, and the Committee look forward to a continuance of the support they have already received.

Subjoined is a list of the schools to which notices were sent. An asterisk is placed opposite those from which returns have been received:—

[1] The Second Annual Report appeared in the *Journal of Anatomy and Physiology*, vol. xxvi., October 1891.

*St Bartholomew's Hospital, London.
Charing Cross Hospital, London.
*St George's Hospital, London.
Guy's Hospital, London.
King's College, London.
London Hospital, London.
*St Mary's Hospital, London.
Middlesex Hospital, London.
*St Thomas' Hospital, London.
*University College, London.
*Westminster Hospital, London.
London School of Medicine for Women.
Cook's School of Anatomy.
*University of Oxford.
*University of Cambridge.
*Queen's College, Birmingham.
Bristol Medical School.
*School of Medicine, Yorkshire College, Leeds.
*School of Medicine, University College, Liverpool.
*The Owens College, Manchester.
Medical School, Firth College, Sheffield.
*University of Durham School of Medicine, Newcastle-on-Tyne.
*University of Edinburgh.
School of Medicine, Royal College of Surgeons, Edinburgh.
School of Medicine, Minto House, Edinburgh.
University College, Dundee.
School of Medicine for Women, Edinburgh.
*University of Aberdeen.
*University of Glasgow.
Anderson College, Glasgow.
St Mungo's College, Glasgow.
Western Medical School, Glasgow.
*School of Physic, Trinity College, Dublin.
Carmichael School of Medicine, Dublin.
*Catholic University School of Medicine, Dublin.
Royal College of Surgeons, Ireland.
*Queen's College, Belfast.
Queen's College, Cork.
Queen's College, Galway.

REPORT.

QUESTION I.

Mode and place of origin of the middle sacral artery.

To this question replies have been received from the following gentlemen, representing different schools:—

Messrs E. Knight, The Owens College, Manchester; G. Jamison, Trinity College, Dublin; J. Yule Mackay, University of Glasgow; J. M. Martin, University of Cambridge; W. Thelwall Thomas, University College, Liverpool; Lockhart Lowe, Queen's College, Birmingham; C. G. B. Kemp, University of Durham Medical School, Newcastle-on-Tyne; W. P. Herringham, St Bartholomew's Hospital, London; J. W. Crerar, University of Edinburgh; John Campbell, Queen's College, Belfast; H. G. Lawrence, St Mary's Hospital, London; Edward Fawcett, Yorkshire College, Leeds; F. Kenneth Wilson, Westminster Hospital, London; F. G. Parsons, St Thomas' Hospital, London; and the University of Oxford.

Records in all of 400 cases have been received, and after analysis have been arranged in nine classes, as figured A, B, C, D, E, F, G, H, I in the accompanying diagram. Appended to each figure is the number of cases noted, with, in most instances, the percentage of occurrence.

Little requires to be added in explanation of the figures, except *to note particularly that it is the posterior surface of the aorta that is represented*: this view of the vessels was adopted as being more convenient for the representation of the various modes of origin of the middle sacral artery.

Fig. A includes all those cases where the middle sacral artery took origin at a point $\frac{1}{8}$ of an inch and upwards from the bifurcation of the aorta. From the data furnished by the various observers,

20 per cent. of the instances recorded in fig. A arose at a point about $\frac{1}{8}$ of an inch or 3 mm. distant from the bifurcation.

44 per cent. at a point about $\frac{1}{4}$ of an inch or 6 mm. from the bifurcation.

30 per cent. at a point $\frac{1}{2}$ an inch or 12·5 mm. from the bifurcation; and

6 per cent. at a point $\frac{3}{4}$ of an inch or 19 mm. from the bifurcation.

Instances were also recorded where the artery arose from the parent stem as high as 1 inch or 25 mm. above the bifurcation.

Fig. B includes all those examples in which the artery arose *within* an $\frac{1}{8}$ of an inch or 3 mm. of the bifurcation. It has been very rare indeed to find the artery arising just at the point of division of the aorta, and only one case is recorded of this condition.

Fig. C includes those cases in which the middle sacral arises in common with the fourth lumbar arteries. The point of origin of this common trunk averaged about 10 mm. from the bifurcation of the aorta. As a rule, the fourth lumbar arteries are the vessels associated with the origin of the sacra media; but Mr Lockhart Lowe, of Queen's College, Birmingham, records a case in which it arose in common with the third lumbar branches. No mention is made as to whether a fourth pair was present.

In fig. D, of which we have eighteen examples, it may be noted that the origin of the sacra media is much more common from the *right* fourth lumbar than from the *left*. Compare fig. G, of which there are only 2 cases, with fig. D. On the other hand, it is interesting to note that the middle sacral artery arises more frequently from the left common iliac (fig. E) than from the right common iliac artery (fig. F).

The case represented in fig. H is recorded by Mr E. Knight, of the Owens College, Manchester; and Mr H. G. Lawrence, of St Mary's Hospital, London, gives the following details in regard to fig. I:—"The middle sacral arose $\frac{1}{2}$ an inch above the bifurcation, divided into two about $1\frac{1}{2}$ from its origin, each branch coursing laterally on either side of the sacrum."

Mr D. M. Martin, B.A., of Cambridge, records a case where three pairs of lumbar arteries arose from a common stem on the right side of the aorta, 4 cm. above its bifurcation.

Mr Lockhart Lowe, of Queen's College, Birmingham, describes a condition in which the sacra media, arising as shown in fig. C, was displaced along with the left lumbar artery to the right side, so that before it could reach its normal position it had to pass obliquely behind the right common iliac artery.

Dr Crerar, of the University of Edinburgh, in discussing the condi-

TABLE I.—*Variation in the Mode and Place of Origin of the Middle Sacral Artery. Total number of Cases examined* 400.

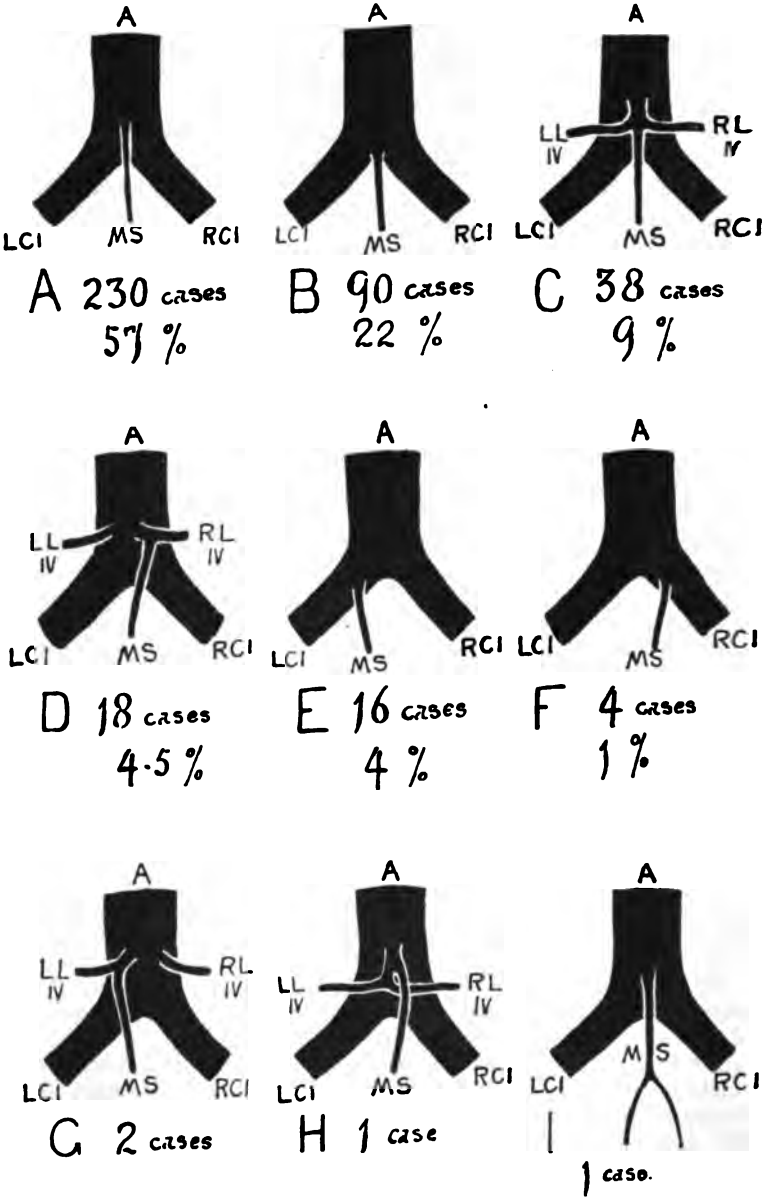

tion figured at C, writes as follows:—"In only one subject could it be said that the middle sacral artery arose by a common trunk with the lowest pair of lumbar arteries: in the majority of cases the lowest pair of lumbar arteries took origin from the middle sacral artery." Dr Crerar, however, furnishes no details as to the number of pairs of lumbar arteries in each subject.

Dr John Campbell, of the Queen's College, Belfast, in discussing the relation of the point of origin of the sacra media to the vertebral column, furnishes the following details of 21 cases examined:—

3	arose from	the aorta opposite the disc between III. and IV. L.V.
6	opposite the	upper border of the IV. L.V.
6	,,	middle of the IV. L.V.
3	,,	lower border of the IV. L.V.
1	,,	disc between IV. and V. L.V.
2	,,	upper border of V. L.V.

Dr Campbell furnishes notes that in 5 cases in which the sacra media gave off the 5th pair of lumbar arteries, the lumbar arteries of the fourth vertebra had an origin by a common trunk.

Mr F. G. Parsons, of St Thomas' Hospital, in one instance was unable to find the slightest trace of a middle sacral artery.

EXPLANATION OF TABLE I.

A., aorta.
R.C.I., right common iliac.
L.C.I., left common iliac.
M.S., middle sacral.
R.L. and L.L., right and left fourth lumbar respectively.

Some of the observers furnished details of the sex of the subjects examined; but as the information on this point is somewhat scant, it has not been thought necessary to embody it in the present report, nor do the details furnished appear to have influence on the final results.

QUESTION II.

Frequency of the psoas parvus, and, if possible, to note the nerve-supply.

The following gentlemen have contributed reports on this question:—

Messrs F. G. Parsons, St Thomas' Hospital, London; H. G. Lawrence, St Mary's Hospital, London; A. F. Dixon, Trinity College, Dublin; H. L. Sutherland, University of Aberdeen; F. K. Wilson, Westminster Hospital, London; Edward Fawcett, Yorkshire College, Leeds; John Campbell, Queen's College, Belfast; J. W. Crerar, University of Edinburgh; W. P. Herringham, St Bartholomew's Hospital, London: C. G. B. Kemps, University of Durham Medical School, Newcastle-on-Tyne; G. J. Branson, Queen's College, Birmingham; H. C. Phillips, University of Cambridge; George Lamb, University of Glasgow; D. Drew, University College, London; M. T.

Dempsey, Medical School, Catholic University, Dublin; E. Knight, The Owens College, Manchester; and A. Thomson, University of Oxford.

The general result is tabulated below, and requires no further explanation.

TABLE II.—*Frequency of occurrence of the Psoas parvus.*

Total Number of subjects examined.	Muscle absent.	Muscle present.		
457	270	187		
		Both sides. 139, or 30 per cent.	Right side. 27, or 6 per cent.	Left side. 21, or 5 per cent.
Percentage. 100	59 per cent.	41 per cent.		

Particulars were furnished regarding the sex in 174 instances. Of these, 105 were males and 69 females. The muscle appears to be more frequently absent in the female than in the male.

The percentages are as follows:—

	Male.			Female.		
Muscle absent	54	. . .		65		
„ present	46	. . .		35		
		Both sides	35		Both sides	22
		Right „	6		Right „	4
		Left „	5		Left „	9
			46			35
Total,	100			100		

The returns from the Irish and Scotch schools and the London hospitals were treated separately, with the result that the presence of the muscle was noted in 34 per cent. of the Irish returns, in 37 per cent. of the Scottish, and in 50 per cent. of the London subjects. It must, however, be borne in mind that any conclusions based on these facts are open to grave doubt, as the class from which subjects are obtained is very mixed both in Scotland and in England. The higher percentage in the London returns was noted, however, and it was thought that the fact was worth recording.

Mr C. G. Kemps describes one example of the muscle which he saw as "inserted into a fibrous band which extended from the IV. lumbar vertebra to the ilio-pectineal line."

In regard to the nerve-supply of the psoas parvus muscle, there are 108 records of its being carefully examined and traced. The subjoined list is an analysis of the returns:—

Nerve-supply of the Psoas parvus.

From the XII. dorsal nerve,	2	cases
„ loop between XII. dorsal and I. lumbar,	2	„
„ I. lumbar nerve,	36	„
„ loop between I. and II. lumbar nerves,	28	„
„ genito-crural nerve,	7	„
„ II. lumbar nerve	27	„
„ loop between the II. and III. lumbars,	6	„
	108	„

In one or two cases more than one twig passed to the muscle; these were derived from the I. and II. lumbar nerves respectively.

The nerve-supply of the muscle frequently varied on different sides of the same subject. Mr G. J. Branson, B.A., of Queen's College, Birmingham, noted the presence of a well-marked sympathetic branch joining the twig which went to the muscle from the I. lumbar nerve.

Question III.

Variation in the arrangement of the branches arising from the arch of the aorta.

In reply to this question, the Secretary has received reports from the following gentlemen:—

Messrs Montague Griffin, Trinity College, Dublin; L. S. Giles, University of Cambridge; J. Yule Mackay, University of Glasgow; Percy Fleming, University College, London; Wm. Dargan, Medical School, Catholic University, Dublin; T. T. Jeans, The Owens College, Manchester; John Campbell, Queen's College, Belfast; Edward Fawcett, Yorkshire College, Leeds; F. K. Wilson, Westminster Hospital Medical School, London; F. G. Parsons, St Thomas' Hospital Medical School, London; W. P. Herringham, St Bartholomew's Hospital Medical School, London; C. K. Bryant, University of Durham Medical School, Newcastle-on-Tyne; Lockhart Lowe, Queen's College, Birmingham; G. H. Clarkson, St George's Hospital Medical School, London; W. T. Thomas, University College, Liverpool; J. W. Crerar, University of Edinburgh; H. L. Sutherland, University of Aberdeen; A. Thomson, University of Oxford.

The arrangement of the branches of the arch of the aorta was noted in 500 cases, and, as a result of the inspection of the returns, the varieties have been grouped in 8 classes figured A, B, C, D, E, F, G, and H respectively in the accompanying diagram. The condition described as normal occurs in 82 per cent. of the cases examined, though here considerable variation is noted in the distance between the origins of the arterial trunks as they spring from the parent stem.

In Class B the length of the trunk common to the right subclavian, right common carotid, and left common carotid varied in length from zero to 1¼ inches. The average length, however, did not exceed ½ an inch.

In Class C the left vertebral artery was seen entering the vertebr-arterial foramen in the IV. cervical vertebra in two cases—the V.

in 4, and the VI. in 1: the fact was noted that in several instances it was joined by an accessory branch from the left subclavian.

No remarks are necessary in regard to Classes D, E, and F: the diagrams sufficiently explain themselves.

The examples represented in figures G and H were exhibited at a meeting of the Anatomical Society by Mr F. C. Abbott, of St Thomas' Hospital, and a detailed description of them will be found in the *Proceedings of Anat. Soc. of Great Britain and Ireland* for Feb. 1892.

Appended are some notes by the individual observers:—

Mr Montague Griffin, M.B., of Trinity College, Dublin, notes two cases in which the brachio-cephalic trunk arose from the ascending part of the arch and passed vertically upwards parallel to and to the right side of the trachea, whilst the left common carotid arose from the most anterior part of the transverse arch and passed obliquely upward and to the left, crossing the trachea in the middle line. In the first subject this point was $1\frac{1}{3}$ inches, in the second $1\frac{1}{4}$ inches above the level of the arch.

Mr L. S. Giles, B.A., University of Cambridge, notes the occurrence of a large vas vasorum to the pulmonary artery in one instance.

Dr Herringham, of St Bartholomew's Hospital, records a case where the left vertebral arose from the left common carotid $\frac{5}{8}$ of an inch above its origin.

Mr C. H. Bryant, of the Medical School, Newcastle-on-Tyne, mentions an instance, in a female subject, of a left bronchial artery springing from the posterior part of the arch, close to the ductus arteriosus; in three other subjects, bronchial and mediastinal branches were seen arising from the descending part of the arch; and four cases are recorded of the origin of the thyroidea ima from the innominate artery.

Mr G. A. Clarkson, of St George's Hospital, London, in his account of a case of root-origin of the right subclavian classed in Group D, gives the following details:—

"The artery (right subclavian) arose from the posterior aspect of the descending part of the aortic arch $\frac{1}{2}$ an inch below the origin of the left subclavian . . . . its length from origin to the first branch (vertebral) was 3 inches . . . . . the ductus arteriosus was pervious, and the inferior laryngeal nerve was not recurrent."

Mr W. Thelwall Thomas, F.R.C.S., of University College, Liverpool, describes a large mediastinal branch which arose from the front of the arch between the innominate and left common carotid arteries, and coursed downwards in the fat of the mediastinum for $4\frac{1}{2}$ inches.

Dr Crerar, of the University of Edinburgh, also mentions a case in which a bronchial artery arose from the back of the arch, just below the origin of the left subclavian.

The figures in Table III. are lettered as follows:—

R.S., Right subclavian.
R.C.C., Right common carotid.
L.C.C., Left common carotid.
L.S., Left subclavian.
L.V., Left vertebral.
R.V., Right vertebral.
T.I., Thyroidea ima.

TABLE III.—[illegible]

Total number examined 500.

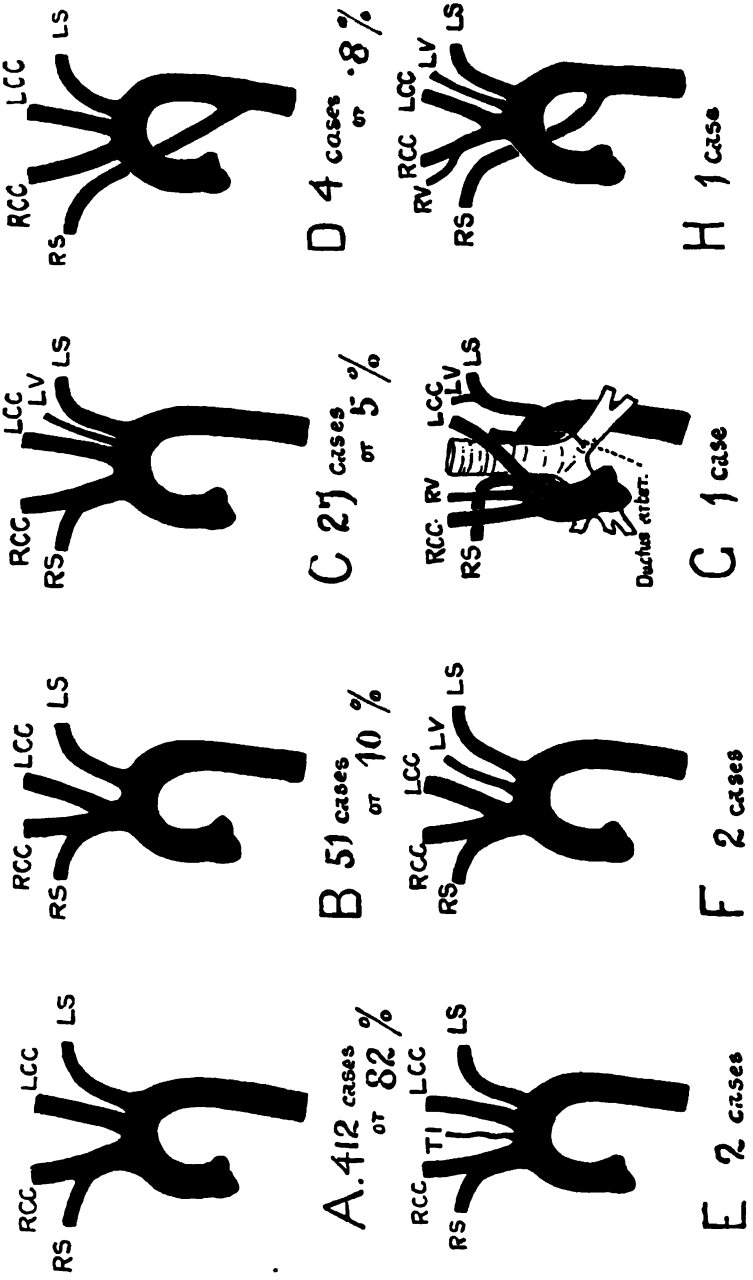

In each figure the number of such cases met with is recorded, and the percentage of occurrence given.

QUESTION IV.

Frequency and arrangement of communication between the median (or anterior interosseous) and ulnar nerves in the forearm.

The answers to this question were not so numerous as to the others. The difficulties of observation were no doubt greater, but notwithstanding reports have been received which yield a total of 406 forearms examined.

The gentlemen to whose assistance we are indebted are—

Messrs Richard Smith, Trinity College, Dublin; T. T. Jeans, The Owens College, Manchester; A. K. Gordon, University of Cambridge; P. J. Fagan, Medical School, Catholic University, Dublin; John Campbell, Queen's College, Belfast; J. W. Crerar, University of Edinburgh; W. T. M. Whitling, University of Durham Medical School, Newcastle-on-Tyne; H. L. Sutherland, University of Aberdeen; and A. Thomson, University of Oxford.

Out of 406 forearms examined a communicating branch was noted in 63 instances, or about 15 per cent.

The results are classified into four varieties.

Class I., of which 33 examples were noted out of the 406 cases examined, yielding a percentage of occurrence of 8 cases per hundred, was as follows:—The branch of communication which arose from the *anterior interosseous* at a point varying from the commencement of that nerve to a spot 2½ inches down its trunk, coursed downwards with a varying degree of obliquity and lay behind the ulnar artery, resting on the flexor profundus digitorum and being crossed superficially by the muscles springing from the internal condyle, with the exception of the flexor carpi ulnaris: it usually joined the ulnar nerve at a point corresponding to the junction of the upper and middle thirds of the forearm.

Class II., of which, out of the total of 406 cases examined, there were 12 instances recorded, or an average of about 3 per cent., differed from Class I. only in the fact that the communicating branch arose directly from the *median* in place of the *anterior interosseous*, otherwise its course and relations were the same, except in one instance recorded by Mr A. K. Gordon, B.A., of Cambridge University, in which case the ulnar artery lay *behind* the nerve in place of in front, as described in Class I.

Class III. includes 16 cases out of the total of 406, or rather under 4 per cent., in which the communicating branch was formed by a junction between the filaments of nerve supplying the flexor profundus digitorum: in this way a loop was formed which underlay the ulnar artery, the convexity of which was directed downwards.

Appended is Mr P. J. Fagan's description of this condition as observed in the cases reported by him. Mr Fagan writes:—

"In seeking for communications between the ulnar and median

nerves, I observed the following method as far as possible. Before the forearm had been dissected, I cut the anterior head of the flexor carpi ulnaris, and traced the branches of the ulnar nerve lying on the flexor profundus digitorum. I then traced the offsets of the median to the ulnar artery; and at a later stage in the dissection, noted the lower part of the ulnar. In all, I collected 17 examples. In four instances I failed to find any communication; in the remaining thirteen, communications were established. There were few variations, the usual arrangement being, a twig from the ulnar lying on the flexor profundus digitorum ran to the posterior aspect of the ulnar artery, and, at that place, anastomosed with a twig from the median. When traced with a little care the plan of the nerves proved to be this:—As soon as the ulnar had passed between the heads of the flexor carpi ulnaris it gave off a slender branch, which ran downwards and outwards on the flexor profundus digitorum muscle, to which it furnished a small twig, and then beneath the ulnar artery, where it joined the branch from the median. The branch from the median, in some cases, emerged from the substance of the flexor sublimis digitorum; in others, it came under that muscle. It usually divided into two twigs: one entered the flexor profundus digitorum, the other joined the ulnar twig, forming an arch with its convexity downwards. From this arch a varying number of twigs arose. In two cases the number was three: two short, entering the muscle almost immediately; one long, arising by two heads, and extending as low down as midway between the elbow and wrist, where it supplied the part of the muscle for the middle and ring fingers. In one case where the usual communication did not obtain, I found a very large branch low down coming from the ulnar to the median.

"On the whole, I am inclined to think that the variations in the twigs depended rather on the condition in which I found the part than on the actual state of affairs, and that the usual arrangement is for the ulnar alone to supply that part of the flexor profundus destined for the little finger; the median, the part for the index finger; and the arch formed by the ulnar and median, the remaining two fingers."

Class IV. includes only 2 examples out of a total of 406. These cases which came under the notice of Mr T. T. Jeans, of the Owens College, Manchester, are thus described by him:—"The communication was by a superficial branch which left the median at the bend of the elbow, passed across the muscles rising from the internal condyle (except the flexor carpi ulnaris), and joined the ulnar nerve in the lower third of the forearm.

The results may be summarised as follows:—

Total number of cases examined, 406.

Class I.

Communication between anterior interosseous and ulnar	33, or 8 per cent.

Class II.

Communication between median and ulnar trunks	12, or 3 „

Class III.	
Communication between muscular twigs to flexor profundus . . .	16, or 4 per cent.
Class IV.	
Communication by means of a superficial branch	2, „ „
Total, . . .	63, or 15 per cent.

Some extracts from the reports are added.

Mr T. T. Jeans, of The Owens College, reports that he only saw the communication between the anterior interosseous and ulnar nerves in both arms of the same subject in one instance, a female.

Dr John Campbell, of the Queen's College, Belfast, mentions a case in which the slender communication joined the ulnar palmar cutaneous branch, and describes, in three of the instances recorded, how the communicating twig from the median trunk arose in connection with its muscular offsets, pierced the flexor sublimis digitorum, and joined the ulnar nerve in his upper third of the foramen.

In 5 of the subjects examined by Dr Crerar, of Edinburgh University, the communication was present on both sides. In one case the communication took place in the fibres of the flexor sublimis digitorum. The communicating branch varied in size from the thickness of thread to that of small whipcord, and in length from 3 to 9 cm. In one of the subjects examined a twig was given off from the branches of the ulnar nerve to the flexor profundus, which, passing behind the ulnar artery, did not communicate with the anterior interosseous nerve, but recurved over the artery, to be distributed to the flexor sublimis digitorum near the internal condyle of the humerus. From this twig a small condylar muscular branch of the flexor profundus received a branch of supply in addition to a larger one which it received from the anterior interosseous nerve.

Dr Crerar concludes by stating that Professor Sir W. Turner has recorded a case of supply of the flexor sublimis digitorum by two twigs from the ulnar nerve (*Nat. Hist. Rev.*, 1864).

In conclusion, the Committee desire to place on record their sincere thanks to those gentlemen who have so kindly assisted them in the publication of the present report.

The Secretary will at all times be pleased to receive suggestions with regard to subjects for future inquiry. Communications may be addressed to him at the Department of Human Anatomy, Museum, Oxford.

ON THE GASTRIC DIGESTION OF PROTEIDS. By A. LOCKHART GILLESPIE, M.D., F.R.C.P.E., *Medical Registrar, Edinburgh Royal Infirmary.*

THE following paper has been partly extracted from a thesis presented to the University of Edinburgh for the degree of M.D. in August 1892, and for which a gold medal was awarded to the author. A summary of the results was read before the Biological Section of the British Association for the Advancement of Science (Edinburgh meeting) in the same month, of which very condensed abstracts were printed in the *Proceedings* of the Association and in the *Medical Press and Circular.* The experiments on which the observations rest were performed in the Laboratory of the Royal College of Physicians, Edinburgh, and to the Laboratory Committee of the College my best thanks are due for the liberality displayed to me, and particularly to the Superintendent, Dr Noël Paton, for his ready help when I happened to be in difficulties.

My object throughout has been to endeavour to elucidate some of the problems presented by the gastric digestion of proteids. A great part, therefore, of my work has been directed towards the relations between hydrochloric acid and proteid substances.

That some kind of combination could exist between this acid and proteids has been known for some time. Danilewsky,[1] Richet,[2] Leo,[3] and Ewald[4] have demonstrated its existence, and more lately Hayem[5] and Winter have placed the subject on a more satisfactory footing.

I have elsewhere[6] called the combinations between HCl and proteids Proteid-hydrochlorides, and this term I shall continue to use throughout this paper.

[1] *Centralblatt für med. Wissenschaft*, 1888.
[2] Sur le suc gastrique chez l'homme et les animaux, 1878.
[3] *Centralblatt für med. Wissenschaft*, 1889.
[4] *Virchow Archiv*, xc., ci., civ.
[5] Du chimisme Stomacale, 1891.
[6] *Medical Press and Circular*, August 1892.

Methods.

I must in the first place briefly note the methods I employed in my experiments. The total acidity of any solution was estimated in the ordinary way by means of a decinormal solution of NaOH; and an alcoholic solution of phenolphthalein. The results were all calculated out in terms of HCl. The amount of the combined acidity in a specimen was arrived at by estimating its acidity before and after evaporation at 100° Cent. If an aqueous solution of HCl be evaporated in an evaporating dish for a sufficient time none remains, but if albumen be added to it beforehand, no matter how long the heat be applied, some hydrochloric acid remains behind. Hayem and Winter's method of applying this fact to the determination of the different forms of acidity is more accurate than mine, but much more elaborate. They worked with chlorine alone, they estimated the total chlorine by means of chromate of potash and silver nitrate, after adding to the solution to be tested carbonate of soda, to transform all the chlorine into NaCl, and by fusing this, to burn off the proteids. The chlorine combined with proteids was calculated by a similar procedure after the solution had been dried at 100° for some hours, the chlorine originally fixed to bases, &c., having been calculated beforehand, by simple incineration of another quantity of the fluid, and then subtracted. The chlorine combined with proteids and the fixed chlorine together when subtracted from the total chlorine, gave the free chlorine or HCl. In the following pages, when the chlorine was estimated, this process was made use of. It is, however, long, troublesome, and in the many incinerations a small quantity of chlorine is undoubtedly lost. If carefully done it is suitable for laboratory work; for practice it is too cumbersome. Simple estimation of the acidity before and after evaporation for some hours at 100° or 110° is, to my mind, sufficient for most practical purposes.

The different proteids were separated from each other in the usual way. The albumoses from peptone by saturation with ammonium sulphate when warm, after the addition of a small quantity of acetic acid. The different albumoses from one another by saturation with NaCl and dialysis. Albumen was procured almost pure from white of egg, the globulin being first precipitated by copious dilution with distilled water, the salts in some cases dialysed off, and the solution dried at 40° Cent. in large open dishes. The fibrous tissue had been previously got rid of by shaking up the white of egg with broken glass and filtering.

Other matters regarding methods used are explained in the text.

The Functions of the Stomach.

Czerny's dog lived for several years without a stomach, and to all appearance suffered little inconvenience. Personally, I should not like to do without this organ, but I have little

doubt that if I fed as moderately and as simply as a laboratory dog, I would suffer little from the want. As it was proved, therefore, that the stomach was not indispensable to the organism as an agent for digesting food, an idea which was long and widely entertained, some other theory had to be framed to account for its rôle in the animal economy. It was allotted purely an antiseptic function—it was styled the Cerberus of the digestive tract: past it, in health, only the most resistive and least poisonous organisms could pass. Against this view, however, is the fact that Nature or Evolution has given the stomach a reagent which is largely antagonised in its antiseptic action by that very kind of food which it is mainly capable of digesting; in other words, proteids act as Cerberus's sop. Another function which may be attributed to the stomach is the bringing of foods to a proper consistency before ejecting them into the duodenum, excess of fluid is absorbed, deficiency made good. Witness the state of the gastric contents after a meal of pure porridge, with no fluid added,—in a short time the contents are much diluted; while, on the other hand, if a large quantity of fluid be taken as well, the consistence of the food at the end of a similar time is almost identical.

The stomach is useful also in mixing and subdividing the food, and thus, in allowing no large and irritating masses to enter the duodenum, it allows animals to take a large meal without discomfort; for without such a receptacle, men and animals would always have to be eating, leaving no time for other pursuits. Lastly, the amylolytic action of the saliva is checked. The attempted allocation of one supreme function to the stomach is, I believe, foredoomed to failure. It can do many things well, or perhaps I might say, fairly well, a wise instance surely of the law of conservation of energy so often manifested elsewhere in nature.

The Affinity of Proteids for Hydrochloric Acid.

If some albumen—it matters not whether serum or egg albumen—be dissolved in water, the solution placed inside a parchment tube, and the tube immersed in a solution of hydrochloric acid in water, in time, after a few hours, the fluid inside

will be found to be more acid than that outside. That this is not due simply to the higher specific gravity of the fluid inside, is shown by the fact that if a solution of sugar or other carbohydrate be substituted for that of the proteid, the acidities in and out become equal. Any other proteid has the same effect as albumen. HCl, then, has an affinity for proteids.

Now, if the tube containing the albumen and acid be removed from the acid solution and placed in a beaker containing water, much of the acid dialyses out again, and in time, if the water be changed often enough, all may be removed. The affinity of the acid for proteids is weak, and may be overcome by the action of dialysis into pure water. This is shown by the following experiment.

Experiment I.

A neutral solution of proteids of unknown strength was placed inside the tube of a dialyser, the tube immersed in a ·612 per cent. solution of HCl; in two and a half hours the acidity inside was ·432 per cent. and in twenty-four hours ·684 per cent. Distilled water was then substituted for the hydrochloric acid outside; in two and a half hours the acidity of the proteid solution was ·468 per cent., and in twenty-four hours ·09 per cent. That is to say, that most of the acid had dialysed out, but a residue remained. This residue gave none of the tests for free HCl.

On subjecting this to the further action of dialysis into distilled water all traces of acidity disappeared in forty-eight hours.

Again, if the acid be in large proportion as compared with the proteid, and the contents of the tube are analysed after dialysis of the acid to the inside, we find the acid to be in two forms—acid which is free and acid which is organically combined. On estimation of the free acidity also, less free acid is found inside than there had been outside before removal of the parchment tube with its contents, but the sum of the combined and free acidity inside always exceeds the total acidity outside. That is to say, that HCl organically combined, even if it be in excess, does not hinder the further dialysis of free HCl. This point is of importance in artificial gastric digestion by means of a dialyser, and also in natural digestion. It is clearly shown in the following dialyser experiments.

Experiment II.

A solution containing beef bouillon, gelatine, and egg albumen

was placed inside a parchment tube, and this suspended in a ·036 per cent. solution of HCl. In two and a quarter hours the solution inside, which had been almost neutral, had an acidity of ·324 per cent., or nearly ten times that out, of this only ·027 per cent. was free.

Experiment III.

In this the fluid inside was a little more dilute; and although the solution outside was as high as ·198 per cent. in acidity, the acidity inside never rose above ·288 per cent., or less than in the last experiment when the acidity outside was only ·036 per cent. When the acidity in this experiment was at its height only ·09 per cent. was free.

Properties of a Proteid-hydrochloride.

If a certain quantity of hydrochloric acid, say 5 grammes, be added to 100 grammes of egg albumen, and the resulting mixture tested, no free HCl can be found. That is to say, a drop of the resulting solution strikes no scarlet colour with Günzberg's vanillin-phloroglucin, with Boas' resorcin, with Möhr's sulphocyanide reagent. On testing it by Sjoquist's process, or by Leo's or Mintz', no free HCl is shown. And again, on drying some of the solution on a water bath for a couple of hours or so, no change in acidity occurs on redissolving the dry residue in distilled water and titrating with soda. On the other hand, if a simple solution of HCl in water be evaporated for the same length of time, no trace of acid is left.

This combination of hydrochloric acid with albumen is therefore not destroyed by a heat of 100° Cent., and does not give any reaction when treated with the aniline reagents commonly used for the identification of free mineral acids. It has, however, the same or almost the same acid value as the original HCl; or to put it otherwise, HCl combined to proteids neutralises the same quantity of decinormal soda solution as it does when it is in a free state.

Experiment IV.

3 ccms. of a solution of egg albumen (·3465 grm.) were added to 15 ccms. of a ·2304 per cent. HCl solution (·0345·6 grm.).

The mixture was tested with Günzberg's reagent, and no free HCl found. That is, 9·98 per cent. of acid had combined with the albumen; the acidity, however, was ·192 per cent., or equal to that before.

1 ccm. more was added (·002304 grm.); free HCl was present with 10·6 per cent. of acid.

Experimemt V. Performed in the same manner.

1.	2 ccms.	albumen	solution	= ·23	gramme	+ 13 ccs.	·18	per cent.	HCl.
2.	2 ,,	,,	,,	= ·23	,,	+ 7 ,,	·342	,,	HCl.
3.	2 ,,	,,	,,	= ·23	,,	+ 50 ,,	·045	,,	HCl.
4.	5 ,,	,,	,,	= ·575	,,	+ 9 ,,	·342	,,	HCl.

The results were :—

1. 10·17 per cent. of acid, free HCl present.
2. 10·4 ,, ,, ,,
3. 9·18 ,, free HCl absent.
4. 5·34 ,, ,, ,,

Acidity of Nos. 3 and 4 were ·044 per cent. and ·219 per cent. respectively.

It is more difficult to arrive at the exact amounts of each when both free and combined hydrochloric acid are present in the same solution. Drying a few cubic centimetres at 100° Cent. drives off the free HCl; but the charring of the proteid, and the resolution of some of it into simpler forms, one of which has a violet colour (Liebermann's reaction for free HCl), tend to vitiate the results. Adding, drop by drop, a decinormal solution of sodium hydrate until the fluid tested ceases to give any reaction with vanillin-phloroglucin is also fallacious, as some of the combined acidity is affected as well as, and at the same time as, the free. Neutralisation of the free HCl with carbonate of barium, which is said not to affect the combined acid, gives better results, but the process is tedious. On the whole, I prefer drying the fluid at 100° and then titrating again: the difference between the total acidity and the acidity left after drying gives the free HCl, and the fallacy present is constant and very small, the free acidity in fact being always slightly too great, the combined slightly too small.

Although this combined acid is equal quantitatively to the original free HCl, it has not retained any of the other properties of the free acid in the same proportions. For, as I have said above, it does not give any of the common reactions for the free acids, but on investigating its action further I find that its antiseptic property is very slight. I have grown the *Staphylococcus pyogenes aureus* in a ·68 per cent. solution of combined HCl,[1] while the amylolytic action of saliva goes on in a solution of combined acidity double the strength of that necessary, if the acids were free, to destroy the ferment.

[1] *Journal of Pathology*, 1892.

This last fact is of interest with regard to the previous work which has been done on the subject. For instance, Chittenden and Ely[1] found that ·05 per cent. HCl if added to saliva rather increased its action on starch. Astachewsky[2] affirms the same. Langley[3] worked at the subject and found the following facts:—

Ptyalin is destroyed by solution of HCl above ·005 per cent.
" " $NaCO_3$ above ·5 "

—while the same author, when working with Eves,[4] found that ·0015 per cent. HCl distinctly diminishes the action: he got best results from saliva which was absolutely neutral.

Experiment VI.

Some starch paste was made of a strength of 1·5 per cent. I collected 15 ccms. of my own saliva and filtered it. The alkalinity was not tested. A solution of proteid hydrochlorides was also made by addition of proteid material, albumen, and albumoses to a solution of HCl until no free HCl remained. The acidity of this solution was ·504 per cent.

The details are as follows:—In seven flasks were placed—

5 cc. of starch and 1 cc. of saliva +	2 ccs.	HCl ·504	per cent.	combined.
	2 "	HCl ·252	"	"
	2 "	HCl ·144	"	free.
	2 "	HCl ·072	"	"
	2 "	HCl ·126	"	combined.
	2 "	HCl ·063	"	"
	2 "	water.		

That is to say, that there was in the flasks—

1.	·01008 gr.	HCl or	·126	per cent.	all combined.
2.	·00584 "	HCl "	·063	"	"
3.	·00288 "	HCl "	·036	"	mostly free.
4.	·00144 "	HCl "	·018	"	"
5.	·00252 "	HCl "	·0318	"	all combined.
6.	·00126 "	HCl "	·01575	"	"
7.	·00000 "	HCl "	·0		

The flasks were put in a hot air chamber and kept at 38° Cent. for half an hour. The contents of each was then tested with Fehling's solution, and with iodine and iodide of potash.

1.	No sugar,	Blue with iodine.
2.	"	"
3.	"	"
4.	"	"
5.	Trace of sugar,	Slight violet tinge.
6.	Sugar present,	Decided violet.
7.	"	Red violet.

[1] *Journal of Physiology*, vol. iii., and in *American Chem. Journal*, vol. iii. 305.
[2] *Centralblatt für med. Wissenschaft*, 1878.
[3] *Journal of Physiology*, iii. p. 246.
[4] *Journal of Physiology*, iv. p. 18.

It is clear, then, that although the addition of ·018 per cent. of free HCl was sufficient to stop the amylolytic action of the salivary ferment, ·0318 per cent. of the combined acid only checked it, while ·01575 per cent. had little effect.

As the hydrochloric acid in the stomach at the commencement of digestion of a proteid meal is entirely combined, it is obvious that the continuation of the amylolytic action of the salivary ferment is possible for a short time.

Forms of Proteid-hydrochloride.

All the reactions mentioned above may occur in the absence of pepsine, when acid and proteid are simply brought together. The amount of acid taken up by the albumen under these circumstances is nearly constant,—some variation, however, being observed in direct proportion to the strength of acid solution used. Without pepsine, hydrochloric acid combines with albumen only up to the proportion required to form acid albumen: the proportion may be less than that required, but never more, unless we look on the charring effect of strong acid as primarily a combination. This acid, nevertheless, though now combined, is still able to act further on the proteid if pepsine be added to the solution. For, if pepsine be added to a mixture of HCl and albumen, part of which is acid albumen and part serum albumen, but in which there is no free HCl present, further and simpler proteid bodies are formed, but only to a limited extent, and then at the expense of some of the acid albumen, which perhaps may become serum albumen again.

Hydrochloric acid combining with proteids in the absence of pepsine can saturate the molecules, but cannot split them further.

Experiment VII. illustrates this fact, and will also serve as a text for further observations on the action of HCl on proteids in the presence of pepsine.

A solution of egg albumen, of which 9 ccs. contained 1 grm., was used, to which solution hydrochloric acid in varying strengths was added. All the figures in the tables have been corrected for ash.

The quantities were as follows :—

1.	2	grms. albumen	·38528	grm. HCl	86	ccs. in all,	·448	per cent. acidity.
2.	1·98	,,	·24948	,,	66	,,	·378	,,
3.	1·96	,,	·08424	,,	36	,,	·234	,,
4.	1·96	,,	·08424	,,	36	,,	·234	,,

After three hours at 38° Cent. the condition of the acid was tested with regard to whether it was present in the free state or not.

Condition of the hydrochloric acid in the above fluids.

No.	Total Acidity per cent.	Combined Acidity		Free Acidity		Liebermann's Reaction.
		per cent.	HCl in grms.	per cent.	HCl in grms.	
1	·448	·27	·2322	·178	·15308	+
2	·378	·252	·15448	·126	·095	+
3	·234	·234	·08424	...	...	...
4	·234	·234	·08424	...	...	...

Percentages of combined HCl to proteid present.

No.	Total Proteid in grms.	Combined Acidity in grms.	Percentage.
1	2	·2322	11·61
2	1·98	·15448	7·8
3	1·96	·08424	4·29
4	1·96	·08424	4·29

The exact amounts of the solutions figured in the first of these tables were now poured into dialyser tubes, and 150 ccms. of distilled water placed round each.

To Nos. 2 and 3 ·054 grm. of pepsine was added.

The four beakers with their contents were now placed in an incubator at 38° Cent. In six hours the amounts of the proteids and the acidities were again estimated.

Acidities after six hours' dialysis.

No.	Amount in ccms.	Total Acidity		Combined Acidity		Free HCl		Liebermann's Reaction.
		per cent.	in grms.	per cent.	in grms.	per cent.	in grms.	
a. Inside.								
1	91	·216	·19656	·198	·18018	·018	·01638	+
2	75	·2052	·1539	·2052	·1539	...	...	...
3	50	·126	·063	·126	·063	...	...	...
4	46	·144	·06624	·144	·06624	...	...	...
b. Outside.								
1	141	·108	·1522	·02119	·029888	·0868	·1224	+
2	130	·082	·1066	·07759	·10087	·00441	·00573	+
3	130	·216	·02808	·0216	·02808	...	...	...
4	136	·0072	·009792	·002104	·002862	·00693	·00942	+

Proteids after six hours' dialysis.

No.	Albumen.	Acid Albumen.	Albumose.	Peptones and Extractives.	Total.
a. Inside.					
1	·0	1·8564	trace	·02073	1·87713
2	·12	·245	·28	·8036	1·4486
3	·851	·42	·101	·29922	1·67122
4	1·0948	·7314	trace	·0404	1·8666
b. Outside.					
1	...	...	trace	·12287	·12287
2	...	...	·076	·4754	·5514
3	...	...	·018	·291876	·309876
4	...	...	trace	·0934	·0934

Total proteids or organic solids recovered in grams.

No.	Inside.	Outside.	Total.
1	1·87713	·12287	2
2	1·4486	·5514	1·99
3	1·67122	·309876	1·981096
4	1·8666	·0934	1·96

Total solids and ash found outside.

No.	Total Solids.	Ash.	Organic Solids.
1	·196698	·073814	·122884
2	·63	·0786	·5514
3	·38369	·073814	·309876
4	·1672	·0738	·0934

This is a long and seemingly complicated experiment. Careful study, however, soon unravels its intricacies.

The result of No. 1 is as follows: originally albumen with excess of HCl, finally acid albumen with a small quantity of diffusible organic material and still an excess of free acid.

In No. 2 there was also originally an excess of HCl, amounting, however, to only ·095; judging from the previous example, however, as there was some free acid present, all the albumen would be in the form of acid albumen. On the addition of

pepsine, there is a marked change in the results, no free acid inside, only a trace outside, while some of the albumen can be recovered unchanged. The other varieties of proteids are also present, with an appreciable amount of albumose (deutero) outside. At the end of the experiment only ·0053 grm. of free HCl was available, at the beginning there was ·095: ·0897 gr., therefore, have been required to perform the work indicated by the amounts of the lower proteids.

In No. 3, although the HCl added at the beginning was all combined to proteids, the addition of pepsine to this enabled a further digestion. The dialysis, though, of peptones prevented the presence of free acid outside.

In No. 4, under the same circumstances, but without the presence of pepsine, a small quantity of organic material was lost in some way, but the proportion of acid albumen to albumen is instructive, as indicative of the energy of HCl. The presence of free HCl outside is explained by the power which simple dialysis has of separating HCl from proteids.

If the details of the experiment be more broadly considered, it will be seen that in Nos. 1 and 2 the diminution of free HCl at the end of the experiment was ·0143 gr. and ·0897 gr. respectively, the sole difference in the working being the addition of pepsine. The decrease in free HCl is proportionate to the increase of simpler proteid forms. Throughout Nos. 3 and 4 digestion has gone on in the absence of free HCl, and it also follows that the addition of a very small quantity of free HCl and a little pepsine to a mixture of albumen and acid albumen, which contains no free acid, results not in more acid albumen, but in the splitting up of this proteid into peptones and albumoses. The amount of albumen remains the same, or even increases. This is also seen in the case of No. 2, where, although all the albumen had probably been converted into acid albumen before the pepsine was added, yet after further digestion some albumen could again be separated.

On the other hand, HCl combined with proteids during an act of digestion, and therefore in the presence of pepsine, is incapable of further action; and if all the acid be so combined, digestion will not proceed until further free acid be added. In the combination of the acid with the proteid without pepsine,

potential energy is stored up ready to split up the molecules of albumen or albumose—for HCl combines with all proteids in a similar way—when further action is facilitated by the addition of pepsine.

For it is not to albumen alone that HCl unites. If to a solution of proto-albumose hydrochloric acid be added, a compound with or a hydrochloride of proto-albumose is formed, but it is not until pepsine is added that this albumose can be changed into deutero-albumose or into peptone. Hydrochloric acid is able in the presence of pepsine to over-saturate and thereby to split up proteid molecules.

Mode of Digestion of Proteids.

These observations suggest a simple way of explaining the course of the gastric digestion of proteids. Suppose that I have, to begin with, some serum albumen in solution in the tube of a dialyser, to which I add a few grains of pepsine and surround it with a weak solution of hydrochloric acid, the whole apparatus being kept at 40° Cent. As the molecules of the acid dialyse through the membrane they combine with molecules of the albumen. The albumen molecules are so large that in all probability more than one molecule of HCl is required to unite with each to form acid albumen. There may be, therefore, an intermediate stage, in which acid is combined to albumen, but no acid albumen has yet been formed. When some of the albumen molecules have been transformed into acid albumen, and while free HCl is still dialysing through the membrane, more acid combines with the acid albumen, and in the presence of pepsine this combination affords sufficient energy to split up the larger molecule into two smaller ones, each of which can unite with a larger proportion of acid than its parent. We have now got to proto-albumose, and the same applies to the splitting of this into deutero, and of deutero albumose into peptone.

How does this theory accord with fact? Fairly well. Previous observers have investigated the subject.

Danilewski[1] was the first who tried to estimate the exact amount of acid which combined with proteids, coming to the conclusion that

[1] *Centralblatt für med. Wissenschaft*, 1888.

10 to 12 parts of HCl were taken up by 100 parts of proteid material. Ewald[1] supported his conclusion, while Herth,[2] working in Maly's laboratory, found that the hemialbumoses took up HCl with avidity. Moritz[3] gives 8 to 12 parts of albuminates to 1 part of HCl. Pfungen,[4] testing with methyl violet (a very uncertain reagent), notes that no free HCl appeared until after ·843 grm. of HCl had been added to 100 grms. of beef, ·674 grm. of HCl to 100 grms. of bread, and ·504 grm. of HCl to 100 ccms. of milk. Sansoni and Molinari,[5] finally, in a very interesting research, have tried to solve this problem. They added to a known quantity of a decinormal or a centinormal solution of HCl a solution of an albuminoid until the fluid ceased to give a reaction with phloroglucin-vanillin. They note that soluble proteids take up the acid quickly, the insoluble slowly.

My results are obtained by the evaporation of mixtures of proteids and hydrochloric acid at different temperatures. The following table gives the sum of a number of experiments.

Proteid.	HCl Per Cent.			
	Without Pepsine.		With Pepsine.	
	Evaporation at 100° C.	Evaporation at 38° C.	Evaporation at 100° C.	
Egg albumen, . .	7·2	14·45	19·8	18·8
Globulin, . . .	8·6	15·97	17·1	19·8
Acid albumen, . .	9	18·4	18·4	18·8
Proto albumose, .	11	23·6	18	19·8
Deutero albumose, .	14	27·9	18	20·2
Peptone, . .	18–20	31·95	19·4	21

The strength of the HCl solution used in these experiments was ·27 per cent. Evaporation was continued for two hours after the contents of the capsules were dry. In each case excess of acid was added.

It is at once clear that evaporation at 38° Cent. is insufficient to drive off all the free HCl, and it is as apparent that there is a great difference between those in which pepsine had been added previously and the specimens evaporated without previous digestion. The amount of acid combining in the series in which this digestion had occurred was much the same throughout.

[1] *Die Klinik der Verdauungs Krankheiten*, Berlin, 1889.
[2] *Monatschrift für Chemie*, 1884, S. 206.
[3] *Deutsch. Archiv für Klin. Med.*, xliv.
[4] *Wiener Klin. Wochenschrift*, vi.–x., 1889.
[5] *Annali di Chimica*, ix., 1889, pp. 13 and 329.

In the other cases the amount of acid per cent. increased as the proteids became simpler. The totals in the last two columns closely approximate to the total in the simplest proteid in the first series.

The Probable Relation of the Proteid Molecules to one another.

Speculating on these *data* I have been led to project a scheme illustrating the splitting up of the albumen molecule. I must first premise that in using the number 8 or multiples of 8, I simply consulted my own convenience. And again, that I have used A = A to signify the primary proteid molecule, here again using a double form to simplify matters. As the benzine nucleus is represented in chemistry as —so, for illustrative purposes, I will use this form as a graphic representation of my scheme:—

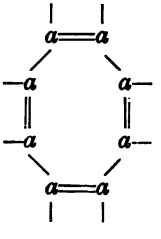

Serum-albumen I would represent thus:—

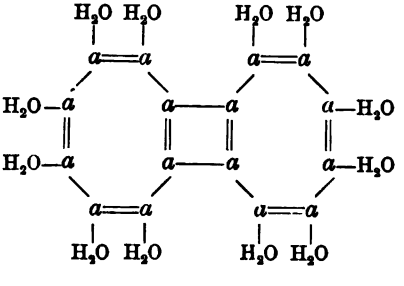

or $8A_2 + 12H_2O$. This is the constitution of it when uncoagulated or when dissolved in water. If coagulated by boiling, the form changes to 16A.

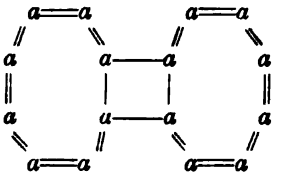

In this form it is insoluble in water, and more difficult to digest than in the former.

Acid albumen has almost the same properties as serum-albumen: it is indiffusible, is coagulated on boiling under certain circumstances, and readily returns to the form of albumen: it probably has nearly the same size of molecule in it: six

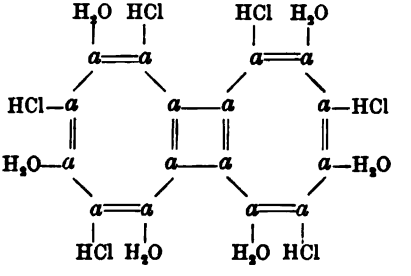

molecules of water are replaced by six molecules of HCl, or the formula is $8A_2 + 6H_2O + 6HCl$.

Leaving hetero-albumose out of consideration for the present, proto-albumose has clearly a smaller molecule than the preceding; it is not coagulated by boiling, and it dialyses to quite an appreciable extent. In the presence of pepsine and free HCl another molecule of the latter combines with an A_2, and in so doing splits up the acid-albumen molecule into $(4A_2 + 4H_2O + 4HCl)$

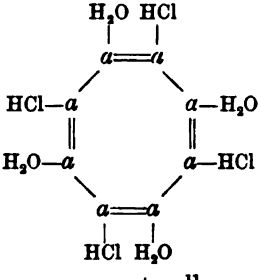

this when washed gives pure proto-albumose.

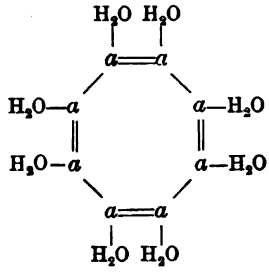

I do not see why hetero-albumose may not be looked upon as the preceding without the water molecules; at anyrate it is easily formed from proto-albumose, and in this form would be analogous in theory, as it is in fact, to coagulated albumen, insoluble in water.

Further addition of HCl in the same way gives

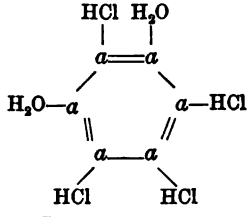

Deutero-albumose.

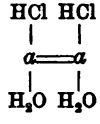

Peptone.

That deutero- has a smaller molecule than proto-albumose is proved, I believe, by the fact that it dialyses more quickly, and the same argument applies to peptone.

In this very hypothetical scheme, I have looked on the primary and indivisible proteid molecule as $\overset{|}{\underset{|}{A}} = \overset{|}{\underset{|}{A}}$, and postulate the inability of A standing by itself without splitting up into amido-acids and extractives. Again, for convenience, I have made each simple molecule quadrivalent. The building up of albumen from peptones and albumoses in the walls of the stomach may be a reversed process to this, probably consisting in the partial dehydration of the simpler forms, leaving some of the links open, which, under the influence of a ferment, clasp one another and re-form the higher molecule.

That HCl is absorbed by and combined to proteids during digestion is also proved conclusively by the fact that if a mix-

ture be made containing some albumen, pepsine and HCl, only a very small amount of free HCl being present, after digestion has gone on for some time no free HCl can be detected. The total acidity of the mixture, however, remains the same. This was referred to before in discussing Experiment VII.

Size of the different Proteid Molecules.

The different arguments in favour of the lower proteids being simpler, the higher more complicated molecules may now be brought together in one place. *First*, the lower forms can be obtained from the higher, and contain the same elements in very much the same proportions. This has been shown by various analyses. *Secondly*, the sulphur constituent of each proteid is practically the same—somewhere between one or two molecules in each. This can only be explained on two hypotheses—either that the lower are rearrangements of the higher proteid molecules, or that the higher are formed of several molecules of the lower series joined together in some way, each primary molecule of which resembles that of the lowest proteid in the scale. The last hypothesis is the most feasible and most workable. *Thirdly*, differences exist in the proportion of different metals combining with different proteids.

Silver Salts of the Proteids.

In pursuit of information regarding the relative sizes of the proteid molecules, I was led to make researches into the bodies which are formed when silver nitrate is added to them. The actual working out of the problem I must leave for another occasion. I only wish to give here the proportionate weights of the bodies formed under identically similar circumstances. The results obtained have been so uniform, that I have ventured to call the combinations by the name of salts.

Loew (*Archiv für Physiologie*, Bd. xxxi. s. 393), who worked at this subject, obtained varying results as he varied the strengths of his silver solution: below a 1 per cent. he got no precipitate with egg-albumen without the addition of sulphuric acid, with a 1 per cent. he found the ratio of silver to albumen as 2·18 per cent.; with a 5 per cent. to a 10 per cent. solution the ratio rose to 4·31 per cent. Further manipulation afforded combinations richer in silver,—the

addition of ammonia, for instance, causing the precipitate to contain 10·7 per cent. of silver.

Loew estimated the amount of the silver by dissolving the ash of the washed precipitate in nitric acid, precipitating with hydrochloric acid, and weighing as chloride of silver. He considered that atoms of metallic silver were attached directly to the proteid molecule.

Fuchs (*Ann. Chem. Pharm.*, Bd. 151, p. 372) found in his silver albuminate an average of 3·28 per cent., but he always had an excess of albumen present.

Loew also investigated the amount of silver which combined with "peptone," but in those days "peptone" comprised albumoses as well as true peptone. He only made three analyses with a mean of 11 per cent. of silver. All through his work this observer has theorised from too scanty grounds, two or at most three analyses sufficing in each case.

As the percentage of silver to albumen varied so much in these results, it was doubtful whether the bodies obtained were true chemical combinations or not. But it seems likely that a molecule of silver may take the place of one molecule of water, or that two or more may be so added to the albumen. Loew's figures are also borne out by Harnack's copper compounds. This observer succeeded in separating two series of cupric-albuminates, which correspond closely to the first two silver compounds of Loew.

I have made an extended series of observations on the silver salts of the proteids. For this purpose I separated the globulin from white of egg as described above (p. 196), neglecting however the salts. These, however, I estimated in the usual way, calculating also the weight of chlorine by precipitation of the dissolved ash with nitrate of silver. I adopted the same procedure with regard to the other members of the proteid group. In the case of deutero-albumose and peptone, I found that so much of the proteid was lost during the dialyses necessary to abstracting the salts, that it was better to calculate the ash and chlorine as above stated. All the specimens of individual proteids, however, were free from traces even of the others.

I added to each proteid in turn an excess of silver nitrate, dissolved in distilled water, the solutions being of unknown strength, but usually above 10 per cent. The precipitate with albumen was pure white, flocculent and comparatively light, the solution filtering slowly. With proto-albumose the precipitate was finer, of a bright light-yellow colour and filtered well. Deutero-albumose, on the other hand, gave an orange yellow, fine, heavy precipitate, filtering rapidly, while peptone afforded a slightly yellow, very minute precipitate, which filtered badly, much going through the filter-paper at first, and which washed extremely ill. The precipitates were washed with distilled water until no further reaction was given

on the addition of HCl to the filtrate or precipitate caused by the addition of alcohol. They were then washed with methylated spirits and absolute alcohol, dried at 110° and weighed. The filter-papers used were practically ash free, each containing ·000085 grm. The weighed paper was now incinerated in a capsule of known weight, the silver recovered and estimated. On occasion the result was checked by solution of the silver in HNO_3, filtering, then precipitation with HCl and reweighing.

The silver obtained by the incineration was both in the form of chloride, from the chlorine in the ash, and of the metal, the oxide Ag_2O and carbonate being converted to the metal by the prolonged action of heat. The chloride of silver in the remainder had already been calculated from the known chlorine of the ash of the original proteid, and could be subtracted.

The results are given both in percentages and in simple proportions.

Experiment VIII. A. *Silver to Egg Albumen.*

No.	Silver albumen.	Silver freed from chloride and ash of filter-paper.	Proportion of silver to albumen.	Percentage.
1	·191	·0129	1 to 14·8	6·75
2	·17	·0123	1 ,, 13·9	7·23
3	·16	·0106	1 ,, 15·09	6·62
4	·3972	·0277	1 ,, 14·33	6·97
5	·3371	·0242	1 ,, 13·92	7·22
6	·3961	·0261	1 ,, 15·1	6·58
7	·239	·0161	1 ,, 14·84	6·73
8	·246	·0167	1 ,, 14·73	6·78
9	·891	·0602	1 ,, 14·8	6·75

Average 1 to 14·61, or 6·847 per cent.

These numbers are very satisfactory when the fact is considered that the silver was added in varying strengths, though always in excess.

B. *Silver to Proto-Albumose.*

No.	Silver albumose.	Silver freed of chloride and of ash of filter-paper.	Proportion of silver to proto-albumose.	Percentage.
1	·081	·0136	1 to 5·94	16·79
2	·054	·0091	1 ,, 5·93	16·85
3	·065	·0105	1 ,, 6·19	16·15
4	·154	·0245	1 ,, 6·28	15·92
5	·07	·0112	1 ,, 6·24	16
6	·113	·025	1 ,, 6·01	16·63
7	·128	·02	1 ,, 6·4	15·62
8	·2722	·0468	1 ,, 5·81	17·2

Average figures, 1 to 6·1, or 16·395 per cent.

C. *Silver to Deutero-Albumose.*

No.	Silver albumose.	Silver freed of chloride and of ash of filter-paper.	Proportion of silver to deutero-albumose.	Percentage.
1	·092	·0217	1 to 4·239	23·58
2	·09	·0221	1 ,, 4·07	24·44
3	·075	·0169	1 ,, 4·43	22·57
4	·037	·0095	1 ,, 3·89	25·7
5	·04	·0102	1 ,, 3·92	25·5
6	·097	·0234	1 ,, 4·14	24·12

Average figures are 1 to 4·1149, or 24·313 per cent.

D. *Silver to Peptone.*

No.	Silver peptone.	Silver free from chloride and ash of filter-paper.	Proportion of silver to peptone.	Percentage.
1	·04	·1011	1 to ·39	256
2	·031	·0617	1 ,, ·502	199
3	·087	·275	1 ,, ·316	316
4	·098	·1141	1 ,, ·858	116

The average figures are 1 to ·5165, or 221·75 per cent.

It will be noticed at once that the numbers in the albumen series are more constant than in the proto-albumose compounds; the numbers in the deutero-albumose are still less constant, while little reliance can be placed on the peptone figures. The precipitate, in fact, of the peptone is probably very unstable.

From these figures the relation of the different proteids to one another is as follows:—

Albumen.	Proto-albumose.	Deutero-albumose.	Peptone.
14·61	6·1	4·1149	·5165 ?
or 1	·417	·281	·0353 ?

To check these results, I precipitated similar solutions of these bodies by means of a very dilute solution of silver nitrate, using ·1 per cent. in distilled water. This was added in excess. Very similar precipitates to those obtained before fell in the first three. With peptone, however, a precipitate appeared which was so diffuse and light that by no means could it be retained on a filter-paper. Two determinations were made in each case.

Experiment IX.

	Proteid and Silver.	Silver alone.	Proportion.	Percentage.
Albumen, . . . 1	·273	·038	1 to 7·18	13·9
,, . . . 2	·306	·04	1 ,, 7·65	13·07
Proto-albumose, . 1	·016	·0032	1 ,, 5	20
,, ,, . 2	0·155	·0027	1 ,, 5·94	16·79
Deutero-albumose, 1	0·22	·0067	1 ,, 3·28	30
,, ,, . 2	0·3	·0075	1 ,, 4	25

The combination with albumen here has double the quantity of silver in it; in the others also the silver is in slightly greater proportion. The numbers are too small to found any conclusion on, and require repetition.

The general result, then, of these observations is to point to the great probability of a descending series of proteid molecules. I attempted to check my results with a similar set of experiments on copper salts of the proteids, but the time at my disposal has proved insufficient.

Harnack (*Zeitschrift für Physiol. Chemie*, Bd. v. s. 198), who gives an account of the literature of the subject, found that egg albumen combined with 1·35 or with 2·64 per cent. of copper. He also submitted the bodies so obtained to analysis, and found the composition of the albumen was almost identical in the two.

The following figures, which, being derived from too scanty materials, are not to be relied on, corroborate to some extent the previous results.

Experiment X.

Copper sulphate solution was added in excess to the various proteids with the following result:—

Copper to Albumen, ...	1·5 per cent.
Copper to Proto-Albumose, ...	2·9 ,,
Copper to Deutero-Albumose, ...	4·17 ,,
Copper to Peptone. Could not be retained on a filter-paper.	

As in the silver combinations, the albumen precipitate was flocculent, the others finer and heavier.

Diffusion of the different proteids, I thought, might also aid in determining the relative sizes, and the following series of observations was performed for that purpose.

Experiment XI.

The following amounts of the different proteids were each dissolved in 50 ccms. of distilled water, other 50 ccms. were placed outside the dialysing tubes, into which the proteid solutions were poured. The levels of the solutions inside and out were carefully rendered the same. After three hours the water outside was evaporated, the residue weighed in capsules. Corrections for ash were made in each case.

Inside.		Outside 50 ccs. water, which, after three hours, contained—
1. ·237 Egg albumen, .	+50 ccs. water.	1. ·0015 gr. or ·64 per cent.
2. ·24198 Proto-albumose, .		2. ·006 ,, or 2·47 ,,
3. ·24148 Deutero-albumose,		3. ·013 ,, or 5·38 ,,
4. ·0421 Peptone, . . .		4. ·01 ,, or 23·75 ,,

That is to say, that albumen dialyses little if at all, but that the others dialyse progressively faster as we go down the series.

The different facts which have been noted above about the relative size of the proteid molecules, and the consequent support they give to my theory of the combination of HCl with them in peptic digestion, may be here set down together:—

No.		Hydrochloric acid per cent.	Silver per cent.	Copper per cent.	Diffusion per cent.
1	Albumen, . .	7	6·847	1·5	·64
2	Acid albumen, .	9	...	...	...
3	Proto-albumose, .	11	16·395	2·9	2·47
4	Deutero-albumose,	14	24·318	4·17	5·38
5	Peptone, . .	20	221· (?)	...	23·75

All these series are of one form, though naturally, as the reagent varies, so the intervals vary. I do not propose to argue further from these figures on the present occasion.

Speaking broadly, then, I believe the class of proteids to consist of bodies which are multiples of one another, which, when dissolved in water, combine with a certain quantity of it, and which have an affinity for hydrochloric acid, this substance replacing water, or combining with the proteid instead of water. And further, that the combination of hydrochloric acid with them in the presence of pepsine—a ferment which probably renders the links binding together the primary proteid molecules more unstable,—this combination evolves sufficient energy to split up the compound molecule. The daughter molecules

combining with a greater percentage of acid than their parent, in a similar manner may be resolved into a younger generation. In fact, serum-albumen is usually the grandfather of peptone. Molecules of peptone may not always, however,—to carry the analogy further,—be twins: that is to say, two molecules of proto-albumose, combining with hydrochloric acid, may split into partly deutero-albumose, partly peptone. Perhaps the difference of the hemi- and the anti- compounds so commonly displayed in the text-books on physiology arises in this last way, though I must say that, when I determined to do so, I seemed to have little difficulty in simplifying the anti-compounds if I used a dialyser as an artificial stomach; not, however, if I proceeded in the ancient manner—namely, by means of a flask.

A discussion of the probable form and constitution of the primary molecule would just now be foreign to my purpose. The manner in which the molecule of HCl takes the place of water is also immaterial; the Cl probably takes the place of hydroxyl.

I said above, that washing coagulated albumen, which is combined with some hydrochloric acid, with water, removed in time most of, if not all, the acid. In like manner, washing albumoses or peptones to which acid is combined with alcohol, serves to remove the acid. The insolubility of these substances in alcohol being probably due to the removal of water and the formation of a closed ring, so, in the same way, it may remove the combined acid. A point of some note with regard to this is, that by washing acid albumen frequently with distilled water, one may remove all the acid from it, obtaining what I believe to be serum-albumen again.

Turning now more particularly to this acid albumen or to acid globulin, two of the most peculiar of the proteid series, I would direct attention to the following facts. If a solution containing acid albumen, to which has been added a drop of phenolphthalein, be carefully neutralised by the addition, drop by drop, of a deci-normal solution of caustic soda, long before the fluid becomes neutral the first opalescence formed by the precipitation of the acid albumen appears. If soda be still added until the precipitation of the proteid occurs in flakes, it will be seen that it has as yet no red colour; it is not yet alkaline. Filter off the acid

albumen, the filtrate is acid. Add the acidity of the filtrate to that corresponding to the soda previously added, and a deficiency will be found proportionate to the amount of proteid removed. This deficiency is generally 5 or 6 per cent. The first opalescence occurs usually when the acid, still not neutralised, is about 9 or 10 per cent. of the acid albumen. The latter figure probably represents the first interference by the soda with the acid combined to the proteid; the first figure, the point at which some of the acid combined to all the acid albumen molecules is affected, leading to complete precipitation. Another point remains to be noticed, namely, that immediately after the complete precipitation of the acid albumen, if it be not filtered off, any further addition of the soda causes a solution of the previous precipitate, which has generally almost vanished before the solution becomes alkaline. Does the soda take the place of the acid, to some degree, before general alkalinity occurs?

These observations are justified by a group of experiments of a similar character to Nos. XII. and XIII.

Experiment XII.

One gramme of dried uncoagulated egg albumen with 50 ccms. of distilled water was placed in a dialyser, with 200 ccs. of a ·072 per cent. HCl solution outside. Next day there were 53 ccms. inside of an acidity of ·1116 per cent., ·0396 per cent. of which was free. 46 ccms. of this fluid was taken, containing ·491 gr. of acid albumen. A drop of phenolphthalein was added, and decinormal soda dropped into it, with the following result:—

HCl equivalent of soda added.	Result.
·03636 grm.	Precipitate beginning to fall.
·04458 ,,	Precipitate dense.
·048 ,,	Clearing up.
·05148 ,,	Clear, pink, just alkaline.

The total acid present then was ·05148 grm.: the proteid began to fall when ·01512 gr. HCl was still present. This amount of acid was required to keep it in solution. But beforehand, ·072 per cent. was combined to the albumen, or ·0156 grm. Therefore, whenever this amount of acid was interfered with, some of the proteid was precipitated. The whole of the proteid was precipitated when ·0069 grm. HCl still remained.

Experiment XIII.

·251 grm. and ·294 grm. of acid albumen were dissolved in 50 ccms. of a solution of hydrochloric acid, free acid being present. They

were then tested as before, one with deci-, the other with centi-normal soda solution. The total acidity of the first solution was lower than in the second, ·132 and ·209 per cent. respectively.

1. HCl equivalent in grms. of soda added.	2. HCl equivalent in grms. of soda added.	Result.
·054	·090576	Opalescence.
·05652	·094212	Opaque.
·05904	·097776	Flaky precipitate.
·06012	·09954	Beginning to clear.
·06282	·103572	Clearing.
·06624	·104686	Alkaline, almost clear.

Between the first precipitation and alkalinity in these two a very similar proportion exists. In No. 1, ·01224 grm. HCl, or 4·91 per cent.; in No. 2, ·01411 grm. HCl, or 4·79 per cent. The other figures closely correspond.

That the fluid is not neutral when acid albumen is precipitated in flakes, is proved by the following observation on No. 2 of the last experiment.

Experiment XIV.

After the fluid in No. 2 of Experiment XIII. had been rendered alkaline, it was acidified again, and the acid albumen again precipitated in flakes by the addition of alkali. It was now filtered, and the filter-paper washed several times with distilled water. The filtrate contained no proteid material, but was acid, containing ·00216 grm. HCl. The difference between the point at which the precipitate fell in flakes in Experiment XIII. No. 2, and the alkalinity point, was equal to ·00691 grm. of HCl. The removal of the acid albumen diminished this by ·00475 grm. This either represents acid attached to the proteid, or the equivalent amount of soda required to be taken up by the albuminoid before phenolphthalein is changed in colour by free alkali.

Acid globulin behaves in much the same manner, falling sooner, however, and persisting longer in an insoluble form, than the corresponding albumen.

The Effect of Dialysis on the Proteid Hydrochlorides.

On submitting albumen with which hydrochloric acid is combined to the action of dialysis into distilled water, the acid is removed, the albumen remains. If albumoses similarly combined are similarly treated, some of the albumose, more if it be the secondary albumose, dialyses, and with it the acid combined to it, and also the acid combined to the remainder left inside.

On the other hand, peptone and the acid combined with it dialyse out freely together. Again, if a solution of albumen with HCl combined, in which, however, there is no free acid present, be dialysed, free acid appears in the water outside and never more than a trace of acid in a state of combination, while if peptones be similarly treated, no free acid appears either outside or within. An interesting point occurs here, but before touching on it, I must contradict what I said above. I there made the statement that acid combined to proteid without the aid of pepsine is capable of further digestion on the addition of that ferment, while, conversely, acid which had saturated the proteid molecules under the influence of pepsine, was incapable of further digestion. This last statement is not correct, for I have been enabled to separate, in the presence of pepsine, the acid combined to albumoses after a regular digestive act by means of dialysis, and to split up these albumoses further into peptones by the action of the free acid thus obtained. The acid which is freed from some of the albumose molecules, probably those next the sides of the dialyser, is at once seized by adjacent molecules: these are able, owing to pepsine being present, to pick up the acid, they become over saturated, they split up, they form peptones. But as peptones require a greater percentage of acid than albumoses, the process can only go on for a short time,—the supply of acid is deficient.

Experiment XV.

25 ccms. of white of egg were digested for some hours with HCl and pepsine. The solution then contained the following constituents:—

Total solids, .	1·81	per cent.	Total acidity, ·164 per cent.
Ash, . . .	·09	,,	Free acidity, ·0
Organic solids, .	1·72	,,	
Albumen, . .	·375	,,	
Acid albumen, .	·0		
Albumose, . .	·6	,,	
Peptone, . .	·3184	,,	
	No free HCl.		

40 ccms. of such a solution were placed in two parchment tubes with 44 ccms. of distilled water added to each. ·015 grm. of pepsine was added to the first, the second was boiled. Round each, 200 ccms. of distilled water were poured. Each therefore contained ·724 grm. total solids, ·036 grm. ash, and ·680 grm. organic solids.

The two were kept at 38° Cent. for twenty-four hours. Next day, Outside—

1. 182 ccms. ;	·0175 per cent. HCl	= ·03185 grm. HCl.	
2. 183 ,, ;	·0173 ,,	,, = ·31659 ,,	

1. Total solids, .	·2971 grm.	
Ash, . .	·0301 ,,	No Liebermann's reaction.
Organic solids,	·267 ,,	
2. Total solids, .	·2436 grm.	
Ash, . .	·0328 ,,	Trace of free HCl as shown by
Organic acids,	·2108 ,,	Liebermann's reaction.

Inside—

1. 79·75 ccms.	·03075 per cent. acidity.		·0245 grm. HCl.
2. 82 ,,	·0351 ,,	,,	·02878 ,,

No free HCl in either.

1. Total solids, ...	·3828 grm.	
Ash, ...	·01196 ,,	
Organic solids, ...	·37084 ,,	
Albumen, ...	·13706 ,,	·17 per cent.
2. Total solids, ...	·4428 grm.	
Ash, ...	·0082 ,,	
Organic solids, ...	·4346 ,,	
Albumen, ...	·1394 ,,	·17 per cent.

To sum up—

1 + Pepsine, .	inside,	·37084 grm.	organic solids.
	outside,	·267 ,,	,,
Total, .		·63784 ,,	,,
2 – Pepsine, .	inside,	·4346 grm.	organic solids.
	outside,	·2108 ,,	,,
Total, .		·6454 ,,	,,

As in both cases there was no free hydrochloric acid to start with, and as it had already done its work in digestion, it is clear that dialysis has the power of separating it from its proteid. In the example without pepsine, which had been previously boiled to preclude any error from the previous addition of this ferment, free HCl was found outside at the end of the experiment. In No. 1, on the other hand, the dialysable bodies were increased, and yet no free HCl could be discovered. Any free HCl that might have been liberated has, under the influence of the pepsine, attached itself to some nearly saturated proteid molecule, and split it into a simpler form. In this way the organic solids outside are increased considerably.

One or two similar experiments, performed on similar lines, corroborate this assertion, and need only be referred to here.

One was especially striking, as albumose and peptone were alone used in it, and a large proportion of the albumose was converted into peptone by a like process to the preceding.

Natural Digestion.

It will be seen from what I have said that during an act of gastric digestion all the albumen is not converted into albumose before that is turned into peptone. From the foregoing experiments it is plain that if a solution containing both serum and acid albumen be digested with HCl and pepsine, the acid albumen molecules are acted on first, and that, indeed, peptone may be formed long before any difference has occurred in the quantity of serum albumen present.

This accords with the fact that within a quarter of an hour after a meal of the higher proteids, all the simpler forms may be identified in the stomach contents; and that long before, comparatively speaking, any free HCl can be detected in those contents, the gastric digestion of proteids has, in part, progressed to its appointed end. The acid secreted by the stomach combines with the albumen and globulin; combining, splits them into simpler forms; and free acid still being secreted, these in turn are simplified, and in this process the free acid is used up. In time, however, the ratio of free HCl added to the stomach contents exceeds that which can combine, when naturally the presence of free acid can be demonstrated in the contents. Until this point is reached, generally an hour after food is taken,—the time varying, however, with the food,—all the free acid secreted by the gastric glands combines at once with proteids. The stages of gastric digestion, after a meal consisting chiefly of proteids, may be divided into—

1. Amylolytic stage, acidity slight, rising, no free HCl present, but some combined to proteids. Duration, about ten minutes. Peptones generally present.

2. Combined-hydrochloric acid stage, acidity considerable, rising, all forms of proteid present, no free HCl. Probably some lactic acid. Duration, until about the half hour.

3. Free hydrochloric acid stage, acidity still increasing, some

free HCl, mostly combined, lactic acid disappearing. From the half hour to three hours or so.

4. Last stage. Acidity falling, free acid rather in excess of the combined. From the third to the fifth hours.

Absorption probably goes on in varying degrees throughout; as albumoses dialyse, they possibly can be absorbed in their complete form. Indeed, as the rectum can absorb albumen, there is no reason why the stomach should not be able to absorb albumoses. Then, by some converse process, these bodies are changed into albumen again.

Pancreatic digestion, most energetic when there is considerable excess of fatty acids present, may be of much the same character: that I must leave for future investigation.

FORKED NERVE ENDINGS ON HAIRS. By the late GEORGE HOGGAN, M.B., and by FRANCES ELIZABETH HOGGAN, M.D. (PLATE XII.)

As far back as 1880 my late husband undertook, conjointly with myself, a series of researches on nerve terminations in different classes and species of animals. A paper was written early in 1882 on the Nerve Terminations in the Insectivora as modified by their habits; but before its publication, we had the mortification of learning that some of our discoveries and conclusions, in relation to forked terminations on hairs, had been forestalled by other workers, notably by Arnstein and Bonnet. Our work had therefore to be recast, and continued on somewhat different lines. In the years 1882–84, the subject of nerve endings on hairs and in the skin was treated of by us in a number of articles,[1] all illustrated by careful camera-lucida drawings by my husband, from specimens prepared by the gold method, as described in this *Journal*, vol. xviii. p. 182.

My husband's health broke down in 1885, and from that year to the date of his death, in May 1892, but little histological work was done, health requirements having become a major consideration, to the exclusion almost of scientific research. There remains, however, on hand much unpublished work left behind him, by one so skilled in methods of histological research, so keen in his insight, and so acute in his perceptions and deductions, that it seems wrong to withhold from the scientific public these few posthumous fragments of what would, if life and health had been spared, have expanded into an extended series of observations on the comparative anatomy of the peripheral nervous system. I am now engaged in other work, and may

[1] On some Cutaneous Nerve-Terminations in Mammals, *Linnæan Society's Journal*, vol. xvi., 1883. Etudes sur les Terminaisons nerveuses dans la Peau, *Journal de l'Anatomie et de la Physiologie*, Paris, t. xix., 1883. Des Formes nouvelles de Terminaisons nerveuses dans la Peau des Mammifères, Td. t. xx., 1884. Neue Formen von Endigungen in der Haut von Saügethieren, 1884. New Forms of Nerve Terminations in Mammalian Skin, *Journal of Anatomy and Physiology*, vol. xviii., 1884.

never (or not for years to come) pursue further the same line of research; and I therefore give forth this article in its present incomplete form, believing that the faithful and accurate drawings which accompany it will be of value to other workers in the same field, and supply some missing links of evidence in the history of the comparative evolution of an important part of the peripheral nervous system in different and widely separated species of animals and in Man. If this be so, it will form a fitting last bequest to his fellow-workers, from one who gave to science ungrudgingly and freely the best years and the ripest thought of his life.

The innervation of the hair follicle, especially of tactile hairs, has been investigated by many since Jobert discovered in 1872 the coil which is known by his name. As far back as 1870–71 Schöbl examined the wings of bats and the ears of albino mice.[1] In the skin of the mouse's ear he saw a medullated nerve going to each follicle, and forming round it a nerve ring. He further describes and draws a wonderful nerve coil below the hair bulb; but the drawings are so diagrammatic, that it is not surprising that later investigators have failed to make out Schöbl's coil, which corresponds rather with the position of blood-vessels than of nerves. Arnstein[2] in 1876 speaks of the terminal brush of the nerves of the follicle of the feeler hairs of the mouse's ear, which, he says, "pinselförmig in die Glashaut ansstrahlen." Bonnet, in his classical studies on the innervation of the hair follicles of domestic animals, gives in the *Morph. Jahresbuch* for 1878 some very good and evidently accurate drawings of feeler hairs from some of the numerous species he examined (ox, dog, cat, pig, rat, and mouse). In one of his drawings he shows, on a large feeler hair from a dog's nose, straight terminal forked fibres, and he also expresses the well-founded opinion that every hair, with its envelopes, is a tactile organ. Richiardi in 1884 describes, on feeler hairs from the ox, medullated fibres, passing into non-medullated, very irregular, tortuous fibres, which subdivide anew, and intertwining, form beautiful ovoid or fusiform nerve tufts, which extend upwards to about the middle of the follicle.

[1] *Arch. f. mikroskop. Anatomie*, 1871.

[2] Die Nerven der behaarten Haut, *Sitzungb. d. k. k. Akad.*, 1876.

In Quain's *Anatomy* (edition of 1882) the innervation of the hair follicles is summarily treated of as follows:—"Nervous branches enter the hair follicles, but their final distribution is obscure;" and the nerves in tactile hairs are said finally to end in an annular expansion, which no doubt refers to the coil of Jobert. In the edition for 1891 only the following passage occurs:—"Ordinary hairs receive fewer nerve fibres, but as in the tactile hairs, most of these appear to end in the outer root sheath, at about the level of the orifices of the sebaceous glands." So far, therefore, little recognition of the work done in the minute anatomy of the nerves of the hair follicles has found entrance into our English text-books, for other writers are equally reticent and chary of detail.

Other investigators having devoted special attention to the nerve supply of *feeler* hairs, and their fitness to be regarded as tactile organs, we were early led to examine more particularly the *ordinary* hairs, on which we were not long in discovering an amazing richness of terminal forks, in contradistinction to what is found on feeler hairs, where they are far less plentiful, and are more difficult to make out. Feelers and ordinary hairs possess the same categories of nerve elements, but they vary greatly in the manner of their distribution. In the feeler hairs, for instance, the branched nerve or ganglion cells, so variously interpreted by different writers, are found in densely massed groups, and they are connected with many medullated nerves; whereas in the ordinary hair these branched or stellate ganglion cells are not present in anything approaching the same number or regularity. Indeed, they have been overlooked there altogether by most observers; and we were, I believe, the first to call attention to them on ordinary hairs. We have also failed to find on ordinary hairs a single example of a medullated nerve passing to these cells, the connection being always, in the ordinary hair follicle, with non-medullated nerves.

The number of medullated nerve fibres entering hair follicles varies from several hundred on large feelers (my husband counted nearly 400 on some of the largest, in the horse) to only one. In ordinary hairs these nerves may be one or two only, and they generally pass to the hair at a much higher level, and often from opposite sides of the follicle.

The circular fibres of the follicle, both the inner and the outer coil, were first described by Jobert in 1872, in the *Annales des Sciences Naturelles*, and we at that time only knew of them as occurring on the fine hairs of the tail of the rat. These coils exist, however, on all hairs. They are the most superficial of the nerve structures of the follicle, and are found just below the opening of the sebaceous gland, external to the forked terminations, between them and the basement membrane. These coils of Jobert receive nerves horizontally from the side of the follicle, and we have traced a connection between some of these fibres and the branched cells lying perpendicularly below them.

The forked terminations lying between the lower layer of epidermic cells lining the follicle and the basement membrane are not very easily seen on large feelers, but they are found on the smaller feelers, where they form, as Bonnet has shown, a row of short, broad, spade-like bodies, just above his end bulbs or the above mentioned branched nerve cells; and upon the ordinary hair follicles, the forked endings are the most prominent of all the nerve elements. That these essentially terminal elements should be so much better developed on ordinary than on feeler hairs is, on the whole, in favour of the interpretation that they are the terminal organs subserving the sense of touch or general tactile sensibility. We have shown in previous articles (see list on first page) that these forks, variously modified, are found as nerve endings in all the known tactile bodies, and we have traced them from the simple two or three pronged fork on the ordinary hair (see Plate XII.) through the Browne and Hoggan bodies, the Pacinian and Meissner corpuscles, in a great variety of modified but strictly allied forms. The complicated organ of Eimer is also, as we have demonstrated (see *Linnæan Society's Journal*, vol. xvi., 1883), the survival of the nerve elements belonging to an original cluster of hairs, dragged out, in the course of evolution, by the digging habits of the mole; and in this organ the homologies of the forked endings may be distinctly traced. The probable reason why this chain of development was not sooner worked out by some one before we began to work at it is, that naturalists and histologists have been accustomed to work too much on separate lines. Minute anatomists have been too apt to

confine their attention to Man or to a few other species, whereas it is necessary to study the nerve terminations in many different, and not too closely related, species, in order to get an idea of their variety, and yet orderly sequence. Naturalists proper have, on the other hand, only too generally, until quite recent times, limited their study to naked-eye characters, to the neglect of microscopical peculiarities. The further working out of this most interesting chapter of the development and morphology of the nervous system will have to proceed more on the lines of comparative histology, and will necessitate cordial co-operation and mutual aid between histologists, zoologists, and the authorities of zoological gardens, where so much valuable histological material is yearly available for purposes of study.[1]

Our appreciation of the physiological significance of feeler hairs must be somewhat modified by the fact of the comparatively small number of forked nerve endings found on them. As they are organs which the human species does not possess, and they may be taken to represent a (to us) lost sense, and voluntarily projected sense organ, worked by means of the voluntary muscles at their base, it is probable that some time will yet elapse before we have a rational conception of the place these organs occupy in the general plan of the nervous system. It is further probable that our knowledge of their special meaning and function will be best advanced by the comparative study of the nerves and sense organs of invertebrates, beginning with the transparent, soft-bodied, marine mollusca, and that clearer notions of the functions of feeler hairs will only follow on such wider study of the nervous system, in its earlier evolution, in lower forms of animal life.

Our researches on forked nerve endings in hair follicles were pursued on a large number of species. Within the two years preceding 1885, my husband examined thousands of preparations, many of which were of course found worthless, from the mouse, the rat, the mole, the water-shrew, the hedgehog, the rabbit, the guinea-pig, the cat, the leopard, the dog, the horse, the pig, the

[1] I have pleasure in acknowledging here how much my husband and myself owed to the kindness of the officials of the Zoological Gardens, Regent's Park, for placing at our disposal, immediately after death, portions of the skin of animals difficult to obtain elsewhere.

bullock, the raccoon, the opossum, the wallaby, the kangaroo, the jerboa, the tree porcupine, the washing bear (*Procyon lotor*), the coypu, the bear, the seal, various monkeys, and Man from childhood to old age. The resulting mass of our unpublished material, and the unpublished drawings made by himself, are now partly utilised by me in this paper. The drawings I have selected are those which best show, at a glance, the oneness of type of the forked endings in as great a variety of species as possible within the limit of one plate. I have omitted from the selection all such as have been already shown by us in previous publications, either English or foreign, as they can easily be seen by referring to the publications themselves, and I only give a few of the last drawings made. Those relating to the human species are of especial interest, as affording the proof that the forked nerve endings persist from early childhood to old age, unaltered in their character, although diminished in number. Previous researches have shown (see hairs of kitten in the *Journal* of the Linnæan Society) that although we had failed to make out forked endings prior to birth, they are distinguishable as extremely fine objects (we designate them as appearing almost to have length without breadth, so delicately slender are they) on both the largest and smallest hairs of a newborn kitten.

If a hair from a monkey is compared with a human hair, the similarity of the terminal forks is seen to be very great. In a specimen from the weeper capuchin the resemblance is particularly more striking. They are indeed so much alike that the specimens might be supposed all to belong to the same species, although the direction taken by the medullated nerves is different, and they have a longer longitudinal course in Man, more nearly resembling their course in the horse (fig. 1), but more twisted than in that animal. In fig. 8 the two-pronged type of fork is clearly shown, but it is less regular than in some of the other figures. In a similar transverse section from the raccoon (fig. 2), 3, 4, and even 5 forks are seen. From an unpublished drawing, it appears also that the relative number of the forked endings is less in the thin hair of an almost bare scalp from a man of 58.

A good deal has been said by different writers about the

different shapes of the peripheral endings of the forks. They may be spade or hoof shaped as in the horse (fig. 1), lancet shaped as in the mouse or as in the leopard (fig. 4), club shaped as in fig. 5, from the seal (centre fork), merely linear as in the ocelot or as in the newborn kitten, pointed as in the child and in the weeper capuchin monkey, or they may show several of these forms in the same specimen, as in fig. 7 from the baboon. In Man the shape does not offer in our specimens anything peculiar or characteristic, and, as will be seen, it would be difficult to pick out a human hair, with its forked nerve endings, from amongst a number of other specimens. The forked terminations are, as a rule, flattened, probably by pressure from contiguous structures, but this circumstance does not appear to be of moment in relation to Man.

In conclusion, the fact which more than any other must strike the reader or investigator is, that the scheme of the forked nerve endings in hair follicles is so consistent and so little varied in such a large number of species only remotely related to each other. If in the mouse, the chinchilla, the cat, the dog, the opossum, the seal, different species of monkeys, and in Man the plan of the axis cylinder losing its medullary sheath and ending sometimes in one branch, but generally in from 2 to 5 forks or branches, is invariably met with, the inference may be drawn that we have here an important typical part of the peripheral nervous system of the mammalia, very early developed in point of time in the zoological scale, formed and ready for use at birth, and equally well-marked in mammals who pass great part of their lives in the water (see fig. 5, from the seal). It would be interesting to look for this nerve terminal apparatus in the lanugo hairs of children dying at birth, and also in animals at the other end of the mammalian chain, the Monotremata. In the latter there is every reason to expect that there will be found but slight, if any, divergence from the type which persists so constantly in those other classes of the mammalia which have been already made the subject of investigation and histological research.

DESCRIPTION OF PLATE XII.

(Drawings made by the camera-lucida.)

Fig. 1. View of nerves on ordinary hair follicle of horse, $\frac{1}{12}$ oil immersion of Zeiss, tube drawn out. Nerves seen from interior of follicle. Section oblique to axis of hair.

Fig. 2. Transverse, slightly oblique section of hair of raccoon.

Fig. 3. Nerves of ordinary hair from nose of chinchilla.

Fig. 4. Nerves of ordinary hair from nose of leopard.

Fig. 5. Nerves of ordinary hair from seal.

Fig. 6. Do. from rabbit.

Fig. 7. Do. from Rhesus monkey (*Macacus erythræus*), $\frac{1}{12}$ oil immersion of Zeiss.

Fig. 8. Do. from weeper capuchin.

Fig. 9. Do. from guinea-pig.

Besides the forked nerve endings shown in all the figures, either in longitudinal or transverse section, branched nerve cells are shown at the base of the forks in most of the figures. The forks are of a very dark, the nerve cells, with their processes, of a paler colour.

F. E. H.

THE SUPRASTERNAL BONES IN MAN. By THOMAS CARWARDINE, M.R.C.S., L.R.C.P., *late Demonstrator of Anatomy, Middlesex Hospital Medical School.* (PLATE XIII.)

(Read before the Anatomical Society, 21st November 1892.)

THE suprasternal bones are said to be of rare occurrence in Man, and attention does not seem to have been drawn to their vestiges which frequently, and almost constantly, exist in the human body. This may be because the ligaments of the sterno-clavicular articulation are very seldom thoroughly dissected whilst in the fresh state.

It is the object of this short paper to point out that the suprasternal bones are normally represented by distinct ligamentous fibres quite apart from the other ligaments of the region; and a few specimens and diagrams are shown to the Society by way of illustration. One specimen is an excellent dry preparation, kindly lent for the occasion by Mr Bland Sutton, showing both the suprasternal bones. The others are moist preparations and serve especially to illustrate the purpose of this paper.

The first specimen is represented in fig. 1. It shows a well-marked T-shaped interclavicular ligament with horizontal limbs, and vertical fibres descending to the sternum, representing the episternal bone of Lizards and Monotremes.

Beneath its horizontal limbs two well-marked ligamentous bands are seen, passing from behind the clavicles in a direction forwards, inwards, and downwards to the sternum, where they are attached on either side of the suprasternal notch. That on the right side is occupied near its attachment to the sternum by a suprasternal bone, which is rather larger than a pea, and elongated from before backwards. It is freely movable upon an articular facet on the sternum, has a synovial membrane, and the fibres binding it to the sternum form a capsular ligament for it. The corresponding ligament on the left side presents no suprasternal bone, but has at the most a slight cartilaginous thickening at its lower part. From this it would appear that

the suprasternal bone is an ossification in connection with a ligament which may be called the "suprasternal ligament."

The second specimen (fig. 2) represents the "suprasternal ligament" of the left side, passing into an irregular scale-like nodule of bone, which, on careful examination, will be found to show undoubted traces of secondary connection with the sternum by ankylosis. This suprasternal nodule is in fact a suprasternal bone, which, though at an early period independent, has fused with the sternum at a later stage. On the right side the ligament passes into a tubercle representing a similar, but more advanced condition, and which, in order to adopt uniform nomenclature, may be called the suprasternal tubercle.

In the third specimen (fig. 3), taken from a child thirteen years of age, we find the condition most commonly met with. There is here no obvious bony trace of the suprasternal bones, but the suprasternal ligaments still persist as beautiful flat bands of bright ligamentous fibres, the central parts of which have the typical attachments already described, whilst a few fibres blend with the interclavicular ligament, and a few at times with the sterno-clavicular capsule.

The series is made complete by reference to the development of the sternum. In the ossification of the præsternum short processes of advanced ossification may sometimes be seen beneath the attachments of the above-named suprasternal ligaments, and occasionally two independent centres of ossification may be observed in this position as described by Breschet (fig. 4).

The conclusions to be derived from these specimens are—(1) that the suprasternal bones occur as ossifications in ligaments which are almost constantly present in the adult, though to a variable extent; (2) that the suprasternal bones may fuse with the sternum at an early period, being represented by tubercles, with the ligaments attached to them; (3) that in other cases the suprasternal bones are incorporated with the sternum, leaving the ligaments attached to the sites of incorporation.

When, therefore, these bones occur in Man, they may be regarded as a sign of incomplete ossification and development of the sternum. It was this opinion which led to the discovery of the specimen represented in fig. 1. This specimen occurred

in a subject having a bifid xiphisternum with sternal foramen perceptible through the skin. On opening the abdomen I also found that the 7th costal cartilages had failed to contribute to the formation of the sternum as they should do, but only articulated with it, and with each other in the middle line. Following this up by a search for signs of arrested ossification of the præsternum also, I found the specimen in question.

The literature upon the suprasternal bones is scanty, whilst the ligaments have not, as far as I am aware, been yet recorded in Man. The bones appear to have been first noticed by Beclard, who regarded them as rudiments of the "fourchette" or furcular clavicle of birds. Breschet suggested that they were ventral vestiges of a 7th cervical rib. Dr Robert Knox described a striking specimen in the *London Medical Gazette* for 1843. Luschka and Gegenbaur have also described and discussed them. Mr Bland Sutton, in his excellent work on the Nature and Morphology of Ligaments, remarks that "the interarticular fibro-cartilages at the sternal and acromial ends of the clavicle arise from the regression of the inner and outer extremities respectively of the cartilaginous præcoracoid," and that "the nodule of bone known as episternal, is developed in this remnant of the præcoracoid bar." This view is a distinct advance upon that recorded by Mr W. K. Parker in his monograph on the shoulder girdle, published by the Ray Society, who endeavoured to show that the sternal portion of the præcoracoid was represented by the interarticular fibro-cartilage of the sterno-clavicular joint. It seems to me probable that the suprasternal bones, and the suprasternal ligaments described in this paper, are the *true* remains of the præcoracoid cartilage at its sternal end, and that not the clavicles alone, but also the sterno-clavicular fibro-cartilages may be adventitious structures. It may also be mentioned that the reduction of the suprasternal bone or omosternum to a ligamentous condition has been shown by Parker to occur in animals, particularly in some Rodents.

THE FUNCTION OF THE URETHRAL BULB. By F. J. ALLEN, M.A., M.B. Cantab., *Professor of Physiology in Mason College, Birmingham.*

THE urethral bulb is usually understood to assist the action of the bulbo-cavernosus muscle in emptying the urethra; but the *modus operandi* is not explained. A very peculiar feature of the bulb is, that it does not surround the urethra, but is situated behind it. Such a peculiarity may be expected to serve some purpose, and of this purpose I would suggest the following explanation:—

A tube with spongy walls, like the distal portion of the urethra, offers a certain impediment to the passage of fluid. That is to say, the lumen of the tube is usually closed, and if a small quantity of fluid be forced into one end of it, the momentum is expended in opening the tube (or in other words, in pushing aside the blood in the erectile tissue), and the fluid may fail to reach the far end. If the tube were muscular, a peristaltic movement would secure the propulsion of the fluid; but in the case of the urethra, the work is performed by a special action of the erectile tissue with the assistance of the bulb. When the bulbo-cavernosus compresses the bulb, it drives the blood from thence onwards, causing a wave of increased fulness to pass along the corpus spongiosum. *This increased fulness closes the urethra behind any fluid contained therein, and the advancing wave drives the fluid onwards before it to the end of the tube.* It must be remembered that during erection the bulb is largely distended with blood, and therefore specially capable of this action.

The bulb, whence the wave starts, must be placed behind the point where the fluid enters. If the bulb *surrounded* the entrance of the urethra into the corpus spongiosum, the effect would be different. The contraction of the bulbo-cavernosus would then start simultaneously two waves—one in the urethral walls, the other in the urethral tube. The increased pressure in the one would be just balanced by the same in the other, and no advantage would be gained. The blood-wave would not close the urethra behind the fluid contained, or at least would

have an equal tendency to close it either behind or before. In fact, there would be a race between the two waves, and the least impeded would win. If the urethral contents were viscid, they would move with difficulty; while, on the other hand, the blood-wave would always travel unimpeded, since it is a true wave,—the fluid not moving in mass, but communicating its impulse from particle to particle. An evidence of this rapid wave-movement is seen in the suddenness and completeness with which the spongy urethra can empty itself; and herein probably consists the advantage of this mechanism over peristaltic action in the case of the urethra.

The diagrams may help to explain the action. In fig. 1 the actual condition is shown, the blood-wave B starting behind the

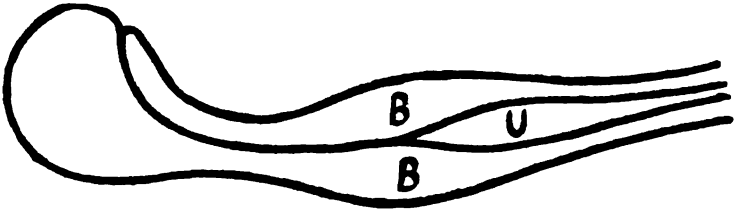

FIG. 1.

intra-urethral wave U, and driving the latter before it. Fig. 2 represents a hypothetical urethra surrounded by the bulb, the

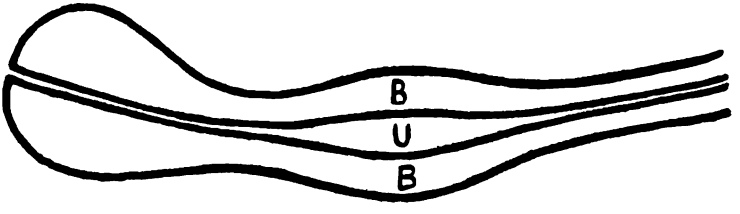

FIG. 2.

two waves starting simultaneously, giving no advantage to the intra-urethral wave, and not necessarily closing the tube behind it.

[For the sake of distinctness, the blood-wave is represented as if occupying only a short section of the length of the urethra, whereas in reality its posterior limit would be at the bulb. In fig. 2, where the waves are simultaneous, this remark applies also to the intra-urethral wave.]

ON THE ABSENCE OF THE MALE REPRODUCTIVE ORGANS IN TWO HERMAPHRODITE MOLLUSCS.

By WALTER E. COLLINGE, *Demonstrator of Biology, Mason College, Birmingham.*

IT is now generally agreed that hermaphroditism "was the primitive state among multicellular animals, at least after the differentiation of sex elements had been accomplished. In alternating rhythms, eggs and sperms were produced."[1] Gegenbaur[2] regards the present distinction of sexes as being derived from a hermaphrodite condition; while Broch,[3] speaking more particularly as regards the mollusca, holds that the reproductive organs "are laid down and developed in the female type, and only secondarily become hermaphrodite." It will be well to keep these ideas before us while considering the following interesting cases.

The species of molluscs which I shall here describe are normally hermaphrodite, and, so far as I am aware, there are no observations on record of either of these species or members of the same class ever having been found with either the male or female reproductive organs absent.

Some two years ago, when dissecting large numbers of the *Helicidæ*, in connection with some researches upon the dart and dart-sac, I met with a specimen of *Helix aspersa*, Müll., in which there was an absence of the male reproductive organs. There were present the vestibule, vagina, oviduct, continued as a single common duct, dart-sac, albumen gland, and an exceedingly small hermaphrodite duct and gland. There were no traces whatever of the penis, vas deferens, flagellum, retractor muscle, receptaculum seminis, or diverticulum. A drawing was made at the time of the organs present, but owing to an unavoidable accident, the specimen was destroyed, and so, in the hopes of securing another example, I deferred the publication

[1] Geddes and Thomson, *Evolution of Sex*, p. 78, 1889.
[2] *Elements of Comp. Anat.*, trans. 1878.
[3] *Morphol. Jahrb.*, vol. iv.

of a note upon the subject. Not until quite lately has any similar occurrence come under my notice, although I have, since the loss of the above specimen, dissected some hundreds of the various species of *Arion*, *Limax*, and *Helix*.

Some two weeks ago Mr W. A. Gain of Tuxford, Newark, sent me a number of small slugs, some of which, being very young specimens, I found somewhat difficult to diagnose. From dissections I came to the conclusion that they were young forms of *Arion empiricorum*, Fér., *A. circumscriptus*, Johnston, and possibly *A. subfuscus*, Drap., and *A. intermedius*, Normand, but was very doubtful of the two latter species, so I forwarded to Dr R. F. Scharff some of the specimens. Dr Scharff has very kindly made further dissections, and thinks the forms to be *A. circumscriptus*, Johnst., with a somewhat abnormal receptaculum seminis, *A. empiricorum* or *A. subfusca*, immature, and *A. intermedius*, one specimen of which is remarkable in having no male reproductive organs. Unlike the example of *Helix aspersa*, Müll., previously met with, there is here no hermaphrodite duct, and only a slight dilatation standing out from the inner base of the albumen gland, which it is very likely is only functional as an ovary.

There is no vas deferens or sperm duct (= Patronstrecke of Simroth, which is the lower portion of the vas deferens, and in the *Helicidæ*, &c., forms the penis), no receptaculum duct or receptaculum seminis, and the common duct consists of a continuation of the oviduct only. Attached to the upper portion of the oviduct is a retractor muscle, which, from its position and size, is very conspicuous.

I have elsewhere[1] shown how few *important variations* there are in the reproductive organs of any individual species of mollusc (*Arionidæ*), so that these two cases will, I think, be of interest generally, and also as showing a reversion.

[1] *The Conchologist*, vol. ii. p. 56, 1892.

NOTES OF A CASE OF CONGENITAL ABSENCE OF BOTH ULNÆ. By J. HOGARTH PRINGLE, M.B. Edin., F.R.C.S. Eng., *Assistant Surgeon Glasgow Royal Infirmary.*

M. B., æt. 31, is the seventh member of a family of nine, all the others of whom are well, and not the subjects of any deformity. No case of deformity is known to have existed among the members of either his father's or mother's families.

His mother states that the patient was born at full term, but that during the early months of the pregnancy she had received a severe fright.

In addition to the above-mentioned deformity, the patient is the subject of very advanced right-sided scoliosis. The two upper extremities are short, and small from want of muscular development. The measurements of the two limbs are as follows:—

	Right.	Left.
From tip of acromion to most prominent point of the external condyle of humerus . . .	29 cm.	29 cm.
From most prominent point of external condyle of humerus to tip of styloid process of radius .	15 cm.	14·5 cm.
Circumference of limb over humeral condyles .	18 cm.	18 cm.
" " at level of styloid process of radius . . .	13·5 cm.	13·5 cm.
" " at level of metacarpo-phalangeal articulations .	17·5 cm.	15 cm.

The Right upper extremity.—The hand is provided with three fingers only, one well developed, which appears to be the third (middle) digit, and two malformed ones, one to each side of the former.

The middle finger is perfectly developed and about the same size as in a normal adult hand; its movements are perfect, and flexion is very powerful.

The digit situated to the radial side of the former is probably the index, for although "opposed" to the middle finger, it is provided with a metacarpal bone and three phalanges. Its distal phalanx is small, and provided with a rudimentary nail

The two interphalangeal joints are ankylosed, but that between the metacarpal bone and proximal phalanx is movable, and the patient is able to flex and extend it to a limited degree.

The third digit present, situated on the ulnar side of the middle finger, is apparently the representative of the fifth finger; it consists of a metacarpal bone and two phalanges, the distal being very short and provided with a rudimentary nail, a mere speck. He is able to exert a certain amount of movement at the metacarpo-phalangeal articulation, which consists of an ulnar flexion so far as to bring it to a right angle with the ulnar border of the hand.

There is no trace of the ring finger or its metacarpal bone, unless a small tubercle over a distinct projection on the radial side of the base of the proximal phalanx of the little finger can be considered its representative. There is a distinct gap between the metacarpal bones of the middle and little fingers.

The wrist joint is freely movable. The trapezium is absent, but it is not possible to determine if any other carpal bones are wanting.

There is no trace of the ulna.

The lower extremity of the radius is thicker than normal, and more widened out; it seems to end in two styloid processes. The head of the radius is not distinctly definable; it lies rather to the anterior aspect of the external condyle.

The internal condyle of the humerus is very prominent, as is well seen in the figure.

Right Arm of M. B.

A slight olecranon fossa seems to be present, but the trochlea is not felt. The external border of the humerus is continued

directly on to the radius, the two bones being united by osseous ankylosis, the forearm being flexed on the arm at an angle of about 150°. The pulsations of an artery can be felt just above the wrist on the ulnar side of the limb, but none can be made out on the radial side.

The muscles of the forearm are well developed.

The biceps and brachialis anticus are feebly developed, but the patient can voluntarily contract them to a slight extent. Only the long head of the triceps seems to be present; it ends in a distinct cord-like tendon 8 cm. long, which passes to be inserted into the back of the internal condyle of the humerus: the patient cannot bring this muscle into action. Its tendon stands out distinctly to the inner side of the internal border of the humerus. There seems to be no muscular tissue between the skin and the posterior aspect of the humerus.

The deltoid and other muscles about the head of the humerus are well developed, and all movements at the shoulder joint can be fully executed.

The Left upper extremity.—The hand is narrower and less well shaped than the right: it also is provided with only three digits—the best developed of which seems to be the index, but its movements cannot be executed so forcibly as in the functional finger of the right hand.

To the radial side of this digit, and attached to it by a web, which extends up almost to its first interphalangeal articulation, is a rudimentary thumb. Its metacarpal bone is very small, measuring 1 cm. in length, and with the first phalanx lies in the soft tissues of the hand, not articulating with any bone: the digit is functionless.

The remaining digit, situated to the ulnar side of the index, may be the representative of either the third or fourth finger—I believe it is the third. It is maintained in a state of flexion at the interphalangeal articulations, the first of which is ankylosed, the second free, though not under the control of the patient. The metacarpo-phalangeal articulation can be feebly flexed and extended.

There is no trace of the other fingers.

The wrist joint is freely movable, the left trapezium is present.

No trace of the ulna can be made out.

The radius is much the same as on the right side. The head is united to the external condyle of the humerus by osseous ankylosis, but rather to its anterior aspect. The external border of the humerus ends abruptly at the external condyle, is not prolonged down into the radius as on the right side. Felt from behind, the lower extremity of the left humerus is bifid.

An artery is felt pulsating on each side of the anterior aspect of the forearm just above the wrist.

The muscles of the forearm are well developed.

What there is of a left biceps is inserted by a fine tendon into the anterior aspect of the internal condyle; and close to it, at the upper and back part of the condyle, is attached the tendon of the long head of the biceps, which here, as on the right side, seems to be the only part of that muscle present.

The radius is ankylosed to the humerus at an angle of about 150°.

The hands, when the arms hang by the sides, lie so that the palms touch the side of the upper part of the thigh.

There is no deformity of the lower extremities.

Remarks:—Congenital absence of the ulna seems to be an exceedingly rare condition. Förster, in his work, *Missbildungen d. Menschen*, does not mention it, though he states that of the bones of the upper extremity the scapula clavicles, and more often the radius, have been found absent.

Mr Hutchinson, writing in the *Archives of Surgery*, so recently as April 1892, on "Cases of Congenital Absence of the Radius," states, "It is remarkable that omission of the ulna and its associated digits does not occur. (I know of no example.)"

I have only been able to find three cases recorded, and I may perhaps give a short note of them.

One by Göller, in 1698 (quoted by A. Schnelle in an *Inaugural Dissertation*, published at Göttingen, 1875), but whose original paper I have not been able to see. According to Schnelle, Göller described a seven months fœtus, in which both ulnæ with four fingers were absent, only the radii and thumbs being present, and in the lower extremities, only the tibiale and great toes were present.

A second case, recorded by Senftleben in *Virchow's Archiv*, vol. xlv.:—

The patient was a recruit, æt. 21, in whose left ulna there was a defect, occupying the middle third of the bone, and measuring 2½ in., and at which point only a ligamentous string was to be felt. The movements at the elbow joint, in spite of a complete congenital dislocation of the head of the radius outwards, were stated to be nearly perfect, the hand and wrist normal.

A third case, reported by Roberts in the *Transactions of the Pathological Society of Philadelphia*, vol. xiii. :—

A man æt. 73, 6 ft. 4 in. in height, whose right ulna was absent, along with the third, fourth, and fifth digits, and their metacarpal bones; the pisiform, cuneiform, and unciform bones were absent from the wrist. There was limited movement in all directions between the radius and humerus, but neither complete flexion nor extension. On the left side the ulna was present, but the third and fourth digits with the third metacarpal bone were wanting. "The patient's grandfather (maternal) had one index finger stiff, and two (maternal) uncles had each a stiff little finger. One sister had a hand deformed like his, but she had a perfect child. Another sister's child had a hand deformed like his right hand." The patient had seven children, three of whom "had malformations similar to his" (but the reporter does not describe these).

In Göller's and Roberts' cases, the digits wanting were those of the ulnar side of the hand. It is curious that in the case of M. B., though the fourth and fifth digits of the left hand are wanting, the thumb is so rudimentary, and that in the right hand the thumb as well as the fourth finger is absent; in fact, there is no similarity at all between the digits attached to the two hands.

It is difficult to know whether these cases should be looked on as reversions or cases of arrest of development. Although in almost all the Mammalia the radius is the more important of the two bones of the forearm, I incline to the idea that they are due to arrest of development. The patient whose case has been described was shown before the Glasgow Medico-Chirurgical Society on 2nd December 1892, when a Committee consisting of Mr Henry E. Clark, Mr John Barlow, and Dr T. H. Bryce were appointed to consider the case, and the following is the report which they drew up:—

We, the committee appointed by the Medico-Chirurgical Society on December 2nd to consider the case of "congenital absence of the ulna," submitted by Dr Pringle on that evening, and to report thereon.

beg to report that we have examined the patient, and that while agreeing generally with Dr Pringle in his description of the condition, we have some doubt as to the following points:—

1st. Whether the rudimentary digit on the radial side of the right hand is not the thumb.

2nd. Whether the fully developed digit on the left hand is not the middle finger.

3rd. Whether the projection on the ulnar side of the wrist on both arms is not the lower end of the ulna firmly fused with the radius.

(Signed) HENRY E. CLARK.
JOHN BARLOW.
THOMAS H. BRYCE.

NOTES ON THE ACROMION. By Professor ALEXANDER MACALISTER, M.D., F.R.S. (PLATES XIV., XV.)

(Read to the Anatomical Society, 21st November 1892.)

THE acromion is one of the first of the bony landmarks of the body learned by the student, who is usually taught concerning it that it forms the summit of the shoulder. If by summit is meant the highest point, this is not the case in more than 50 per cent. of shoulders, in which the acromial end of the clavicle rises to a higher level; so that the acromion makes an outer ledge of the prominence of the shoulder, overtopped by the clavicle above, and outreached by the greater tuberosity of the humerus externally.

The acromion is one of the most variable portions of the scapula. Out of 100 scapulæ taken at random this process was narrowly falcate in 7, trigonal in 26, quadrate in 25, and of some intermediate shape in the remainder.

This variation in shape depends on the relative development of the several parts of its periphery and their consequent relations to each other. We may divide the margin of the process into the following parts:—

1. *The clavicular facet.* This is usually placed on the antero-internal margin; its surface is commonly elliptic-ovate, seldom distinctly oval, still more rarely (1 per cent.) circular. Its lower margin is sharp, its upper edge is often raised into a rough ridge, which is the highest part of the acromion: its surface in 75 out of 100 was placed obliquely, looking upwards and inwards, to correspond with the obliquity of the extremity of the clavicle, which is usually on a higher level.

2. In front and external to this facet is the *preclavicular margin,* which is short and usually sharp-edged below to give attachment to the coraco-acromial ligament, but rounder and more tuberculated above for the attachment of the foremost fleshy fibres of the acromial deltoid. This margin ends in the *anterior tubercle,* the foremost portion of the process.

3. This tubercle is usually inclined a little downwards, and gives attachment to the anterior tendinous origin of the acromial deltoid; from it (4) the outer or deltoid margin is continued backwards. This border is convex, and presents a row of tubercles along its upper edge, with intervening depressions. To these the tendinous slips of the deltoid are attached, while to the more uniform under edge the continuous tendon of this surface of the deltoid, together with the fibres continued outwards from the coraco-acromial ligament, are attached. The curve of this border and the sizes of the tubercles vary. There are generally three tubercles between the anterior tubercle and the metacromion corresponding to the three intermediate tendons of origin of the acromial deltoid.

5. The *metacromion* is the hindmost tubercle on this process, and projects in general as an angular outgrowth of the acromion on a plane well behind the glenoid cavity, as well as external to it, consequently it generally projects quite clear of the cavity, very rarely overhanging it. That is to say, a perpendicular let fall from any point of the metacromion will not touch the glenoid cavity.

This may be taken as the hinder limit of the acromion. The margin behind the metacromion is continuous with the lower edge of the scapular spine, and chiefly varies in the degree of approximation of the two sharp edges which give attachment to the two tendinous planes of the corresponding portion of the scapular deltoid, the space between them being the measure of the thickness of the intervening lamella of muscle. The point of convergence of these two planes is usually beneath the metacromion.

The upper edge of the scapular spine is continued on into the post-articular upper edge of the acromion. There are on this part of the spine two similar ridges which include between them the area of insertion of the trapezius. The deeper of these divides into two at a point a little more than a centimetre behind the articular facet; to the upper division line the edge of the trapezius is attached, to the lower the continuation of the supraspinous fascia. Between the two lines is an irregular area partly occupied by ligament, partly by soft areolar tissue.

The relative positions of these several parts vary within wide

limits. The long axis of the clavicular facet forms an angle with the axis of the scapular spine, which ranges from 122° to 156°. The angle formed by the preclavicular margin with the clavicular facet varies from 92° to 142°. The former angle we may call *retroclavicular acromial angle*, the latter the *preclavicular*. The prominence of the metacromion may likewise be measured by the angle between the hinder part of the outer margin, and the posterior edge continuous with the scapular spine. In the example of most prominent metacromion this angle was 89°; in the case of least prominence it was 139°.

We have now a means of characterising the leading types of the process. When the metacromial angle approximates to a right angle, and the preclavicular angle is also low, the acromion is quadrate. When a similar low metacromial angle coexists with a high preclavicular angle, the acromion is trigonal. If both angles are large, the acromion is falcate; with intermediate conditions the acromion is rounded or spatulate.

The commonest shape of the acromion in the Anthropoids is the trigonal, with a prominent metacromion and a short preclavicular edge. This condition I have also found in six Australians, in four Negroes, four Bushmen, and in two Lapp scapulæ. In European scapulæ this trigonal form was found in twenty-six, mostly females. The quadrate form was for the most part confined to what were, for their size and muscular impressions, presumably male scapulæ. The metacromion was inconspicuous as a prominence in 38 per cent. of European scapulæ.

The obliquity of the acromion is also a variable feature, and this produces a certain discrepancy in the description of the bone in our standard books. Thus Quain describes it as "compressed from above downwards," and Gray as "flattened from behind forwards." Both are really right in degree, and in some scapulæ the downward, in other the coronal, flattening becomes the marked feature. The concavity of the lower surface is a portion of the surface of a nearly spherical figure, which usually bears a definite proportion to the diameter of the epiphysary end of the humerus and its surrounding mass of ligaments and tendons which rotate beneath the acromion. The relation of

this surface to the vertical axis of the glenoid cavity can vary within wide limits.

If the inferior pole of the glenoid cavity be taken as a fixed point, the distance from this to the metacromion varies from 35 to 60 mm., and from this to the anterior tubercle ranges from 43 to 65 mm. The width of the acromion from metacromion to anterior tubercle varies from 28 to 54 mm., and the angle which this line of width forms with the gleno-metacromial line varies from 76° to 91°.

When the long axis of the glenoid cavity is placed vertically (an unnatural position), the horizontal plane of the metacromion will be seen usually to cut the cavity across somewhere in its upper third, but I have instances in which the plane passes clearly above the cavity, and in others it cuts it below its middle. I cannot find, however, that the indexes representing these conditions have any value, and after much troublesome measurement and calculation I have not reached any results which warrant my publishing them.

The development of the acromion process is also a matter of variety, and consequently its method has been differently stated by the different observers who have given original descriptions. The basis, as far as the hinder border of the metacromion, is ossified from the body centre as an outgrowth of the spine. At two years the acromion generally has assumed a definite shape in its cartilaginous condition. Out of fifteen scapulæ of children between two and four years of age, four were decidedly quadrate, one was falcate, the others trigonal or intermediate. In all the metacromion is larger, and projects proportionally more than in the adult, so that the amount of trigonality would have probably diminished with increased age.

Ossification had not begun in the cartilaginous area of one scapula of fourteen, but in one of sixteen it has made considerable progress. Up to fourteen years all has ossified as far as a line drawn on the upper surface of the acromion from the hinder border of the articular facet to the front of the metacromion. The first trace I have found consists of a number of bony points on the surface of the cartilage from the metacromion forward to the middle of the deltoid edge. These rapidly coalesce into a bony strip, narrow behind, wider in front, corresponding to

Uffelmann's osteo-epiphysis posterior. Almost simultaneously there appears a middle portion, consisting at first of a number of nuclei. Those ossifying points which lie along the outer margin of this area coalesce and form the most of the remainder of the outer edge. The ossification of this part extends gradually inwards, the clavicular-facet portion of it being the last to develop. Anteriorly a single large nucleus forms, from which the anterior tubercle is ossified.

All these nuclei are more extensive on the upper than on the lower surface of the acromion, the portion of the process formed by them on the lower surface being that bounded by a line drawn from the middle of the clavicular facet to the metacromion. I have counted in all five large and eight small nuclei in the scapula of a boy of seventeen. These have coalesced in a boy of eighteen into three large and four small centres.

It is extremely probable that the number of these ectosteally ossifying nuclei is irregular; but in all cases which I have examined of acromia under eighteen there are three sets of these which fuse into three independent parts,—the *metacromial* epiphysis, very slender; the *mesacromial*, which is always the most complex in formation; and the *preacromial*.

The order of ossification is also variable. In six cases the metacromial strip had united to the base while yet the others were detached. In all the apical preacromial portion had united with the mesacromial before the final consolidation of the latter with the spine. I have only twice seen the metacromial joined to the mesacromial before consolidation had begun. I have never found a central ossification in the cartilage like that figured by Quain or Gray. I can, however, believe that such may occur, but it must be the exception, not the rule, as in the twenty scapulæ which I have seen in this stage of growth, I have detected no trace of this condition.

The condition of the persistently separate os acromiale which I have found in fifteen out of a hundred scapulæ taken at random is due to the consolidation of the preacromial and mesacromial centres, and the persistence of their separation from the base of the spine and from the metacromial centre which always consolidates with the base. This is probably too high a degree of frequency of occurrence, as many of the specimens were

museum specimens,—among which cases of such an anomaly were naturally numerous. Out of the forty-five instances of this condition which I have examined I have never found the metacromial element attached to the ossicle. It is very rare to find the partition of the preacromial and mesacromial centres except in young bones. I have seen it once, but this was, I believe, only a transitory condition.

In the cases where the real os acromiale persists as a permanent condition, its union has ceased to be a true synchondrosis, and the uniting material is generally fibro-cartilage. I have once seen a true synovial joint with a surrounding capsule, but I have at least five times found a cavity in the uniting medium comparable, as far as the histological structure of its wall is concerned, with that in the sacro-iliac joint.

The order of ossification I believe to be normally—

1. Many bony nuclei, forming about the 15th year.
2. Consolidation of these into three marginal centres, about 17.
3. Extension of the mesacromial centre inwards towards the clavicle, between 17 and 18.
4. Consolidation of the metacromial centre with the basis, and of the preacromial and mesacromial with each other, about 18.
5. Consolidation of this element with the spine.

This description of the development of this process will be found to differ in many respects from the accounts of the ossification of the process given by different authors. A good account of observations on this process is that given by Uffelmann, *Anatomisch-Chirurgisch Studien*, Hameln, 1865.

In the above description I have spoken of the metacromion as if it were a point. In reality it is usually an area of some extent along the hinder edge of the spine from the metacromial angle, and is not uncommonly limited towards the spine by a tubercle, which may be called the post-metacromial tubercle. In all cases it has been only the aspect of the metacromial angle towards the outer side that has originated from the metacromial epiphysis, which here diminishes to a superficial crust,

and never extends on the hinder aspect of the process, which invariably is ossified along with the basis scapula.

EXPLANATION OF PLATES XIV., XV.

Plate XIV.—Types of Acromion Processes.

Fig. 1. Quadrate type, with a postarticular concavity.

Fig. 2. Variety of the quadrate type in which the clavicular facet is in the same plane as the postarticular margin.

Fig. 3. Trigonal acromion with prominent metacromion, from an Australian scapula.

Fig. 4. Falcate acromion.

Fig. 5. Trigonal acromion with prominent metacromion and rounded preacromial tubercle.

Fig. 6. Typical quadrate acromion.

Plate XV.

Ossification of Acromion.

Fig. 1. Acromion at 4 years: *c*, cartilaginous portion.

Fig. 2. Acromion at 14 years, the cartilaginous part diminished by the extension of ossification from the basis.

Fig. 3. Acromion at 17 years, many ectosteal centres of ossification: *c*, the portion which is still cartilaginous.

Fig. 4. Acromion at 18 years, with marginal ossification of preacromial, mesacromial, and metacromial parts. The portion marked *c* still cartilaginous.

Fig. 5. Acromion at 18 years, showing different condition of same parts.

Fig. 6. Acromion at 19 years: preacromial, mesacromial, and metacromial elements united into one ossicle.

Fig. 7. Acromion at 19 years.

Fig. 8. Os acromiale of preacromial and mesacromial elements.

THE FIRST COSTO-VERTEBRAL JOINT. By Professor ALEXANDER MACALISTER, M.D., F.R.S. (PLATE XVI.)

IN modern text-books there is a tendency to describe the ligaments of the costo-vertebral joints as if they were grouped in a certain arbitrary category, and, in consequence, the descriptions are usually meagre and diagrammatic. This may be in the interest of the student, but it is misleading from a scientific point of view. Every costo-vertebral joint has its own special mechanical characteristics, and these are remarkably constant even in thoraces of very different proportions.

As an introduction to a future detailed description of these, I desire to call attention to some points in the anatomy of the first vertebro-costal joint, which, although for the most part already described by earlier anatomists, yet have dropped out of some modern descriptions.

In recent editions of *Quain's Anatomy*, the name *costo-central* is used to characterise the joint between the head of the rib and the base of the pedicle of the vertebra. In colloquial descriptions one often speaks of the costal facet as on the body of the vertebra, but when one uses the name *centrum*, it implies greater precision in defining the part of the vertebra, and the name conveys an erroneous meaning, as the articulation in Man preserves its morphological character of being on the dorsal side of the neurocentral suture. If we must depart from the old time-honoured names, "costo-vertebral" and "costo-transverse," it would be better to call them both "costo-vertebral" joints, and speak of them respectively as "capitular" and "tubercular."

I. For the first rib-joint there is ventrally an anterior costo-vertebral or stellate ligament, imperfectly separate, as are all the stellate ligaments, from the front of the capsule. The strongest slip of this is the band attached to the base of the costal process of the seventh cervical vertebra. This extends at its insertion for some distance along the upper edge of the neck of the rib. As the axis of rotation of the first rib passes

directly behind its attachment, it limits the downward and forward motion of the rib, being made tense by this motion. Although not really separable from the capsule, this band appears as a prominent accessory fascicle which can be dissected off the face of that ligament.

The upper fibres of the capsule behind this band run horizontally from the root of the pedicle to the upper surface of the neck, and there is usually a posterior fascicle of the capsule distinct from the rest, which ascends inwards to the back of the body of the seventh cervical vertebra. This is Luschka's *ligamentum colli costæ jugale.* That anatomist was quite correct in pointing out that while this band in its position resembles Mayer's *ligamentum conjugale costarum*, yet is essentially different from it in nature. The real conjugal ligament is connected with the intervertebral substance; and my observations confirm those of Mr Bland Sutton, that it is in Man closely connected with, and usually inseparable from, the interarticular ligament.

Out of fifty first costo-vertebral joints examined during this term for the purpose, I have not found any instance of a true articular surface on the seventh cervical vertebra for the head of the first rib. I have seen the condition, but I believe it to be one of very rare occurrence.

The relative strengths of the upper and lower fascicles of the stellate ligament are correlated to the amounts of the excursion of the upper and lower borders of the first rib respectively in respiratory movements. In the lower ribs, the axis of motion passes through the interosseous ligament, and is at an intermediate level between the two borders. In the first rib the axis passes through the dorsal border of the preaxial edge of the head, hence the lower border moves through a greater space. It is this upper band which determines these relative degrees of mobility. The whole front of the head moves upwards and forwards in extreme inspiration.

The capsule is also distinct below the neck of the rib; the rough area which is usually present around the costal capitular facet on the vertebra is for the attachment of this ligament.

II. On carefully raising the upper part of the capsule, and dividing the whole anterior costo-vertebral ligament, it is easy to

show a thin, somewhat felted, layer of fibres passing from the intervertebral disc to the upper edge of the head of the rib. This lies directly over the articular cavity, and is separated from the overlying capsular ligament by a looser plane of areolar tissue. This represents the interosseous costo-vertebral ligament usually described as non-existent for this joint.

III. The superior costo-transverse ligament, also described as absent, is always present, but weak. It arises from the under side of the process which I have described elsewhere as the costo-transverse lamella of the seventh cervical vertebra, and is attached below to the upper and back part of the costal tubercle. Although in direction it runs downwards and a little outwards, yet it has the same relation to the posterior branch of the spinal nerve, as the corresponding ligaments in the lower costo-vertebral joints. It is in series with the hinder of the two lamellæ of this ligament of the other rib-joints, and the levator costæ is quite distinct from it. At first I was doubtful whether it represented the true superior costo-transverse ligament, or the *ligamentum tuberculi costæ superius* of Henle, but its close relation to the muscle and nerve mark it out as truly representing the former.

IV. The *ligamentum colli costæ* (middle costo-transverse ligament) is double, as it is for the four or five joints below; the inferior lamella described by Arnold being distinct and radiating, though thin. It is usually in two slips, an inner passing more directly forwards, and an outer passing obliquely outwards. These are separated by the usual vascular areolar tissue and fat from the stronger superior lamella. There is a smooth area between the attachments of these lamellæ on the back of the neck of the rib and a similar but rougher area on the front of the transverse process.

V. The posterior costo-transverse ligament is fairly strong, and consists of short fibres inseparable from the costo-transverse capsule.

A retro-costal anastomosis admitting of injection usually passes between the ligamentum colli and the capsule of the

capitular joint, homologous serially with the second stage of the vertebral artery in the cervical vertebræ above.

There is some obscurity in the text-books in relation to the first levator costæ muscle. The first rib is described as being furnished with such a muscle, but the scalenus medius is also described as having an origin from the seventh cervical transverse process. These are in reality the same structure, and if a separate levator costæ be described as arising from the seventh cervical transverse process for the first rib, then the scalenus should be regarded as terminating at its sixth cervical origin. When these are separated, it will be found that most of the area usually marked on the first rib as that for the costal attachment of the scalenus is really occupied by the levator costæ, and the scalenus insertion, if this separation is to be admitted, should be restricted to the marginal ridge and the area around the attachment of the levator costæ. The separation can be made, but is always more or less artificial, and it would probably be more natural to regard the whole muscle as scalenus medius, and to consider a separate levator costæ for the first rib as non-existent.

In one of my specimens there is a cervical rib on the right side, united to its vertebra by a weak capitular and a stronger tubercular capsule. This rib has no superior costo-transverse ligament, and its ligamentum colli is single. A down-going retro-costal anastomosis passed between its neck and the transverse process of the seventh cervical vertebra. This rib is 38 mm. long, and ends in a fibrous cord which is continued forwards to end in a small costal cartilage 25 mm. long attached to the sternum, between the sterno-clavicular joint and the first rib cartilage.

From these and the intervening cord, the bilaminar intercostal muscle of this supernumerary space arises. The scalenus anticus passes under this muscle to its normal attachment to the first thoracic rib; and the subclavian artery, and the lowest branch of the cervical plexus rose over the cord. A small intercostal filament of the eighth cervical nerve passed beneath, and ended in this intercostal muscle.

EXPLANATION OF PLATE XVI.

The First Costo-Vertebral Joint.

Fig. 1. First thoracic vertebra, with the rib removed on the right side. The articular surfaces, capsules, interarticular ligament, and the two planes of the ligamentum colli costæ are shown.

Fig. 2. Dorsal surface of the first rib, showing the attachments of the same structure.

Fig. 3. First rib of left side, showing the superior costo-transverse ligament and the upper slip of the stellate ligament.

Fig. 4. First rib, with its levator costæ muscle, and a small scalenus pleuralis overlying the suprapleural fascia (dome-like fascia of Sibson).

DELIMITATION OF THE REGIONS OF THE ABDOMEN.[1]

By D. J. CUNNINGHAM, M.D., D.C.L., F.R.S., *Professor of Anatomy in the University of Dublin.* (PLATES XVII., XVIII.)

PART I. PLANES OF DELIMITATION.

IN our endeavours to obtain a rational and a convenient method of subdividing the abdomen into regions, it is essential that we should keep clearly before us certain elementary points in the construction of the abdominal wall. In the upper part of the cavity the viscera are partially protected by the lower costal arches, and in its lower portion, to a less degree, by the iliac bones, whilst between these regions there is usually a narrow belt of abdominal wall which receives no skeletal support beyond that which is afforded to it by the vertebral column. This fundamental conception of the construction of the abdominal wall forms the basis upon which the majority of anatomists have proceeded in their attempts to find a proper method of subdividing the cavity. The loose and unscientific manner, however, in which this idea has been acted upon has been most ably pointed out by Professor William Anderson.[2] The scheme proposed in *Quain's Anatomy* alone carries out the idea to its logical conclusion. In this scheme the two horizontal lines which are employed traverse the lowest points of the thoracic wall and the highest points of the iliac crests respectively. These lines may be termed the *subcostal* and the *supra-iliac lines.* Two objections may be raised to this method of delimitation. One of these is altogether insuperable, viz., that in

[1] This paper gives the substance of a report which was submitted to the committee appointed by the Anatomical Society to consider the question of the delimitation of the abdomen. The report was accompanied by models of the liver, right kidney, and second part of the duodenum, which had been constructed with the view of illustrating their true shapes, and also their topography within the abdominal cavity.

[2] *Journal of Anatomy and Physiology*, vol. xxvi. p. 543.

certain cases the two lines actually coincide, so that an umbilical or intermediate zone does not exist. The second objection has been referred to by Professor Anderson: the umbilicus, which gives its name to the intermediate zone, may not lie altogether within it.

In sixteen subjects, comprising nine of males and seven of females, I have tested the relationship which exists between the subcostal and supra-iliac lines. In two (one male and one female) they coincided, whilst in the others the distance separating them varied from half an inch to two and a quarter inches. In the nine males the average distance was one inch; in the six females it was 1·2 inches. The position of the umbilicus with reference to the supra-iliac line varied slightly. In only one case did it lie altogether above the line. In the others the line grazed its upper border, or its lower border, or passed through its midst.

The cause of this variation in the relationships presented by these two lines is not far to seek. The supra-iliac line is fairly constant in its level. The variation is produced by a rise and fall of the subcostal line; in other words, the lateral depth of the thoracic wall varies considerably in different subjects, and in males there is reason to believe that it is relatively deeper than in females.

It is obvious, therefore, that if we decide upon retaining the three regional zones of the abdomen we must discard one or other or both of the lines proposed in *Quain's Anatomy*. Professor Anderson seems inclined to abolish the intermediate zone altogether, and to employ only one horizontal plane of subdivision. This, he proposes, should pass through the umbilicus. I am loath to adopt this mode of escaping the difficulty. There is a very great convenience in the old method of subdivision: it is fundamentally correct in principle; and further, it has sunk so deeply into our terminology, and taken so firm a hold upon all who have studied anatomy, that it would be exceedingly difficult to uproot. Professor Anderson himself is keenly alive to these objections to the scheme, and does little more than merely hint at it. I believe that a change of so radical a kind would for many years give rise to greater confusion than that which exists at present. Let us rather see if we cannot im-

prove upon our present method, and bring it within the area of accuracy and truth.

Although the most variable in regard to its relative level, I am of opinion that we should retain Quain's subcostal line. One alteration I would suggest, however, viz., that this plane should pass through the abdomen at the level of the most dependent point of the tenth costal arch, *i.e.*, the lowest of the fixed ribs,—the eleventh rib being a floating rib, and moreover so variable in point of length that it is well to discard it altogether. Further, the lowest point on the tenth costal

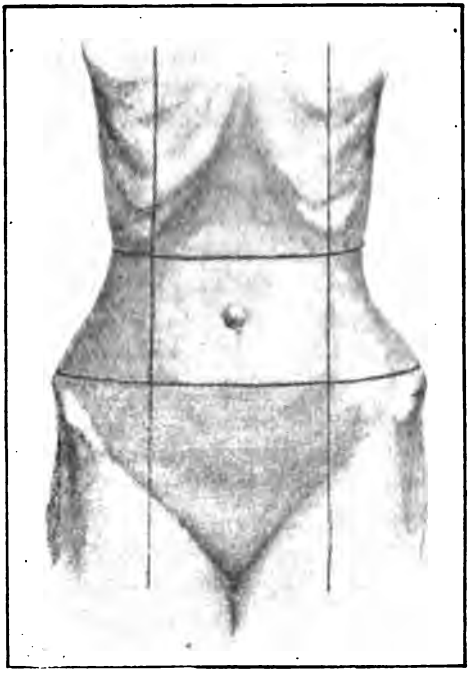

FIG. 1.—From a photograph of a female subject in the erect posture. The points between which the intertubercular and subcostal lines are drawn are well seen. The mid-Poupart lines were ascertained by dropping two plumb-lines from a height.

arch is always easily ascertained, and lies in front of the lateral line of the trunk, which is a distinct advantage. In many cases, indeed, it can be detected by the eye.

The subcostal plane so fixed, in a young male subject six feet in height (in which the supra-iliac plane was placed 2¼ inches lower down), passed through the upper part of the body of the third lumbar vertebra (*vide* tracing 4, Pl. XVII.).

It is the supra-iliac plane that I propose, therefore, that we should abandon. At the same time I am not prepared to adopt a plane passing through the anterior superior spines of the iliac bones. This would throw the greater part of the iliac fossa on each side into lumbar region, and constitute an extremely artificial method of delimitation.

Every anatomist is familiar with a prominent tubercle which juts out from the outer lip of the crest of the ilium about 2 inches behind the anterior superior spine. It constitutes the upper extremity of the strong bar of bone which extends upwards in the ilium from the upper part of the acetabulum, and which forms the convexity of the concavo-convex surface of the dorsum ilii. As a prominence it is usually better marked on the surface of the body than the anterior superior spine of the ilium, from the fact that when the body is viewed from the front it is the point on the iliac crest from which the outline of the flank starts. It is therefore placed on the outer aspect of the highest part of the iliac crest that is seen from the front in the living subject. It is true that the iliac crest rises to a higher level behind, but this higher point is not seen from the front, and can only be determined with exactitude when the subject is turned on its side.

I would suggest that this conspicuous tubercle on the crest of the ilium should be used as giving us the level at which we should place the lower plane of abdominal subdivision. By drawing a line between two points situated one on each crest of the ilium immediately above the iliac tubercle, the level of the plane may be readily obtained.

But there is abundance of proof to show that this is no new suggestion. It is merely a more exact mode of expressing what other anatomists have meant all along. When the editors of *Quain* speak of the highest point of the crest of the ilium, they in reality mean the highest point as seen *from the front*, and not as seen *from behind;* in other words, the level which is expressed by our *inter-tubercular line.* In evidence of this,

look at the figure which they give to illustrate the delimitation of the abdomen. Their lower line passes between the two iliac tubercles in question, the two points at which the outline of the trunk meets the crest of the ilium. The loose way in which anatomists have described this line has also led to the confusion which has arisen in connection with the position of the umbilicus with reference to the lower plane of abdominal delimitation.

The inter-tubercular line is an exceedingly convenient one, not only on account of the ready and exact manner in which it can be applied both in the living and the dead, but also on account of its affording us a really useful plane of delimitation

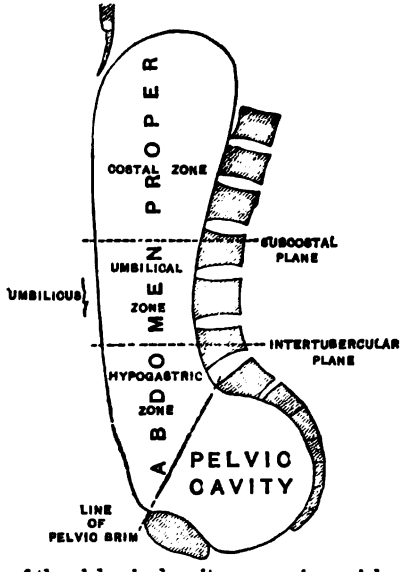

FIG. 2.—Outline of the abdominal cavity as seen in mesial section. The planes of subdivision are indicated by dotted lines.

The only objection to it is that it cuts off and transfers to the umbilical zone about 1¼ inches of the highest part of the iliac fossa. It traverses the vertebral column so as to divide the body of the fifth lumbar vertebra into two nearly equal parts. Behind, it emerges from the body of this vertebra at its postero-inferior margin (*vide* tracing 4, Pl. XVIII.).

Let us next inquire into the extent of the regions which are thus marked out by the subcostal and the inter-tubercular lines. Owing to the varying level of the subcostal plane the breadth

of the umbilical zone shows considerable differences in different subjects. Seven females gave an average breadth of 2·7 inches; nine males gave exactly the same results. The narrowest area noticed was in a female subject, in which it measured 1½ inches; the broadest zone in a male subject, in which it measured 4 inches. The following table shows the breadth of the umbilical zone in each of the twelve subjects examined:—

Breadth of the zone between the subcostal and inter-tubercular lines in sixteen subjects:—

Males.	Females.
2 inches.	1½ inches.
2 "	2½ "
2¼ "	3 "
2¼ "	3 "
2½ "	3 "
2½ "	3 "
3 "	3½ "
3½ "	
4 "	

The umbilicus always lies within this zone, and presents a fairly constant relation to the inter-tubercular line. As a rule, it lies from 1¼ to 1½ inches above it.

In the same sixteen subjects, I have also ascertained the depth of the costal and hypogastric zones, as measured along the middle line in front. The costal zone, measured from the lower border of the gladiolus of the sternum to the subcostal line, gave an average in the seven females of six inches; and in the nine males I obtained an exactly similar average. In the case of the hypogastric zone, measured from the inter-tubercular line to the pubis, the average depth was again precisely the same in the two sexes, viz., five inches.

The three zones, therefore, which are mapped off by the two horizontal lines in question, present the following average depths:—

	Males.	Females.
Costal zone, .	6 inches.	6 inches.
Umbilical zone,	2·7 "	2·7 "
Hypogastric zone,	5 "	5 "

It is a curious coincidence that in the two sexes the average depth of each zone should have turned out in the sixteen sub-

jects examined exactly the same. It must be remembered, however, that these are absolute results, and that if we take into account the greater height of the males, the relative depth of the abdomen in the females must have been greater than in the males. How far this may be considered to be the rule I am not at the present moment prepared to say,[1] but this much we do know, viz., that the lumbar section of the vertebral column in the female presents a greater relative length than the corresponding part of the column in the male, whilst the dorsal region is relatively shorter. Taking the entire length of the column as 100, the relative length of the dorsal and lumbar sections of it in the female are 45·8 and 32·8; and in the male, 46·5 and 31·7.[2]

We have referred to the rise and fall of the subcostal line produced by variations in the lateral depth of the thoracic wall in different subjects. It may be well to state here definitely that this is not due to differences in the level at which the ribs are attached to the vertebral column. The absolute length of the lumbar section of the vertebral column, even in individuals of different heights, is very constant. In six males I found the average to be 7 inches, and only two of the spines varied from this average—one to the extent of $\frac{1}{8}$ of an inch, and the other to the extent of $\frac{1}{4}$ of an inch. In female spines the same constancy in the lumbar section of the column is observed. The average absolute length in six spines was $6\frac{1}{2}$ inches, and the variations from this did not exceed half an inch.[3]

It is clear, therefore, that the rise and fall of the subcostal line in different individuals is brought about by differences in the slope and in the length of the ribs. In the females it did not appear that tight-lacing materially affected the position of the subcostal line.

So far as the vertical lines of subdivision are concerned, I

[1] In connection with this point, we should not lose sight of the fact that there is reason to believe that the sternum of the female is relatively shorter than that of the male.

[2] "Cunningham Memoir," *Royal Irish Academy*, No. 2, p. 80.

[3] These measurements were made on tracings obtained from frozen spines, divided in the mesial plane. The lumbar part of the column in each case was measured in a straight line from the antero-superior corner of the first lumbar vertebra to the antero-inferior corner of the fifth lumbar vertebra.

do not think that we could improve upon those in general use, viz., two perpendicular lines reared from the mid-points of Poupart's ligaments. The two planes which are thus indicated on the surface may be termed the "right and left mid-Poupart planes."

Whilst I would, therefore, recommend the retention of these lines, I must not be understood to imply that they are altogether free from objection. The two sides of the body are not often absolutely symmetrical. Thus it will be frequently found that these lines strike the lower margin of the chest at different points on the two sides, and at different points in different subjects. Further, it will sometimes be seen that the districts to the right and left of these lines are not of equal extent. So far as my experience goes, it would appear that the left district (composed of left hypochondrium, left lumbar region, and left iliac region) is in certain cases distinctly smaller than the corresponding district on the right side. Lastly, the mid-Poupart lines leave us with a very wide district between them. This, however, is no great objection, as the mesial plane affords us an excellent means of subdividing it into a right and left portion.

The employment of oblique lines, or the curved lines suggested by Dr Wilberforce Smith (viz., the outer border of the rectus abdominis), would in my opinion only lead to confusion. When an artist is desirous of reproducing a sketch in exact proportion, he does not draw oblique lines upon the paper which is to receive the drawing, but a series of horizontal and vertical lines. The same applies to the abdomen. It is easier for us mentally to map in the position of the viscera with reference to a "chess-board" arrangement of lines, than with reference to a series of oblique or curved lines. To the *linea semilunaris* I would urge certain special objections, viz.—(1) it is not always marked on the surface of the abdomen; (2) it is not a fixed line, but varies with the development of the rectus abdominis muscle, and in the female it is extremely variable from other causes; (3) the lateral district which it would map out would be very much too wide in its lower part.

PART II. TOPOGRAPHY OF THE VISCERA.

It is not only necessary to fix upon planes of delimitation, but, as Professor Anderson has remarked, it is also requisite that we should know the structures that are divided by these planes, and also those that lie in the regions which are marked out. The observations which I have to offer on this aspect of the question are derived entirely from the examination of one subject, but when these are compared with the results obtained by other anatomists, a close correspondence will be remarked. I consider, therefore, that we may provisionally regard them as affording us that "regional type" to which Professor Anderson alludes, and which he rightly says "would be of material service in medical education."

It is now nearly four years ago since I resolved to make a series of sections through the frozen abdomen along lines and planes which would enable us to accurately localise the viscera in the different regions of the cavity. For some time I was unable to carry out this project, because no suitable subject presented itself. For the success of the scheme it was necessary that we should obtain a well-developed healthy body. At last an opportunity occurred. A well-built male, about thirty years of age, who had committed suicide by the clumsy method of cutting his throat, was brought into the school. He was six feet in height, rather spare but not emaciated, and so far as our superficial inspection went, he seemed to be healthy. It afterwards turned out that we were not quite correct in our surmise as to the healthy condition of all the internal organs. There were cavities in the lungs, tubercular disease of the vesiculæ seminales, &c. The abdominal organs, however, were perfectly sound. Having placed the body on its back, so that an accurate mesial section could afterwards be made, it was frozen entire in the ordinary way. Unfortunately, without due forethought, the left thigh was slightly flexed and adducted. This produced a small degree of tilting of the pelvis to the opposite side, the effect of which will be seen later on, when the sections come to be studied. In four days the subject was ready for section. After the removal of the head and limbs, a series of horizontal

sections were made through the upper part of the trunk down to a level a short distance above the nipples. The lower part of the pelvis was then removed by a horizontal cut at the level of the pubic crests. The portion of the trunk which remained included the whole of the abdomen, with the exception of the lower part of the pelvic cavity.

A series of sagittal sections were made through this abdominal block. Three of these were planned so as to pass through the right and left mid-Poupart planes and the mesial plane. Each of the four slabs thus obtained was still further subdivided in a vertical sagittal direction into two as nearly equal parts as possible. These sections were made with a fair amount of success. Owing to the slight degree of tilting of the pelvis, the portions of the innominate bones cut in the mid-Poupart planes differ to some extent. Further, the sections to right of the mesial plane deviated to a small degree from the accurate

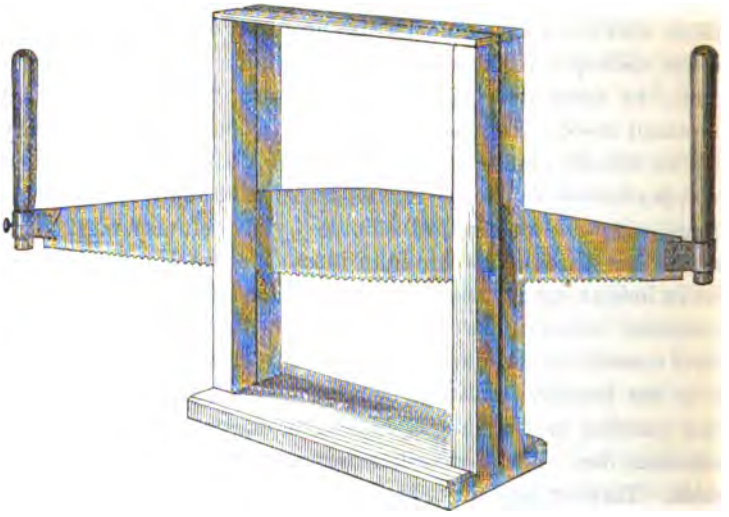

FIG. 3.

sagittal direction which we had proposed the saw should follow. The apparatus which I employ to ensure that the saw will follow a desired plane was too small to take in so large a block, and as we proceeded in our section-cutting from left to right, the portion still remaining to be cut became so narrow

that it was an exceedingly difficult matter to obtain absolutely accurate results.

The stomach and intestinal canal were empty, and the abdominal wall in consequence was much retracted. In the mesial plane opposite the umbilicus, the antero-posterior diameter of the cavity was only 1¼ inches.

It will be most convenient to indicate, in the first place, the parts cut through in the two mid-Poupart planes of section, and then localise the viscera in the different regions.

Left mid-Poupart Plane.—The saw passed very accurately through this plane. Owing to the slight tilting of the pelvis, the innominate bone is cut behind about ¼ of an inch too far out. In place of passing through the pelvis, as it should have done, ½ an inch to the outer side of the sacro-iliac joint, the saw traversed the bone about ¾ of an inch to the outer side of the articulation (tracing No. 6, Pl. XVIII.).

The structures divided in this plane are—(1) the spleen, so that at least one-third of the organ lies to right and two-thirds to the left of the plane of section; (2) the empty stomach, through the greater part of its length; (3) the liver, one and a half inches from its left extremity; (4) the left kidney, so that by far the greater part of the organ lies to the right of the plane of section; (5) the colon in four different places, viz., at the summit of the splenic flexure, the termination of the transverse colon, the commencement of the descending colon, and the sigmoid flexure; (6) some coils of the small intestine.

Right mid-Poupart Plane.—When the tracing (No. 2, Pl. XVII.) which shows the parts cut in this plane is compared with that which shows the structures cut in the left mid-Poupart plane, it will be noticed that the portion of the innominate bone divided differs considerably. Indeed, on the right side the saw has passed through the outermost part of the sacro-iliac joint, *i.e.*, half an inch too far in. This is partly due to the tilting of the pelvis already referred to, and partly to a slight deviation of the saw inwards as it was carried backwards through the trunk. It will be also noticed that the outer portion of the psoas muscle is sliced off. The section should have passed to the outer side of this, and divided the muscle only in the neighbourhood of Poupart's ligament.

The parts divided in this section are seen in tracing No. 2 (Pl. XVII.), which was taken from the surface of the slab which lay to the right of the plane of section:—(1) The liver bulks most largely in this section. It is cut immediately to the right of the gall-bladder; indeed, the gall-bladder has suffered somewhat by the section. The saw has passed through its right wall. (2) The kidney is divided so that very nearly two-thirds lie to the right of the plane of section—only one-third to the left of it. (3) The hepatic flexure of the colon is cut at the point where it is giving place to the transverse colon. (4) Curiously enough, the only part of the small intestine divided in this plane of section is the terminal part of the ileum. This part, about four inches in length, is seen in the slab which bounds the plane of section on the right, passing vertically upwards on the psoas. Had the section passed accurately backwards through the mid-Poupart plane, a much smaller portion of the ileum would have been seen in this slab.

Instead of giving a catalogue of the viscera contained in each region, our purpose will be better served if we describe the position of each viscus, with reference to the planes of subdivision that we have chosen. In the tracings taken from the surface of the slabs, the three horizontal lines indicate the sub-costal, supra-iliac, and inter-tubercular planes. It will be remembered that the last-mentioned plane is the one which has been selected as the lower boundary of the umbilical zone. In this subject the intermediate zone measured four inches in depth, *i.e.*, between the sub-costal and inter-tubercular planes.

KIDNEYS.—A considerable difference is noticed in the position of the two kidneys. The position of the *right kidney* is shown in tracings Nos. 1, 2, and 3 (Pl. XVII.). In these it is seen to be sunk deeply into the posterior surface of the liver. About two-thirds of the organ is placed in the hypochondriac region, and one-third in the epigastric region. The subcostal plane crosses its lower end, so as to cut off a portion not exceeding a quarter of an inch in length. This is the only portion of the right kidney which enters the lumbar and umbilical regions.

The *left kidney*, in the subject under consideration, is for the most part contained within the epigastric region. Rather less than one-third of the organ lies to the left of the mid-Poupart plane in the hypochondrium. Its position may be studied in tracings Nos. 5 and 6.

(Pl. XVIII.). It will be seen that its lower end does not reach the subcostal plane.

The fact that only on the right side did the kidney enter the lumbar and umbilical regions was to me a matter of surprise. In the admirable sketches given by Dr Symington to illustrate the true position and shape of the liver and kidney, a somewhat similar condition will be seen. In plate iv. of his work[1] both kidneys appear to be placed above the level of the subcostal plane. In the subject at present under consideration, the kidney is separated from the highest point of the iliac crest by an interval of two inches. The variability which is exhibited in different subjects as to the width of this interval formed the subject of a Report from the Committee of Collective Investigation. This variability goes hand in hand with the variations which we have noted in the lateral depth of the thoracic wall. The kidneys rise and fall with the rise and fall of the subcostal plane.

A model of the right kidney in this particular subject was submitted to the Committee. The form is somewhat different from that which we are in the habit of regarding as peculiar to the kidney. But into this we need not enter at present.

LIVER.—(See tracings Nos. 1 to 7.)—A model which exhibits the true shape of the liver in the subject under consideration also accompanied this Report. It must be remembered that the stomach and great intestine were empty. This partly accounts for the differences in form which are seen to exist between this model and that prepared by Professor His. The inferior surface, as described by His, in my model looks directly backwards, and the antero-posterior diameter of the liver is greatly reduced. All this is due to the empty state of the hollow viscera in relation to it, and also to the consequent retraction of the abdominal wall. These conditions, however, would only exercise a partial influence in altering the relations between the liver and kidney. In the model prepared by His, the renal impression looks downwards and is a shallow fossa; in the model submitted to the Committee, the renal impression will be seen to be a deep excavation, which looks directly backwards, and into which the entire kidney is sunk. I was prepared for this from the study of a series of transverse sections in my possession. Symington has also called attention to the same point, and has figured a similar depression in the liver. It is important to note also that his observations were made on a subject in which the stomach was distended. The model of His, therefore, clearly requires some modification in this respect.

The position of the liver is seen in the various tracings submitted to the Committee. The organ lies in all the three regions of the costal zone. The portion which lies in the left hypochondrium is represented by one inch and a half of the extremity of the left lobes. The right surface is very steep and long, and extends downward

[1] "On Certain Physiological Variations in the Shape and Position of the Liver," *Trans. Med. Chir. Soc. Edin.*, 1887, plate iv.

into the lumbar region for about one inch (see tracing No. 1, Pl. XVII.). Here the liver attains a lower level than the lower end of the kidney. Symington has observed a similar relationship, but is inclined to regard it as being due to an increase in the vertical diameter of the right lobe of the liver brought about by the compression produced by a distended stomach.

The different parts of the liver which occupy the three regions of the costal zone are exhibited in the accompanying outline sketch of the model referred to (fig. 4).

Amongst the many interesting points to be noted in connection with this model of the liver we may specially mention—(1) the intimate relationship between the right lobe and the kidney, already referred to; (2) the small extent of the impression for the empty

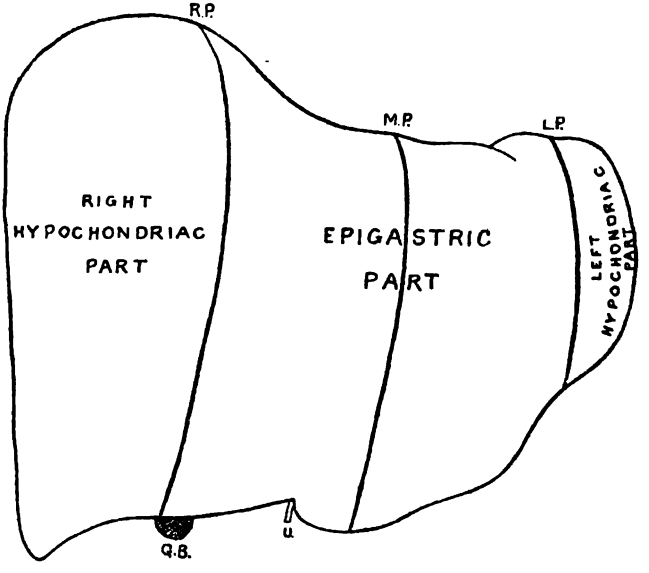

FIG. 4.—Outline obtained from a tracing of a photograph of the model constructed from the liver.

R.P.—Right mid-Poupart plane; M.P.—Mesial plane; L.P.—Left mid-Poupart plane; G.B.—Gall Bladder; U.—Ligamentum teres.

stomach; (3) the large size of the tuber omentale; (4) the marked depression for the œsophagus; (5) the depression on the inner part of the tuber omentale corresponding to the injected cœliac axis and the grooves leading away from this, which indicate the course taken by its three radiating branches.

GALL BLADDER.—(Tracing No. 2, Pl. XVII.)—The gall-bladder lies in the epigastric region close to the right mid-Poupart plane, and even encroaches to a very slight extent beyond this plane into the hypo-

chondriac region. The fundus approaches the subcostal plane, but is separated from it by an interval of rather more than half an inch.

STOMACH. — (Tracings Nos. 4, 5, 6.) — With the exception of a little mucus the stomach was empty, and its lining mucous membrane was thrown into a series of infoldings which almost completely obliterated its cavity. The left mid-Poupart plane passes through the stomach about half an inch to the left of the lesser curvature. Very nearly equal portions of it lie in the hypochondriac and epigastric regions. It is seen that the greater part of the stomach, in its empty condition at least, is very nearly vertical in its direction. Placed in the interval between the liver and spleen, it extends downwards, with a slight inclination forwards and to the right (tracing No. 6). This vertically-placed portion of the organ may be said to comprise very nearly three-fourths of its bulk. The pyloric fourth is horizontal, and lies in the epigastrium, partially overlapped by the thin edge of the left lobe of the liver (tracing No. 5). The pyloric opening corresponds accurately with the mesial plane (tracing No. 4), where it lies completely under shelter of the liver, half an inch above the subcostal plane, and $4\frac{3}{4}$ inches below the lower end of the gladiolus. The œsophageal opening lies a short distance to the left of the mesial plane.

SPLEEN.—About one-third of the upper and inner part of the spleen lies in the epigastrium; the remaining two-thirds occupy the left hypochondrium (tracings Nos. 5, 6, 7, Pl. XVIII.).

SUPRARENAL CAPSULES.—These are both placed high up in the epigastric region.

PANCREAS.—The pancreas is almost entirely placed in the epigastrium; its tail crosses the left mid-Poupart plane and enters the hypochondriac region.

DUODENUM.—The first part of the duodenum has a position very similar to that exhibited in figure 2 in Dr Symington's article upon the liver. It lies entirely in the right part of the epigastric region, completely under shelter of the liver, and in relation to the lobulus quadratus, the gall bladder, and the parts entering the transverse fissure (tracings Nos. 3 and 4). It ascends slightly as it passes to the right. Thus at its commencement it is only half an inch above the subcostal plane, whilst at its termination it is one inch above that level.

The second part of the duodenum (tracing No. 3) descends into the umbilical region. The right mid-Poupart plane grazes its convexity, but does not open into it. It is moulded on the convex surface of the psoas, and merely touches the lower end of the kidney. In a distended condition it would, no doubt, lie in front of the kidney.

The third part of the duodenum crosses in front of the vertebral column in the umbilical region. In the mesial plane (tracing No. 4) it lies in front of the third lumbar vertebra, and immediately below the subcostal plane. Lastly, ascending into the epigastric region, it ends on the left side of the second lumbar vertebra. The jejunum is divided close to its commencement in the epigastric region in the

section midway between the mesial plane and the left mid-Poupart plane (tracing No. 5).

Even in absolutely normal conditions, the relations presented by the duodenum and the kidney are seen to be very different in different subjects. Dr Brooks, who has studied this question, has kindly supplied me with three drawings which illustrate this point (fig. 8, Pl. XVIII.). In one of these the duodenum is related to the upper end of the kidney; in another it overlies the inner part of the kidney throughout its whole length; in the third it merely touches its lower end, as in the subject at present under consideration.

This variability in the mutual relations exhibited by these two organs is a matter of very great interest, and I believe that it is due to changes in the position of the kidney. We have seen that the kidney moves up and down with the rise and fall of the subcostal plane; in other words, its position is affected by the lateral depth of the thoracic wall. In health the duodenum, however, is very constant in its position. It is moulded on the vertebral column, and its position is in no way influenced by those conditions which affect the level of the kidney. If I am right in these views, it would be possible to foretell by an examination of the exterior of the body and by the determination of the level of the subcostal plane, the relative position of the kidney and the duodenum.

Coils of Small Intestine.—With the exception of the terminal four inches of the ileum, there is no part of the small intestine placed to the right of the right mid-Poupart plane. The coils of the small intestine chiefly occupy the hypogastrium; but they are also found in the umbilical left lumbar and left iliac regions, whilst a small portion of the jejunum ascends into the left hypochondrium.

The terminal four inches of the ileum passes vertically upwards on the psoas in the right iliac fossa (tracing No. 2) immediately to the right of the mid-Poupart plane, and ends in the cæcum at the level of the inter-tubercular plane.

Cæcum.—The cæcum lies almost entirely in the right iliac fossa. The ileo-cæcal opening is placed immediately above the inter-tubercular plane. When distended, the cæcum no doubt encroaches further into the right lumbar region. Indeed, Symington has recently figured the ileo-cæcal valve in the distended gut at the level of the disc between the fourth and fifth lumbar vertebræ,[1] *i.e.*, three-quarters of an inch above the inter-tubercular plane.

Colon.—The ascending colon proceeds vertically upwards in the right lumbar region until its progress is arrested by the liver. The hepatic flexure takes place at this point, but only a very small portion of its summit is in the right hypochondrium (tracing No. 2). The subcostal plane cuts off about one inch of its highest part. From this the transverse colon descends and enters the umbilical region (tracing No. 3), across which it may be traced into the left lumbar region. It reaches its lowest level in the mesial plane (tracing No. 4), where it lies rather more than half an inch below the subcostal plane.

[1] *Proc. Anat. Soc.*, August 1892, p. 11.

It gains the level of the subcostal plane in the left mid-Poupart plane, and immediately turns upwards into the left hypochondrium (tracing No. 6). In this region it attains a position in the interval between the stomach and spleen, and bends upon itself to the form of the splenic flexure (tracing No. 6). The summit of the flexure is placed immediately below the left extremity of the liver, four inches above the subcostal plane (tracing No. 7). The descending colon proceeds downwards in front of the kidney and through the left lumbar region into the left iliac fossa, where it gives place to the sigmoid flexure. This portion of the colon is only partly contained in the iliac region. A considerable portion of it crosses the mid-Poupart plane, and comes to occupy a place in the hypogastrium and pelvis.

In the first volume of *Quain's Anatomy* (ninth edition) a table is given which details the position of the abdominal viscera with reference to the planes of subdivision. Making allowance for the difference in the level of the two horizontal planes of subdivision, the facts stated in this table agree in the main with the results which I have obtained.

Throughout the greater part of this work I have received the able assistance of Dr Brooks. He has tested the results on a large number of freshly-opened subjects, and he assures me that in cases where the viscera are healthy he has almost invariably found them in the regions indicated above.

EXPLANATION OF PLATES XVII., XVIII.

Plate XVII.

Tracing 1.—From the left surface of the slab which lay to the right of a plane of section midway between the right lateral surface of the trunk and the right mid-Poupart plane.

Tracing 2.—From the left surface of the slab which lay to the right of the right mid-Poupart plane of section.

Tracing 3.—From the left surface of the slab which lay to the right of a plane of section midway between the right mid-Poupart plane and the mesial plane.

Tracing 4.—From the left surface of the slab which lay to the right of the mesial plane.

Plate XVIII.

Tracing 5.—From the left surface of the slab which lay to the right

of a plane of section midway between the mesial plane and the left mid-Poupart plane.

Tracing 6.—From the right surface of the slab which lay to the left of the left mid-Poupart plane of section.

Tracing 7.—From the right surface of the slab which lay to the left of a plane of section midway between the left lateral surface of the trunk and the left mid-Poupart plane.

Fig. 8.—Diagrams to show variations in the relations of the duodenum and right kidney; also the peritoneal relations of the left kidney.

PLATE XVII.

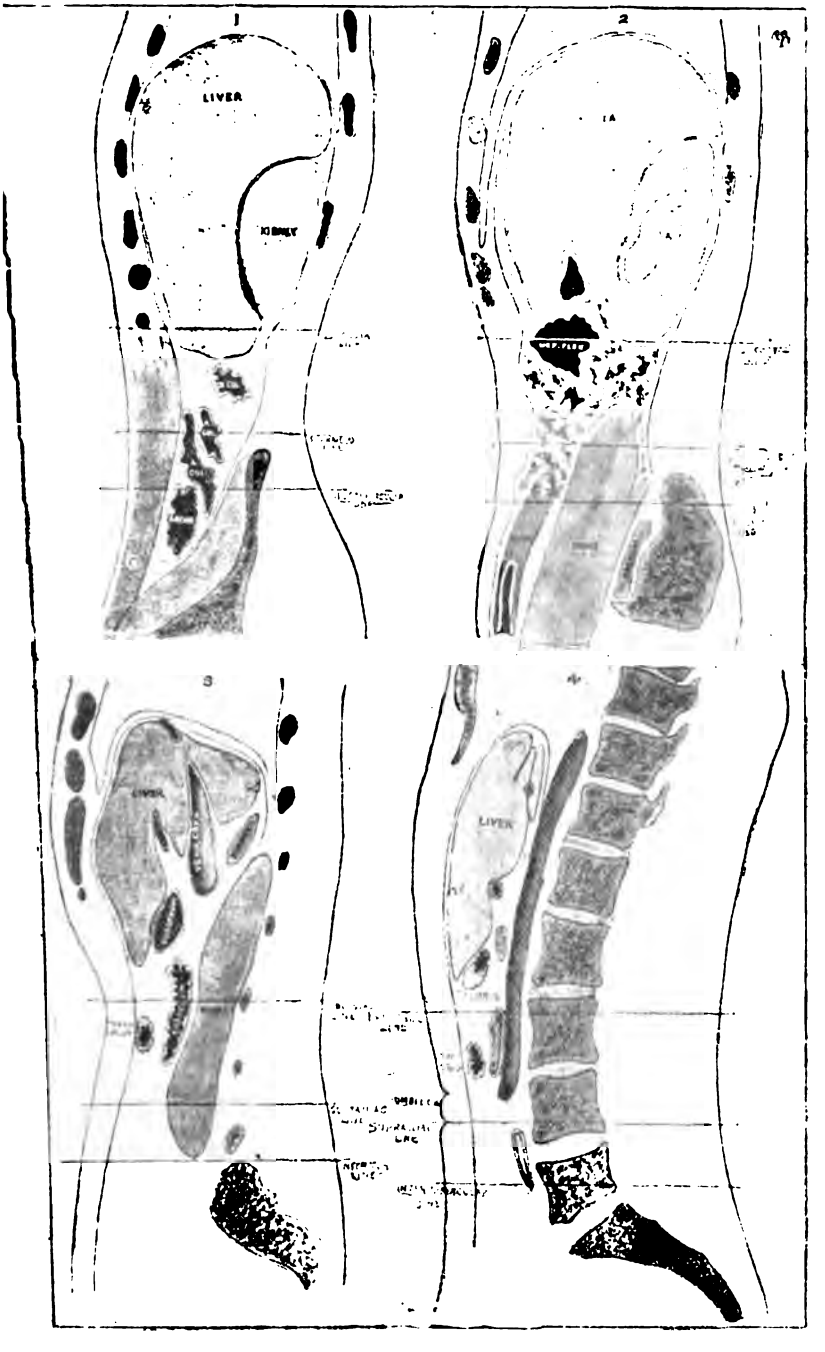

PLATE XVIII.

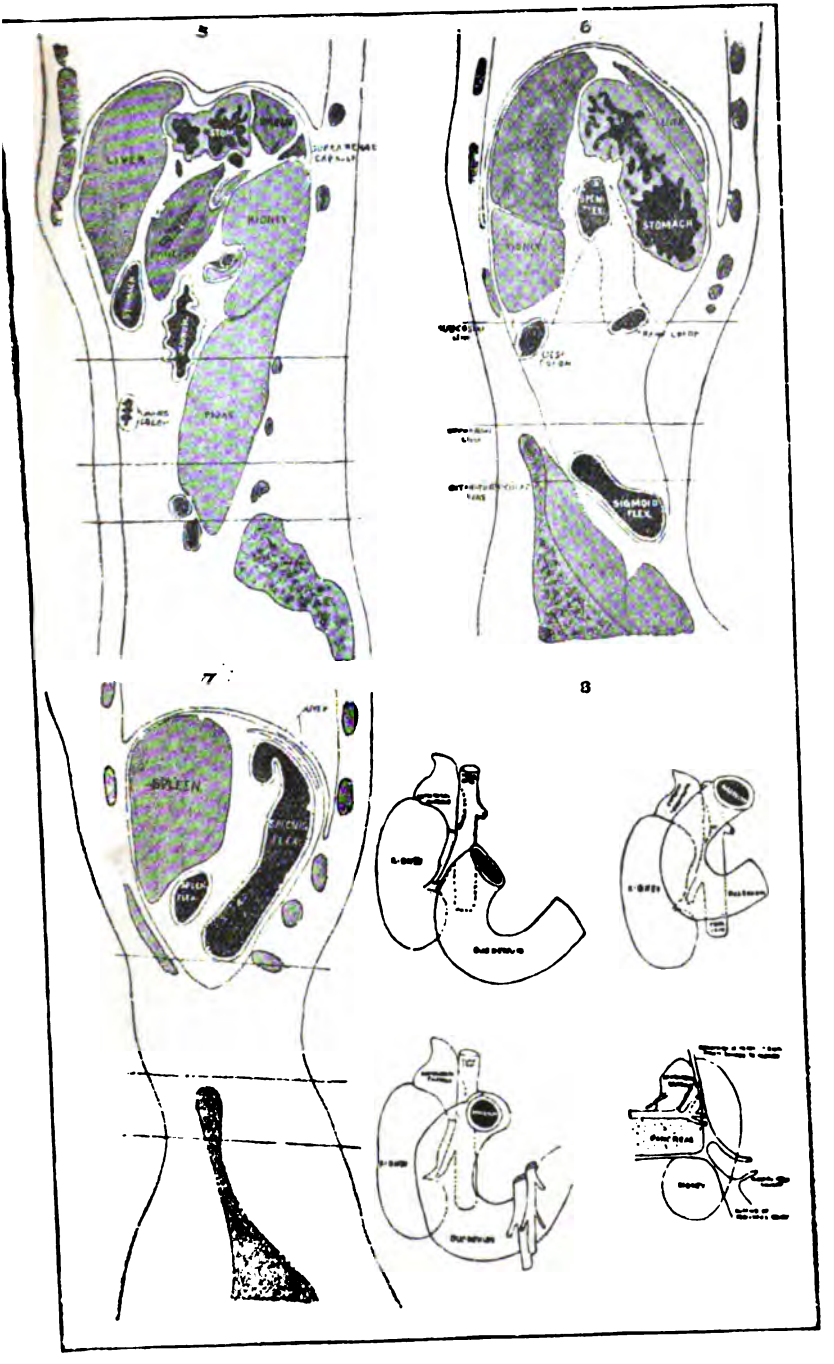

It gains the level of the subcostal plane in the left mid-Poupart plane, and immediately turns upwards into the left hypochondrium (tracing No. 6). In this region it attains a position in the interval between the stomach and spleen, and bends upon itself to the form of the splenic flexure (tracing No. 6). The summit of the flexure is placed immediately below the left extremity of the liver, four inches above the subcostal plane (tracing No. 7). The descending colon proceeds downwards in front of the kidney and through the left lumbar region into the left iliac fossa, where it gives place to the sigmoid flexure. This portion of the colon is only partly contained in the iliac region. A considerable portion of it crosses the mid-Poupart plane, and comes to occupy a place in the hypogastrium and pelvis.

In the first volume of *Quain's Anatomy* (ninth edition) a table is given which details the position of the abdominal viscera with reference to the planes of subdivision. Making allowance for the difference in the level of the two horizontal planes of subdivision, the facts stated in this table agree in the main with the results which I have obtained.

Throughout the greater part of this work I have received the able assistance of Dr Brooks. He has tested the results on a large number of freshly-opened subjects, and he assures me that in cases where the viscera are healthy he has almost invariably found them in the regions indicated above.

EXPLANATION OF PLATES XVII., XVIII.

Plate XVII.

Tracing 1.—From the left surface of the slab which lay to the right of a plane of section midway between the right lateral surface of the trunk and the right mid-Poupart plane.

Tracing 2.—From the left surface of the slab which lay to the right of the right mid-Poupart plane of section.

Tracing 3.—From the left surface of the slab which lay to the right of a plane of section midway between the right mid-Poupart plane and the mesial plane.

Tracing 4.—From the left surface of the slab which lay to the right of the mesial plane.

Plate XVIII.

Tracing 5.—From the left surface of the slab which lay to the right

of a plane of section midway between the mesial plane and the left mid-Poupart plane.

Tracing 6.—From the right surface of the slab which lay to the left of the left mid-Poupart plane of section.

Tracing 7.—From the right surface of the slab which lay to the left of a plane of section midway between the left lateral surface of the trunk and the left mid-Poupart plane.

Fig. 8.—Diagrams to show variations in the relations of the duodenum and right kidney; also the peritoneal relations of the left kidney.

PLATE XVII.

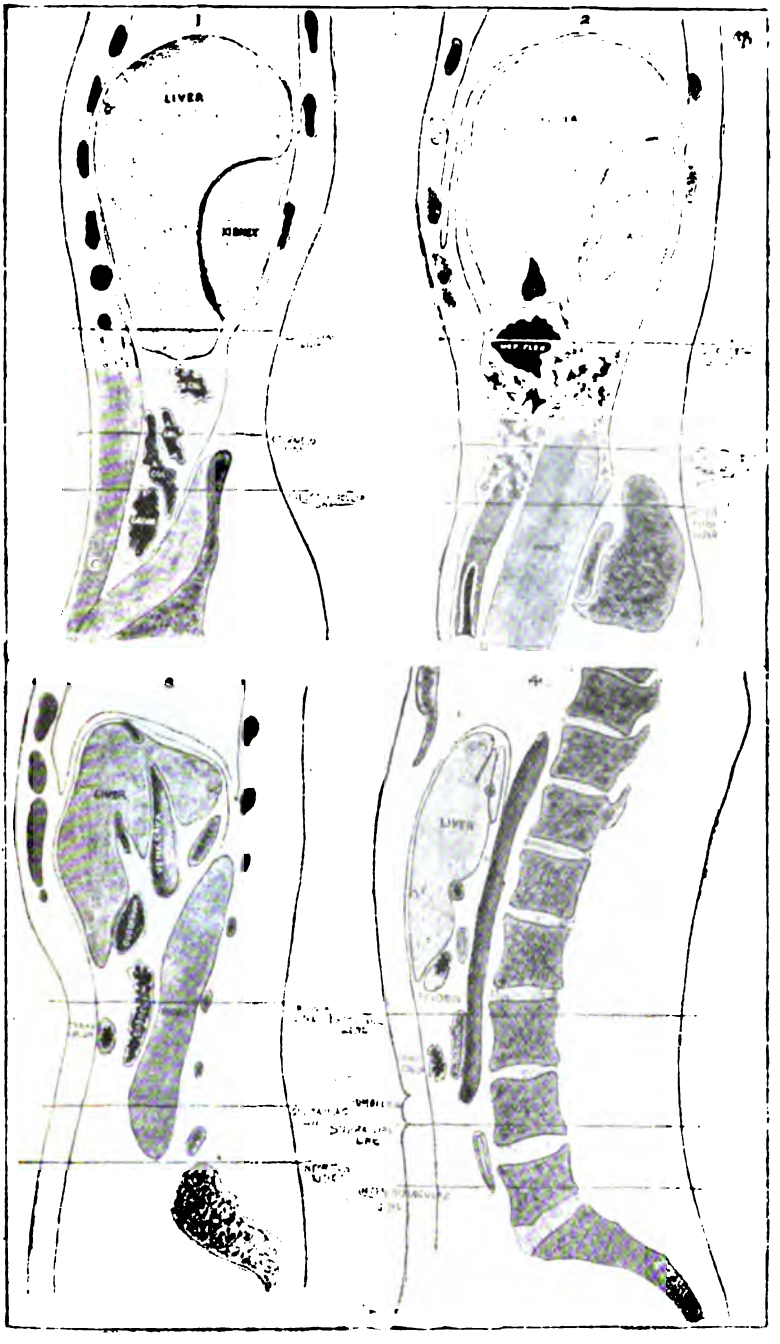

PLATE XVIII.

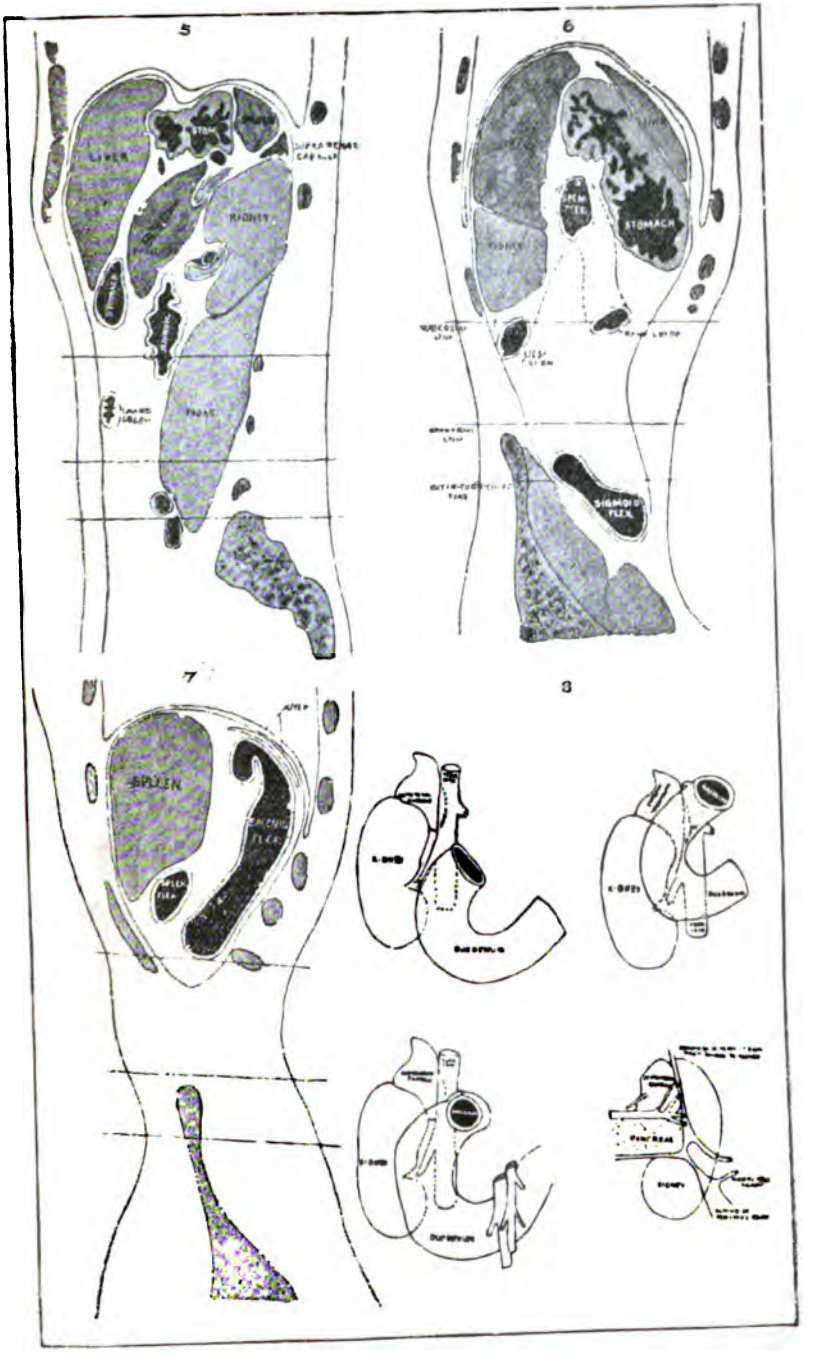

ORIGIN OF THE OPHTHALMIC ARTERY FROM THE MIDDLE MENINGEAL. By JAMES MUSGROVE, M.D., M.R.C.S., *Demonstrator of Anatomy, Edinburgh University.*

THE intimate connection between the blood supply of the eyeball and that of the brain, as revealed by ophthalmoscopic examination of the retina in cerebral disease, gives a special significance to the varieties in the origin and distribution of the ophthalmic artery. The two conditions that may give rise to varieties in the arterial supply of the orbit are, first, a demand made upon the ophthalmic artery to extend its area of distribution, as when the meningeal arteries of the middle fossa of the skull are absent or smaller than usual, and the ophthalmic sends a branch to supply the deficiency; and second, where the ophthalmic artery, from some cause or other, has either not been developed, or has become obliterated, and the blood supply of the orbit has to be drawn from some other source. In this case it is the internal maxillary, and usually its middle meningeal branch, rather than the facial artery, that takes its place. And thus the orbit becomes associated in its blood supply with the cranial wall and the external carotid artery, and loses that intimate connection with the brain which it has when supplied from the internal carotid.

In the eighth volume of this *Journal*, Professor Curnow [1] described "two instances of irregular origin of the ophthalmic and middle meningeal arteries," and in the second of these cases there was given off from the middle meningeal the whole of the ophthalmic artery, except the arteria centralis retinæ—an exception that is interesting as showing that the retina preserved its connection with the cerebral circulation, while the remainder of the orbit was supplied from the meningeal system. Henle [2] mentions cases where the middle meningeal gave off the whole ophthalmic artery, or an accessory ophthalmic, or only the lachrymal branch.

In a case which recently occurred in the dissecting-room of Edinburgh University, the whole of the blood for the orbit was

[1] *Journ. Anat. and Phys.*, vol. viii. page 156.

[2] *Handbuch der menschlichen Anatomie.*

supplied by a branch from the middle meningeal, and the remains of what appeared to be the normal ophthalmic artery were found as an impervious fibrous cord, traceable back through the optic foramen to the region of the internal carotid.

On the *left* side, where the variety was first observed, a large artery arose from the anterior branch of the middle meningeal, and passed to the orbit through the outer part of the sphenoidal fissure. It coursed forwards and inwards above the external rectus muscle, but below the lachrymal nerve, and then between the optic nerve and superior rectus to the inner side of the orbit. As the artery passed through the sphenoidal fissure, it gave a small vessel which passed forwards for a short distance and then turned outwards, and probably supplied the lachrymal gland, but its connection had been lost in the previous dissection. The second branch given off was distributed to the external rectus muscle. From the artery, while above the optic nerve, two twigs were given to the superior rectus muscle, and some distance forwards a supra-orbital branch passed round the anterior margin of the orbit. Approaching the inner side of the orbit, the main artery gave a large branch that passed inwards in an arched manner over the nasal nerve, and the main vessel continued its course forwards with the infra-trochlear branch of the nasal. The ethmoidal arteries were not found on this side. The branch which has been referred to as arching over the nasal nerve is of special interest, because, in addition to muscular branches to the internal and inferior recti and ciliary arteries, it supplied the arteria centralis retinæ, and then became a fibrous cord, which was attached behind to the inner and lower margin of the optic foramen, where it became blended with the fibrous tissue around that opening.

On the *right* side, the ophthalmic artery resembled the left in origin, course, and distribution. It arose from the anterior branch of the middle meningeal, passed through the outer part of the sphenoidal fissure above the external rectus muscle, crossed over the optic nerve, and ended as the nasal artery, after giving off a branch which sent back a fibrous cord towards the internal carotid. Immediately after entering the orbit, it gave a long slender lachrymal branch to the gland, and from the opposite side of the artery, at the same spot, a supra-orbital branch.

Next in order came the branches to the external and superior recti muscles, and then the posterior ethmoidal artery. After these, a branch curved downwards at the inner side of the optic nerve, and supplied muscular offsets, ciliary arteries, and the arteria centralis retinæ, and ended, as on the left side, in a fibrous cord which could be traced backwards to the inner margin of the optic foramen, where it blended with the surrounding fibrous tissue close to the internal carotid. The main stem of the ophthalmic artery, after giving off this last-mentioned branch, divided into an anterior ethmoidal artery and a vessel which passed forwards with the infra-trochlear nerve.

When we consider the cause of this condition of the ophthalmic artery, I think there can be little difficulty in coming to the conclusion that there has been an obliteration of the original branch of the internal carotid, and that the present ophthalmic artery is an enlargement of what is described[1] as the orbital branch of the middle meningeal. Why this obliteration should have taken place it is difficult to explain, but I would point out that the fibrous cord which no doubt represents the original ophthalmic artery, was found on both sides at the inner part of the optic foramen, as though the artery had passed to the orbit at the inner instead of the outer side of the optic nerve.

[1] *Quain*, 10th edition, vol. ii., part 2, p. 404.

COMPLETE SEPARATION OF THE TWO HEADS OF THE BICEPS FLEXOR CRURIS MUSCLE. By

DAVID HEPBURN, M.D., F.R.S.E., *Senior Demonstrator of Anatomy, University of Edinburgh.*

IT will usually be found that varieties in the arrangement of the human muscular system are explainable by reference to the facts of comparative anatomy, and hence it is customary to regard the great majority of such abnormalities as regressions to a type of which the permanent form is found in some of the lower animals. The case which I am about to record affords a striking illustration of the foregoing statement. Moreover, its great rarity invests it with an additional interest. The complete independence of the two portions of the biceps flexor cruris muscle is referred to by Testut[1] in his elaborate treatise on muscular anomalies, and he quotes two cases recorded by Macalister.[2] In one of these, the ischial and femoral heads remained distinct until the immediate vicinity of the fibular insertion; in the other, the two parts were completely separated by the interposition of the external lateral ligament of the knee-joint.

Various modifications of the insertion of the biceps are also recorded. The most important of these consist of additional fasciculi detached from the ischial or long head, and inserted either into the tendo Achillis, or the fascia of the leg.

Wenzel Gruber[3] and W. Turner[4] have recorded such cases under the names of M. *Tensor fasciæ suralis*, and M. *Tensor fasciæ poplitealis.*

In the following notes it will be seen that the present case presents an instance of more complete independence between the two heads of the muscle than any of those above referred to.

The subject was a well-nourished female, of which the left

[1] Testut, *Anomalies Musculaires*, 1884.

[2] Macalister, *Transactions of Roy. Irish Acad.*, 1871.

[3] Gruber, (*a*) Bull. de l'Acad. des Sciences de St Petersbourg, t. x., 1878. (*b*) *Beobachtungen aus der menschl. und vergleich. Anatomie*, ii. Heft, p. 55.

[4] Turner, *Jour. Anat. and Phys.*, 1872, p. 442.

inferior extremity was being used by Sir Wm. Turner for the demonstration of its muscles to his class of Systematic Anatomy.

The long or ischial head of the biceps had the usual place of origin in common with the semi-tendinosus, but it was also closely blended with the origin of the semi-membranosus muscle. The belly of the muscle was of small size, being only six and a half inches in length, and little more than half an inch in width. The tendon which descended from this belly was at first rounded and slender, but after a course of three inches it became flattened and inseparably blended with the deep fascia of the outer part of the thigh, in which the expanded tendinous fibres might be traced as far as the deep fascia covering the outer head of the gastrocnemius muscle. This head of the biceps was therefore a *tensor fasciæ poplitealis.*

The short or femoral head was considerably larger than the ischial head. It took origin from the external intermuscular septum, and the upper third of the line leading from the external condyle of the femur to the linea aspera, from the whole length of the linea aspera between adductor magnus and vastus externus, extending as high as the gluteus maximus. Throughout its entire length this head was separate from the ischial portion. Its tendon was only an inch and a half in length, and was inserted into the outer side of the head of the fibula, some of its fibres being continuous with the fascia investing the peroneus longus, and it was not divided into two parts by the external lateral ligament of the knee-joint.

A disposition of parts approximating to that just described is known to occur normally in several of the anthropoid apes. In a recent number [1] of this *Journal* I have recorded the results of my dissection of this muscle in the Gibbon, Orang, Chimpanzee, and Gorilla. Among these, the Orang presented appearances most akin to those described above, but in the Chimpanzee and Gorilla the complete separation of the two heads from each other was not so definite as in the Orang.

Indeed, in them there was a partial fusion between the two heads, and the fused part was inserted into the head of the fibula, but a considerable portion of the long head was in-

[1] July 1892.

serted independently into the external tuberosity of the tibia, and the posterior fibres of the short head were inserted into the deep fascia covering the outer head of the gastrocnemius.

In the Gibbon, on the other hand, the fusion between the two heads and the insertion of the muscle as a whole, closely resembled the normal disposition of the corresponding parts in Man.

These observations on the insertion of the biceps in the Anthropoid Apes are corroborative of statements quoted by Testut from the writings of Duvernoy, Bischoff, and Champneys.

DELIMITATION OF THE REGIONS OF THE ABDOMEN.

By W. Wilberforce Smith, M.D., M.R.C.P. Lond.

Accustomed for many years to explore the abdomen of every patient with rare exceptions, I beg to offer a note from the medical consulting-room. The various existing chess-board methods of delimitation appear to have but slight relation to actual practice, and their obliteration would leave little to regret. Landmarks should be as nearly as possible under the exploring hands, the regions mapped out should not be over-numerous, and their names should have no equivocal meaning. Professor Anderson's proposed six divisions,[1] viz., upper and lower regions, subdivided into right, middle, and left, have for some time past been in use (so it occurs) in my consulting-room notes, and have afforded an altogether new sense of satisfaction and precision. His proposed horizontal line is always under the eye, viz., the level of the umbilicus, or, failing that, the level of the highest part of the crest of the ilium. The latter serves when the umbilicus is displaced on a pendulous abdomen. This displacement is of essential consequence. It occurs especially in women. And women furnish the majority of abdominal cases: witness the Registrar-General's tables, showing a large preponderance amongst adult females, of mortality from abdominal diseases.

For vertical lines, I would draw attention to the advantage of using the external borders of the recti abdominis. They are under the explorer's hands: the recti muscles are, in moderately muscular subjects, well marked to palpation, mostly furnish a considerable increase of dulness to percussion, and not infrequently can be made out by the eye. (Reference is here made to results of examining subjects in the erect posture.) This facility of definition could hardly apply to a line drawn vertically to the middle of Poupart's ligament. In routine medical practice such a vertical line would be mostly guessed at, particularly in women. It would have the further drawback of affording right and left lower provinces of disproportionate smallness. On the other hand, the convergence of the edges of the recti to the pubes, would afford divisions of more convenient size.

In relation to structures within the abdomen, it would probably be difficult to find divisions more convenient than those marked off by the horizontal umbilical line and the intersecting vertical lines suggested. Such divisions give the feeling in actual use, of working on a natural plan, as compared with more artificial, little-used methods.

[1] *Journal of Anatomy and Physiology*, July 1892.

Notices of New Books.

RECENT WORKS ON THE NERVOUS SYSTEM.

I. *Illustrations of the Nerve Tracts in the Mid and Hind Brain, and the Cranial Nerves arising therefrom.* By ALEXANDER BRUCE, M.A., M.D. Young J. Pentland, Edinburgh and London, 1892.

DURING the last few years Dr Bruce has from time to time communicated to the Royal Society of Edinburgh interesting and valuable papers on the anatomy of the central nervous apparatus. In the handsome volume now before us he has incorporated the results of some of the investigations treated of in these papers, and has supplied a quantity of additional matter. He has illustrated the volume with numerous drawings, which occupy twenty-seven large and beautifully executed plates, and with twenty-seven diagrammatic figures interspersed in the text. The work is therefore an important treatise on the parts of the Brain to which it refers, and will have to be read by those who are engaged in the study of the central nervous system.

The observations have been principally made on brains of the human fœtus between the fifth month and full time, hardened in Müller's fluid, and stained by the methods of Weigert or Pal. The drawings were made under the microscope with the aid of the camera-lucida, so as to ensure accuracy of outline and of the relations of the constituent parts shown in each section.

In his chapter on the tracts of the medulla, pons, and crura, the author begins by tracing the antero-lateral ground or basis bundle of the cord into the medulla oblongata. He states that in the medulla it occupies two distinct regions: the more anterior set of fibres lies internal to the roots of the hypoglossal nerve, and eventually forms the posterior longitudinal fasciculus; whilst the other set on the outer side of the hypoglossal nerve and on the dorsal aspect of the olive, terminates in part in the cells of the grey reticular formation, and partly ascends in the "lateral medullary tract," then enters the lateral fillet, which it accompanies to the testis. He confirms the fact that the ascending antero-lateral tract of Gowers occupies in the lower part of the medulla a position immediately on the ventral side of the direct cerebellar tract, and forms a part of the lateral medullary tract above referred to; but he traces it no higher than the lateral nuclei of the medulla. He suggests that it possibly may end there, though he thinks that the question of its termination is more likely to be settled by the study of its ascending degeneration than by that of its development—a view in which we fully concur. He considers that the direct cerebellar tract enters the

cerebellum in the core of the restiform body, and extends into the superior vermis of the opposite side. The pyramidal tracts, though figured and referred to in the explanation of the plates, are not specially described in the text.

As regards the posterior column, the postero-median tract (Goll) is traced to the post-pyramidal nucleus, from the cells of which apparently fibres pass to the fillet and the restiform body. The postero-external tract appears to terminate in the cuneate nucleus, out of which fibres also proceed to the fillet and the restiform body. The origin and termination of the lemniscus or mesial fillet has always been a puzzle difficult to unravel. Dr Bruce's observations support the view that this tract arises from the nerve cells of the post-pyramidal and cuneate nuclei, and that the fibres arising therefrom, and known as deep arciform fibres, decussate in the mesial plane of the medulla, immediately above the decussation of the pyramids; those from the cuneate nuclei become medullated long before those which arise from the post-pyramidal nuclei. Beyond the decussation, the fibres turn sharply upwards, and form the inter-olivary layer or stratum of longitudinal fillet fibres, situated between the raphé and inferior olive. The fillet, on entering the pons, lies between the raphé and the root of the sixth nerve; but above the level of the corpus trapezoideum some of its fibres terminate in, others arise from, the cells in the anterior part of the tegmentum of the pons. The main tract of the mesial fillet passes obliquely outwards and upwards, and gives off a few fibres to the testis through the lateral fillet, and others to the nates, whilst the rest is continued into the subthalamic region, and possibly onwards to the cortex cerebri. The lateral or lower fillet, which has usually been described as arising from the superior olive, is stated by Dr Bruce to receive in addition fibres through the median fillet from the posterior columns and from the lateral columns through the lateral medullary tract. This fillet passes to the testis.

The restiform body has two distinct origins, an external from the medulla and cord, and an internal from the pons. The external division proceeds from the direct cerebellar tract; from the cells of the post-pyramidal and cuneate nuclei of the same side; from the corresponding nuclei and the inferior olive of the opposite side by decussating fibres, and from the lateral (antero-lateral) nucleus, apparently of the same side. The internal division is derived from the external nucleus of the vestibular root of the auditory nerve, and from the superior olive, and the fibres belonging to it pass from below upwards to the roof nuclei of the cerebellum. The author has described a strand which appears to connect the inferior olive with Deiters' nucleus of the auditory nerve: observations on the corpus trapezoideum, superior olive, roof nuclei, nucleus dentatus, and superior cerebellar peduncle are also recorded. He regards the flocculus as associated in an important way with the division of the auditory nerve distributed to the vestibule and semi-circular canals; for the majority of its fibres enter into connection with the internal and external nuclei of the auditory nerve. It is also connected with the nucleus of the 6th nerve.

A chapter is devoted to the consideration of the origin of all the cranial nerves except the olfactory and optic. Our space does not admit of a detailed abstract; but we may state that the chapter contains a careful description, with corresponding illustrations, of their nuclei of origin and of their connections. We cannot close this notice without commending the admirable digest of the literature incorporated in each chapter; and we bring with pleasure this handsome volume not only under the notice of anatomists and physiologists, but of physicians, on account of its value in a clinical aspect.

II. *Contribution to the Surface Anatomy of the Cerebral Hemispheres.* By D. J. Cunningham, M.D., *with a Chapter upon Cranio-Cerebral Topography*, by Victor Horsley, M.B. Cunningham Memoirs, No. VII. Published by the Royal Irish Academy, Dublin, 1892.

THE preliminary contributions to the surface anatomy of the cerebrum, which Professor Cunningham has from time to time made to this *Journal*, have paved the way for the elaborate treatise now before us. The author in his introductory chapter states that his original intention was to study each fissure and gyrus in the hemisphere through every stage of its development and growth; but as he proceeded in his work he found that from the magnitude of the task it would be necessary to restrict himself to the more important fissures and gyri. The questions which he has more especially sought to determine are—1st, the more usual mode of development of the fissures which have been investigated, the period of life when they become fully formed, and the light thrown by the process of fissure formation on the growth of particular areas of cerebral cortex; 2nd, do the fissures change their position after their original appearance, and is the change in their relations to the cranial sutures at different periods of growth due (*a*) to an increase or decrease of certain areas of cerebral surface; (*b*) to a want of harmony in the growth-rate of the different cranial bones; (*c*) to both these influences acting together?

In pursuing his investigations Dr Cunningham has enjoyed the advantage of having a large number of brains at his disposal, both from the human fœtus at various stages of development, and from the adult, together with a smaller number of the brains of children of different ages, and along with these he has studied the brains of the Orang, Chimpanzee, and several species of tailed monkeys.

The "complete" fissures—totalfalten of His—are investigated with a thoroughness which they had not received from any other anatomist, and his views regarding them are summarised in a series of propositions. Special chapters are then devoted to the study of the fissure of Sylvius and the island of Reil, the fissure of Rolando, the intraparietal fissure of Turner, and the precentral and other sulci on the external surface of the frontal lobe. The several areas of the

cerebral cortex immediately associated with these fissures, as well as the fissures themselves, are described with a fulness of detail, both in their development and in their arrangement in the adult brain, such as could only have been attained through the abundance of material which the author has had at his command. The most important facts and observations are illustrated in the eight large quarto plates at the end of the memoir, and in numerous figures interposed in the text. In Plates I.–VI. the stages of development of the fissures and convolutions are represented in a large number of figures, and those which are especially valuable are the drawings of the transitory fissures, and the earlier condition of the persistent fissures of the human cerebrum.

In papers published in volume viii. of this *Journal*, Nov. 1873 and May 1874, and in *Proc. Roy. Soc. Edinburgh*, Jan. 19, 1874, Professor Turner mapped out the surface of the cerebrum in its relations to the skull and scalp, and described his method of exposing the brain *in situ* by cutting out definite areas of bone, a method which he preferred to the plan previously pursued by M. Broca and Professor Bischoff, who localised the convolutions by introducing pegs into the brain through holes bored through the cranium. Professor Cunningham has pursued a somewhat similar method of investigation to that employed by Professor Turner, though he has combined with it the insertion of pegs into the brain through holes in the skull. In many instances, after the brains were hardened in spirit, moulds were taken and casts in plaster of Paris were obtained. A series of such casts is figured in Plates V.–VIII. The large amount of material illustrating the relations of the brain to the surface of the head, which Dr Cunningham had gathered together in the course of his investigation, he has with great liberality placed at the command of Mr Victor Horsley, by whom the chapter on cranio-cerebral topography has been written.

We cannot close this notice of Dr Cunningham's memoir without expressing a strong opinion of its value, and with the hope that he may find time to complete the study of the surface anatomy of the cerebral hemispheres in a manner as carefully and as accurately as the areas which are embraced in the present memoir.

III. *The Structure and Function of the Brain and Spinal Cord, being the Fullerian Lectures for* 1891. By Victor Horsley, B.S., F.R.S. London: Charles Griffin & Co., 1892.

The author has selected as the subject of the courses of lectures delivered by him as the Fullerian Professor at the Royal Institution, the anatomy and physiology of the brain and spinal cord. The present volume is limited to a discussion of the structure and functions of the spinal cord and the ganglia associated with it, whilst the consideration of the structure and functions of the brain, and the recent results of research in physiological psychology, are left over for publication in two succeeding volumes.

As the Fullerian lectures are delivered to a general audience, and not to one exclusively composed of anatomists and physiologists, the professor is required to employ as far as possible non-technical language, so as to popularise the subject, without, however, sacrificing scientific precision. This Mr Horsley has done, and his little book can be recommended as furnishing a well written account of recent researches and opinions regarding the structure and functions of the spinal cord. As the author has himself undertaken, along with Mr Gotch, an experimental enquiry into the physiology of this division of the central nervous system, he has naturally incorporated in his lectures the results of this research.

IV. *Untersuchungen über die Vergleichende Anatomie des Gehirns.* 1st, *Das Vorderhirn*, 1888; 2nd, *Das Zwischenhirn*, Heft I, 1892. By Dr Ludwig Edinger. Frankfurt am Main.

Dr Edinger, whose lectures on the Central Organs of the Nervous System we noticed in the *Journal* for July 1892, is engaged in a series of researches into the comparative anatomy of the brain. Two memoirs have now been published, the first of which contains his observations on the Fore-brain in fish, amphibia and reptiles, and the second comprises the study of the Thalamencephalon (*Zwischenhirn*) in Selachia and Amphibia. The memoirs are produced under the auspices of the Senckenberg Naturalist Society in Frankfurt, and are illustrated with clearly executed coloured plates.

V. *Das Central-nerven-system von Protopterus annectens.* By Dr Rudolph Burckhardt. Berlin: Friedländer & Sohn, 1892.

This memoir is an important contribution to the anatomy of the brain and spinal cord of the Dipnöi. It has been worked out under very favourable conditions, as the author had an ample supply of fresh material, and is illustrated with five plates. He regards the brain of *Protopterus* as a link between the Selachian and Amphibian brain.

BRAIN OF THE LATE GEORGE GROTE, by Professor JOHN MARSHALL. October 1892.

ERRATA.

Page 33,	line 24,	*for*	'growth'	*read*	'quantity'.
,, 33,	,, 28,	,,	'firmly'	,,	'finally'.
,, 48,	,, 26,	,,	'back'	,,	'bent'.
,, 55,	,, 26,	,,	'upper'	,,	'inner'.
,, 61,	,, 16,	,,	'$\frac{1448}{1000}$ths'	,,	'$\frac{1440}{000}$ths'.
,, 61,	,, 18,	,,	'1 to 2'	,,	'1 to 11'.
,, 64,	,, 2,	,,	'extreme'	,,	'external'.

Journal of Anatomy and Physiology.

ON THE RUDIMENTARY HIND-LIMB OF A GREAT FIN-WHALE (*Balænoptera musculus*) IN COMPARISON WITH THOSE OF THE HUMPBACK WHALE AND THE GREENLAND RIGHT-WHALE.

By JOHN STRUTHERS, M.D., LL.D. (PLATES XVII.–XX.)

I EMBRACED this favourable opportunity[1] of endeavouring to ascertain what interpretation can be given to the occurrence of a part apparently so rudimentary as a thigh-bone of about the size of a pigeon's egg in a great whale; whether any definite function can be assigned to it, or whether it must be interpreted as a vestige only. This inquiry could be conducted to a satisfactory conclusion only by a searching dissection of the parts in the neighbourhood as well as of the more immediate connections. A large mass, of the whole thickness of the abdominal wall, including all the pelvic parts, was cut out of the carcase and preserved so as to keep the tissues fit for dissection. Full-sized drawings were made as the dissection went on, and these are now reduced to $\frac{1}{8}$ in the figures, Plates XVII., XVIII., XIX., and XX. It will greatly facilitate the reading if these draw-

[1] *History of this Whale.* It was found stranded on the beach at Nairn on Dec. 18, 1884. By communications from my former pupil Dr Brodie Cruickshank, of Nairn, and my friend Mr Alex. Macfarlane of the Custom House there, I inferred that it was a Razorback (B. musculus). It was sold to Mr Davidson, oil-merchant, Aberdeen, for £6; the nett proceeds, after deducting expenses and salvage, accruing to the Crown being £1, 15s. 5d. It was towed round to Aberdeen on February 2. The landing was a difficult operation. The endeavour to drag it up the bank of the river on rollers, 20 horses yoked to the ropes, having failed, it was towed round to the sheer-poles at the dock, hoisted in mid-air with tackle fastened round the tail, placed on a series of large waggons, and dragged on them by two dozen of horses and a large number of men to the recreation grounds for exhibition. The carcase was sufficiently fresh to enable me to give a satisfactory demonstration of the characters of this species to my students. I purchased and macerated the bones for the University, and the skeleton was mounted in portions, but not yet as a whole, when I left Aberdeen. It was the bones of this *B. musculus* that I gave the measurements of, in comparison with those of the 40-feet-long *Megaptera longimana*, in my account of the latter, in *This Journal*, 1887–8–9.

ings, with the accompanying explanation, are first looked at. I am now able to give at the same time a comparison of the parts with the corresponding parts in the Humpback Fin-whale (*Megaptera longimana*) and in the Greenland Right-whale (*Balæna mysticetus*). As my accounts of the dissection of these whales have at different times all appeared in this *Journal*, and as the comparison implies frequent reference to them and to the accompanying drawings, the references may be given simply as (Megaptera, 1887–8–9) and (Mysticetus, 1881). The parts of the text relating to comparison with these other whales are placed within [ ] brackets. Reference will also be made to my account of the pelvic bone and femur, with figures, of a 64-feet long B. musculus in this *Journal* (vol. vi., 1871). The B. musculus now to be noticed, also a male, was 50 feet in length. A preliminary notice of this dissection was given at the meeting of the British Association in Aberdeen in September 1885, by which time all the dissections now to be described had been made.

Parts noticed, and Order.

	PAGE
I. PELVIC BONE AND FEMUR.	
Measurements,	293
(A) *Pelvic Bone*,	294
Acetabular Cartilage,	295
(B) *Femur*,	297
Ligaments of Femur,	297
Position of Femur,	299
II. MUSCLES AND OTHER SOFT PARTS.	
Formation of Cetacean Perineum and fibrous Pelvic Cavity,	299
(A) *Relation of Pelvic Bone to Genital Organs.*	301
Great Interpelvic Ligament,	301
Triangular Ligament,	301
Notes on Bladder and Penis,	302
1. Levator ani muscle,	303
Rectal Fossa of pelvis,	304
Post-pelvic Band,	304
2. Bulbo-cavernosus muscle,	305
3. Ischio-cavernosus muscle,	306
Comparison of these muscles,	307
4. Retractor penis muscle,	309
(B) *Muscles attached to the Pelvic Bone.*	309
Interpelvic Membrane,	309
Longitudinal muscular masses,	311
Great Intermuscular Septa,	312
1. Posterior muscular mass,	313
2. Anterior do. do.	314
Pre-pelvic Band,	315
Comparison of these muscles,	316
(C) *Muscles attached to the Femur.*	316
1. Posterior muscle,	317
2. Anterior do.	317
Tensor Fasciæ muscle,	317
3. Internal muscle to Femur,	319
4. Anterior fibrous bands,	319
Summary of connections of Femur and their adaptations,	320
III. ADAPTATIONS AND COMPARISON OF PELVIC BONE AND FEMUR.	321
(A) Adaptations of the Pelvic Bone,	321
(B) Comparison of the Pelvic Bone in Fin-whales and in Mysticetus,	323
1. In B. rostrata,	323
2. In B. borealis,	323
3 and 4. In B. musculus, mature and not mature,	325
5. In Megaptera,	326
6 and 7. In Mysticetus, mature and not mature,	327
(C) Comparison of the Femur in Fin-whales and in Mysticetus,	328
Concluding remarks,	329
Appendix.—External Characters and Measurements of this B. musculus,	330
Explanation of the Plates,	332

I. Pelvic Bone and Femur.

Measurements of the Pelvic Bone and Femur.

The following Table gives these measurements, in inches, in this 50-feet-long B. musculus, and, for comparison, in the 64-feet-long B. musculus. The breadths (transverse) and thicknesses (vertical) show the change of form of the anterior and posterior parts of the pelvic bone at different parts.[1]

A.—The 50-feet-long B. musculus. B.—The 64-feet-long B. musculus.	Length.		Breadth.		Thickness.	
	A.	B.	A.	B.	A.	B.
Pelvic bone, straight, including cartilages,	$10\frac{1}{8}$	23				
,, anterior portion, or beak, .	9	$13\frac{1}{2}$				
,, posterior portion, . .	$5\frac{1}{2}$	$10\frac{1}{2}$				
,, ossified part, . . .	$8\frac{1}{8}$	$20\frac{1}{4}$				
,, anterior cartilage, . .	$1\frac{1}{4}$					
,, posterior cartilage, . .	$\frac{3}{4}$					
,, at 1 inch from end of anterior portion, ...	...	...	$1\frac{1}{8}$	$\frac{1}{2}$	$1\frac{1}{2}$	$1\frac{3}{4}$
,, at middle of anterior portion,	...	...	$1\frac{3}{8}$	$\frac{7}{8}$	$\frac{7}{8}$	1
,, at 3 inches in front of promontory, . . .	...	...	$1\frac{1}{2}$	$1\frac{1}{2}$	$\frac{3}{8}$	$\frac{5}{8}$
,, at the promontory, . .	...	...	$4\frac{3}{8}$	4	$\frac{3}{8}$	$\frac{5}{8}$
,, at 2 inches behind promontory, ...	...	...	2	2	$\frac{1}{8}$	$\frac{1}{8}$
,, at 1 inch from end of posterior portion, ...	...	...	1	1	$\frac{3}{8}$	$1\frac{1}{4}$
Femur, ...	$1\frac{3}{8}$	2	$1\frac{1}{16}$	$1\frac{1}{4}$	$\frac{7}{8}$	$\frac{1}{8}$

[1] The measurements of the femur and pelvic bone in the 50-feet-long B. musculus include the periosteum, which is $\frac{1}{16}$ inch thick on the femur, and $\frac{1}{10}$ to $\frac{1}{8}$ inch on the pelvic bone. About $\frac{1}{8}$ inch has, therefore, to be deducted from the breadth and thickness of the femur of it, as given in the Table, for exact comparison with the femur of the 64-feet-long one. The pelvic bone and femur of the latter are cleaned and dried. The measurements of the anterior and posterior portions of the pelvic bone are taken from the middle of the outer border of the promontory to the tip of each. The length of the cartilages is taken from the end of the ossified part, ascertained by passing in needles, not from where the cartilage overlaps the rounded end of the bone, which may be as much as $\frac{1}{4}$ inch on the surfaces, and $\frac{3}{4}$ inch on the borders. There is slight a-symmetry on some of the measurements. The right *pelvic bone* is $\frac{1}{4}$ inch longer than the left, seen on its ossified part as well as on the total length. The left is $\frac{1}{4}$ inch broader than the right at the promontory. In the Table the mean is given for these measurements. The $\frac{7}{8}$ inch thickness of the *femur* given in the Table is that of the right, that of the left is $\frac{1}{16}$ inch less. I obtained the bones only of the left side of the 64-feet-long B. musculus.

(A) *The Pelvic Bone.*

The differences presented by the pelvic bone in these two specimens of B. musculus (figs. 8 and 9) are so striking that, on first sight, they might be taken as belonging to different species. But the differences are owing merely to prolonged ossification at the anterior and posterior ends. At the promontory, and for three inches before and two inches behind it, the central region of the bone, the dimensions correspond closely. Notwithstanding the seeming greater breadth at the promontory in the younger specimen, the breadth exceeds that in the older specimen by only $\frac{1}{8}$ inch, allowing $\frac{2}{8}$ inch for the periosteum still on the former. The enormous elongation in the older specimen, giving a length more than twice that in the other ($10\frac{1}{8}$, 23) is more than one would expect in the growth of an individual from 50 to 64 feet, being an increase of between a fourth and a third on the length.

In the older specimen, the *anterior portion* or beak of the bone shows great difference in form on its anterior half, becoming much flattened laterally, in contrast with the vertical flattening of the central region of the bone. The measurements of the anterior portion of the bone show that, at its middle, the thickness has already begun to exceed the breadth, and that, near the end, the thickness is thrice as great as the breadth, so that the terms *thickness* and *breadth* might here be reversed. What is the inner border opposite the promontory runs forward as the superior and inferior borders of the anterior portion, and the outer border at the promontory becomes nearly lost on the anterior third of the anterior portion of the bone. In the younger specimen, the breadth at the middle is still much greater than the thickness, and, near the end, the thickness is only about a third greater than the breadth. The outer border does not fall away so soon as in the older specimen, so that in the younger one the beak maintains, throughout its yet ossified part, a prismatic form, more marked on the left bone than on the right. But the increase of the flat internal surface forwards is well marked. Thus, the part corresponding to the laterally much-flattened anterior half of the beak in the full-grown specimen is not yet developed in the younger one.

On the *posterior portion* of the bone, in the older specimen,

the thickness near the end has come to exceed the breadth by $\frac{1}{4}$ inch, but in the younger specimen the thickness at that part is less than the breadth by $\frac{1}{4}$ inch. In the latter specimen, the thickness increases a little (to $\frac{7}{8}$ inch) close to the end, on the cartilage, with a flattened surface on the inner aspect. In the more mature specimen, this flattened surface begins about six inches from the posterior end, bounded by the bifurcation backwards of the inner border of the central region of the bone, and the outer border of the central region becomes much rounded off on the posterior third of the posterior portion of the bone. Thus its thick posterior half, which gives this portion of the bone its robust character in the full-grown specimen, is not yet developed in the younger one. The flattened inner surface attaches the great interpelvic ligament on which the crus penis is set. Both of these specimens are male.

Acetabular Cartilage—(Figs. 4, 5 and 8, *a c, c*).—It is very interesting to find this cartilage present in B. musculus, representing the socket of a hip joint, although the vestigial femur does not rest on it. In *mysticetus*, in which I first met with it, the neck or head of the more developed femur rests on it, with a synovial cavity between, forming a true hip joint. Concealed by the periosteum here, as in *mysticetus*, it might readily be overlooked, or it might carelessly be taken for a growing cartilage of the promontory. A little observation, however, shows that it is not the latter, but that it corresponds very closely to the acetabular cartilage constant in my specimens of *mysticetus* (this *Journal*, 1881, p. 168, 17 and 18, and seen in fig. 11, *a c, c*, of this paper). On comparing it with one of these, still preserved moist, the correspondence is manifest. In this B. musculus the main part of the cartilage lies behind the promontory, on the under aspect of the bone, forming an ovoid elevation, like a broad almond, 1 to $1\frac{1}{4}$ inch in length, $\frac{5}{8}$ inch in breadth, about $\frac{1}{8}$ inch in thickness at the middle, less towards the edges, which are well marked. The outer edge is $\frac{1}{8}$ inch from the border of the bone, the bone here beginning to be excavated for the cartilage. On raising the cartilage from the bone, to which it adhered very intimately, the bone is seen to present a well-marked though shallow fossa corresponding to the above-mentioned dimensions of the main part of the carti-

lage. The periosteum over the cartilage is very thin, and so adherent that it was dissected off with difficulty, contrasting in both of these respects with the periosteum near it and on the rest of the pelvic bone.

From this oval and convex main part, the cartilage sends a thin prolongation forwards and outwards on the superficial surface of the promontory, as far as the border, and then ceases, except at the hinder slope of the promontory, where, as in *mysticetus*, a thin tongue, about ½ inch in length, goes round the border for about ⅛ inch on the upper aspect of the bone. The cartilage is thin where it reaches forwards on the promontory and very thin towards the border. From the position of the main part, and as the cartilage does not cap the promontory like a growing cartilage, this cartilage cannot be regarded as a growing cartilage of that projection. The inner edge of its prolongation on the promontory retains some thickness, and here it gives attachment to the external ligament of the femur. Were the inner edge of the cartilage, and of its forward prolongation, to become ossified, a bony ridge would be formed like the anterior part of the ridge seen on the bone in the 64-feet-long B. musculus to which the now dried ligament of the femur is attached (1871, fig. 3), and, external to that ridge, rough depressions are seen on the now cleaned bone, suggesting that this cartilage had been present. In this less mature B. musculus the locality of the cartilage is marked on the bone by the oval fossa for the main part, and by a flat area for the anterior part, the latter bounded internally by a sharp edge corresponding to where the external ligament of the femur is attached. The area occupied by the cartilage in my specimens of *mysticetus* is seen on the macerated bones.

[The presence of the acetabular cartilage in B. musculus is the more remarkable, as I could find no vestige of it in my 40-feet-long *megaptera* (this *Journal*, vol. xxii., 1888, p. 273 and p. 279), in which the femur is larger and longer than in B. musculus, and in which the ossification of the pelvic bone is not so advanced as it is in this B. musculus. In the *megaptera*, rather internal to the corresponding part of the pelvic bone, there is an elongated elevation of the bone to which the external ligament of the femur was attached, and against which the cartilaginous femur may have loosely rested, but there is no cartilage whatever there or on the promontory.]

(B) *The Femur*—(Fig. 8, F, and other figures).

The femur is of a generally oval form: the diameters, stated generally, are, without the peri-chondrium, length $1\frac{1}{2}$ inch, breadth 1 inch, thickness $\frac{3}{4}$ inch. The surfaces are superior (deep) and inferior (superficial); the borders, anterior and posterior; the ends, external (towards the promontory) and internal. The oval outline is not quite uniform, the broad posterior border showing two elevations, separated by a groove running obliquely outwards and upwards between them. The internal elevation attaches the tendon of the posterior muscle; the external elevation, placed well towards the deep surface, attaches the posterior ligament of the femur. Where this great ligament is attached in *mysticetus*, this prominence is generally very marked on the bone. The outer end attaches the external ligament of the femur; a fibrous tuft remains attached to the inner end, and to this tuft were attached some of the muscular fibres to be noted below (p. 318).

On section, the femur is seen to be entirely cartilaginous, closely enveloped by a $\frac{1}{16}$ inch-thick peri-chondrium. The vascular channels, seen by the naked eye to permeate abundantly the much larger entirely cartilaginous femur of *megaptera* and the tibia of *mysticetus*, are seen in the femur of this B. musculus with the aid of a lens. In the 64-feet-long B. musculus, the femur, 2 inches in length, is ossified in its outer or posterior three-fourths, but that ossification is not necessarily a matter of age is seen from the fact that in the 67-feet-long B. musculus, also a male, in which the presence of a femur was discovered by Sir W. H. Flower (*Pro. Zoo. Soc.*, 1865), the femur was in the condition of a cartilage, $1\frac{1}{4}$ inch in length by $\frac{3}{4}$ inch in breadth. Variation is to be expected in parts so rudimentary.

Ligaments of the Femur.—The ligaments connecting the femur to the pelvic bone are an external, a posterior, and an interosseous. (1) *External ligament* (figs. 4, 5 and 8, *e*, *l*). Length, on superficial surface, $\frac{3}{4}$ to 1 inch; breadth $\frac{1}{2}$ inch; thickness $\frac{1}{4}$ inch. Attachments, externally, at about $\frac{3}{4}$ inch from outer edge of promontory, being at the ridge bounding internally the forward prolongation of the acetabular cartilage; internally, to the outer end of the femur, running further on the posterior than on the anterior border. Direction, inwards and a

little forwards. It will check movement in that direction, and it is a strong ligament for so small a femur. (2) *Posterior ligament* (figs. 4, 5, and 8, *p*, *l*). Length, on superficial surface, 2¼ to 2½ inches; breadth, at the narrowest part, ½ inch, expanding a little towards the femur and backwards on the pelvic bone. Thickness about half that of the external ligament. Its attachment at the femur is to the external elevation, above noticed, on the posterior border towards the deep surface. There is no cartilage or special roughness on the pelvic bone where this ligament is attached to it, nor is the ridge that bounds internally the fossa for the acetabular cartilage continued to where this ligament is attached, or continued backwards beyond the fossa. The direction of the ligament is forwards and considerably outwards. It is a strong ligament, and will resist forward movement of the outer part of the femur. (3) *Interosseous ligament.* This short ligament is concealed by the outer part of the femur and by the anterior part of the posterior ligament, and is therefore not shown in the figures. Length under ½ inch, breadth ½ inch. Its direction towards the femur is a little forwards, and it will mostly check forward movement. It would also check much backward movement of the outer end of the femur, and much lifting of the femur off the pelvic bone, but the latter does not seem to be a possible movement by any muscular structure present. These three ligaments are all attached to the outer part of the femur, and might be taken for a kind of capsule to the head of the bone, but they are distinct ligaments. They offer strong resistance to inward and forward muscular traction on the femur, but not to backward muscular traction on the inner part of the femur.

In the 64-feet-long B. musculus, the external and posterior ligaments (fig. 9, *e*, *p*, *l*) form one large triangular ligament, bifurcated posteriorly, a thinner portion filling the interval. It is attached to the outer or posterior end of the femur, and, at the pelvic bone, to a 4-inch-long ridge, corresponding to the inner boundary of the area for the acetabular cartilage in this less mature B. musculus, with a prolongation of that boundary backwards. The more transverse position of the femur in this 50-feet-long B. musculus may account for the ligament being differentiated in it into two distinct ligaments.

[In *mysticetus* the posterior ligament (fig. 11, *g*, *p*, *l*) is quite separate and very large, and is attached to a usually well-marked prominence on the femur, some way internal to the head and neck; and there are anterior and posterior ligaments of the head, and two interrosseous ligaments of the body of the femur. In *megaptera*, although the femur is placed antero-posteriorly, the external and posterior ligaments are distinct (fig. 10). The posterior was large and bifurcated backwards, and the internal limb contained a true muscle. An appearance to the naked eye of muscular streaks in the posterior ligament in the 50-feet-long B. musculus was deceptive, as shown on examination under the microscope.]

Position and Mobility of the Femur.—The femur, with its long axis directed inwards and a little forwards, has the following position. Outer end, 1½ to 1¾ inch from the extreme outer edge of the promontory of the pelvic bone, and ¾ inch distant from the nearest part of the acetabular cartilage. From a third to a half of the breadth (more on the left than on the right side) projects in front of the anterior border of the pelvic bone. Most of its very convex deep surface thus rests on the pelvic bone; but there is no cartilage on the pelvic bone here, only the usual periosteum; nor any special excavation, but only the general shallow concavity of this region of the bone. There is no synovial membrane, only a little of the usual cetacean fat and areolar tissue, and part of a muscle mixed with fibrous tissue (p. 319). The femur slips about very loosely, except in so far as restrained by the ligaments above noticed, and as retained in position by the muscular and fibrous structures to be noticed below.

II. The Muscles and other Soft Parts.

Formation of the Cetacean Perineum and fibrous Pelvic Cavity.—Preliminary definition in comparison with the quadrupedal pelvis will simplify, and the accustomed nomenclature of human anatomy is quite applicable. Fgures 1, 2, and 3 may be referred to generally. Imagine, in the human body, only an elongated ischium to be present, the rest of the bony true pelvis represented by fibrous membrane; the pubic arch and symphysis to be represented by a fibrous band, and the perineum to be bounded behind by a fibrous band in the position of the lower edge of the great sacro-sciatic ligament. There is thus, in the cetacean, a large oval or elliptical gap in the abdominal wall

representing the pelvic cavity and perineum. The parts presented on dissection from the surface are those of the perineum, having a narrow bar of bone, the pelvic bone, along part of each side. Although there is no bony pelvis above the perineum, there is a soft-walled pelvic cavity, formed at the sides by the longitudinal muscular masses, and before and behind by the convergence and meeting of these masses; all smoothly lined by a very strong aponeurosis, the pelvic fascia, from the brim above to the outlet below. At the outlet, this fascia is attached to the upper edge of the pelvic bone and pre-pelvic band; and to the lower edge of the bone, and to the pre-pelvic band, is attached the deeper layer of the strong interpelvic membrane, thus closing the pelvis and giving support below. The wall slopes upwards and inwards, giving the cavity the form of a funnel reversed, so that while, in this B. musculus, the width of the outlet at the anterior end of the pelvic bones is 10 inches, that of the inlet above that point is only 6 inches. The pelvic cavity has a height of at least 5 inches above the pelvic bone as the parts lie on the dissecting-table, probably more when in the natural position. The upper opening, or inlet, of this soft-walled pelvis receives the bladder and rectum. The outlet, or perineum, below, a large ovoid area, is divided into anterior and posterior parts by the great interpelvic ligament, each about 14 inches in length. The anterior division, broadly heart-shaped, is bounded at the sides by the pelvic bones, and in front of them by the band connecting the anterior ends of the pelvic bones, the pre-pelvic band, uniting with its fellow in an anterior symphysis. The posterior division is bounded laterally by a post-pelvic band, uniting with its fellow in a posterior symphysis. The posterior or rectal division, described as the rectal fossa, transmits the rectum, emerging from the posterior part of the pelvic cavity, into which it is bound below by the great funnel-shaped levator ani muscle. The anterior, or genito-urinary, division contains in the centre the parts of the penis and urethra with their muscles, and on each side of these is a wide space (2 to 3 inches wide) which is packed with a mass of loose areolar tissue and fat, allowing of distention of the central parts, or of compression of them by the coming inwards of the movable lateral boundary. The pelvic bone lies at and bounds the two posterior

thirds of the genito-urinary division. The distance between the right and left pelvic bone is, at their posterior end 16 inches, at their anterior end 10 inches.

The muscles and other soft parts in relation with the pelvic bone and femur may be considered under three heads. (a) The relation of the pelvic bone to the genital organs. (b) The muscles attached to the pelvic bone. (c) The muscles attached to the femur. Previous reference to the figures and their explanation will greatly facilitate the reader in following the account of the muscles and their connections.

(A) *Relation of the Pelvic Bone to the Genital Organs.*

Great Interpelvic Ligament.—This great ligament is seen in figure 3 (*i*, *l*), passing across between the posterior ends of the pelvic bones, supporting the crura penis and attaching muscles. Its attachment to the bone is at the end and to ¾ inch of the inner surface (the as yet cartilaginous part), here flattened, and from this it is continued forwards along the inner side of the bone as a thick fascia. The length of the ligament between the bone and the crus-penis is 3½ inches. This part of the ligament is divided in most of its length by an elliptical interval into an anterior and posterior part. The posterior part is about one third of the bulk of the anterior, and gives attachment along its whole length to the inner part of the posterior muscular mass. The interval between the two parts appeared as if it had transmitted blood-vessels. The anterior part is the interpelvic ligament proper. It is flattened, like a leather strap, ¾ inch by ⅛ inch, set edgeways on the pelvic bone. Along its inner half it gives attachment to the ischio-cavernosus muscle. The two portions, united at the crus penis, are 1¼ inch in breadth. The anterior and greater part of this fibrous mass joins the fibrous tissue of the crus, spreading longitudinally over chiefly the inferior surface of the crus, and contributing to the great thickness of the fibrous wall of the crus here. The more posterior portion of the ligament partly joins the end of the crus, and partly passes behind and on the under surface of the crus to join the triangular ligament, thus joining the fibres from the opposite pelvic bone.

The *Triangular Ligament*, or intercrural ligament (fig. 3, *t*, *l*),

occupies the space between and connects the crura penis, is pierced anteriorly by the urethra, and is in part concealed on the under surface by the bulb of the corpus spongiosum. It is a strong structure, behind about $\frac{1}{3}$ inch thick, thinner towards the hinder edge. For its posterior inch it is composed of uninterrupted transverse bundles. In front of this it sends a covering of transverse bundles over the bulb, the fibrous covering of which is $\frac{1}{2}$ inch thick, that of the corpus spongiosum, in front of the bulb, being only $\frac{1}{8}$ inch thick. At the sides the triangular ligament becomes continuous with the longitudinally directed fibrous bundles of the crura, chiefly with the thick fibrous plate on their under surface. The strain against separation of the pelvic bones must be borne chiefly by this thick fibrous plate on the crus, through its connection with the interpelvic ligament externally and with the triangular ligament internally, as only a comparatively small proportion of the bundles of these two ligaments pass across behind and under the crura, none at all on the dorsal surface of the crura. On its upper surface, the triangular ligament attaches the bladder around where the urethra perforates the ligament.[1]

[1] *Note on the Bladder.*—What I saw of the bladder may be noted here. The attachment to the triangular ligament is 5 inches in length, an inch of it by a median fibrous band, by $1\frac{1}{2}$ inch in breadth. The muscular coat of the bladder was thicker towards the neck, but nothing resembling a prostate gland was seen. The muscular coat, fully $\frac{1}{2}$ inch thick, was composed of very red bundles, but examination with the microscope showed no striped fibres. The mucous and sub-mucous coats were pale, in contrast with the red muscular coat, about $\frac{1}{8}$ inch thick, and very distensible and elastic. Length of bladder, 12 inches; breadth when empty and flattened, 3 to 4 inches. It could be distended at the middle to form a ring $3\frac{1}{2}$ inches in diameter, not more. [In my account of Mysticetus reference is made to "the neck of the bladder, with its thick red muscular walls, seen under the microscope to be composed of *striped* fibre" (p. 305, 1881). I am unable to account for this discrepancy if there is an error. On referring to my notes of the dissection of Mysticetus I see that, when the observation under the microscope was made, I had still remaining a portion of the bladder $2\frac{1}{2}$ inches in length by $3\frac{1}{2}$ inches in breadth, attached round the perforation in the triangular ligament, noted as with "very thick walls, dark red muscular fibres, fully striped under the microscope. Central cavity lined by mucous membrane, admits of being much dilated. No trace of seminal ducts or of anything like a prostate." It is noted that large red muscular bundles join the bladder to the interpelvic ligament, around and near the aperture, and pass on the surfaces as longitudinal bundles and also in part as circular bundles. The muscular fibres of this part of the bladder of Mysticetus were undoubtedly of the striped kind. I do not think

[The interpelvic ligament in B. musculus is not so large a structure as in Mysticetus or in Megaptera. In the 40-feet-long *megaptera* the ligament was 1½ to 2 inches in breadth, antero-posteriorly, and about ½ inch thick, and met the crus penis at 2½ inches from the pelvic bone. This greater size of the ligament in Megaptera is in adaptation to the greater breadth of the penis and its crura, and of the ischio-cavernosus muscle (*loc. cit.*, fig. 15). The ligament is still broader and thicker in *mysticetus*, meets the crus penis much sooner, and sends strong bundles across the dorsal surface of the crus to join those from the opposite pelvic bone on that aspect of the triangular ligament. The crus penis and the muscle are much larger in Mysticetus (*loc. cit.*, figs. 11, 12, 13, and 14).[1]]

(1) *Levator ani muscle.*—This great muscle, covering the under surface and part of the sides of the rectum, seen in full view in fig. 1 (*l*, *a*), presents a funnel shape, tapering backwards. Length, fully 12 inches; breadth, 10 to 11 inches towards the fore part, 6 to 7 inches at the back part; thickness, as seen on section, 2 inches, diminishing to 1 inch behind, and thinning a little also towards the anterior border. It arises, anteriorly, for two to three inches from the general superficial aponeurosis internal to the position of the pelvic bone; externally, from the great interpelvic ligament; and chiefly, along the side, from the post-pelvic band. The direction of the great bundles presented by the muscle may be noted as contrasting, except at the fore part, with their direction in Megaptera.

it likely that the fibres I placed under the microscope in B. musculus were taken from the superficial bundles prolonged from the retractor penis muscle. As noted below (p. 309) these are pale, and very unlike the deep red bundles of the muscular coat of the bladder.]

[1] Some differences of the crus penis in B. musculus, as compared with Mysticetus, may be noted here. In this 50-feet-long B. musculus, the erectile tissue goes back close to the posterior end of the crus. There it is about the size of the little finger; forwards, at the middle of the crus, it is about the size of the transverse section of a hen's egg. The fibrous wall on the free under surface of the crus is ⅛ inch thick. In the 35-feet-long *mysticetus* (*loc. cit.*, p. 302, figs. 11 and 12) the erectile medulla ceases 2 inches from the posterior end of the crus, being on a level with where the anterior part of the interpelvic ligament joins the crus. There, beginning abruptly, it is about the size of the fore-finger, much larger in front of this. That is in the collapsed condition. The fibrous cortex of the crus is nearly 1 inch thick on the under surface. The crura are thus much larger and more firmly supported in Mysticetus than in B. musculus, and are, in addition, in Mysticetus, completely covered and supported by the posterior compressor muscle. I had noted of *megaptera* that the penis is much broader than in this B. musculus, and of the crus, that at its conical hinder end the fibrous wall was ⅓ to ½ inch thick, with erectile tissue internally.

Curving inwards to the middle line, at the anterior 2 to 3 inches, the direction is backwards; then a few pass directly inwards; then, along the great part of the muscle the direction changes to forwards, increasingly so as we go back, and curving with the concavity backwards. There is no distinct median raphé, the bundles merely interlacing and decussating irregularly at the middle line below.

At the anus, for about 2 inches, the arrangement is modified so as to form a sphincter muscle, the bundles arising on each side from the post-pelvic band passing above as well as below the bowel. This part of the muscle is about 1 inch in thickness, increasing in thickness backwards. It is not certain that I had the parts quite to the anus. This strong red sphincter ani, or recti, contrasts with the pale ½ inch thick muscular coat of the bowel in front of it, composed chiefly of circular fibres, but covered by an external longitudinal stratum.

When the rectum is removed a long deep fossa is exposed, *rectal fossa*, shown in fig. 2 (*r*, *f*). This is the rectal portion of the pelvic cavity, directed obliquely backwards and downwards, about 13 inches in length. The sides and roof are formed by the posterior muscular mass of each side, lined by a strong fascia. The fibres of this fascia pass from the post-pelvic band to meet in the middle line of the roof, those along the posterior 8 inches with a definite direction inwards and backwards. In this fossa the rectum will be compressed by the levator ani muscle below, and at the sides and above by the contraction of the posterior muscular mass. The rectum is surrounded by loose areolar tissue and fat.

The *post-pelvic band*, above referred to, is shown on the surface in fig. 1 along the side of the levator ani muscle, and in fig. 2 (*po*, *p*) as the boundary of this part of the pelvic outlet. In front it is connected to the hinder end of the pelvic bone and with the great interpelvic ligament. At the latter connection it is continuous with the fibrous ridge on the crus penis, there and for several inches backwards bounding and attaching the bulbo-cavernosus muscle. Behind, it joins its fellow in a posterior symphysis, where the right and left posterior muscular masses meet mesially, thus bounding the outlet of the pelvis. Deeply, it is continuous with the fibrous wall of this part of the

pelvic cavity. Superficially, it is connected inwards with the fascia on the surface of the levator ani, outwards with the thick fascia on the surface of the posterior muscular mass. The post-pelvic band is a strong structure, and is important as a boundary and as giving origin to several muscles.

[In *megaptera*, all but a few of the anterior bundles of the levator ani muscle are directed obliquely backwards to the middle line below, where they decussate irregularly. None of it appeared to go on the upper surface of the rectum till near the anus, and there the bundles decussate obliquely and pass round. The reason for the backward direction of the bundles of the great body of the muscle appears to be, that the bulk of the muscle arises from the interpelvic ligament and end of the pelvic bone. I have no note of the presence of such a structure as the post-pelvic band, subsequently found in B. musculus, giving continued origin backwards to the levator ani; but the posterior muscular mass is noted as meeting its fellow in a median septum, just behind the anus. In the figure given of megaptera (*loc. cit.*, fig. 15), only the anterior part of the muscle is shown. In *mysticetus* (*loc. cit.*, fig. 13) also only the anterior part of the muscle is shown. The back part of the muscle had been mutilated. The anterior part is seen to arise further forwards than in the two finners, carried forwards by the horse-shoe septum.]

(2) *Bulbo-cavernosus muscle.*—This muscle is shown in full view in fig. 2 (*b*, *c*). It measures, transversely, 7 inches in front, increasing to 10 inches behind; antero-posteriorly, 3 inches at the middle, increasing to 6 inches externally; in thickness at the anterior border, ¾ inch. It is composed of large red bundles, interrupted at the middle line by a fibrous septum, dividing the muscle in its whole length and thickness, and showing itself on the surface as a raphé with tendinous bundles on each side. For comparison with its greatly developed homologue in Mysticetus, the median septum may be described as the origin of the muscle. It arises also, more deeply, from the under surface of the great interpelvic ligament. The external attachments of the muscle are, posteriorly, to the post-pelvic band above described; anteriorly, including the thicker part of the muscle, to the crus penis, on which it is separated by a firm fibrous ridge from the attachment of the ischio-cavernosus muscle to the crus. The direction of the bundles is, at the anterior part, a little backwards, towards the back part very much backwards. The deep surface is, anteriorly, entirely adherent to the crura penis and posterior part of the

bulb; posteriorly, unattached, in relation with the now expanded retractor penis muscles. The superficial surface is concealed in more than its posterior half (fig. 1), by the levator ani muscle, and, at the middle, by the rope-like retractor penis muscles, now becoming flattened before they turn round the posterior border of the bulbo-cavernosus. Where this muscle and the levator ani are attached to the post-pelvic band the bundles might seem to be continuous, as if forming a circular muscle, but they are not really continuous. Fig. 1 shows the elliptical space between these two muscles through which the two rope-like retractors pass. The actions of the bulbo-cavernosus muscle must be to draw the crura penis and, through the interpelvic ligament, the pelvic bones towards each other; also to compress the back part of the bulb and of the crura, and to give general support to the penis.

(3) *Ischio-cavernosus muscle.*—This large muscle is shown, on the under aspect, in full on both sides in fig. 2 (*i c*), on the right side in fig. 3, and in part on both sides in fig. 1. Length, at the outer side, 11 inches; greatest breadth, on the surface, 3 inches; breadth on section, 2 to 2½ inches. Though the name is homologically correct, the muscle has no direct connection with the pelvic bone in B. musculus. The more external part arises from more than the inner half of the great interpelvic ligament by a series of thin tendinous laminæ, the more internal and deeper bundles from the outer part of the crus penis on both aspects. The bundles pass forwards and inwards to be inserted into the corpus cavernosum, and in part into the crus. The cortex of the part of the crus covered by and attaching the muscle is soft and compressible, and only ⅛ inch thick, in contrast with the part of the crus not covered by the muscle. This latter part of the cortex, between the inner edge of the muscle and the bulb, forms a hard fibrous plate ⅝ inch in thickness, marked off from the soft part by a strong ridge. This ridge, overhanging and giving origin to the ischio-cavernosus, rises for ¾ inch, is at the base ½ inch thick, and tapers to a blunt margin. This fibrous ridge (shown on the left crus in fig. 3) will be seen to correspond to the horse-shoe septum in Mysticetus. The ischio-cavernosus muscle, thus, in B. musculus, is far from extending inwards to meet its fellow of the opposite side on

either aspect. The interval on the under aspect is seen in fig. 2, bounded by the inwardly convex border of the muscle. On the dorsal aspect, there is, along the posterior 7 inches, a wide triangular interval, bounded by the inwardly concave border of the muscle, and along the anterior 4 inches a narrow interval, 1¼ inch broad, bounded by a straight border of the muscle. At the back part of the triangular interval are seen, besides part of the crura, the neck of the bladder, and the triangular ligament between the crura. In regard to the action of this muscle, the deeper bundles, attached on the surface of the soft part of the crus and at their other end to the inter-pelvic ligament behind or to the corpus cavernosum in front, should at first have the effect of dilating the wall of the erectile medulla; but the swelling of the contracted muscle should rather have a compressing influence when the crus is distended. The general action of the muscle along with its fellow, and with the bulbo-cavernosus muscle, forming together a muscular triangle, should be to grasp and support the crura and corpora cavernosa during erection.

[*Comparison of the Bulbo-cavernosus and Ischio-cavernosus muscles in B. musculus, Megaptera, and Mysticetus.*—The interpretation of the vast muscles here in mysticetus, and of the fibrous structure I described as the "horse-shoe septum," is made clear by this subsequent dissection of B. musculus. The "great compressor muscle" in mysticetus, enveloping in one great muscular covering all the parts of the penis here (1881, figs. 13, 14, 15), with median raphé on both aspects, I had interpreted as comprehending a great ischio-cavernosus muscle, and also, in the part arising from the inferior median raphé, a bulbo-cavernosus muscle, while the homology of the "posterior compressor muscle," separated from the great compressor by the horse-shoe septum, was not evident. It is now evident that the posterior compressor of mysticetus (1881, fig. 13, *m*) is the bulbo-cavernosus muscle, much more developed forwards than in B. musculus, so as to cover the whole of the bulb and greater part of the crura. The posterior bundles have a nearly transverse direction, the succeeding bundles a direction more and more forwards, to be inserted into the crus and the horse-shoe septum. The great anterior compressor of mysticetus is the ischio-cavernosus, arising not only extensively from the pelvic bone, but inwards from the horse-shoe septum, and from the median raphé on the under aspect, the whole passing to be inserted into the dorsal median raphé and corpus cavernosum.

It becomes evident, too, that the horse-shoe septum, attaining a depth of 2 to 2½ inches, is but a greater development of the fibrous ridge on the side of the crura in B. musculus, the ridge being, in

mysticetus, carried across the bulb, or corpus spongiosum, to join its fellow of the opposite side, owing to the inward extension of the ischio-cavernosus muscle to the middle line. The fibrous ridge, or septum, on the crus in B. musculus may, moreover, be regarded as a continuation of the post-pelvic band, where they meet at the posterior end of the crus. These septa together form the lateral and anterior limits of the bulbo-cavernosus muscle in B. musculus, as the horse-shoe septum does in mysticetus. The horse-shoe septum begins within the posterior end of the pelvic bone, and along its posterior half attaches the anterior part of the levator ani muscle (1881, fig. 13, *i*), just as the anterior part of the post-pelvic band does in B. musculus. I had not the opportunity of dissecting the parts further back in mysticetus.

The correspondence of these two muscles (ischio-cavernosus and bulbo-cavernosus) in mysticetus and in B. musculus, however unlike they are at first sight, is therefore clear. The mass of these muscles, great as it is in B. musculus compared with the size of the crura and corpora cavernosa, is actually several times greater in the but half-grown mysticetus described and figured. The action of these two muscles in mysticetus, in compressing all the parts of the penis here, and in giving support to the root of the penis during erection, is evident.

In *megaptera* the ischio-cavernosus muscle, though with the same general arrangement, is much larger than in B. musculus, especially in breadth (1888, fig, 15, *f*), in accordance with the greater extent of the interpelvic ligament and greater breadth of the penis. The breadth was about twice that in B. musculus. The broad interval between the right and left muscle, on the under aspect, is seen in the figure. On the dorsal aspect, they approach within ½ inch of each other along the posterior 3 inches, then diverge forwards for the remaining 7 inches, leaving a white triangular interval, the base formed by the whole breadth of this aspect of the penis. This may be compared with the figure (14, *l*, 1881) given of the dorsal aspect of the muscle in mysticetus, in which the greater part of the muscle is seen to meet its fellow in a median raphé and septum, the anterior part separated from its fellow by a narrow interval. I estimated the total bulk of this muscle in megaptera as equal to twice that of an average human gluteus maximus muscle, but that falls far short of the bulk of the muscle in mysticetus. The great size of these muscles in the cetacea—in each of these whales the ischio-cavernosus muscle thicker than the penis—may be in adaptation to the crura penis being set upon the interpelvic ligament, instead of on the bone, and to the pelvic bone itself not being a fixed part of the skeleton.

I referred to the *bulbo-cavernosus* muscle in megaptera very shortly as the "transversus perinei" (1888, p. 275). The part of it shown in the figure (15, *d d*, 1888) is the posterior border, but the muscle, with the same general appearance as in B. musculus, faced somewhat differently. In my notes it is described as having one surface applied against the bulb and crura, the other towards the rectum. I

infer from my notes that the muscle was turned in part in behind the interpelvic ligament, so that the small part shown in the figure just referred to was the inferior as well as the posterior border. The muscle in megaptera was, as far as I can judge, about the same size as in B. musculus, not larger. It is noted that the bundles passed across without any median raphé, but the raphé may have been overlooked, from the condition of the parts here, which were not so fresh as in my subsequent dissection of B. musculus.

The separate bundle, about the bulk of the little finger, noted in the dissection of mysticetus (1881, p. 307) as passing across just behind the bulbo-cavernosus, between the ends of the crura penis, without median interruption, was not seen in megaptera or in B. musculus. But the crura in mysticetus form free conical projections behind the interpelvic ligament (figs. 11 and 12, 1881), which may account for the development of this separate bundle.]

(4) *Retractor penis muscle.*—This muscle, shown in this B. musculus in fig. 1 (*r r*), in Megaptera (1888, fig. 15 *e e*), and in Mysticetus (1881, fig. 13 *k k*), has the same arrangement in all these whales. Passing back, as a soft rope-like structure, close to its fellow, on the under surface of the penis and its muscles, it sinks in between the levator ani and the bulbo-cavernosus muscles, and breaks up into its bundles of origin. In this B. musculus some of the bundles passed backwards on the rectum; most of them turned upwards, some to be attached to the posterior edge of the interpelvic ligament, and some were continued forwards on the bladder, for 3 or 4 inches on its upper surface, as a pale continuous layer, contrasting with the red filres of the muscular coat of the bladder. It is composed of pale unstriped muscular fibre mixed with areolar tissue, enclosed in a fibrous sheath. It was dissected forwards in Megaptera, and seen to begin behind the middle of the penis to be inserted gradually along its outer edge, the inner part passing much further forwards.

(B) *Muscles attached to the Pelvic Bone.*

The Superficial Interpelvic and Interfemoral Membrane (Perineal Fascia).—This is a thickened part of the general aponeurosis of the region. It is figured with Megaptera (1888, fig. 15, *k k*), but a more extended view was obtained in this B. musculus, fig. 1, in which it was 3 feet in length from the anus forwards. The general aponeurosis is seen posteriorly to be attached, at the side of the levator ani muscle, to the post-pelvic

band. In front of this it passes across between the pelvic bones, covering them and extending outwards beyond them over the anterior muscular mass. The position of the pelvic bones and femur is shown by the dotted lines in the figure. Here, between the anterior portion of the bones and for some way in front of them, the aponeurosis is greatly thickened and forms the interpelvic membrane proper. The thickness is, over the posterior muscular mass, about $\frac{1}{12}$ inch; external to the pelvic bone, about $\frac{1}{8}$ inch; at the special interpelvic part, $\frac{1}{3}$ to $\frac{1}{2}$ inch. This thickened part is 8 inches in length, antero-posteriorly, at the middle, but the concave anterior and posterior margins, as seen in the figure, are not natural edges but the stages at which the special thickening begins. The window shown in the figure between the membrane and the levator ani is closed by a thinner portion of the membrane. The coarse bundles of white fibrous tissue composing the membrane are transverse, those in front curving a little forwards, those behind curving very much backwards opposite the femur and behind it towards the back part of the pelvic bone. The thickening of the part connecting the femur inwards suggests a strap, and here, for some inches internal to the femur, is inserted a considerable muscle (tensor fasciæ) which will be noticed with the muscles attached to the femur.

The thick part between the pelvic bones shows three strata, separated by some oily fat, which outwardly have the following connections. The superficial stratum passes to the general surface and embraces the femur, not forming a distinct capsule for it, but joining its perichondrium at both borders and at both ends. This connection is a further means of keeping the femur in its place. The middle stratum is in part attached to the pelvic bone, continuously along the posterior half, more broken up along the anterior half; and in part passes across below the bone to join the fibrous septum external to the bone, seen in fig. 2. This crossing is especially by two strap-like bands, the posterior of which lies between the fore part of the femur and the pelvic bone. The deepest stratum is attached to the pelvic bone at the inner side, and in front of this to the neighbouring part of the pre-pelvic band, and may be said thus to join the fascia lining the pelvic cavity. At the anterior part of the pre-pelvic band the continuity with the pelvic

fascia is with the layer of the general aponeurosis immediately investing the anterior muscular mass. The penis here lies in a space roofed by the latter and bounded below by the interpelvic membrane. The uses that may be assigned to this strong interpelvic membrane are, assisting to resist over-separation of the pelvic bones; closing the outlet of the anterior division of the pelvis, thereby supporting the penis and the viscera above; and assisting to retain the femur in its place.

[In *megaptera* the arrangement of the interpelvic membrane corresponded very closely to that above described in B. musculus (1888, p. 277, and fig. 15). The larger femur renders that connection more important. In the dissection of the megaptera, the following, not included in my account of it, was noted, and may be of interest here. There was a *subcutaneous muscle* supporting the penis, extending from 3 inches behind the position of the rudimentary mammæ (which are situated 2 feet in front of the anus), forwards to the preputial opening (1½ feet in front of the mammæ), and thus supporting the anterior half of the penis. Its thickness at the edge of the prepuce was ½ inch, increasing backwards to 3 inches. It ended in tendinous tissue 3 inches behind the mammary pouch. Its bundles arose from a median raphé, were directed outwards and forwards, the obliquity increasing at the anterior part, and ended in the fibrous tissue of the wall. This subcutaneous muscle was not continuous with the transverse muscular layer dissected in front of the prepuce. I had the latter for 3½ feet, to in front of the umbilical fissure. Its bundles arose from a median raphé, and were directed transversely outwards, except behind, where they curve backwards and are overlapped a little by the former muscle. This *anterior subcutaneous muscle* is fully 1 inch in thickness, increasing at the back part to 2 inches. It lay close below the blubber, and there was a layer of fat 1 inch thick on its deep aspect. Both of these superficial muscles looked as if belonging to the panniculus, separated by the preputial opening, the posterior one adapted to supporting and compressing the penis and the prepuce. Behind it, that supporting function is served by the interpelvic membrane, the thickening of which between the pelvic bones further gives it the ligamentous function of tying the bones together. The interpelvic membrane and the compressor muscle may, perhaps, be regarded as the same stratum histologically changed. In *mysticetus* the tubularly developed ischio-cavernosus muscle serves this supporting function to the penis opposite the pelvic bones, and for a considerable distance anterior to them. If any special interpelvic membrane exists in *mysticetus* it had been removed; but with a femur so much longer and so differently placed, any such membrane could not have the same arrangement as in the finners.]

The Longitudinal Muscular Masses, anterior and posterior —(Fig. 2, *a*, *m*, *m*, and *p*, *m*, *m*).—These enormous masses of

muscle manifestly could not find attachment to parts so slender as the pelvic bones. Although the appearance at first is that they pass largely along the pelvic region, it is not so; they are entirely interrupted by attachment mainly to fibrous structures, in less part to the pelvic bone. The dissection of these intermingled masses of muscle and fibrous tissue was not easy, nor could the numerous particulars noted in the course of the dissection be given so as to convey a clear idea. But the following general account of the arrangement may be sufficient, noticing first the fibrous structures concealed within the fleshy masses.

Great Intermuscular Septa.—The longitudinal muscular masses all along the side of the pelvis, and backwards and forwards from it, are divided horizontally into an upper and a lower stratum by a thick sheet of white fibrous tissue, stretching out like a wing from each side of the pelvic cavity to beyond the pelvic bone and on a plane above the bone. This horizontal *fibrous plate*, as it may be termed, is of great extent and of great thickness. Behind the rectal fossa, it was traced for 6 inches (as far as the part removed for dissection allowed) and was there attached internally to the deep median fibrous septum. The median septum there shows, on transverse section, a diamond-shaped mass of fibrous tissue about 3 inches vertically, joined at the lateral angles by the fibrous plate. Forwards from this, along the side of the rectal fossa and for two inches outwards, the thickness of the fibrous plate was 1¼ inch; at four inches outwards, ¾ inch, diminishing outwards to about ⅛ inch. Inwardly here it spreads over the whole rectal fossa giving it a fibrous covering ½ inch in thickness, lined internally by the adherent fascia seen on the inner surface of the fossa (fig. 2). Along the anterior region of the pelvic cavity the thick inner edge of the right and left fibrous plates, continued from the raphé at the roof of the rectal fossa, form the boundary of the brim of the pelvic cavity, at first curving forwards and outwards, and then, when they have reached the part of the cavity in front of the bones, passing more directly forwards. The fibrous plate then passes forwards above the pre-pelvic band, concealed in the anterior muscular mass. At the side of the cavity the fibrous plate has above and below it the strata of the longi-

tudinal muscular mass, covered by the pelvic fascia passing down to be attached at the outlet to the pelvic bone and in front of that to the pre-pelvic band, smoothly lining and closing the cavity laterally and anteriorly.

Opposite the anterior region of the pelvis the fibrous plate passes outwards on a higher level than the pelvic bone and to beyond the bone. Here, external to the promontory, the fibrous plate shows itself as an edge, having bent down to interrupt the lateral longitudinal muscles. This part of the fibrous plate is seen in the dissection of the inferior aspect, as a free edge (fig. 2, *s*, *s*) passing semicircularly round and close to the promontory of the bone, from 6 inches behind the promontory forwards and inwards to about the middle of the beak of the bone. This part may be referred to as the semicircular septum. It has an attachment anteriorly to the beak of the bone, and sends two small bands inwards to the anterior border of the femur, seen in the figure. It had previously given off, under cover of the outer edge of the promontory, bands to the pelvic bone, directed inwards and forwards, attached on the upper surface of the bone two inches internal to the promontory. A continuation of this septum forwards is shown in the figure, seen on its edge on the right side, exposed on the left side (fig. 2, *f l*), separating a superficial longitudinal muscle from the neighbouring part of the longitudinal mass.

This great fibrous plate, concealed within the longitudinal muscular masses, thus furnishes an extensive surface for muscular attachment, far surpassing that of the pelvic bone, by which together the continuity of the entire muscular mass is interrupted; and, with its fellow of the opposite side, serves to form a more definite and fixed boundary to the pelvic cavity than the muscles alone would have formed. It may be said that, while the pelvic bone and post-pelvic band serve the purposes of the ischium, the great fibrous plate and the pre-pelvic band serve the purposes of the ilium and pubes of the quadrupedal pelvis.

(1) *The Posterior muscular mass.*—The anterior attachments, besides those to both surfaces of the fibrous plate, may be enumerated as follows. Those of the *under stratum* are shown in fig. 2 (*p*, *m*, *m*), the more superficial view on the left side

and in fig. 3 (*p, m, m*) the deeper attachments are seen. They are, from within outwards, to the post-pelvic band and neighbouring part of the wall of the rectal fossa; aponeurotic to the great interpelvic ligament; tendinous to the end of the pelvic bone; forwards and inwards to the inner part of the under surface of the pelvic bone; by a tendon, 1½ inch long, ⅝ inch broad, to the inner half of the posterior border of the femur; external to the promontory, broadly to the semicircular fibrous septum; fleshy to the great interpelvic ligament, and along the outer border of the bone to near the promontory; to the promontory by a narrow tendon; and to the semicircular septum, concealed by the part seen in the figure going to that septum. The first mentioned of these parts is seen to be soon attached behind to the median intermuscular septum. The attachments of the *upper stratum* are to the upper surface of the fibrous plate and to the fibrous roof of the rectal fossa, not to the pelvic bone. The bulk of the posterior muscular mass is partly shown in fig. 2 in the section made just behind the rectal fossa. The section is that of the under stratum only, and measures 12 inches by 4 inches.

(2) *The Anterior muscular mass.*—The attachments of the *under stratum* are shown in fig. 2 (*a, m, m*), differently dissected on the two sides. On the right side a distinct superficial muscle, 3 to 4 inches broad, is seen to arise behind from the semicircular septum, external to the promontory, and to be separated anteriorly from the rest of the longitudinal mass by the edge of the septum continued forwards from the semicircular septum. On the left side most of this muscle is removed, showing the surface of the septum with its transverse fibres; and to the inside of the latter is seen a portion of the superficial aponeurosis of the anterior muscular mass, left to show its relation to the tensor muscle of the interpelvic membrane. The attachments of the great part of the under stratum, besides that to the concealed fibrous plate, are, from within outwards, some bundles to the pre-pelvic band, passing shortly between it and the anterior median raphé; to the anterior half of the beak of the pelvic bone; to the semicircular septum, for 3 inches on the surface and deeply for more than that; and, external to this (as shown in fig. 3, *a, m, m*, right side), by a tendon, 1½ inches

broad, to the bone in front of the promontory. This tendon is superficial and closely adherent to the semicircular septum. It is not shown in fig. 2, in order to show the course of the septum and the fibrous bands to the femur.

The *upper stratum* is attached to the fibrous plate, inwards to the brim of the pelvis and outwards to above the pelvic bone. This stratum is connected to the fibrous plate by a series of tendons which, if described backwards, might be said to form the fibrous plate by their expansion, giving the fibrous bundles of the anterior part of the plate a longitudinal direction. One of these tendons, at the anterior half of the pelvic wall, is nearly as thick as the wrist and 4 inches in length, streaked in the interior with muscular fibres, and gives origin to a great pyramidal muscle which soon blends with the rest of the mass. One tendon, mixed with muscular fibre, as large as a thick finger, goes outwards and backwards to join the fibrous plate in front of the promontory of the pelvic bone. Some tendinous bands are attached to the anterior half of the pelvic bone on its upper surface, but the greater part of the upper surface of the bone is not occupied. A few inches in front of the pelvic bone the two strata (except the superficial lateral muscle) blend, the fibrous plate having broken up and ceased. Fig. 2 shows the bulk of the anterior mass in section, at 6 inches in front of the pelvic bone, 12 inches broad by 4 inches deep, but I am not certain that this gives the whole depth of the mass. It had been noted at first as 9 inches by 6, and had probably become flattened on the table when the figure was drawn.

In regard to action, the posterior mass is among the moving powers of the long caudal region, the anterior mass belongs to the abdominal wall. Acting reversely, the posterior masses will retract the pelvis and narrow it; the anterior mass will advance the pelvis, its action in either narrowing or widening the pelvis will depend on the anterior attachments of its parts; the whole acting together will compress the abdomen and pelvis.

The *pre-pelvic band* (fig. 3, *pr. b.*) connecting the anterior ends of the pelvic bones, is a band of white fibrous tissue; at the middle on each side $\frac{1}{8}$ inch thick, much thicker at the middle line where it joins its fellow as the anterior symphysis of the pelvis; and is connected with the raphé between the anterior

muscular masses. It was probably this band that formed the fibrous tuft at the end of the pelvic bone in Mysticetus.

[*Comparison with the anterior and posterior muscular masses in Megaptera and in Mysticetus.*—The differences in *megaptera* are considerable. My notes of the dissection contain no reference to a horizontal fibrous sheet concealed within the masses. The only fleshy attachment of the masses to the bone, is that of the posterior mass to the hinder end of the bone, and for 3 inches along the outer side (fig. 15, 1888). For the rest, the fibrous interruption is on the surface in the form of a tendinous expansion, sent forwards external and superficial to the pelvic bone. Nor is there even any fibrous attachment to the pelvic bone anteriorly, except by two flat tendons near the promontory (*i i* of the figure), together not much larger than the corresponding tendon near the promontory in B. musculus (fig. 3, *a*, *m*, *m*). For 4 inches forwards, being the extent available for dissection, there was only fibrous tissue. Thus the flesh in megaptera, especially in front, does not come nearly so close to the pelvic bone as in B. musculus, nor, so far as I can judge, is its bulk so great as in B. musculus. The lesser bulk would account for the absence of the fibrous plate in megaptera. What is merely an intermuscular septum (the semicircular septum) in B. musculus is, in megaptera, elongated into an intervening tendon, a transformation often enough met with in anatomy. Comparing the pelvic bones in B. musculus and megaptera, the shortness of the beak in the latter may be accounted for by the much less attachment to it of the anterior muscular mass than in B. musculus.

In *mysticetus* (1881, figs. 13, 14, 17, 18), the posterior muscular mass showed no subdivision and was entirely attached, fleshy, to about the posterior half of the pelvic bone. The anterior mass was larger than the posterior, and the subdivisions of the fleshy mass are accounted for by the length and position of the femur. The whole of the attachments of both anterior and posterior masses were fleshy upon the bones. Besides the presence of a good-sized femur, the pelvic bone in mysticetus is very much larger than in the finners.

Exact comparison of the bulk of these muscular masses in these three species would be difficult, but on comparing the size of the sections now given in a full-grown mysticetus, in megaptera, and in B. musculus, and my full-sized drawings made during the dissection of each, it appears that the bulk of red flesh at and near the pelvis is much greater in B. musculus than in the other two. If so, that would accord with the great activity attributed to B. musculus, to which it owes its name. The great fibrous plate concealed within the masses in B. musculus appears to stand in relation to this greater muscularity.]

(C) *Muscles attached to the Femur.*

Besides the ligaments and other retaining fibrous bands above described, the femur has three direct muscular connections, a

posterior, an internal, and an anterior, and indirectly a fourth, connecting it to the anterior muscular mass. These are portions of muscles rather than muscles devoted to the femur, but they will act on it not the less. Being attached to a structure so rudimentary as this femur they deserve particular examination.

(1) *Posterior muscle of the Femur.*—This is one of the anterior attachments of the posterior muscular mass already noticed. Its different arrangement on the two sides is shown in the figures (fig. 2 and in fig. 3, *p m*). On the left side the tendon is $\frac{5}{8}$ inch broad at the middle by $1\frac{1}{2}$ inch long, and is inserted along rather more than the inner half of the posterior border of the femur; on the right side the tendon is a little smaller, attached to rather less than the inner half of the femur, and the fleshy portion is more isolated from the rest of the muscular mass than on the left side. At 4 inches from the femur, where the muscle becomes detached from the mass, it is 2 inches in breadth by $\frac{5}{8}$ inch in thickness. It is the strongest of the muscles attached to the femur, say, at the point mentioned, equal in bulk to the biceps muscle of the human arm, very large in proportion to the femur if regarded as for moving the femur. It may be regarded simply as one of the anterior attachments of the posterior muscular mass, for which the femur is rendered a fixed point by the resisting action of its anterior muscle.

(2) *Anterior muscle of the Femur.*—This muscle is a part of a large muscle (fig. 2, *t f*), the inner and greater portion (tensor fasciæ) inserted into the interpelvic membrane, the outer portion, about a $\frac{1}{4}$ of the whole, inserted into the femur. The entire muscle is as bulky as the palm of the hand, but of different shape on the two sides: on the right side fan-shaped, the apex forwards; on the left side square-shaped, owing to the outer portion being carried more forwards. The *tensor fasciæ* portion arises from the anterior part of the pelvic bone for $1\frac{1}{2}$ inch, beginning about 1 inch from the point. This narrow origin is by a short tendon from which fibrous septa, 4 or 5 in number, radiate backwards, giving origin to the fleshy fibres, forming a multi-penniform muscle. The outermost part of the tensor arises in part from the deep aponeurosis external to the bone and in part from a septum common to it and the femoral portion of the muscle. On the left side this septum received a

narrow slip of tendon direct from the posterior muscular mass, not present on the right side. The *femoral portion* of the muscle is bi-penniform, arises internally from the last mentioned septum, externally from the deep aponeurosis, and on the left side is prolonged forwards a little, giving the square shape and leaving a notch anteriorly between it and the tensor. Thus the entire origin of the femoral part is from movable fibrous structures, that of the tensor mostly from the bone.

The insertion of the femoral portion is along the inner half of the anterior border of the femur, by its median septum and flesh on each side, this being just opposite the insertion of the posterior muscle at the posterior border. But it is inserted also into the superficial aponeurosis for an inch before it reaches the femur, so that the femoral portion of the muscle is likewise a tensor of the fascia, not acting distinctively on the femur. The most posterior insertion of the greater portion (tensor fasciæ) is to the interpelvic membrane for about 4 inches transversely internal to the femur, its outer part reaching to the tip of the femur; and in front of this the insertion is on the deep surface of the interpelvic membrane along the posterior half of the length of the muscle. Length of the greater muscle, 4½ inches; breadth at the back, 4 inches: length of the femoral portion, 4 inches; breadth, 1½ inches. Thickness of the greater portion over ½ inch, of the femoral portion about ¼ inch. The femoral portion, besides being thinner, is mixed with fibrous tissue, giving it a ligamentous function in addition to its contractile function. The bulk of the femoral portion of the muscle is equal to three times that of the femur. The left was larger than the right; it weighed 4 oz. 50 grains, the right ½ oz. less.

The action of the entire muscle will be to move the femur forwards and inwards, but only along with the aponeurosis in front and internal to it. The femoral portion acting alone would move the inner end of the femur more directly forwards, but the close connection with the larger portion will cause a general inward and forward movement of the femur and of this part of the aponeurosis. Where the greater portion of the muscle is attached to the interpelvic membrane, the membrane is specially strong, almost like a strap crossing from side to side, the fibres curving backwards, as noted with the membrane and

as seen in fig. 1. The function of this pretty large muscle is not evident apart from that of resisting retraction of the femur by its posterior muscle, and of fixing the femur as one of the attachments of the posterior muscular mass. The external ligament of the femur is adapted to resist inward and forward traction as by this muscle acting as a whole. [No such muscle was found in connection with the femur or the interpelvic membrane in Megaptera.]

(3) *Internal muscle of the Femur.*—This muscle (fig. 3, *i m*, left side) is only in part attached to the femur, and consists of muscular fibre much mixed with fibrous tissue. It looks like a deeper portion of the tensor fasciæ muscle, but is separated from it by a tendinous covering. The origin of this sub-pelvic muscle is from the beak of the pelvic bone, beginning just behind the origin of the tensor fasciæ, and extending outwards for some inches as far as to between the femur and the pelvic bone. It divides into two parts, each about the size of the fore-finger; the anterior inserted into the semicircular septum and the bands from the septum to the femur, and in part to the tip of the femur; the posterior, passing between the pelvic bone and the femur, inserted into the outer and posterior part of the femur, on its deep surface; and a portion is continued, tendinous, to be attached to the pelvic bone, seen behind the femur and the posterior ligament of the femur, near the acetabular cartilage. The posterior portion of the muscle, that to the femur, is parallel to the portion of the posterior muscular mass that is continued forward on the under surface of the pelvic bone, but is distinct from it. The part to the femur looks at first more like a ligamentous structure, but striped muscular fibres are blended with the white fibrous tissue. This part of the muscle is smaller on the left side than on the right. The action of this sub-pelvic muscle upon the femur will be to move it inwards and a little forwards, like the tensor fasciæ muscle superficial to it, resisted by the external ligament of the femur. The part that is detached to pass behind the femur, to be attached again to the pelvic bone, can have no contractile action except slightly to assist in preventing the femur being lifted off the pelvic bone.

(4) *Connection of the Femur with the anterior muscular*

mass.—The anterior fibrous bands to the femur have been noticed as proceeding from the semicircular septum. They come from where that septum is intimately adherent to the deep surface of the tendon of the part of the anterior muscular mass shown in fig. 3 (*a, m, m*) and are common to both. These two bands (seen on the right side of fig. 2) are of considerable strength; length $\frac{3}{4}$ inch; breadth of one is $\frac{1}{2}$ inch, of the other $\frac{1}{4}$ inch; thickness about $\frac{1}{10}$ inch; direction backwards and a little inwards. That was on the right side; on the left side they were more broken up; on the right side attached more to the outer, on the left side more to the inner part of the anterior border of the femur. By means of these bands the anterior muscular mass here may move the femur a little forwards, or they may serve, with the anterior muscle of the femur, to resist retraction of the femur and to fix it as a point of attachment of the posterior muscle.

Summary of the Connections of the Femur and their Adaptations.

The various ligamentous and other fibrous retaining structures, and the muscular connections, now described, may be here summarised, reference again to the figures being implied.

Ligaments.—The external ligament, the strongest, is adapted to resist over-movement inwards and forwards; the posterior ligament to resist movement forwards and outwards; the interosseous ligament, small, mostly to resist forward movement.

Other fibrous retaining structures.—The superficial interpelvic and interfemoral membrane, attached all round the edges of the femur, retains it in its place generally, especially resisting inward and outward movement. The anterior bands resist backward and inward movement. The fibrous tissue mixed with the femoral part of the sub-pelvic muscle would resist outward and backward movement, but there is no muscle placed so as to produce that movement.

Muscles.—The femur is moved forwards and inwards by its anterior muscle together with the tensor fasciæ muscle, and deeply by its portion of the sub-pelvic muscle, together a strong muscular power; resisted specially by the external liga-

ment. It is moved backwards by its posterior muscle, a strong power, resisted only and not very exactly by the fibrous bands connected with the anterior muscular mass. The femur will be moved forwards by its anterior muscle, and a little through the bands connecting it to the anterior muscular mass; resisted by the posterior ligament, but it is not evident why the posterior ligament should be directed so obliquely outwards, unless the connection of the femur to the anterior muscular mass has a strong influence in moving it forwards and outwards.

All these attachments—ligaments, fibrous bands, and muscles, some of them very large in proportion to the femur—which I have endeavoured to trace with exactness, look like adaptations for the performance of various movements of the femur and for checking over-movement, but to no evident purpose. The comparison of the femur to a sesamoid bone, like the patella, is suggested, but there is no synovial membrane, no cartilage on the pelvic bone for the femur to play on, and no definite movement. Within the limits resulting from these attachments, and before any of them were divided with the knife, the femur slipped about loosely in the fingers in all directions. The attachments were not quite the same on the two sides, and, in the next B. musculus dissected, they may, not unlikely, be found to differ from those above described.

[In *megaptera* (fig. 15, *l*, 1888) the posterior ligament is the great one, and there is only one muscle attached to the much larger femur, contained within a division of that ligament. In *mysticetus*, the predominance of the posterior ligament (fig. 11, 1881) is still greater. The greater length and different position of the femur prevents any useful comparison of the muscles with those now described in B. musculus.]

III. Adaptations and Comparison of the Pelvic Bone and Femur in the different species.

(A) *Adaptations of the Pelvic Bone in relation to the soft parts in B. musculus.*

Although much reduced, compared with the innominate bone in mammals with a hind limb employed in locomotion, the pelvic bone in the cetacea is not a rudimentary structure. On the contrary it is fully and variously functional. The pelvic bones, in rela-

tion to the visceral chamber of the body, form a firm boundary on each side of the pelvic outlet, and they attach and form stretchers to the fibrous structures that complete the girdle before and behind; in relation to the reproductive organs, they attach and stretch the great transverse ligament on which the penis and its muscles are supported in the male; and they attach large muscles that, posteriorly, assist in moving the tail in locomotion, and, anteriorly, act on the abdominal and thoracic walls. The numerous muscular and fibrous parts attached to the bone and other relations to the soft parts in this B. musculus are fully given above, and may be referred to here only in relation to the form of the bone. That will be better understood by taking the full-grown bone.

The general concavity of the bone internally has reference to bounding the pelvic outlet. The thickness of the posterior portion of the bone is related, (*a*), to the attachment of a large amount of muscle along nearly its whole length; and, (*b*), to attaching, behind and for some way on the inner surface, the great interpelvic ligament for the support of the penis and for the attachment of various muscles. The lateral flattening of the anterior part of the beak appears to be related to attaching a considerable amount of muscle on one side, the external; and internally to inclosing the pelvic cavity. To the borders here are attached the pelvic fascia above, the interpelvic membrane below, the smooth flat periosteal surface forming a wall to this part of the pelvic cavity. The narrowing of the internal surface into a mere border, at the central part of the bone, corresponds to the flattening and expansion of the bone at this part. The upper surface is free, covered only by periosteum, except where it attaches a few fibrous bands; at two inches internal to the promontory, from the semicircular septum; and some on the beak, connected with the great intermuscular fibrous plate. The under surface, as seen in the figures, is mostly occupied by muscular attachments, though not of large muscles. The promontory, with the great breadth of the central part of the bone, is a striking character. This projection is not, like many long projections, for muscular leverage. A tendon of moderate size was attached near it in front, and a small tendon, which was not symmetrical, was attached to it from behind, but the

process proper is for the most part unoccupied by muscles, and lies free beneath the semicircular septum. The breadth and projection of this part of the bone would seem to stand in relation to the presence and retention of a femur, or to the presence of an acetabular cartilage. The external ligament of the femur is the most definite structure attached to the promontory, and it is interesting to notice that just external and posterior to this ligament is an area (as seen in figs. 2 and 3) to which neither muscle nor ligament is attached, and that this is the area of the acetabular cartilage, concealed beneath the periosteum.

(B) *Comparison of the Pelvic Bone in the Fin-whales and in Mysticetus.*

In Plate XX. figures are given of the pelvic bones in the Whale-bone whales I have had the opportunity of dissecting: a 14½-feet-long *Balænoptera rostrata;* a 36-feet-long *B. borealis;* and of the pelvic bone, and femur and its ligaments, of the 50-feet-long and of the 64-feet-long *B. musculus;* of a 40-feet-long *Megaptera;* and of a 35-feet-long and a 48-feet-long *Mysticetus.* They are all from males except that of the B. rostrata, and all the figures are reduced to ⅛ the natural size. In making the comparison it is essential to bear in mind the degree of maturity of each, as inferred from the length of the whale.

(1.) Figure 6. This figure is from the young Lesser Fin-whale (*B. rostrata,* Pike-whale of John Hunter) stranded alive at Aberdeen, July 1870, the articulations of the cervical vertebræ of which I described in this *Journal,* 1872. Having reached only about half (14½ feet) the attainable length in this species, the bone figured cannot be regarded as typical. Total length, 3¼ inches, of which the anterior cartilage occupies ⅞ inch, the posterior cartilage ⅝ inch. The ossified part increases gradually in breadth backwards; breadth at the middle ½ inch, posteriorly ⅝ inch; thickness ⅛ to $\frac{3}{16}$ inch.

(2.) Fig 7 (R) and (L). These figures represent the right and left pelvic bone of the 36-feet-long Black whale (*B. borealis,* Rudolphi's rorqual) beached alive at St Margaret's Hope, Orkney, in the end of November 1884; as yet only referred to

occasionally in my account of Megaptera longimana, in this *Journal*, 1887–89. As the length of this species may reach 45 feet or even 50 feet, the figure cannot be regarded as representing the full-grown pelvic bone, but it may be taken as showing the general form in contrast with that of B. musculus. The bone of both sides is figured, as there is considerable a-symmetry. The chief differences are, that the bone of the right side has a well-marked promontory, that it presents a marked flattening and expansion towards the anterior end, and that it is somewhat broader generally, so that it is altogether more robust than the left, rendering it about a fourth heavier than the left. The total length was about 7 inches, of which the cartilages made $1\frac{1}{2}$ inches.[1]

On the bone possessing the considerable promontory, that of

[1] The dissection of the pelvic region was made in 1885, under pressure for time, only to the depth necessary to enable me to ascertain that a femur was not present. The parts were preserved for subsequent dissection of the muscles, &c., but, under the misapprehension that I was done with them, have been macerated since I left Aberdeen. In their natural position the pelvic bones were 12 inches apart, the hinder end 9 inches in front of the anus. The superficial compressor muscle of the penis and prepuce, and the superficial interpelvic membrane, had the same arrangement as described above in Megaptera and B. musculus. The former was 2 inches, the latter $\frac{1}{2}$ inch thick. The following particulars of the *ossified part* of the pelvic bones are given to show their a-symmetry. The measurements are in inches, those of the *right* side the *first* given of each measurement. Lengths, total $5\frac{4}{8}$ and $5\frac{6}{8}$; of the anterior portion $3\frac{6}{8}$ and $3\frac{7}{8}$; of the posterior portion, equal, $1\frac{7}{8}$. Breadth and thickness of the *posterior portion*, at the middle, breadth $\frac{7}{8}$ and $\frac{6}{8}$, thickness $\frac{7}{16}$ and $6\frac{6}{16}$; at the posterior end, breadth $\frac{11}{16}$ and $\frac{10}{16}$, thickness $\frac{7}{16}$ and $\frac{6}{16}$. The posterior portion is thus a little broader and thicker on the right than on the left bone. At the *promontory*, breadth $1\frac{1}{4}$ and 1; thickness, equal, $\frac{7}{16}$. Breadth and thickness of the *anterior portion*, at the middle, breadth $\frac{6}{8}$ and $\frac{5}{8}$, thickness, equal, $\frac{5}{8}$; at the broadest part anteriorly, being $1\frac{1}{4}$ inch from the end, breadth 1 and $\frac{5}{8}$, thickness $\frac{5}{8}$ and $\frac{6}{8}$; at the middle of the anterior flattened end, transversely $\frac{8}{16}$ and $\frac{9}{16}$, vertically $\frac{14}{16}$ and $\frac{13}{16}$. The change in proportion between these two last measurements is owing to the anterior end of the bone, especially of the right side, becoming flattened laterally, so that the thickness (vertically) exceeds the breadth (transversely). But the change in direction is not complete, the outer surface towards the anterior end facing obliquely outwards and downwards, so that the expanded anterior end of the right bone appears as if twisted on the part behind it. In the figures the bones are rotated a little so as to show the square-shaped expansion of the anterior end of the right bone. Thus, the right bone is broader than the left throughout, much so at the anterior end and at the promontory; the left bone is $\frac{1}{8}$ inch longer than the right, and, in thickness, loses as much on the posterior portion as it gains near the anterior end. The weight of the right pelvic bone is 571 grains, of the left 458.

the right side, there is on the promontory a marked oval area corresponding exactly to the area where the *acetabular cartilage* lies in the B. musculus and in the Right-whales. It is here ½ inch in length by ⅓ inch in breadth, and lies entirely on the under surface of the promontory, not extending round the edge of the bone. The surface is irregular, mostly excavated, and is quite like a surface which had sustained a cartilage. On the left bone, on which the promontory is but little developed, this mark is not present. The outer border of the promontory is thicker than that of the right bone, and along it there is a longitudinal depression, not reaching to the under surface of the bone. It does not look as if it had supported a cartilage, but rather to be the result of the growth of its margins. It may be that a well-developed promontory and the presence of an acetabular cartilage stand related. At fully ½ inch in front of the promontory there is a notch in the outer border of the bone, deepest and narrowest in the left, the least broad of the two bones. This notch corresponds in position exactly to the oval foramen noticed in the 64-feet-long B. musculus, as seen in fig. 9. One would expect such a foramen to be vascular, but in the B. musculus it was occupied by fat.

(3 *and* 4.) Figs. 8 and 9. The characters and differences of these two pelvic bones of the Razorback whale (*B. musculus*), one from a 50-feet-long, the other from a 64-feet-long, have been commented on above. In contrast with B. borealis they have great breadth at the central region with outward projection to form a promontory, and with this there is the presence of a femur. These two pelvic bones of B. musculus differ from each other very little in breadth at the central portion, but very much in the more mature specimen showing great prolongation of its anterior and posterior portions, much flattening laterally on the anterior half of the anterior portion, and great robustness on the posterior half of the posterior portion. As this species attains a length of from 60 to 70 feet, with an average of over 64 feet, this specimen may be regarded as nearly full-grown. Between the 50-feet-long one and the 64-feet-long one the increase in length, on the anterior portion of the bone from 9 inches to 13½, and on the posterior portion from 5½ inches to 10½, giving an increase on the total length of the bone from 10⅛ to 23

inches, is remarkable if the difference is merely a matter of age. There may be differences from variation, but we see at least the necessity for, if possible, having mature specimens for comparison. The shortness of the cartilages in the younger specimen (about the same length as in the more mature one), in striking contrast with their length, relatively to the ossified portion, in Megaptera, would seem to render doubtful that it could ever have attained such a length as that of the more mature specimen; but that raises the question of the mode in which ossification proceeds.

(5.) Fig. 10. This figure is from my account of the 40-feet-long Humpback whale (*Megaptera longimana*) in this *Journal*, 1888, the skeleton now placed in the museum at Dundee, in the neighbourhood of which this Megaptera first showed itself. As this species may attain a length of fully 50 feet, this specimen, judging by the attainable lengths of the two species, may be inferred to be about as far from maturity as that from the 50-feet-long B. musculus. In the latter the total length of the bone is 10⅛ inches, in Megaptera 9¼, but the relative length of the anterior and posterior portions is very different; in B. musculus the anterior much longer than the posterior (respectively 9 and 5½ inches), in Megaptera the anterior shorter than the posterior (respectively 5 and 6½ inches). The shorter beak in Megaptera may be accounted for by there being no fleshy attachments to it, and tendinous attachments only near the promontory; but, looking to the relative size of the anterior and posterior muscular masses, it is not evident why in B. musculus the anterior part of the bone should be so much longer than the posterior, nor is it evident why the posterior part of the bone should be longer in a 40-feet-long Megaptera than in a 50-feet-long B. musculus.

A remarkable difference is in the lesser extent of ossification in Megaptera. The lengths in Megaptera are, ossified part 4½ inches (straight) and about equally in the two portions; posterior cartilage 3¼ inches, anterior cartilage 2 inches. In B. musculus, ossified part 8⅛ inches, posterior cartilage ¾ inch, anterior cartilage 1¼ inches. The progress ossification has made is perhaps not always a very reliable test of age. In this Megaptera a large part of the bone had still to ossify at the expense of the cartilages, in the B. musculus much further elongation could not

have taken place within the cartilages. In Megaptera the promontory is less projecting, and the breadth of the bone here is less; breadth in Megaptera $2\frac{1}{4}$ to $2\frac{1}{2}$ inches; in the 50-feet-long B. musculus $4\frac{3}{8}$ inches, in the more mature one 4 inches. In regard to this difference it may be noted that in Megaptera the femur lies more towards the inner edge of the bone, and is differently directed, so that its chief ligamentous attachment to the bone is not at the promontory, but behind.

(6 *and* 7.) Figs. 11 and 12. These figures are from among those given of the Greenland Right-whale (Balæna mysticetus) in this *Journal*, 1881. They are selected, the 35-feet-long one (probably about $\frac{2}{3}$ grown) for comparison with the not mature B. musculus; the 48-feet-long one (probably full grown, being a male) for comparison with the mature B. musculus. Had the pelvic bone of the Megaptera been more fully ossified it might be taken, carelessly, for that of a Mysticetus younger than the 35-feet-long one, but the differences are marked. Especially the more transversely directed beak, and the shortness of the beak, relatively to the posterior part of the bone, would at once indicate Mysticetus. A comparison of the pelvic bone of a full-grown male and female Megaptera with those of B. musculus and Mysticetus is desirable should opportunity offer. These specimens enable that to be done between B. musculus and Mysticetus, and a glance at the figures will show that they are quite different both in the young and in the mature condition. In Mysticetus the shortness of the beak compared with the body, and still more the transverse direction of the beak, coming down in some of my specimens (as in figs. 1, 3, and 5, 1881) so as to form almost a right angle with the body; and the form of the body posteriorly, either very thick in the male or flat in the female, are characters by which the pelvic bone of that species may be at once known and easily distinguished from that of B. musculus. I have not had an opportunity of examining the pelvic bone in the female of B. musculus or of Megaptera, but in Mysticetus the great thickness of the hinder end of the bone in the male, and its flatness, usually with expansion, in the female, are characteristic. It is, indeed, easier to tell the male from the female pelvic bone in Mysticetus than to tell a male from a female pelvis in human anatomy. But that, within

these general characters, there may be great individual variation in the form and size of the pelvic bone is abundantly seen in my series of specimens of that bone in Mysticetus, some of which I figured in 1881. I may mention that some of these interesting specimens of the pelvic bone of Mysticetus, with the femur and with a model of the cartilaginous tibia attached, may be seen in the anatomical museums of Aberdeen, Glasgow, and Edinburgh Universities, in the Edinburgh Museum of Science and Art, and in the Natural History Museum, London, presented by me.

(C) *Comparison of the Femur in Fin-whales and in Mysticetus.*

In *mysticetus* (figs. 11 and 12, F) the femur is an ossified bone, of considerable length, varying from 4 to 9 inches, and, amid abundant variety in form, has certain definite characters, such as head, neck, tubercle for the great posterior ligament, and an enlarged distal end adapted for articulation with the cartilaginous tibia, forming the knee joint with a capsule and synovial cavity. In position, it lies nearly parallel to and partially behind the beak of the pelvic bone. At its outer end it forms the hip joint with the pelvic bone, resting on the acetabular cartilage on the back part of the promontory or in a more or less excavated acetabulum, a synovial cavity between, and is retained by anterior and posterior ligaments and by a tendinous capsule provided with three thin capsular muscles. To the body of the femur are attached a great posterior ligament and two small anterior ligaments, three small muscles from the pelvic bone, and anteriorly a great mass of muscle, from the anterior muscular mass, common to the femur and the beak of the pelvic bone. Yet, with all this apparatus for producing and checking definite movements, I found, in two of the eleven Right-whales in which the observation could be made, these functional adaptations rendered nugatory by complete bony ankylosis of the hip joint, in an adult male on both sides, in an adult female on one side only. The only function remaining was that of affording attachment to part of the anterior muscular mass in addition to that afforded by the beak of the pelvic bone.

In *megaptera* (fig. 10, F) the conical cartilaginous femur; in

length, 3¾ inches on one side, 5 inches on the other; lay antero-posteriorly across the beak of the pelvic bone, without hip joint or acetabular cartilage; connected behind by a strong ligament to the pelvic bone and the interpelvic ligament, and externally by a lesser ligament to the promontory; and was otherwise retained in position by anterior fibrous bands and by the general interpelvic and interfemoral membrane. It had one muscle only, concealed within one of the divisions of the posterior ligament, acting as a retractor. It could be under no other muscular influence except indirectly that of the posterior muscular mass, at a distance, through the fibrous membrane; and possibly that of the anterior muscular mass, at a distance, through the fibrous band sent forwards from the apex of the femur. Except as so far retained by these connections, the femur lay loosely and without any apparent function.

In *B. musculus* (figs. 8 and 9, F) the femur is reduced to the condition described above; in the 64-feet-long one, 2 inches in length and mostly ossified; in the 50-feet-long one, 1⅜ inch in length, and entirely cartilaginous; retained by an external and a posterior ligament and by the general interpelvic membrane; with several portions of muscle attached to it, as described above; an acetabular cartilage present, but the femur not in contact with it and no synovial cavity present; except in so far as retained by these structures, lying loosely; the only function recognisable being that through the neighbouring muscles finding some attachment to it.

In the *B. borealis* and the *B. rostrata*, I found no trace of a femur. Reduced to a minimum in B. musculus, it has disappeared in B. borealis.

Concluding Remarks.—The result of the preceding inquiry is, I think it will be granted, the conclusion that the presence of this bone representing the thigh-bone in Fin-whales cannot be accounted for from the point of view of function, that it can be regarded only as a vestige. The significance of such vestiges in relation to the question of the origin of species is evident. A more rudimentary structure than this remnant of a femur in these great whales, it would not be easy to imagine. The femur in Mysticetus reduced and very variable, more reduced in Megaptera, reduced to a minimum in B. musculus, and

vanished in B. borealis. Some lessons in caution in the slippery exercise of seeking functional explanation of the presence of rudimentary structures occur in the above inquiry. After assigning functions to the muscles, ligaments, and synovial sacs of the hip joint in Mysticetus, we are met by the fact of the great variation of the bone, and by the fact of the occasional occurrence of stoppage of all movement by ankylosis of the hip joint without trace of disease; we see the acetabular cartilage not present in Megaptera which has the larger femur, but present in B. musculus which has the most reduced femur; we see the minimised femur of B. musculus with more and larger muscles attached to it than the larger femur of Megaptera has; and so on. It is necessary to the completeness of the inquiry to follow the anatomical details to the end, but in endeavouring to assign uses to rudimentary structures, we have to keep in view that such parts may in reality serve no purpose of functional utility, may be meaningless except as the products of decreasing heredity or as the incidents of variability, and that the parts attached to such structures may be but remnants or may be adaptations acquired amid the surrounding activities. The thigh-bone in this 50-feet-long whale would correspond, in a human body without its lower limbs, to a bone the size of a grain of wheat, concealed in the abdominal wall where the hip joint would have been, with a few threads of ligament and of the neighbouring muscles attached to it.

APPENDIX.

External Characters and Measurements of this Whale.

As I had a good opportunity of observing the external characters and of making careful measurements of this whale, assisted by Mr Robert Gibb and Mr George Sim, I give the following from my notes. These may be compared with those given in my account of the 64-feet-long B. musculus in this *Journal*, vol. vi., 1871.

Colour. Black on the back, white on the breast and belly. *Plaitings of the skin* (carcase lying on left side). Posterior limit, 26½ feet from point of lower jaw, 22½ feet from notch of tail. Highest plaitings run on level from angle of mouth to anterior edge of paddle; two run only ⅓ of that distance. Behind paddle they extend for about 10½ feet, the line of ending along the last half of that distance curved downwards with the convexity backwards. At anterior half of lower jaw the plaitings curve downwards and backwards before they be-

come horizontal. Here the ridges seem broader than further back, but this may be owing to the grooves being opened up. Thence on to the paddle they are narrow, about 1 inch in breadth, a few of the highest nearly 2 inches. Behind paddle and on the belly they are mostly 1¼ to 1½ inches broad, some scarcely 1 inch.

[This contrasts with the great breadth of the ridges in Megaptera, and their narrowness in B. rostrata. In my 40-feet-long *megaptera* the ridges were 4½ inches or more in breadth, the total number of ridges only 24. In my 14½-feet-long *B. rostrata* the ridges I noted across the breast were mostly ½ inch, some ⅝ inch; at their extreme ends before and behind, 1 inch, a few 1¼; the narrowest, below back part of mouth, ¼ to ½ inch; the total number of ridges just in front of the paddle was 57, between the eyes 66.]

Whalebone. Length of longest plates 20 inches; shortest, in front, 4 inches. Colour, on the outside, black or of deep slate colour; on the surfaces between the plates, slate colour; at the fringe of bristles, facing the mouth, and at the lower end of the plates outside as well as inside, of a dirty cream colour.

Paddle (pectoral fin). Length (including estimated 5 inches cut off at tip), on anterior border 6 feet; posterior border 4 feet 2 inches. Greatest breadth 16 inches. Position, distance from point of lower jaw to anterior border 15 feet 4 inches, to posterior border 17 feet 4 inches.

Tail Fin. Tip to tip 10 feet 3 inches; greatest breadth of lobe 2 feet 8 inches.

Dorsal Fin. Position, distance from middle of fin to edge of lobe of tail-fin, 13 feet 4 inches; from point of upper jaw, 37 feet; from point of lower jaw, 37 feet 8 inches. Form, falcate, anterior edge convex, posterior edge very concave, but point not much recurved. Height, requires definition; fin proper 14 inches, but rises 18 inches above general line of back from a 4-feet-long base. This base extends 20 inches behind and 28 inches in front of middle of fin proper, and has an elevation of 6 inches at its fore part and of 4 inches at its back part above the general line of the back. Thickness of fin proper, below, 2 inches.

Body. Total length of whale, from point of lower jaw to edge of lobe of tail-fin, measured straight, 50 feet; to notch of tail-fin, 49 feet 6 inches. Measured along the surface, to edge of lobe of tail-fin, 51 feet. Semi-circumferences of the region between neck of tail-fin and the dorsal fin:—at neck of tail-fin, surface much curved, 2 feet 2 inches; at ¼ of the distance forwards (2 feet 4 inches from neck), 3 feet 10 inches; at 3 feet from the neck, the most "razor-back" part, the form very compressed and sharp above and below, 4 feet 2 inches; at mid-way between the tail and dorsal fins (4 feet 8 inches from the neck), 4 feet 5 inches; at ¾ of the distance, 4 feet 10 inches. Position of preputial opening and of anus:—distance from point of lower jaw to centre of former, 32 feet 3 inches; to centre of anus, 36 feet 2 inches; from edge of lobe of tail to anus, 13 feet 4 inches.

Head. From point of lower jaw to outside of angle of mouth, 10 feet 3 inches; to inside of angle of mouth, 9 feet 9 inches; to middle of eye, 10 feet 2 inches. From point of upper jaw to front of blow-hole, 8 inches; length of blow-holes 13 inches. From eye to eye, centre of, round the top of the head, 7 feet. This line crosses at hinder end of blow-holes. Breadths of upper jaw, between point of jaw and back of blow-holes, taken on the surface:—at ¼ of that distance from point, 2 feet 3 inches; at mid-way, 3 feet 2 inches; at ¾ of the distance, 3 feet 10 inches. Breadths of lower jaw (edge of lip):—at middle (5 feet from point), 4 feet 11 inches; greatest breadth (nearly 8 feet from point) 6 feet 5 inches. From this point to inside of angle of mouth, along the curve, 3 feet.

Ear-hole. Position, 2 feet behind the eye and on the same level; size, just admits a rather small-sized goose quill, to the sigmoid stage.

Beard. Very few hairs remained. One I have preserved is fully ½ inch in length and is white.

EXPLANATION OF PLATES XVII.—XX.

All the figures are reduced to one-sixth.

Plate XVII. fig. 1. Superficial view of pelvic region. The dotted lines show the position of the femur, pelvic bone, and pre-pelvic band, covered by the superficial aponeurosis. The large muscle, *l*, *a*, the levator ani; *a* near the anus, surrounded by the internal sphincter ani muscle; on each side of the levator ani is seen the superficial edge of the post-pelvic band, attaching the levator ani and *a p*, the superficial aponeurosis. In front, *a p*, the superficial aponeurosis; *m*, between the pelvic bones, thickened part of the same, forming the interpelvic membrane or perineal fascia; stronger curved fibres of the membrane are seen internal to the femur where the tensor fasciæ muscle is attached. Through the window cut in the membrane are seen, in the centre, *r*, *r*, the retractor penis muscles, emerging from between the levator ani and the bulbo-cavernosus muscles; on each side a portion of the ischio-cavernosus muscle, *i*, *c*, on the crus penis.

Plate XVIII. fig. 2. Deeper view of same, superficial aponeurosis, levator ani and rectum removed, exposing the anterior and posterior muscular masses and muscles connected with the penis and the pelvic bone and femur, and showing the pelvic cavity and outlet. Posteriorly, *r*, *f*, the rectal fossa, or rectal portion of the pelvic cavity, with its fibrous wall and median raphé at the roof. Bounding the rectal fossa is seen the edge of the post-pelvic band, *po. p*, passing backwards from the pelvic bone to meet its fellow in the median intermuscular septum behind. On each side of the rectal fossa is seen the posterior or caudal muscular mass, *p*, *m*, *m*, the under stratum of it shown in transverse section on the right side. In front of the rectal fossa, *b*, *c*, the bulbo-cavernosus muscle with its median raphé, reaching only a short distance on the parts of the penis. In front of this muscle, in the middle, the bulb of the corpus spongiosum urethræ, with part of the crus penis on each side of it; on each side, the ischio-cavernosus muscle, *i*, *c*, concealing the outer part of the crus and of the corpus cavernosum penis. On each side of the penis and ischio-cavernosus muscle is the anterior region of the pelvic cavity *p*, *c*, shaded on the right side, blank on the left side, bounded externally by the pelvic bone, *P*, occupied at the outlet by fat. The very dark shading at the inner part of the anterior division of the pelvic cavity, and in front of the rectal fossa, shows, as far as possible in such a view, the inlet of the pelvic cavity. Bounding

the pelvic cavity in front, the pre-pelvic band, *pr*, *b*; in front of this and the pelvic bone, the anterior muscular mass, *a*, *m*, *m*, shown in transverse section on the right side. Muscles and fibrous bands attached to the femur, *F*, here shown, are on the *left side* of the dissection, posteriorly, tendon from a portion of the posterior muscular mass, detached from the part of the mass passing forwards to be attached on the under surface of the pelvic bone; externally, the external ligament of the femur; anteriorly, *a*, *m*, the anterior muscle of the femur, from the aponeurosis in front, and, continuous with that muscle internally, is seen the tensor fasciæ muscle, *t*, *f*, with its multi-penniform structure, passing from near the end of the pelvic bone backwards to end in the superficial interpelvic membrane, now dissected off. On the *right side* are seen, besides the posterior muscle and external ligament of the femur, the internal muscle of the femur, placed deeply on the pelvic bone and largely fibrous in its structure; a portion of it is seen to pass out behind the femur to be re-attached to the pelvic bone behind the external ligament of the femur, and a larger portion is seen in front of the femur, attached to the anterior fibrous bands of the femur. External to the promontory of the pelvic bone is seen the edge of a fibrous inter-muscular septum, *s*, *s*, the semicircular septum. Seen attached to this septum are, posteriorly, a large portion of the posterior muscular mass; anteriorly, portions of the anterior muscular mass; the septum is seen to give two fibrous bands to the femur, the anterior bands of the femur, and to extend inwards to be attached to the beak of the pelvic bone. It is seen also to be continuous anteriorly with a septum between a superficial lateral muscle, *l*, *m*, and the more internal part of the anterior muscular mass. On the *left side*, the deep fibrous layer, *f*, *l*, of which the latter septum is the edge, is shown by removing the greater part of the lateral longitudinal muscle. The triangular portion of aponeurosis, *a*, *p*, in front of the tensor fasciæ muscle, is a portion of the superficial aponeurosis left on to show the origin from it of the anterior muscle of the femur and the outer part of the tensor fasciæ muscle. The semicircular septum is part of the great fibrous plate that separates the anterior and posterior muscular masses into upper and under strata, here showing itself.

Plate XIX. fig. 3. Deeper view of the pelvic region. Pelvic bone, *P*; *pr*. *b*, pre-pelvic band; *i*, *l*, great interpelvic ligament; *t*, *l*, triangular ligament; *b*, bulb of the corpus spongiosum urethræ, the oval mark shows where the urethra perforates the triangular ligament; *c*, inner thick-walled part of the crus penis not covered by the ischio-cavernosus muscle; *c'*, upper compressible part of the crus to which the muscle is attached; between *c* and *c'*, the fibrous ridge on the crus bounding the muscles; *i*, *c*, ischio-cavernosus muscle. On the *right side*, *p*, *m*, *m*, parts of the posterior muscular mass, attached to the great inter-pelvic ligament and to the outer border of the pelvic bone; in front of the latter attachment are seen, divided, the part of the posterior muscular mass inserted on the under surface of the pelvic bone, the part of the mass that forms the posterior muscle of the femur, and in front of these the internal muscle of the femur.

External to the femur, *f*, is seen its external ligament, and immediately behind this, the re-insertion of a portion of the internal muscle of the femur; *a*, *m*, *m*, tendon of part of the anterior muscular mass, attached to beak of pelvic bone, near promontory. Internal to this a larger portion of the anterior muscular mass. On the *left side*, *P*, the pelvic bone; *F*, the femur; *i*, *m*, the internal muscle of the femur, mixed with fibrous tissue; *p*, *m*, posterior muscle to the femur from the posterior muscular mass, attached to the internal elevation on the posterior border of the femur; partly concealed by the latter, the posterior ligament of the femur; external to the femur, its external ligament.

Figs. 4 and 5, the right and left pelvic bones, in their natural position and at the natural distance from each other, with the femur in its natural position, seen on their under aspect; *P*, the pelvic bone. The cartilages are indicated by the dotted areæ; *a*, *c*, the anterior cartilage, overlapping the bone for $\frac{1}{4}$ inch on the surfaces, more at the borders; *p*, *c*, the posterior cartilage; *p*, *y*, the promontory of the pelvic bone; *a c*, *c*, the dotted area, shows the position of the acetabular cartilage, the ovoid posterior portion the thicker part, the anterior portion reaching forwards on the under aspect of the promontory. The cartilaginous femur, *F*, shown in section on the right side, enclosed in its perichondrium; a short fibrous tuft is seen at the inner end of the femur. Fig, 5, *left side*, in addition, the ligaments of the femur, *e*, *l*, the external ligament, the strongest; *p*, *l*, the posterior ligament, attached to the external elevation on the posterior border of the femur. *Differences on the two sides* are shown; the left femur mostly in front of the pelvic bone, the right femur mostly upon (below) the pelvic bone; the promontory of the pelvic bone broader and less rounded on the right side than on the left.

Plate XX. figs. 6 to 12, series of views of the different form and size of the pelvic bone and femur (when present) in fin-whales and in the Greenland Right-whale, all reduced to $\frac{1}{6}$ the natural size. The cartilages are indicated by the dotted parts. Each is referred to more fully in part III., (*B*) and (*C*), of the text. All are from males except fig. 6.

Fig. 6. Pelvic bone of a young 14½-feet-long lesser Fin-whale, *Balænoptera rostrata*.

Fig. 7. Pelvic bones of a 36-feet-long Black-whale, *Balænoptera borealis*. Differences between the right and left are seen.

Fig. 8. Pelvic bone and femur, and ligaments of the femur, of the 50-feet-long Razorback whale, *Balænoptera musculus*, described in the text and seen in the previous figures. Cartilaginous femur, *F*; *e*, *l*, and *p*, *l*, external and posterior ligaments of the femur; *a c*, *c*, acetabular cartilage.

Fig. 9. Pelvic bone and femur of a 64-feet-long *Balænoptera musculus*. The femur is ossified in its outer, or here posterior, $\frac{3}{4}$; *e*, *p*, *l*, the external and posterior ligaments united before they reach the femur; *f*, *b*, fibrous band attached to anterior end of femur.

Fig. 10. Pelvic bone and femur, and ligaments of the femur, of a

40 feet-long Humpback whale, *Megaptera longimana*. *F*, femur; *f*, *b*, fibrous band continued from the anterior end of the femur; *p*, *l*, posterior ligament of the femur, the internal division, containing a muscle; *e*, *l*, external ligament of the femur in two parts. The great length of the posterior and anterior cartilages of the pelvic bone is seen. No acetabular cartilage present. The three lines crossing the femur indicate the outline of the pelvic bone, and the commencement of the anterior cartilage.

Fig. 11. Pelvic bone, ossified femur and its ligaments, and cartilaginous tibia, of a 35-feet-long (probably about $\frac{2}{3}$ grown) Greenland Right-whale, *Balæna mysticetus*. *P*, pelvic bone; *F*, femur; *T*, tibia; *a c*, *c*, anterior part of the acetabular cartilage; *a*, *l*, and *p*, *l*, anterior and posterior ligaments of the hip joint; *g*, *p*, *l*, great posterior ligament of the femur; *a*, *l*, *l*, two anterior ligaments of the body of the femur; *f*, *b*, fibrous bands attached to end of pelvic bone and to end of tibia; *c*, *l*, capsular ligament of the knee joint. The four lines crossing the femur indicate the outline of the pelvic bone, the commencement of the anterior cartilage, and the outline of the posterior part of the acetabular cartilage.

Fig. 12. Pelvic bone, *P*, ossified femur, *F*, and cartilaginous tibia, *T*, of 48-feet-long (adult) *Balæna mysticetus*. Cartilages and ligaments of the pelvic bone and femur not represented. Head of femur lodged in a deep acetabulum, overhung by a rough reverted ledge of the promontory. Process on posterior border of femur for attachment of great posterior ligament. Characteristic distal end of femur, anterior $\frac{1}{3}$ bevelled for muscular attachment, posterior $\frac{2}{3}$ adapted for articulation with tibia at knee joint, the whole end rough where it had been covered by the distal cartilage of the bone. The tibia (always cartilaginous) of characteristic form.

EDINBURGH, *March*, 1893.

COMPARATIVE OSTEOLOGICAL NOTES ON THE EXTINCT BIRD ICHTHYORNIS. By Dr R. W. SHUFELDT.

TWELVE years ago, when Marsh published his *Odontornithes*, and described therein the various species of the fossil genus of birds called by him *Ichthyornis*,[1] it would appear from the descriptions that the skeletons of *Ichthyornis victor* and *I. dispar* and others of the group, in so far as existing birds are concerned, were, among the *Longipennes*, only osteologically compared with *Sterna regia*. It has always been the opinion of the writer of the present article that it was unfortunate for science that Professor Marsh did not make far more comparisons of his fossil birds with the skeletons of existing forms than he appears to have done, judging from the monograph just cited. Had he done so, I am confident, and other comparative osteologists are of the same opinion, he never would have suspected *Hesperornis* of having been "essentially a carnivorous, swimming ostrich,"[2] nor have stopped short with "a Tern" wherewith to compare *Ichthyornis*. So far as I am at present aware, Professor Marsh has never extended those comparisons, at least we have never seen any published account of his having done so.[3] But avian anatomy is coming on apace, and some of its objects in the future will be to clear up such questions, and by more extended researches, of a comparative nature, solve many problems now more or less obscure. While such advances are being made, avian anatomists are quite content to rest under the not very weighty cloud of entertaining "unique views" and other heresies,[4] so long as truth at last prevails.

[1] Marsh, O. C., *Odontornithes*, a Monograph on the Extinct Toothed Birds of North America. Washington, 1880 (Government.)

[2] *Ibid.*, p. 114.

[3] Shufeldt, R. W., "Concerning the Taxonomy of the North American Pygopodes, based upon their Osteology," *Jour. of Anat. and Phys.*, vol. xxvi. Lond., Jan. 1892. See the writer's remarks upon page 202.

[4] As a good example of the reluctancy on the part of some systematic ornithologists to adopt the result attained to by comparative anatomists, see the friendly controversy carried on by Ridgway and Shufeldt in *The Popular Science News* of

This will come about the sooner in some directions when the government collection of fossil birds, long ago described, and now in the custody of the author of the *Odontornithes*, are placed in a government museum and accessible to students of such subjects.[1] Without enumerating any of the many instances in ornithology where the developments of comparative anatomy of birds have corrected the views of those who have trusted alone to the characters presented on the part of external structures, I would like in the present article to say something about the Skimmers of the genus *Rhynchops*. One of the two species of this genus, viz., *R. nigra* is represented in the avifauna of the United States, and through the courtesy of the United States National Museum I have had the opportunity of examining the skeleton of a specimen of that bird.[2] Most ornithologists have said that the Skimmer is nothing more than a slightly modified Tern; but ever since I have paid any attention to the structure of that type I have contended that the gap between *Rhynchops* and the other *Longipennes* of the suborder is considerably greater than those ornithologists are disposed to believe. For example, Newton has said, "Some authors make a family of the genus *Rhynchops*, but it seems needless to remove it from the *Laridæ* (Gulls). In breeding-habits the Skimmers thoroughly agree with the Terns, the largest species of which group they nearly equal in size, and indeed only seem to differ from them in the mode of taking food, which of course is correlated with the extraordinary formation of their bill."[3]

Coues considers them only in the light of a subfamily—*Rhynchopinæ*,—and says, excepting a few structural characters,

Boston, on the Systematic Position of the Swifts and Humming Birds. Sept., Nov. 1892, and probably following issues.

[1] Osborn, Henry Fairfield, "A Reply to Professor O. C. Marsh's 'Note on Mesozoic Mammalia,'" a paper read before the Geol. Sec. A.A.A.S., Washington, D.C., Aug. 21, 1891, pub. in *Amer. Nat.*, Sept. 1891, see p. 775. "Without question, these and all other U.S. Geological Survey types, now that they have been described and figured by the author, should be placed in the National Museum, where they could be studied under the ordinary Museum restrictions."

[2] *Rhynchops nigra*. Coll. U.S. Nat. Mus., No. 19103.

[3] Newton, Alfred, art. "Skimmer," *Ency. Brit.*, 9th ed., vol. xxii. p. 120. This writer believes that the peculiar structure of the bill is the *only* anatomical difference between *Rhynchops* and the Terns.

"their general economy is the same as that of Terns."[1] The American Ornithologists' Union, however, place the Skimmers in a separate family—the *Rhynchopidæ*, a place they most surely deserve if we intend to show that they are well separated from the *Laridæ*, as their skeletons indicate.[2] I say their skeletons because unfortunately I have not yet had the opportunity of examining any of the other systems, except the osseous system in one of those birds. Sometime in the future it may be my good fortune to do this. Other ornithotomists of recent time are in the same case, and it would appear that neither Garrod nor Forbes, ever paid any attention to the "soft parts" of the *Rhynchopidæ*.[3] Fürbringer, who from the enormous extent of his work upon the taxonomy of the class, had frequently to rely upon the opinion of others, did so apparently in the case of *Rhynchops*. By him the Skimmers are not even raised to subfamily rank.[4] Such facts as these were passing through my mind recently as I compared my skeleton of *Rhynchops nigra* with the skeleton of several species of Terns, and Gulls, and Auks, and other birds. It struck me as remarkable that there should be no difference in the *form* of the bills as they occur in nestling Terns and in the nestlings of that species of Skimmer known as *R. albicollis*;[5] the peculiar form of the bill which the latter has when adult is only developed as the bird matures. I was led to extend my comparisons by comparing the bones of the skeleton of the Skimmer with the corresponding ones of the two species of *Ichthyornis* figured by Marsh in the *Odontornithes*, already cited above. But first as to the Gulls and Terns—I found that structurally the former

[1] Coues, E., "Key to North American Birds," rev. ed. 1884, p. 772. Here, however, we find a few important habits enumerated distinguishing the Skimmers and the Terns, and of the first this ornithologist says they are "somewhat nocturnal;" they "fly in close flocks," and their "voice is very hoarse," &c.

[2] The A.O.U. Code and Check List of North American Birds. New York, 1886, p. 96.

[3] Garrod, A. H., *Collected Scientific Papers*. London, 1881. On p. 127, he simply points out that *Rhynchops* is a "schizorhinal bird."

Forbes, W. A., *Collected Scientific Papers*. London, 1885. This author never appears to have examined the morphology of the *Rhynchopidæ* at all.

[4] Fürbringer, Max., "Untersuchungen zur Morphologie und Systematik der Vögel," 1888. P. 1160.

[5] Anderson, A., "Remarks on exhibition of young examples of *Rhynchops albicollis* and *Sterna aurantia*," *P.Z.S.*, Dec. 4, 1877, p. 807.

approach the latter at several points, and Coues has truly stated that "such subgenera as *Xema* and *Creagrus* among *Larinæ* change the Larine very gradually to the Sternine form, meeting on the confines of the latter subfamily, such a subgenus as the thick-billed, short-tailed *Gelochelidon*, to render the transition still less abrupt."[1]

Xema sabini has not a little in its skeleton to remind us of the skeleton in the Terns, but still there are also numerous distinct osteological differences, and these can be easily pointed out by comparing its skeleton with the skeleton of a specimen of *Sterna macrura* (*S. paradisæa* of the A.O.U. List—the Arctic Tern). These differences may with advantage be arranged in the form of a synoptical table, thus:—

XEMA SABINI.	STERNA MACRURA.
1. Osseous mandibles showing a curved culmen and symphysis rami as the anterior apex is approached and met.	1. Osseous mandibles very gradually approach the apex, they being drawn out more acutely than in the Gull.
2. Interorbital septum and anterior cranial wall showing deficiencies or vacuities.	2. Those vacuities are far more extensive.
3. Inturned processes at the articular extremities of mandible barely touch the paroccipital projections at the base of the cranium.	3. These processes articulate, though not extensively, with the paroccipital processes (this condition is carried to the extreme in *Rhynchops*).
4. Narial apertures at the sides of the superior mandible extend ⅔ the distance forwards towards the apex of the latter.	4. Narial apertures at the sides of the superior mandible extend only ½ the distance forwards towards the apex of latter.
5. *Os uncinatum* exceedingly small (may not ossify in some individuals?)	5. *Os uncinatum* 3 millimetres or more long in this species.[2]
6. Hæmapophyses of last pair of ribs reach the sternum, to articulate therewith.	6. Hæmapophyses of penultimate pair of ribs fail to reach the sternum; and the last pair are rudimentary and without costal ribs.
7. Pelvis inclined to be narrow and long.	7. Pelvis inclined to be broad and short.
8. Notches in xiphoidal extremity of sternum are of good size.	8. Notches in xiphoidal extremity of sternum small.

[1] Coues, E., *Birds of the North-West.* Washington, 1874, p. 592 (Government).

[2] It is really remarkable how much alike the skulls of these two genera are, belonging as they do to different subfamilies. In some Terns the supra-orbital glandular depressions on the superior aspect of the cranium may not meet in the median line, as they do in *Xema* and *Sterna macrura*. An example of this is seen in a skeleton of a Tern marked *S. arctica*, belonging to the United States National Museum. In it there is an interval of a couple of millimetres, but I am inclined to believe this character varies a good deal.

Differences to be found in the shoulder-girdles, and the limb-bones of the skeleton of these two birds are quite insignificant, and hardly worth the mention.

The differential characters as seen in the ribs are by no means to be relied upon, and they may vary for the two sides of the same individual. The specimen of the skeleton of *S. macrura* before me, for instance, has *seven* costal ribs articulating with the sternum upon the right side, and only *six* upon the left.

As in *Larus glaucus* I find the vertebral column composed of 41 vertebræ plus a pygostyle, and I am inclined to believe that this is the rule for all the typical species of the family *Laridæ*. When I say this I am aware that Coues found 42 in both *Stercorarius pomatorhinus* and *Larus argentatus*, and but 41 in a skeleton of *Sterna hirundo;* and the reckonings of Owen as well as of Eyton are still wider of the true mark (*Birds of the North-West*, pp. 595, 596). The count really is 15 cervicals (the last two bearing free ribs); 6 dorsals; 12 sacrals; and 8 caudals; and a pygostyle. If this latter be counted as a single caudal vertebra, then the chain consists of 42, as stated by Coues, who may have done this in his reckoning.

At this point we are now prepared to make a comparison with one of the Ichthyornine types, and we find that Marsh compared, in this particular, *Ichthyornis dispar* with *Sterna cantiaca* (Gmelin). He found 21 presacral vertebræ (cervico-dorsal series), the same number now existing in the representatives of the modern family *Laridæ*. He adds, however, that the "sacrum of *Ichthyornis* differs from that of the Tern in having only 10 vertebræ in the coössified sacral series, while there are 13 in *Sterna regia*." Coues found only 11 in *Sterna hirundo*, and I count 12 in all the Terns I have examined.[1] Marsh further says, "The tail in *Ichthyornis* is notable mainly for being of the modern ornithic type, thus widely differing from that of both *Archæopteryx* and *Hesperornis*, the only other two Mesozoic birds in which this organ is preserved. The tail in the genus *Ichthyornis* was comparatively short, and the terminal vertebræ were coössified."

"A series of 7 caudal vertebræ are preserved in one

[1] Coues, E., *loc. cit.* p. 595. Marsh, O. C., *Odontornithes*, p. 162.

specimen of *Ichthyornis victor*. They pertain to the median and distal part of the tail, although not including the extreme end, a portion of the *pygostyle*, or the part formed by the united centra of the terminal vertebræ, being lost." Taking this as it stands, it would give *Ichthyornis* but 38 vertebræ in its spinal column, plus a pygostyle. From this we may judge that 3 vertebræ of *I. victor* were not found, and although Marsh says that they "pertain to the median and distal part of the tail," they may nevertheless have been urosacrals, which were *free* in that fossil form, and in which case it may have had a number in its vertebral chain co-equal with existing larine types. Or, what is more likely, only one caudal vertebra was missing, and Marsh made a miscount of the number included in the coössified sacrum of *Ichthyornis victor*, for upon examining his figure of the pelvis of that ancient bird (*Odontornithes*, pl. xxxiii. fig. 3) and comparing it with the same view of a pelvis of a Tern, *Sterna macrura*, it would appear to possess 12 sacral vertebræ, or a number equal to those in the sacrum of a Tern. I am inclined to this latter view.

Let us now retrace, as it were, the line of our comparisons, and introduce here some of the characters of the Ichthyornine skull, and Marsh observed that "In *Ichthyornis dispar*, the type of the genus *Ichthyornis*, and of the order ODONTOTORMÆ," we find, and continuing the quotation from this point and synoptically comparing the data with *Rhynchops* and a Tern, that in,—

ICHTHYORNIS DISPAR.	RHYNCHOPS NIGRA.	STERNA MACRURA.
1. The skull was very large in proportion to the rest of the skeleton.[1]	1. The skull as large in proportion to the rest of the skeleton, as it is in *Ichthyornis dispar*.	1. The skull not especially large in proportion to the rest of the skeleton.
2. The cranial portion of the skull is quite short, but the facial part is much produced.	2. Cranium comparatively short, with the facial part produced.	2. The facial but slightly exceeding the cranial portion of the skull.
3. Above the condyle, the occipital portion of the skull was nearly vertical. The lateral margin of this	3. Above the condyle, the occipital area is nearly vertical. The lateral margin of this surface is bounded by	3. Above the condyle, the occipital area looks downwards and slightly backwards. The lateral margins of

[1] *Odontornithes*, p. 120, *et. seq.*

ICHTHYORNIS DISPAR.—*Continued.*	RHYNCHOPS NIGRA.—*Continued.*	STERNA MACRURA.—*Continued.*
surface is bounded by a sharp ridge which separates it from the temporal fossa, and this united with its fellow above was continued forward on the median line, as a sagittal crest, between the temporal fossæ. The latter were large and deep, and were separated from the orbit by a moderate post-orbital process.	a pronounced ridge separating it from the temporal fossa; and this nearly uniting with the opposite one, forms a low, median, sagittal crest, separating the large and deep temporal fossæ. Post-orbital processes of good size.	this surface being bounded by a faint elevation separating it from the temporal fossa. The temporal fossæ are shallow, and a sagittal crest not developed. Post-orbital processes small and insignificant.
4. Deep glandular depressions along the roof of the orbits, similar to those on the cranium of *Hesperornis*, and some recent water birds.	4. Super-occipital glandular depressions deep, and wide apart.	4. Super-occipital glandular depressions shallow, and divided only by a median line.
5. Sacrum projected beyond the ilia, posteriorly (*Odontornithes*, Pl. xxii.).	5. Sacrum of pelvis projects to the extent of nearly two vertebræ beyond the ilia, posteriorly.	5. Sacrum does not project beyond the iliac bones posteriorly.
6. Femur more than half the length of the humerus.	6. Femur less than half the length of the humerus.	6. Femur still less than half the length of the humerus as compared with *Rhynchops*.

Had I the fossil material of *Ichthyornis dispar*, described by Marsh, no doubt I could find other points for comparison, but that privilege is denied me. In so far as his figures go in the *Odontornithes*, nothing would be gained by contrasting the skeletons farther, as the skeletal characters in the fossil form depart too widely from the two existing types. For instance, the *humerus* of *I. dispar* approached the *Pterydoctyls* in character, and its coracoids decussated in the coracoidal grooves upon the sternum.

In some minor characters *Ichthyornis* seemed to come nearer the Gulls than it did the Terns, while upon the whole, as my comparisons given above go to show, it possessed more in common with our now-existing *Rhychopidæ* than with the *Sterninæ*. This is most apparent in the cranium; in the large skull compared with the rest of the skeleton; and in certain characters in the vertebral chain and pelvis.

A NOTE ON THE ANATOMY OF THE HYMEN AND ON THAT OF THE "POSTERIOR COMMISSURE OF THE VULVA." By CHARLES J. CULLINGWORTH, M.D., F.R.C.P., *Obstetric Physician to St Thomas's Hospital, London.*

1. *Note on the Anatomy of the Hymen.*

THE hymen is stated in the text-books to present, in the adult virgin, several varieties of form, of which the crescentic is the most common, other not unusual varieties being the annular and the cribriform. The aperture is usually described and figured as being either circular or oblong, and its edges are said to lie apart.

The object of this paper is to point out that these descriptions convey an erroneous impression, being based on the appearance presented by the parts when held asunder, and not as they are when allowed to retain their natural position and relations.

For many years it has been my custom to make vaginal examinations with the patient lying in the dorsal position, with the knees flexed and widely separated, and before a good light. In this position a full view of the vulva is obtained, and I have thus been enabled to observe, and to demonstrate to my class, the natural position and relations of the external genital organs as they are seen in the living subject, and before the parts have been in any way disturbed. The position and relations of the structures so displayed vary, of course, according to whether the patient under examination is or is not a virgin, and in the latter case according to whether she has or has not borne children. I propose to limit myself here to the conditions met with in the adult virgin. Normally, the hymen in the adult virgin is completely concealed from view by the labia minora, which close over it, with their internal surfaces in apposition, and their edges (supposing the subject to be in the dorsal position) directed forwards. On separating the labia

minora in such a manner as not to disturb the structures lying in the plane behind them, another pair of closed lips is exposed to view. These lips are formed by the free border of the hymen, and close the orifice of the vagina. No actual opening is seen either into the vagina or the urethra. The orifices of both the urethra and the vagina are vertical slits, bordered by lips, the inner surfaces of which are in close apposition, and the edges of which are, like those of the labia minora, directed forwards. The lips of the hymen are pale, moist, and thin, their free borders being sometimes straight and even, but often irregularly denticulate or notched. Their upper extremities meet in a little fold, the apex of which is prolonged, so as to reach and partially conceal the lower extremity of the orifice of the urethra, and constitute the so-called fleshy caruncle, often recommended as a landmark for discovering the meatus urinarius when passing a catheter.

If an elliptical or slit-like opening, like that of the hymen, be dilated by a more or less cylindrical body, the obvious result will be to separate its sides and to widen, or even obliterate, the angle at each end. In the case of the hymen, such dilatation may take place either from without (by sexual intercourse, digital examination, or the introduction of pessaries or specula) or from within (by the passage of the child during parturition, or by the extrusion of a congenitally elongated cervix, or a partially prolapsed uterus). Except in the healthy virgin, therefore, the apex of the folded hymen is seldom recognisable as a distinct prominence, and this is the reason why, when wanted as a landmark, it so often cannot be found. It has disappeared in consequence of the alterations that repeated dilatation has produced in the hymen. Hence, I entirely agree with Dr Coe ("Amer. Syst. of Gynecology and Obstetrics," *Gynecology*, vol. i., Edin., 1887, p. 115) in his opinion that "in passing a catheter by the sense of touch the physician will do well to disregard the rule laid down in most of the text-books on obstetrics, and, instead of searching the vestibular area for a guide to the meatus, to look for it at once in the median line immediately above the vaginal outlet."

A much better rule than the one commonly given is to introduce the forefinger into the vagina, with its palmar surface

against the anterior wall, in the substance of which the urethra is embedded, and can easily be felt. This method has other advantages besides that of being universally applicable. It ensures that the catheter does not enter the vaginal orifice by mistake for the urethra, and it enables the instrument to be felt and directed by the finger as it passes along the urethral canal.

The inferior extremities of the lips of the hymen are continued into a somewhat longer fold, consisting of the lower part of the hymen (which is considerably broader, from its free to its attached border, than the upper part) folded together, with the edge of the fold forwards. The whole hymen, then, may be described as a long fold of mucous membrane with its edge directed forwards, and divided, along about three-fourths of its length, by a slit, which extends nearer to its upper than its lower extremity. The slit constitutes the orifice of the vagina.

If the lips of the hymen be separated, the appearances usually described will be seen, viz., a fold of mucous membrane surrounding the vaginal orifice, broader below than above, and with its free edge more or less everted. It is often stated that the hymen is occasionally absent. I have had occasion during the last twenty years to examine a very considerable number of women, and I have never yet seen a woman in whom the hymen could not be found, or even one in whom it was not easily demonstrable. In fact, it is quite exceptional to meet with a case presenting any marked departure from the type I have just attempted to describe. Occasionally, there are lateral notches of such a depth that the lips of the hymen close in a more or less cruciform manner, and now and then I have seen the lips meet altogether transversely instead of vertically. A cribriform hymen is a curiosity I have yet to see, and, until I do see it, or discover some one who has seen it, and upon whose accuracy of observation I can rely, I shall feel myself justified in regarding its existence as problematical.

Of the changes that are produced in the hymen by abnormalities—such as persistence of the vaginal septum, and congenital elongation of the cervix; by pathological conditions, such as prolapse of the pelvic floor (which occasionally occurs even in the virgin); by sexual intercourse and by parturition—

it is no part of my present purpose to speak. I should like, however, to call attention to a paper published in the *Path. Trans.* for 1890 by my colleague, Mr Shattock, the Curator of the St Thomas's Hospital Museum. "If," says Mr Shattock, "the termination of the vagina is examined in a fœtus of the earlier months by separating the labia," it is seen to project "forwards into the cleft between the labia as two apposed longitudinal lips." He proceeds to show from actual preparations that the male also possesses a hymen. Leuckart pointed out in 1852 that the vesicula prostatica represents not only the uterus but the vagina of the female, and it occurred to Mr Shattock that, this being the case, an analogue of the hymen would be found in the adult male at the spot where the prostatic vesicle opens into the urethra. He accordingly made dissections, and found that the termination of the male vesicula, as viewed on opening the prostatic urethra through its anterior wall, consists of two projecting apposed longitudinal lips, forming a miniature hymen. It is, in fact, this male hymen that constitutes the eminence of the verumontanum. I merely mention this homology as an extremely interesting scientific fact. The point to which I wish particularly to call attention is that the form of the adult hymen, as I have described it, is precisely the same as that of the fœtal hymen, viz., an elliptical slit, with apposed longitudinal lips.[1]

2. *Note on the Anatomy of the "Posterior Commissure of the Vulva."*

With regard to the "posterior commissure of the vulva," I have only one or two remarks to make. In the first place, extensive clinical observation enables me to corroborate the statement of Luschka, that it is the posterior junction of the *labia minora*, and not that of the *labia majora*, that constitutes this commissure. The *labia minora* are in some women

[1] Even careful writers speak of the vaginal orifice as transverse. The vagina itself is transverse—that is, its apposed walls are anterior and posterior, not lateral. But the entrance to the vagina is a vertical slit, and is at right angles to the vagina itself. The orifice of the vulva and that of the vagina are thus alike in their direction, both being bounded by lips that meet along the middle line.

deeply pigmented. It is in such women that the correctness of Luschka's observation can be most easily demonstrated, for the pigmentation is continued across the anterior boundary of the perineum. But, apart from this, if any one will take the trouble, in an adult virgin, to draw the *labia minora* gently upwards, taking one between each thumb and forefinger, he will find that they pull on the fourchette and draw it upwards too, and he will see that the structures are in all respects similar and continuous. No such effect is produced on the fourchette by upward traction on the *labia majora*, and I am not aware of the existence of any evidence in favour of the still too common statement that the posterior commissure of the vulva is constituted by the *labia majora*.

There is one other point which I wish to mention, viz., the situation of the orifice of the duct of the vulvo-vaginal, or Bartholin's gland. It is frequently stated that it is situated in the *fossa navicularis*. This is not the case. The *fossa navicularis* is the part intervening between the fourchette and the posterior part of the hymen; whereas the ducts open, not behind the vaginal orifice, but by the side of it, and nearer its anterior than its posterior extremity. In other words, they open on the inner aspect of the *labia minora*, close to the groove between the *labia minora* and the hymen.

ON THE MYOLOGY OF THE ANENCEPHALOUS FŒTUS.

By BERTRAM C. A. WINDLE, M.A., M.D., D.Sc., *Professor of Anatomy in Mason College, Birmingham.*

THANKS to the investigations of Abraham and others whose names are mentioned in the short bibliography appended to this paper, it is well known that the sternalis muscle occurs frequently in the type of monster dealt with in this communication,—more frequently, as my figures show, than in normal subjects. I have for some time wished to ascertain whether other abnormalities of the muscular system occurred in these cases with greater frequency than in ordinary subjects; and if so, what was the nature of the deviation from the usual type. Having accumulated a supply of anencephalous fœtuses, I have, with the assistance of my pupils Messrs J. Ganner, R. A. Bennett, and J. C. Griffiths, to whom my best thanks are due for their help, made an examination of the musculature of ten cases, notes of which are appended. I should here state that the examination has been confined to the muscles of the limbs and their girdles, since the shortening of the neck, together with the constantly accompanying Spina Bifida, have rendered any accurate dissection of the muscles of the neck and trunk impossible.

No. 1. Female. Cleft palate, not alveolar. A sternalis muscle is present on the left side, which involves the whole depth of the central fibres of that part of the pectoralis major which arises from the sternum and ribs. These fibres being rotated upwards, a gap is left in the muscle, through which the subjacent pectoralis minor can be seen. The left upper extremity presents the following abnormalities: (1) Palmaris longus is double. (2) A small muscular slip arises from the inner condyle of the humerus, and passes to be inserted into the outermost part of the flexor profundus digitorum. (3) There are two special extensors of the index, besides the slip from the common extensor. The last-mentioned abnormality occurs also on the right side. On both sides there is a detached muscle lying in front of psoas magnus, and occupying the position of the psoas parvus, which it probably represents. This muscle is inserted into the lesser trochanter of the femur. The straight

head of the rectus femoris is absent on the left side. The extensor proprius hallucis of the left side supplies an extensor primi internodii hallucis.

No. 2. Male. No sternalis muscle is present. In the right upper extremity there is a muscular slip arising with the supinator longus from above the external condyle, which joins the supinator brevis. The flexor sublimis digitorum on the same side sends no tendon to the little finger, there being thus only three tendons to this muscle. Psoas magnus is divided into two portions, one being external to the other and smaller. Both are inserted together. Plantaris is absent on one side.

No. 3. Female. No sternalis muscle is present. In the left upper extremity there is a muscular slip arising from the internal condyle of the humerus, which joins the outer part of the flexor profundus digitorum. There is a similarly arising slip on the right side, which passes down the fore-arm, sends an independent tendon under the annular ligament, and joins that tendon of the flexor profundus which is destined for the index finger.

No. 4. Female. No sternalis muscle is present. The platysma is unusually well developed, and extends for some distance over the surface of the thorax. In the right upper extremity there are two special extensors to the little finger, and an extensor medii digiti, as well as the normal tendons from the common extensor. In the left upper extremity there is a second extensor secundi internodii pollicis arising with the extensor indicis. The plantaris of the right side is absent.

No. 5. Male. There is a sternalis muscle on the left side which does not involve the entire depth of the pectoralis major muscle, but lies superficial to its remaining fibres. On both sides a muscular slip arises by a tendon from the outer side of the short head of the biceps, and is inserted into the humerus by the side of the coraco-brachialis. On the right side there is a condylar head to the flexor longus pollicis. On the same side the fleshy fibres of the triceps are continuous with those of anconeus, the extensor carpi radialis longior is inserted by two distinct tendons, and there is no palmaris longus. The extensor proprius hallucis on one side is inserted by two tendons.

No. 6. Female. There are two remarkably developed sternales which arise from the aponeurosis of the external

oblique muscles. Passing upwards, they unite to form a flat tendon which overlies the manubrium sterni. With the upper and outer angles of this tendon the tendons of the sterno-mastoid muscles are continuous. These muscles are also particularly strong, and the continuity which they have with the sternales is easily demonstrated by pulling upon their tendons. The sternales present some differences upon the two sides. That of the right side passes over the pectoralis major, which is otherwise normal in appearance and connections. On the left side, however, the entire of the fibres of the pectoralis major which are normally its lowest are rotated, and thus a gap is left through which the pectoralis minor can be seen. Moreover, there is on this side an additional portion of the pectoralis major which arise from the false ribs, and from the aponeurosis of the external oblique muscle. This is inserted into the humerus with the deeper part of the pectoralis major. Finally, in this region there are distinct muscular fibres in the fascia overlying the external oblique, which resemble a panniculus carnosus.

In the right upper extremity there is an axillary sling, arising from the latissimus dorsi, and inserted by two tendons with the pectoralis major. In the left lower extremity the peroneus tertius forms the greater part of the muscular belly of extensor longus digitorum. In the right lower extremity, tensor vaginæ femoris is unusually large, extending half way down the thigh. The accessorius is unconnected with the flexor longus digitorum, but sends tendons of its own to the second and third toes.

No. 7. Male. There is no sternalis muscle present. On both sides, but more markedly on the right, there is a separate portion of the pectoralis major arising from the false ribs and aponeurosis over the external oblique muscles, which, passing upwards more in the long axis of the body than the remaining portions of the muscle, is inserted with its deeper fibres. Palmaris longus is absent on the left side.

No. 8. Male. There is no sternalis muscle present. Palmaris longus is absent on both sides. There is an extensor medii digiti on the right side. On the left side, a muscle occupying in the abdomen the position of psoas parvus, is inserted into the lesser trochanter as in No. 1.

No. 9. Male. There is no sternalis muscle present. In the

right upper extremity, the fleshy fibres of triceps are continuous with those of anconeus. In the left upper there is a condylar head for flexor longus pollicis. Peroneus tertius has an unusually large muscular portion.

No. 10. Female. There is a well-marked sternalis on the left side, which does not involve the deeper fibres of the pectoralis major.

The anterior belly of the omo-hyoid on the left side is represented by a band of fibrous tissue destitute of muscular fibres.

I now proceed to give a few notes respecting some of these abnormalities. The muscular slip from the biceps (No. 5) is the slip from that muscle to the internal intermuscular septum described by Quain and Macalister (Catalogue, p. 83). The connection between the triceps and anconeus has been described by Harrison and Macalister (p. 79).

The additional slip to the supinator brevis (No. 2) is the epicondylar head of Sandyfort, also described by Halbertsma and Testut (p. 516). It is present in various mammals, and the last-named author found it particularly well represented in *Troglodytes niger*. Palmaris longus was double in one fore-arm, absent in five. This gives a proportion of absence to presence of one to four, which is greater than that observed in normal subjects according to Macalister (1 in 10).

I have dealt with the subject of the accessory heads of flexores longus pollicis et profundus digitorum elsewhere, and suggested the name of Condylo-radialis for the former (the accessorius ad pollicem of Gantzner), and those of Centralis and Condylo-ulnaris for the latter, the former of the two last-mentioned slips joining the outer, and the latter the inner, edges of flexor profundus digitorum. In the paper alluded to, I gave in a table the range of these additional slips amongst the Mammalia. Adopting this terminology for the present, it will be seen that Condylo-radialis was present in the fœtuses examined in two fore-arms, and Centralis in three, two of these being on the same body. The abnormality connected with flexor sublimis digitorum (No. 2) has been observed by Wood, Macalister (p. 89), and others. According to Testut, when the tendon to the minimus is absent, its place is taken by a short palmar muscle, but none such was observed in this instance.

The anomalies of the extensor muscles of the hand and foot are fairly common, and call for no special notice.

The abnormal insertion of psoas parvus (1 and 8) has been described by Le Double.

It remains to speak of the abnormalities of the pectoral region. The Chondro-epitrochlearis (Wood) or Abdomino-humeralis (Zenker) is well known, as is also the axillary sling. I have discussed their relationship to the pectoral group of muscles in another paper, and need not delay further over them here. As regards the sternalis muscle also in these forms much has been written, and I shall therefore content myself by briefly alluding to a few points in connection with it.

In the first place, it may be noted that the kind of sternalis is different in many cases of anencephalus from that which has been observed in ordinary subjects. This difference consists in the fact that the entire depth of the fibres of the pectoralis major is affected, a condition which I do not think has been described in any ordinary dissecting-room subject. I have collected records of twenty-two cases where this muscle has been observed in anencephalous fœtuses. In twelve of these the entire depth of the pectoral was affected, whilst in ten the abnormal muscle lay superficial to the normal. So far as these figures go, they show that a greater number of the unusual form of sternalis muscle is met with in these monsters than of the usual. In the second place, there are now a number of statistics from which a comparison may be instituted as to the relative frequency of occurrence of this abnormality in normal and anencephalous subjects. These figures are shown in the following tables.

TABLE I.—*Sternalis in Anencephalous Fœtuses.*

Observer.	Absent.	Present on both sides.	Present on R. side.	Present on L. side.	Present, side doubtful.	Totals.
Abraham, .	5	3	2	–	–	11
Shepherd, .	1	4	–	4	–	9
Cunningham,	5	1	–	–	–	6
Windle, . .	17	4	2	4	–	27
Totals,	28	12	4	8	1	53

TABLE II.—*Sternalis in other subjects.*

Observer.	Sternales.	Subjects.
Wood,	7	175
Turner,	21	630
Wenzel Gruber,	5	95
Macalister,	21	350
Le Double,	33	722
Schwalbe and Pfitzner,	4	238
Windle,	5	108
Totals,	96	2318

From these tables it appears, that so far as present statistics go, a sternalis is present in nearly fifty per cent. of the anencephalous fœtuses which have been examined for this purpose whilst in other subjects it occurs in something less than five per cent. Thus it is ten times as common in the former type.

From the fact given above, the following conclusions may be drawn as to the myology of the anencephalous fœtus.

1. The sternalis excepted, the musculature does not present abnormalities different in nature to, or in a more strikingly frequent manner than, those of ordinary subjects.
2. The sternalis occurs about ten times more frequently in anencephalous than in ordinary forms.
3. The form of sternalis met with is one which often departs remarkably from the type, if not from the kind, met with in other cases.

BIBLIOGRAPHY.

1. Abraham, *Trans. Acad. of Med.*, Ireland, 1883.
2. Cunningham, *Jour. of Anat. and Phys.*, xxii. 391.
3. Le Double, *Acad. de Méd. de Paris*, 1890.
4. Macalister, *Trans. Roy. Irish Academy*, xxv.
5. Schwalbe u. Pfitzner, *Anat. Anzeig*, 1891, 573.
6. Shepherd, *Jour. of Anat. and Phys.*, xix. 312 and xxiii. 301.
7. Turner, *Jour. of Anat. and Phys.*, i. 246.
8. Wenzel Gruber, *Mem. de. l'Acad. Imp. de St Petersb.*, vii., iii.
9. Windle, "Sternalis," *Anat. Anzeig*, 1889, 715.
10. „ "Flexors of Hand," *Jour. of Anat. and Phys.*, xxiv. 72.
11. „ "Pectoral Group," *Trans. Roy. Irish Acad.*, xxix.

CONTRIBUTIONS TO THE HISTOLOGY OF THE HEDGEHOG. By E. W. CARLIER, M.D., B.Sc., F.R.M.S., *Senior Assistant to the Professor of Physiology in the University of Edinburgh.*[1] (PLATE XXI.).

PART IV. THE LYMPHATIC GLANDS.

Stroma of the Gland.—Kölliker,[2] Leydig,[3] Toldt,[4] Frey,[5] Krause,[6] Orth,[7] Schäfer[8] and others maintain that the fine reticulum found in the gland substance proper, and bridging across the lymph-sinuses, is composed of nucleated branched cells united by their processes.

Ellenbergher[9] Bizzozero,[10] Ranvier,[11] Klein,[12] and Hoyer[13] state that this reticulum is composed of connective-tissue fibres embraced by clasping connective-tissue cells. Hoyer, by digesting the gland in pancreatic glycerine extract, and then washing, obtained a beautiful fine network of connective-tissue fibrils free from cells that had undergone digestion and solution. He figures the network.

Similar results may be obtained in the hedgehog by shaking thin sections of the gland in water, and, if necessary, any cells still remaining can be removed by pencilling with a fine brush. There can be no doubt that the latter is the correct view, for in the case of the cat no such trouble need be taken, fine

[1] Parts I. and II. appeared in the October, and Part III. in the January number of this volume of the *Journal.*

[2] Kölliker, *Handbuch der Gewebelehre*, 1867.

[3] Leydig, *Lehrbuch der Histologie des Menschen und der Thiere*, 1857.

[4] Toldt, *Lehrbuch der Gewebelehre*, 1877.

[5] Frey, *Handbuch der Histologie und Histochemie des Menschen*, 1874.

[6] Krause, *Allgemeine und Mikroskopische Anatomie*, 1876.

[7] Orth, *Cursus der normalen Histologie*, 1878.

[8] Schäfer, *Histology*, 1887.

[9] Ellenbergher, *Handbuch der Vergleichenden Histologie und Physiologie der Haussäugethiere*, 1887.

[10] Bizzozero, *Sulla struttura delle ghiandole linfatiche*, 1872.

[11] Ranvier, *Traité technique d'Histologie*, 1875.

[12] Klein, *Histology*, London, 1886.

[13] Hoyer, "Beitrag zur Kenntniss der Lymphdrüsen," *Archiv f. Mikro. Anat.*, Bd. 34, p. 208.

sections of the gland exhibit the direct continuity of the strands of this network with the fibrous trabeculæ from which they spring (fig. 6, Pl. XXI.). Moreover, in the lymph-glands of the ox, clasping cells may often be seen partially detached from the strands adhering, it may be, by the tips of their wings only.

The fibrous trabeculæ in the hedgehog are not of large size, but, like the capsule, contain a considerable number of non-striped muscle fibres embedded in the connective tissue.

The Cortical Lymph-Nodules are interesting in that they exhibit very clearly three well-marked zones. The nodules vary considerably in size, and in the centre of each there is a pale looking area termed by Flemming[1] the "keim centrum" or germinal centre, which varies in size in different cases, and consists of cells with a relatively large amount of protoplasm surrounding a large centrally placed nucleus. Under favourable conditions, numerous mitotic figures may be seen in these cells, amongst them a few lymph-corpuscles. On account of the energy exhibited by these cells in the ox and some other animals, Flemming named them germinal cells, and he believes that lymph-corpuscles result from their division, which subsequently become pushed out towards the periphery of the nodule, from whence they escape into the lymph-sinuses.

His[2] mentions that these germinal centres are richly supplied with capillary blood-vessels, and Flemming also noted the occurrence of arterioles in them, a fact easily demonstrated in the hedgehog. External to the germinal centre there is a well-marked zone densely packed with lymph-corpuscles of the usual type, some of which may be seen undergoing mitosis; outside this there is another zone extending to the margin of the nodule, in which the cellular elements are less densely packed. They exhibit mitotic figures, but not so numerously as the cells of the germinal centre. On the whole, it would seem that the cortical nodules of the lymph-glands are centres for the active production of lymph-corpuscles.

The Sinuses.—The cells of the lymph-sinuses have been care-

[1] W. F. Flemming, "Studien über Regeneration der Gewebe," *Archiv f. Mikro. Anat.*, Bd. 24, p. 50.

[2] His, *Frey's Handbuch der Histologie*, &c., Leipzig, 1876, p. 435.

fully studied by Hoyer.[1] In addition to the connective-tissue cells clasping the fibres, some of which may be detached, he has described other five varieties of cellular elements, viz., large and small lymph-corpuscles, granule cells of Heidenhain,[2] degenerate lymph-corpuscles, and phagocytes; all these different kinds of cells may be found in the hedgehog. The small lymph-corpuscles far outnumber the others; large lymph-corpuscles, which only differ from the small variety in having a broader zone of protoplasm around a somewhat larger nucleus, are also very numerous, and may sometimes exhibit mitotic figures. The granule cells would appear to be by no means common. I take it that, being degenerating leucocytes, they are identical with the eosinophilous cells of Ehrlich.[3] Degenerating lymph-corpuscles may also sometimes be found, but apparently in no great number. The phagocytes, on the other hand, are very numerous, especially during hibernation; they may exhibit various kinds of debris, from mere granules of colouring matter even to entire blood-corpuscles, according to Hoyer.[4] These cells, however, are by no means confined to the lymph-sinuses, being also found in every part of the gland excepting, perhaps, the germinal centres and fibrous tissue generally.

If I am correct in believing the granule cells described by Hoyer to be eosinophilous, then he has overlooked the plasma cells, which may usually be found in considerable numbers in every part of the gland, more especially in the connective tissue of the trabeculæ near the blood-vessels. The granules of these cells stain with basic anilin dyes, and have been shown by Korybutt-Daskiewicy[5] to be overfed white blood-corpuscles. They are also present in some numbers in the lymph channels and in the medullary cylinders.

During Hibernation some remarkable changes occur in these

[1] Hoyer, "Beitrag zur Kenntniss der Lymphdrüsen," *Archiv f. Mikro. Anat.*, Bd. 34, p. 208.

[2] Heidenhain, *Pflüger's Archiv*, Bd. 43, Supplement.

[3] Ehrlich, "Ueber die specifischen Granulationen des Blutes," *Verhandlungen der Physiologie*, 16th May 1874, No. 20.

[4] Hoyer, "Beitrag zur Kenntniss der Lymphdrüsen," *Archiv f. Mikro. Anat.*, Bd. 34, p. 208.

[5] Korybutt-Daskiewicy, "Ueber die Entwickelung der Nerven und Plasmazellen beim Frosche," *Archiv f. Mikro. Anat.*, Bd. 15.

glands; the germinal centres appear to be at rest, and therefore exhibit very few mitotic figures; but the number of phagocytes becomes greatly increased; they are present in every part except the fibrous framework. They occur singly or more frequently in groups of about a dozen (fig. 4, Pl. XXI.), they are of large size, and usually exhibit a single oval nucleus which stains faintly, and is situated towards one side of the cell; occasionally, there may be more than one nucleus. The protoplasm stains of an orange-yellow tint with hæmatoxylin and eosin, and usually contains numerous granules of a golden-yellow or brown pigment, which can be partially blackened by ammonium sulphide or stained blue with Barrett's reagent, pointing clearly to the presence of iron in it, and no doubt derived from hæmoglobin.

In addition to these granules, many cells exhibit shreds of tissue in various stages of degeneration, small rounded spots that stain of a citron-yellow colour with hæmatoxylin and eosin, and also some sky-blue transparent structureless rounded bodies (fig. 5, Pl. XXI.). I have not been able to satisfy myself that any red blood-corpuscles occur in them as stated by Hoyer,[1] though such may be the case. These cells appear to me identical with the well-known macrophages and splenic cells which also exhibit the same staining reactions and coloured contents.

I believe they do not attack and destroy *living* cells as microphages do, but that their protoplasm picks up and eliminates all kinds of dead cells and debris found circulating in the fluids of the body; so to speak, they come after the fray and remove the dead, being, in short, not soldiers but rather scavengers. We know that during hibernation large numbers of red blood-corpuscles disappear. Almost any specimen of blood film made towards the end of that period will exhibit some red corpuscles apparently in process of disintegration. It is conceivable that the remnants of such cells or their liberated hæmoglobin might find their way, together with the colouring matter derived from degenerating muscular tissue, into the lymph-stream and become arrested in the lymph-glands where

[1] Hoyer, "Beitrag zur Kenntniss der Lymphdrüsen," *Archiv f. Mikro. Anat.*, Bd. 34, p. 208.

these large cells would be conveniently situated to complete the process of their elimination. It does not seem to me justifiable to conclude that living blood-corpuscles are seized upon and destroyed either by these or by the splenic cells, though, as shown by Hunter,[1] a great hæmolysis undoubtedly does occur in the spleen; but, when dead, I see no reason for doubting that blood-corpuscles may be ingested and decomposed by them.

What ultimately becomes of the macrophages I am unable to state; whether in their turn they die and are devoured by similar cells, which is quite conceivable, or whether they ultimately find their way to the liver, where such cells occur as already pointed out,[2] or to the suprarenal capsules, where they may be met with in the zona reticularis, and there be broken down, seems doubtful, as they are not very numerous in either of these organs; that they do disappear after hibernation is certain, for during summer their number is greatly diminished.

These cells are in no way identical with the giant cells found in the spleen of this and some other mammals, except in so far as that the giant cells appear during hibernation also to acquire phagocytic habits.

Another remarkable appearance sometimes presented by these glands during hibernation is the presence in them of large multinucleated cells, or groups of cells, which exhibit the same staining reactions as the phagocytes (figs. 1, 2, and 3, Pl. XXI.). It was suggested to me by Prof. M'Fadyean that these might be groups of phagocytes united into a species of plasmodium, to overcome by united effort some particle of tissue too big to be ingested by a single cell. We know from the researches of Metschnikoff and others that such combinations of cells occur among the lower organisms, and possibly we may be dealing with a similar phenomenon here, but up to the present time I have not been able to convince myself that such is the case in this particular instance.

These large cells or combinations of cells are by no means common, and a great many more would have to be examined

[1] W. Hunter, "The Physiology and Pathology of Blood Destruction," *British Medical Journal*, vol. ii. p. 1223, 1892.

[2] See this *Journal*, vol. xxvii. p. 108.

before one would feel justified at arriving at such a conclusion, however probable it might seem. Certain it is that such bodies contain debris of cells, often of large size, and multitudes of pigment granules, and if they are not combinations of cells, I am disposed to think that they may result from stimulation or irritation of ordinary phagocytes.

Besides the pigment granules contained in the phagocytes, there are numerous highly refractile, brownish-yellow granules floating free in the lymph-stream or adherent to the cells of the stroma throughout the gland; they exhibit the iron reaction when treated with suitable reagents, and are derived no doubt from the colouring matter of the blood and muscular tissues; they are practically absent during summer.

There is also an increase in the number of plasma cells during hibernation in the fibrous tissue and sinuses; I am at a loss to account for this, since at this period they disappear almost entirely from every part of the body except the tongue.

From what has been said, it will be seen that the lymph-glands play a very important part in the economy of these animals, cleansing as they do the lymph-stream from many impurities existing in it during the hibernating state.

EXPLANATION OF PLATE XXI.

FIG. 1.—A Multinucleated Giant Phagocyte, in the protoplasm of which many pigment granules are visible. × Ob. $\frac{1}{10}$ inch water imm. Beck. and Oc. No. 3 Leitz.

FIG. 2.—A similar body with nuclei arranged in a chain, and exhibiting vacuoles as well as pigment granules. × Ob. $\frac{1}{10}$ inch water imm. and Oc. No. 3 Leitz.

FIG. 3.—Sectional view of a Giant Phagocyte. The nuclei, in each of which is a nucleolus, are grouped together. *a*, nuclei apparently situated in a vacuole; *b*, macrophages of ordinary type in its neighbourhood. × Ob. $\frac{1}{10}$ inch water imm. Beck. and Oc. No. 3 Leitz.

FIG. 4.—A group of Macrophages situated in a Sinus in close proximity to a Blood-vessel.

FIG. 5.—A group of Macrophages. × Ob. $\frac{1}{18}$ inch oil imm. Zeiss and Oc. apochrom. No. 4 Zeiss. *n*, in all cases indicates the true nucleus of the cell. A, the protoplasm which is vacuolated (*v*) contains pigment granules (*p*) of various sizes and colours;

B contains, besides pigment granules (*p*), a rounded citron-yellow body (*r*) that may possibly be a red blood-corpuscle; C and D present masses of coarse pigment granules (*a*) situated in vacuoles; E, besides various sized vacuoles (*v*), one of which (*d*) presents a double outline, a vacuolated mass of nuclear matter (*c*), in which is a nucleolus (*o*), is seen partly enclosed by the protoplasm of the macrophage; F, a vacuolated mass of nucleated matter (c) in process of breaking down is here seen entirely enclosed within the cell.

FIG. 6.—Lymphatic Gland of Cat. × Ob. $\frac{1}{10}$ inch water imm. Beck. and Oc. No. 3 Leitz., showing the direct continuity of the branched fibrous strands of the adenoid reticulum with the fibrous tissue of a trabecula; *c*, connective-tissue cell clasping a strand; *l*, lymph-corpuscles.

THE ANATOMY OF ADVANCED PREGNANCY IN *MACACUS RHESUS* STUDIED BY FROZEN SECTIONS, BY CASTS AND MICROSCOPICALLY. By D. BERRY HART, M.D., F.R.C.P.E., F.R.S.E.; and G. LOVELL GULLAND, M.D., F.R.C.P.E. (PLATE XXII.)

A FEW months ago, we were fortunate enough to obtain a *Macacus Rhesus* in an advanced state of pregnancy. Much work has been done recently in regard to pregnancy in apes by W. Turner (17), Waldeyer (18 and 19), and Selenka (13), so that we were anxious to fill any gap in our knowledge rather than to follow in the path already so ably and accurately explored by these investigators. Thus it seemed to us that one could accept unhesitatingly what Turner and Waldeyer have told us about the intervillous circulation in the advanced placenta of apes, as well as the dissectional anatomy of Breschet (1) and Selenka.

We therefore determined to investigate in the first place the frozen sectional anatomy of this specimen, to take casts of the uterine cavity and fœtus, and to examine the microscopic structure of the placenta. Dr Gulland gave the warning indeed that the tissues would be less fitted for microscopical investigation; but though the microscopical sections are less perfect than one could wish, they are definite enough for practical purposes.

The ape was accordingly chloroformed, and when dead, placed in a freezing mixture for several days: it was then sawn mesially and drawn. While still frozen, the fœtus and liquor amnii were lifted out and casts taken of the uterine cavity and fœtus. Portions of the placenta and uterine wall were then hardened, and afterwards cut in paraffin.

We now purpose considering:—

I. *The general anatomy of the specimen so far as it bears on pregnancy.*

II. *The uterine and fœtal casts.*

III. *The microscopical structure of the placenta.*

IV. *The general relation of apes to lower forms, and to the human female in regard to menstruation and pregnancy.*

I. *The general anatomy of the specimen so far as it bears on pregnancy.*

The ape was evidently a young female *Macacus Rhesus*, 18 inches from head to breech. The sagittal mesial section, unfortunately, did not hit the middle line exactly, but by a subsequent cut, the pelvis was cut more mesially. The pregnant uterus measured six inches vertically, and four transversely and antero-posteriorly, was oval in shape, and contained the fœtus and liquor amnii. It was probably near full time. The uterine wall measured only $\frac{1}{8}$ of an inch on section, and seemed equally thin throughout. The unimpregnated and pregnant uterus in the human female are each about one half inch thick.

The Fallopian tubes lay vertically in the abdominal cavity, and the ovary lay behind its corresponding tube. In the left ovary there was a *corpus luteum.*

The more mesial section of the pelvis showed the vagina at right angles to the brim, instead of parallel to it as in the human female: the anal, urethral, and vaginal canals were indeed all parallel to one another. The bladder was loosely connected to the pubis, and also to the posterior vaginal wall. The glans of the clitoris was grooved on the vertical mesial line.

The cervical canal was peculiar. It was somewhat dilated, owing to the plug of mucus having become swollen, and was divided into two parts, the lower portion being more dilated than the upper. This is quite different from the cervical canal of the human female, which is a slit-like cavity on section, with its anterior and posterior walls in apposition. This alteration in the cervical canal of the ape may be artificial, but, at any rate, the cervical canal in this case resembled that of the human female in not being opened up from above down by the advancing pregnancy.

The other points in relation to the fœtus come up afterwards.

II. *The uterine and fœtal casts.*

Fœtal cast.—The fœtus presented the head, although in most cases—Turner's (17), Hunter's (7)—it has at full time presented the breech. The antero-posterior diameter of the head lay in the transverse, and not in an oblique as it usually

does in the human female. The fœtal attitude was quite that of the full-time human fœtus, viz., body with marked dorsal curve and convexity posteriorly; arms flexed at elbow, right arm somewhat across body, left arm less so; hands flexed; thighs flexed on trunk, leg on thigh, toes flexed in, big toe also. The tail was flattened on the right leg, and the head turned a little to the left shoulder. The whole attitude is practically that of the human fœtus *in utero* at the end of pregnancy, but the condition of the hind paw is, of course, entirely different. In the human fœtus the foot is so placed that the dorsum touches the anterior aspect of the leg, an arrangement quite the opposite to that just given in the fœtal ape's hind paw. The doubled-up fœtus measured 6½ inches extended (without the tail).

The uterine cast.—This cast was of great interest, as it showed that the uterine wall was moulded on the uterine contents. Thus one can see the fœtal outlines in it: also the groove of the tail. The placental areas of the bilobed placenta are well shown. The lobes lay as usual, dorsal and ventral (in relation to mother). Their measurements were as follows: dorsal 3½″ × 2½″; ventral 3″ × 3″.

Their relations are well seen in the cast.

The cord was attached to the anterior one and measured 4¾ inches. The vertices and sides of the placentæ were connected by large fœtal vessels,—two arteries and two veins.

It thus seems that the uterine wall is perfectly passive during pregnancy, and is moulded by intra-abdominal pressure on its contents, a condition exactly the same as in human pregnancy.

The behaviour of the uterus during labour is unfortunately not known in apes, but it is to be hoped this gap will soon be filled up.

III. *Structure of the Placenta.*

After the freezing, section-cutting, and casting were terminated, parts of the placenta were cut out for microscopic examination. These were left for 24 hours in saturated solution of picric acid, thence removed to 50 per cent. alcohol for 12 hours, and then hardened in stronger alcohols, embedded in paraffin, and cut with the rocking microtome. The sections were fixed to the slide by the water method, and stained with

hæmatoxylin and eosin. Unfortunately, the placenta had suffered somewhat by the preliminary processes to which it had been exposed, and the preparations are not so perfect as might be desired. However, although they do not enable one to speak with certainty of the details of cell-structure in all parts of the preparation, there is no difficulty in making out the histological relationships of the different tissues, and the appearances we find will, we hope, throw some light on obscure points in connection with this subject.

It is unnecessary to enter into any detailed criticism of the literature bearing upon the placenta of monkeys. This has already been done fully by Turner and Waldeyer, and the only important paper which has appeared since the work of the Berlin Professor is that of Selenka. The points raised by him, and the questions discussed by Waldeyer, can be best approached in describing the individual parts of the placenta. The amnion and the connective tissue of the chorion and chorionic villi have often been described, and in our specimen present no peculiarities calling for remark. Waldeyer has already noted that the villi are more slender than those of the human placenta, and we can quite confirm this observation.

Turner and Waldeyer have also so fully and conclusively proved that the intervillous spaces contain maternal blood, that it is quite unnecessary to discuss that question further. But when Waldeyer says (19, p. 45) that he counts himself among those who accept the view that the intervillous spaces represent dilated capillaries, whose walls are preserved, and instead of being penetrated by the villi are simply invaginated by them, while the villi permanently retain their covering of fœtal epithelium, we join issue with him at once. Apart from the question of the preservation of the capillary walls, which we shall take up immediately, we would ask how it comes, if Waldeyer's view be correct, that this process of dilatation of capillaries has never been observed even in early human pregnancies like those described by Keibel (8) and ourselves (3), or in the still earlier pregnancies of monkeys described by Selenka (13), where there was a considerable thickness of decidua serotina still unconverted into placenta?

We fail to understand how the large numbers of dilated

capillaries which are pre-supposed by this theory unite into the common intervillous space,—a space which extends apparently unbroken except by the villi all through the placenta, or at any rate through large portions of it, and we would point out that we have given reasons for believing that the intervillous space is originally a fœtal space, which becomes secondarily only a part of the maternal circulation. That is to say, we have shown that the degenerated decidua serotina is removed by the actively growing epithelium at the tips of the villi, and that the intervillous space behind this attacking line is bounded only by the fœtal epithelium covering the villi, which in the early history of the placenta is a double layer; later becomes a single cubical layer, and that this single layer is much flattened and degenerated in the full-time placenta. We are therefore among those who believe that the intervillous spaces are extravascular spaces, and that the maternal blood makes its way into them only after the walls of the maternal vessels in the serotina have been destroyed. This view, or something nearly approaching it, is upheld also by Farre, Kölliker, Langhans, and Heinz (*cf.* Waldeyer, 19, p. 44), and we consider that in the degeneration of the serotina, the thrombosis of its vessels and the degeneration of their walls, which we have demonstrated in the early human placenta, we find ample support for our belief. The placenta of the monkey is obviously homologous with that of man, and this homology has been accepted by all writers on the subject, so that we feel justified in taking it for granted that in this matter also the correspondence is complete. That this destruction of vessels by placental growth can happen is proved abundantly by every extra-uterine gestation, as there maternal blood is invariably extravasated round the villi.

Waldeyer's main reason for regarding the intervillous space as representing dilated maternal vessels seems to be that he finds, in the placenta of *Inuus Nemestrinus*, a single layer of cells, which everywhere borders the intervillous space, being continuous with the endothelium of the arteries and veins which open into that space, covering the so-called "decidual hillocks," in which the "Haftzotten" or attaching villi are embedded, and covering the villi and the under surface of the chorion. He says that this layer is easily detached from the subjacent tissues,

and regards this as a sign that it is endothelium. We see this layer perfectly in the placenta of *Macacus Rhesus*—much better than in any human placenta—and note also how easily it is detached, but we consider that it is the outer layer of the fœtal ectoderm, and we shall describe it as such in due course. We would point out, however, that the ease with which it is detached is, to our minds, a proof rather of its epidermal than of its endothelial nature: nothing is more difficult than to separate a true endothelium from subjacent tissue. The cells have a

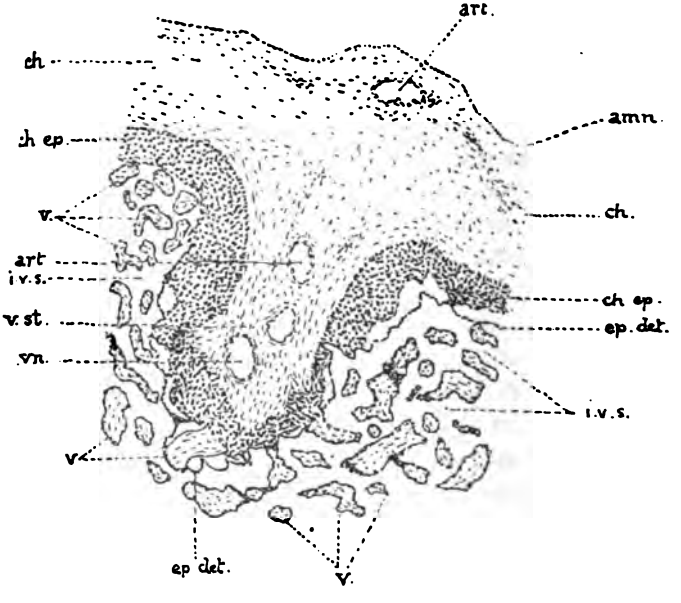

Fig. 1. Part of the amnion, chorion and placenta of *Macacus rhesus*:—*am.*, amnion; *ch.*, chorion; *ch. ep.*, fœtal epithelium (ectoderm covering the chorion and main villi); *ep. det.*, the superficial layer of the epithelium detached in places (Waldeyer's endothelium); *v.*, villus; *v. st.*, villous stem; *art.*, artery; *vn.*, vein; *i.v.s.*, intervillous space containing maternal blood. Ob. $\frac{1}{6}$, oc. 4.

character totally different from any endothelium; they are cubical, closely set together, and with a considerable cell body, and we know of no instance elsewhere where an endothelium inclosing enormous masses of blood is apposed over a vast area to epithelium, and especially epithelium belonging to another

individual, without any trace of connective tissue to support it. Moreover, we know of no force involved in the formation of the placenta which could act so as to dilate capillaries in this imaginary way, nor any reason, logical or histological, why, if all the other tissue-elements of the decidua are removed, by the villi or otherwise, the vascular endothelium should be spared entire, and moulded to the surface of the destroying villi.

In the discussion of the relations subsisting in the placenta, too little attention has been paid by many authors to the fact that the tissues of two separate individuals are involved in its formation, and it has been taken too much for granted that the uterus had an important part to play in the formation of that organ. Turner, however, calls attention to the distinct nature of the fœtal and maternal parts of the placenta, and speaks of the fœtus as a parasite. Selenka also regards the embryo as the parasite of the uterus, and in truth all our observations tend to show that the part played by the maternal tissues is mainly a passive one, and that the fœtus profits by the degenerative processes which go on in them. Even the formation of the decidua reflexa seems to be really an accident, so to speak, connected with menstruation, and not a true formative process; the fertilised ovum, implanted on the surface bared by the menstrual flow, is covered over by the rapid growth of the uterine mucous membrane, and so is "healed in" as any other non-irritating foreign body would be. When the ovum begins to increase rapidly in size, and to invade and press upon the decidua reflexa, that envelope degenerates in precisely the same way as the serotina, but even more rapidly.

The covering of the chorion and villi is entirely fœtal therefore, in our opinion, and, just as in the human placenta, it differs in different places. One point in dispute between different authors is whether the main or amniotic chorion is covered by a single layer of cells, or by a layer of several cells. Turner, in Macacus, found a layer of several cells; Waldeyer, in Inuus, found a single layer. Very possibly, as Waldeyer suggests, the placentæ may have been of different ages, or different parts may have been examined. We certainly find everywhere a many-celled layer, but differ entirely from Turner and Waldeyer in our interpretation of it. These authors seem uncertain whether to

regard it as decidual, and representing Winkler's "Schlussplatte," or as chorionic, and derived from connective tissue cells. We see every reason to regard it as fœtal and ectodermal. It coats the main chorion and the main villi, running along these to become continuous with the so-called "decidual hillocks" into

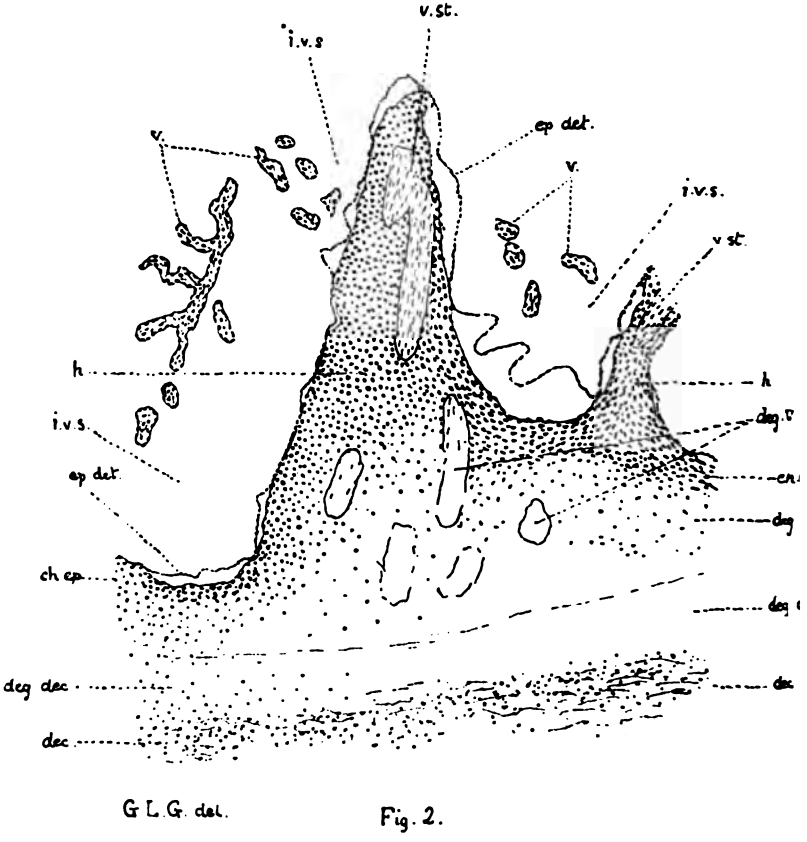

Fig. 2. Section through the same placenta to illustrate the attachment to the deidua serotina :—*deg. v.*, degenerated villi ; *deg. ep.*, degenerated fœtal epithelium on the surface of the trophoblast ; *dec.*, decidua ; *deg. dec.*, degenerated decidua ; *h.*, so called "decidual hillock"—trophoblastic expansion of the fœtal ectoderm at the extremities of the main villi. Other letters as in fig. 1.

which the main villi or "Haftzotten" run. These hillocks we regard as expansions of the fœtal ectoderm of the same nature as those we have described in the human placenta (3), but which

seem to be preserved to a later date, relatively, than in man. The cells of this layer are obviously different in character from the true decidual cells. Next the chorion is a layer of fairly columnar cells; then they are disposed more irregularly, and towards the surface—the intervillous space—are somewhat flattened, while the superficial layer, that which Waldeyer regards as an endothelium, is a layer of flat cubical cells, which, when the villi are cut so that a surface view of them is obtained, are almost exactly like the layer of epithelial cells covering the amnion. Nowhere in the whole of this layer, either on the chorion or villi or in the so-called "hillocks," are there any blood-vessels, leucocytes, or fibres, all of which are invariably present in any modification of the uterine mucous membrane, and the cells (and nuclei) are all very nearly of the same size—a characteristic of epithelium rather than of connective tissue.

Perhaps the most conclusive proof of the fœtal and epithelial nature of this tissue is the fact that a layer presenting exactly the same characters, but with a thickness of two or three cells instead of six or a dozen, covers the surface of the chorion outside the placenta altogether, and is separated by a layer of degenerated fibrinous-looking material from the remains of the decidua vera, which are quite unlike it in appearance.

Where the main villi break up into branches, this thick layer thins out, gradually or abruptly, and the small villi are covered simply by the single superficial layer, which has the same characters here as over the "hillocks" and elsewhere, and these small villi have much the same appearance therefore as the villi in a human placenta of about seven months, when the epithelium of the villi has become reduced to a single layer, and has begun to degenerate.

The so-called "decidual hillocks" require a word or two of description. They are to be found at the points where the main villi come in contact with the serotina, and the old idea in regard to them was that they were masses of decidual cells—*i.e.*, connective tissue cells, which in some unexplained way formed or were found at these points. Whether the villi tended to attach themselves specially to pre-existing hillocks, or whether they produced these masses of decidual cells by some action of their own, no one seems to have inquired, though the

first supposition seems unlikely and the second well nigh impossible, as the hillocks are based upon degenerated serotinal tissue.

What we see in these structures is, that the layer of fœtal ectoderm, which underlies the main chorion and runs along the main villi, becomes thick and massive at the points where the main villi approach the serotina, and the mass of cells forms a cone into whose apex the villus-stem is inserted, and whose base is spread out upon the surface of the serotina. The bases of the cones usually extend somewhat over the surface of the serotina, much more than the corresponding structures in the human placenta do, except in the very beginning of its history, and the base of one cone thus generally meets or nearly meets the base of another, as a flattened layer, unless the opening of an artery or vein into the inter-villous space breaks the continuity. The layer of flattened epithelium (Waldeyer's endothelium) passes from the villus-stem over the surface of the cone which is turned towards the inter-villous space, and runs over the flattened layer between the cones. This fact, as Waldeyer himself half acknowledges, is an important point against his theory, for if this layer really represented the endothelium of dilated vessels, which are invaginated before the growing villi, why is this layer not invaginated before the main villi? Waldeyer regards it as a proof of the correctness of his view as to this layer, that it is continuous with the endothelium of the arteries and veins opening into the inter-villous space, but as this layer bounds the whole of the inter-villous space, it could hardly but be continuous with the endothelium; that continuity cannot imply identity when the two layers are so totally unlike one another. The connective tissue core of the villus leaves the layer behind it at the apex of the cone, and branches and re-branches within the cone without any other covering than the cells of the cone itself. These cells have the epithelial characteristics already mentioned, and we see every reason to regard them as homologous with the masses of fœtal epithelial cells at the tips of the villi which we have described in the human placenta. In the monkey this structure evidently persists to a later period than in man—for what reason we do not venture to surmise. The deep or serotinal surface of these epithelial cones is generally slightly

degenerated, especially if the mass of cells in the cone is large, not so much in the flatter expansions, and the tips of the connective tissue branches of the villi, which are usually flush with the serotinal surface of the cones, are always markedly degenerated, the nuclei are lost, the fibrillated character of the connective tissue disappears, and the villus is only recognisable by its difference from the surrounding structures in the matter of staining. This tendency to degeneration of the surface of the epithelial part of these cones we have noted also, though to a much less extent, in the human placenta, and it is of course a common phenomenon in all many-layered epithelia, especially when exposed to pressure.

It is exceedingly to be regretted that the histological part of Selenka's memoir on the ape's placenta (13) has as yet only the character of a preliminary notice, and that he has not at all discussed the minute structure of the advanced placenta; for his figures show us that between the early stages of the monkey's placenta and that of man, there is the most startling similarity. This is especially to be noted in the great development in the monkey of the "trophoblastic" epithelium at the tips of the villi (*cf.* Taf. 35, figs. 5, 11, 12; Taf. 37, fig. 5). Selenka has indeed entirely missed the significance of this structure, and regards it as a development of the maternal epithelium, because he regards the outer layer of the epithelial covering of the villi as maternal. In this view he stands at the present day almost entirely alone, and his own figures might have shown him his error. As Waldeyer points out, the characters of the two epithelia are totally different. Selenka lays great stress upon the fact that in one specimen the epithelium at the end of a villus, was found entering a large dilated gland, but in the figure which he gives of this, none of the twenty or thirty other villi which reach the serotina enter glands at all, but are all coated with "trophoblastic" epithelium which is apparently destroying the serotina. His fig. 12, Taf. 35, might have been drawn from some of our preparations of the early human placenta. The view that maternal epithelium enters into the covering of the villi, has been abundantly discussed by Minot (12) and ourselves, and need not be further entered into.

The decidua serotina is robbed by us of its "placental layer"

(Waldeyer and Turner), which consists of the hillocks. The superficial part of the serotina we find markedly degenerated, sometimes forming simply a fibrinous mass, just as in the human placenta, and the extremities of the mesoblastic core of the villi, themselves degenerated, sometimes penetrate this layer. Below this layer is a true decidua, not very different from the human serotina, except that the cells are never so large. There are many vessels in this layer, whose walls are often considerably degenerated, and beneath it there is a spongy layer, not well developed, but having the same characters as that in the human placenta. Waldeyer doubts the presence of this layer, but here again a difference in the age of the placentæ examined may explain the discrepancy.

The decidua vera external to the placenta is very like the serotina, but very much thinner and less vascular.

IV. *The general relations of apes to lower mammals, and to the human female in relation to menstruation, the determination of the placental site, and the origin of the umbilical cord.*

Under this head, we wish to consider some special points of great interest. These are :—

(*a.*) *Menstruation in apes.*
(*b.*) *The determination of the placental site.*
(*c.*) *The origin of the umbilical cord.*

(*a.*) *Menstruation in apes.*—In the higher apes it is now well known that a periodical discharge of blood takes place from the genitals. The best research is by Bland Sutton (14), who examined the uteri of several macaques and baboons, at various stages. As the animals were killed and the parts at once preserved, no fallacy of post-mortem changes came into the observations. Sutton found that the mucous membrane became thickened, that blood escaped (small in quantity), and that there was no shedding of the superficial layer of the mucous membrane, *the epithelium remaining intact, although blood was found in the uterine cavity.*

In the human female, however, as is now well known (Kund-

rat (10), Engelmann (2), Leopold (11),), the superficial layer of the uterine mucous membrane is shed, and thus we have a distinct difference between menstruation in apes and the human female. Whether or not in the very highest apes, such as the gorilla and chimpanzee, denudation of the mucous membrane occurs, is as yet unknown.

(*b.*) *The determination of the placental site.*—The comparative physiology of this point is one of the greatest interest and value. In *Ruminants*, as is well known, there are special elevated and thickened parts of the mucous membrane, the cotyledons, on which the villi graft, and give the well-known polycotyledonary placenta. We have, therefore, specially developed areas for placental attachment.

In *rabbits*, the ovum always grafts itself on two folds, the placental folds, which run parallel, and on the side of the broad ligament attachment.

In the *hedgehog*, according to Hubrecht (6), the ovum attaches itself, and the placenta developes in that part of the uterine horn opposite the broad ligament attachment, the mucous membrane being thinnest at the side next the broad ligament in the virgin uterus.

In the *apes* examined by Selenka, it was found that there was a special part of the middle of the posterior uterine wall—the "Haftfleck"—where the dorsal lobe of the bilobed placenta developed; the ventral lobe developing on a corresponding portion of the ventral uterine surface a little later. This "Haftfleck" had about thirty or forty gland openings in it, and increase of the placental site was due to an increase in the "Haftfleck."

It is of remarkable interest that in the apes with bilobed placenta, where the uterus is formed on the same plan as in the human female, *i.e.*, has Fallopian tubes and a single uterus, pregnancy is made uterine by this arrangement of a "Haftfleck" for the placental site, and that in all apes with a bilobed placenta, the placenta is in invariably the same position—the middle portions of the anterior and posterior uterine walls.

In those apes with a single placenta, we have no special observations: in the human female, the placenta may graft itself normally on any part of the uterine surface proper, *i.e.*,

never below the os internum nor outside the inner openings of the Fallopian tubes. If we take the bicornuous uterus as displayed in a ruminant, we find a narrow tube, then the cornua. The implantation of the placenta in the cornua is favoured by the cotyledonary arrangement, and no tubal pregnancy has ever been found.

In the human female, we have already thrown out the suggestion that the human ovum can only graft on connective tissue, and that menstruation thus bares a safe area. It must be remembered that the Fallopian tube of the human female has a very perfect mucous membrane, and one that can form a serotina like the uterine mucous membrane itself, and it is possible that the menstrual denudation maps out a normal attachment-area in the human uterus.

(*c.*) *The origin of the umbilical cord.*—The origin of the cord is at present disputed. The view usually adopted is that of Kölliker (9), viz., that at one period the developing ovum is free, but is again moored to the chorion by the outgrowth of the allantois.

His (5), on the other hand, maintains that at an early stage the developing ovum is in connection with the chorion by its posterior end—"Bauchstiel"; that this forms the cord, the allantois tunnelling it, as it were. The covering of the cord is therefore, morphologically, skin, and not amnion. At first the cord is covered with a single layer of cells; at about the 3rd month this layer is multiple, and at the full time many-layered and flattened. Thus the covering of the cord is morphologically skin, but not so completely differentiated as over the fœtus.

Hertwig (4), on the other hand, holds that the developing ovum is attached to the chorion at first by amnion. The closure of the amnion is at the posterior end of the embryo. The allantois grows out, not free into the cœlom, but along the ventral surface of the amniotic attachment.

Selenka (13) describes this last condition as occurring in the monkey. The question, however, cannot be considered settled as yet.

We have only a few words now on the relation of this class of apes to the scale of evolution. We regard the main branches

of the mammalia as having diverged from the primitive monotremes and marsupials. Thus we have monotremes, marsupials, and then the primates comprising lemurs, apes, and man. We have here a gradation. The ornithorhynchus has a completely bifid genital tract and lays eggs; the marsupials have a less bifid uterus, and a very imperfect villous attachment of the fœtus to the maternal structures.

The lemurs have a bicornuous uterus and diffuse placenta; the lower apes a single uterus, bilobed placenta, and no reflexa; the higher apes and human female, a single uterus, single placenta and reflexa. Looked at from the special point of view of attachment of the placenta, we get:—

(*a*) No attachment of fœtal tissue: ornithorhynchus.
(*b*) Very imperfect attachment: kangaroo.
(*c*) More perfect attachment, but placenta non-deciduate: lemurs.
(*d*) Placenta deciduate, but not embedded: lower apes.
(*e*) Placenta with reflexa—*i.e.*, ovum embedded at first in maternal tissues, placenta deciduate: higher apes and human female.

LITERATURE.

1. Breschet, G., "Recherches anatomiques et physiologiques sur la gestation des Quadrumanes," *Mem. de l'Acad. d. Sciences de l'Institut de France*, Tom. xix., 1845.
2. Engelmann, "The Mucous Membrane of the Uterus, with especial reference to the Development and Structure of the Decidua," *Amer. Journ. of Obst.*, vol. viii.
3. Hart and Gulland, "On the Structure of the Human Placenta, with special reference to the Origin of the Decidua Reflexa," *Rep. Laborat. Roy. Coll. Phys. Edinr.*, iv., 1892.
4. Hertwig, O., "Text-book of the Embryology of Man and Mammals," (English Translation) London, 1892.
5. His, W., *Anatomie Menschlicher Embryonen*, 1885.
6. Hubrecht, "Studies in Mammalian Embryology. I. The Placentation of *Erinaceus Europæus*, with remarks on the Phylogeny of the Placenta," *Quart. Journ. of Micros. Sci.*, vol. xxx. p. 283.
7. Hunter, John, Collected Works, by Palmer, vol. iv. p. 71.
8. Keibel, "Zur Entwicklungsgeschichte der menschlichen Placenta," *Anatom. Anzeiger*, p. 537, 1889.
9. Kölliker, A., "Entwicklungsgeschichte der Menschen und der höheren Tiere," 1879.

10. KUNDRAT, "Untersuchungen über die Uterusschleimhaut," *Stricker's Jahrbuch*, 1873.
11. LEOPOLD, "Studien über die Uterusschleimhaut während Menstruation, Schwangerschaft und Wochenbett," *Arch. f. Gynaek*, Bd. xi.
12. MINOT, "Uterus and Embryo." I. Rabbit; II. Man. *Journal of Morphology*, vol. ii. p. 341. Human Embryology, New York, 1892.
13. SELENKA, E., "Studien über Entwickelungsgeschichte der Tiere," 5tes Heft: Erste Hälfte 1891, Zweite Hälfte 1892, Wiesbaden.
14. BLAND SUTTON, "Surgical Diseases of the Ovaries and Fallopian Tubes," London, 1891, p. 7 *et seq.*
15. TURNER, Sir W., "Lectures on the Comparative Anatomy of the Placenta," 1876.
16. „ "The Placentation of the Lemurs," *Phil. Trans.*, 1876.
17. „ "On the Placentation of the Ape," *Phil. Trans. Roy. Soc.*, part ii., 1878.
18. WALDEYER, W., "Die Placenta von *Inuus nemestrinus*," *Sitzber. d. Berlin Akad.*, 1889, pt. 2, p. 697.
19. „ "Bemerkungen über den Bau der Menschen und Affen Placenta," *Arch. f. mikr. Anat.*, vol. xxxv., 1890, p. 1.

EXPLANATION OF PLATE XXII.

A. Sagittal section through pregnant monkey (frozen), a little to the right of the middle line (about $\frac{1}{3}$ of the natural size).

B. Part of an exactly mesial section through the pelvis, to show the central dilatation of the cervix, the fact that it is not opened up from above down, and that the urethra, vagina, and rectum are all parallel and vertical.

MORPHOLOGY OF LIMB ARTERIES IN VERTEBRATES, WITH ESPECIAL REFERENCE TO THE DISPOSITION IN THE HUMAN SUBJECT. By

ALFRED EICHHOLZ, B.A., Emmanuel College, Cambridge.

(Read before the Anatomical Society, February 1893.)

IN any discussion as to the significance of the disposition of limb arteries, it becomes at the outset necessary to show that Morphology plays an important part, for the recent literature on the subject by no means confirms any such view. The part played by mechanical influences has been made so prominent that phylogeny has been to a great extent overlooked. Ruge,[1] for instance, speaking of all the best known forms of arterial abnormality, says—

"Alle bisher zur Sprache gekommenen Arterienvarietäten sind auf die Ausbildung von feinen und feinsten Gefäszen zurückzufahren welche proximal aus der Axillaris oder Brachialis entspringen." **That accident, however, is not the main determining cause of abnormality he later maintains, for** "in dem beiderseitigen Auftreten von Arterienvarietäten finden wir eine neue Bekräftigung dass die Varietäten nicht durch zufällig Auftretende Ursachen hervorgerufen sein Können."

In attempting to arrive at a morphological basis, Ruge examined fœtal vessels, without however material advance, ontogenetic considerations failing in this case to yield any result.

More recently Bayer has advanced towards a morphological basis in comparing the arterial systems of new-world apes with that of Man.[2]

A common opinion is that the limb arteries, as such, possess little or no morphological significance: they are merely nutritive trunks, at the mercy, so far as disposition is concerned, of the master tissues. But recent physiological research must go far to disprove this. Langley[3] has recently shown how the arm and leg arteries are supplied with nerves as definitely as any other muscular tissue; and though these nerves are non-medullated, Gaskell[4] has shown that the non-medullated, so-called, splanchnic

[1] Ruge, "Beiträge zur Gafässlehre des Menschen," *Morph. Jahrbuch.*, Bd. xix. s. 381.

[2] Bayer, "Beiträge zur vergleichenden Anatomie der Oberarmarterien," *Morph. Jahrbuch*, Bd. xix., 1892.

[3] J. N. Langley, *Phil. Trans.*, 1892.

[4] W. H. Gaskell, *Jour. Phys.*, vol. vii. p. 1, 1886.

efferent portion of a nerve is as typical a portion of a segmental nerve as the somatic efferent portion. So, then, if we concede that nerve-supply has any morphological meaning in cases of somatic musculature, it follows too that in cases of non-medullated nerve-supply, the muscle supplied must have a morphological significance equal at least to that of somatic musculature.

Again, the fact that in the least differentiated portions of ventral somatopleure the nerve is invariably found to be accompanied by an artery, must favour the view that arteries possess more than mere mechanical significance.

Recognising, then, the fact that ontogenetic methods fail, and assuming a phylogenetic significance for arterial trunks, it becomes a problem as attractive as it is important to assign to them their proper position in the vertebrate structure.

In the truly segmental portion of the organism there is little in the way of difficulty to overcome. Each segmental nerve has its accompanying artery, which one may then call the segmental artery. The intercostal nerves and vessels best exemplify this condition. But the problem is one of greater intricacy in the case of the limb arteries.

Here we have to remember that phylogenetic origin of limbs is ascribed by various schools to various causes. The English school adopts Humphry's view, that the limb is formed as a lateral outgrowth from the ventral somatopleure, acquiring additional attachment dorsally and ventrally by backward and forward extension from the primary excrescence. In this formation the deepest layer of the somatopleure is supposed to take no part.

As far as the limb is concerned, then, we have from behind forwards—

1. Dorso-appendicular musculature.
2. Extensor limb „
3. Flexor „ „
4. Ventro-appendicular „

The nerves follow this arrangement too, for we find the posterior cord of the brachial plexus supplying the dorso-appendicular and extensor limb musculature, and the inner and outer cords (anterior cord) supplying the ventro-appendicular and the flexor musculature.

The object of the present discussion is to determine whether or not the arteries of the limbs can be morphologically systematised similarly to the muscles and nerves of the limb, so that we may speak of dorso- and ventro-appendicular arteries, and of extensor and flexor arteries.

The main difficulty to encounter in the case of arterial homology is that of anastomoses. In the nerves the terminations are final and absolute, and the difficulty of homology minimised. But arteries, with their numerous anastomoses, are by no means readily classified. The artery-supply of the limbs to be brought into line with the remaining soft parts must admit of being based on some plan such as the following. The musculature and nerve-supply being derived from the homologue of the ventral portion of the somatopleure (intercostal), the artery-supply will correspondingly be derived from a vessel "intercostal in plan," which,

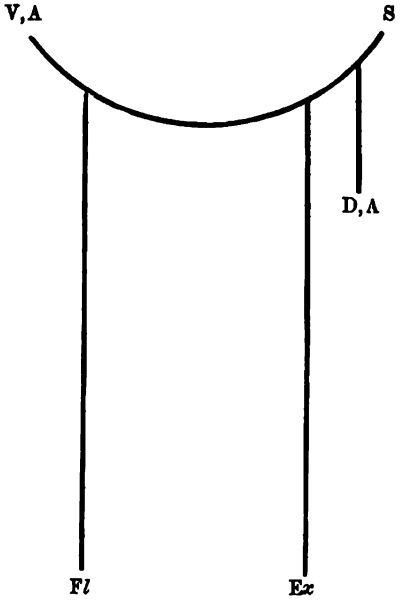

FIG. 1.—Primitive typical Arterial System of the Limb. S, subclavian artery; D,A, dorso-appendicular vessel; *Ex*, extensor vessel; *Fl*, flexor vessel; V,A, ventro-appendicular vessel.

starting dorsally from the aortic trunk, will give off first the dorso-appendicular (D,A, fig. 1) and extensor limb vessels (*Ex*, fig. 1), then the flexor (*Fl*, fig. 1), and finally the ventro-appendi-

cular (V,A supply). Such a simple arrangement seems, at first sight, far removed from the complex arrangement in Man and the primates, but a study of the lower vertebrates serves to confirm this view as a probable primitive arrangement.

Upper Limb Arteries.

The artery "intercostal in plan" is in the upper limb the subclavian, together with a portion of the axillary—how much will be presently indicated.

In *Testudo Europœa*[1] the subclavian artery gives off as the first branch after its origin a branch arteriæ axillaris ramus descendens, which corresponds in supply to the dorso-appendicular

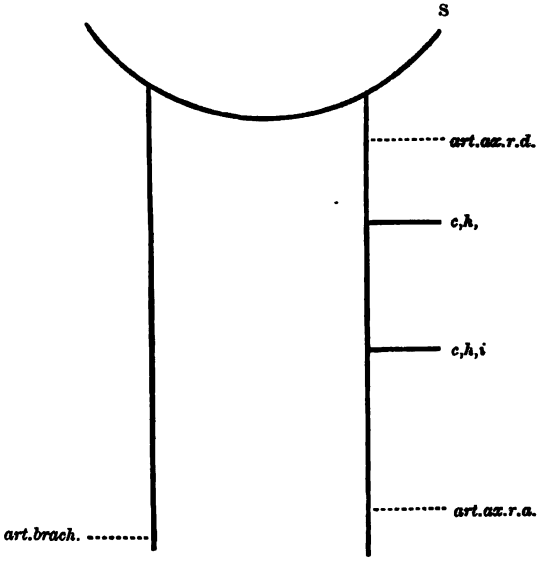

FIG. 2.—*Testudo Europœa.* Fore-limb Arteries. S, subclavian artery; *art. ax. r.d.*, arterial axillaris ramus descendens; *c,h,e*, circumflexa humeri externa; *c,h,i*, circumflexa humeri interna; *art.ax.r.a.*, arterial axillaris ramus ascendens.

and extensor trunk, its supply, as far as the appendages are concerned, being the circumflex humeri externa (*c,h,e*, fig. 2), circumflex humeri interna (*c,h,i*, fig. 2), to the dorso-appendicular muscles, and a ramus anterior to the arm extensor muscles.

Further on its course the main trunk gives off an arteria

[1] L. H. Bojanus, *Anat. Testudinus Europœæ*, 1819–21.

brachialis, which descends on the flexor side of the arm as a flexor supply. *Testudo Europæa*, then, serves to confirm the hypothetic primitive arrangement.

In *Cryptobranchus Japonicus*[1] the upper limb trunk vessel gives off an arteria circumflexa scapulæ, and together with this a branch to the extensor muscles of the forearm. The main

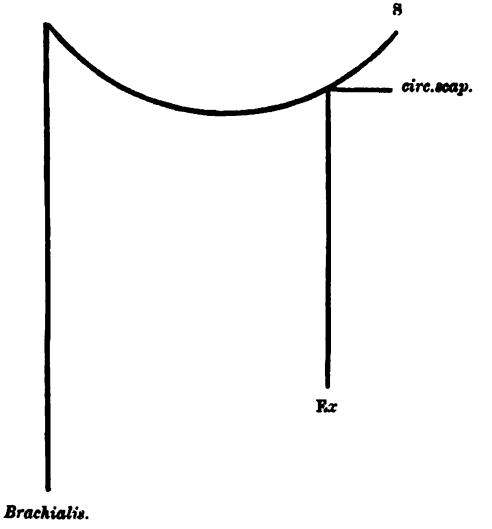

FIG. 3.—*Cryptobranchus Japonicus*. Fore-limb Arteries. S, subclavian artery; *circ.scap.*, circumflexa scapulæ; *Ex*, branch to extensor muscles of arm.

trunk then winds round the humerus and gives off, on the inner side, an arteria brachialis which proceeds down to the inner side of the forearm, supplying the flexor muscles.

In Chameleon[2] the upper limb trunk gives off its dorso-appendicular extensor vessels first, and is then continued along the inside of the biceps, giving off but very few slender muscular branches in the forearm, and is therefore flexor in nature. Here again, then, the typical arrangement persists.

In Crocodiles[3] the dorso-appendicular and extensor supply arise first as the collo-scapularis superficialis and arteria profunda brachii respectively. The ventro-appendicular supply consists

[1] Hyrtl, *Cryptobranchus Japonicus*, Wien, 1865.

[2] J. Yule Mackay, "Art. Syst. Chamæleon," *Memoirs and Memoranda in Anatomy*, 1889.

[3] Bronn-Hofmann, *Eidechsen und Wasserechsen*, 998.

of several arteriæ thoracicæ. The continued trunk, now the arteria brachialis, remains as the flexor trunk.

It may be objected that the flexor brachial artery in the above cases, besides giving rise to the forearm flexor supply, gives origin to the forearm extensor supply. To this objection a provisional answer may be given, that following a general rule of arterial limb supply, the extensor supply is broken up in continuity, and that by anastomosis the forearm extensor supply arises from the flexor trunk. In the connection it may be mentioned, that in those cases of human abnormality, to be presently mentioned, where an extensor trunk persists beyond the elbow, this vessel gives origin to the posterior interosseous artery.

In any case, however, there can be but little doubt that in the reptilian upper limb there is but little deviation from the hypothetic primitive type.

So much having been seen in Reptilia, Mammalia next claim our attention. The domestic animals and lower mammalia do not appear to differ in any great degree from the primates, and the recent work of Bayer[1] on Apes serves exceedingly well to illustrate the points in question.

In determining homologies in apes as well as in Man, we shall be greatly guided to correct inferences in taking into account the relations of arteries to nerves, remembering that of an artery and accompanying nerve, the artery takes, as a general rule, throughout the body the most exposed course. Therefore a vessel lying superficial to either ulnar or median nerve, must be considered as ventro-appendicular, or flexor trunk. This consideration, together with that of muscular arterial supply, will be the chief criteria in deciding the point which often arises as to whether a given trunk is really flexor or not.

The varying supply in apes is of peculiar value in the present instance, for it will be seen to illustrate, firstly, "lower" formations not materially different from the primitive typical, or the reptilian arrangements; secondly, "progressive" forms which throw much light on what must in future be regarded as human atavistic abnormalities; and finally, the "higher" forms very closely resembling the normal human disposition.

[1] Bayer, *op. cit.*, *vide supra.*

In *Hapale penicillata*, the axillary artery divided into—

A. *Brachialis profunda.*

B. *Brachialis superficialis.*

Brachialis profunda has the following branches—

1. Common stem for { arteria sub-scapularis. circumflexæ humeri anterior and posterior.
2. Thoracico-dorsalis.
3. Terminates as { profunda brachii, extensor collaterales media and ulnaris. ending in

Brachialis Superficialis crosses the ulnar nerve at its exit from the axilla, and possesses the following branches:—

1. Acromial thoracic.
2. Long thoracic.
3. Branches to biceps.
4. Terminates as radial.

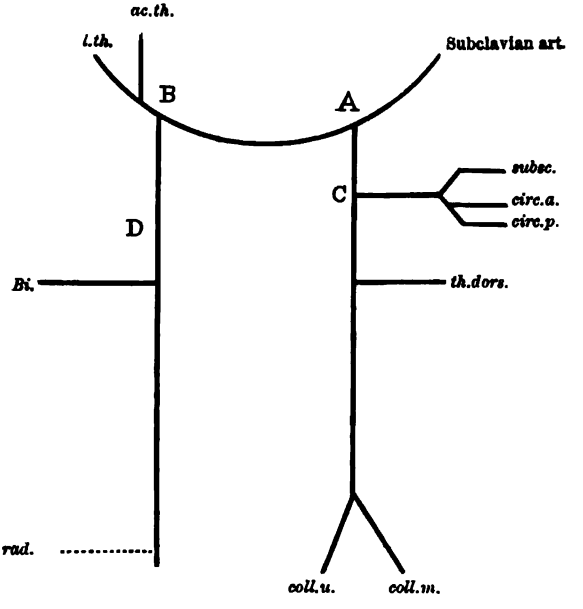

FIG. 4.—*Hapale penicillata.* Fore-limb Arteries. *ac.th.*, acromio-thoracic; *l.th.*, long thoracic; *subsc.*, sub-scapular; *circ.a.*, anterior circumflex; *circ.p.*, posterior circumflex; *th.dors.*, thoracico-dorsalis; *coll.u.*, collateralis ulnaris; *coll.m.*, collateralis media; *bi.*, branch to biceps; *rad.*, radial; A, B, D, brachialis superficialis; A, C, brachialis profunda.

This arrangement very closely resembles the primitive type, summing up in itself the forms found in reptilia.

At A (fig. 4) the axillary breaks into brachialis superficialis

A,B, and brachialis profunda A,C. This latter trunk represents the combined dorso-appendicular and extensor trunk. The first portion of the superficialis A,B represents the portion in the intercostal plan between the extensor and flexor trunks. At B the flexor trunk parts from the ventro-appendicular supply (the thoracic arteries, long thoracic, and in this case acromial

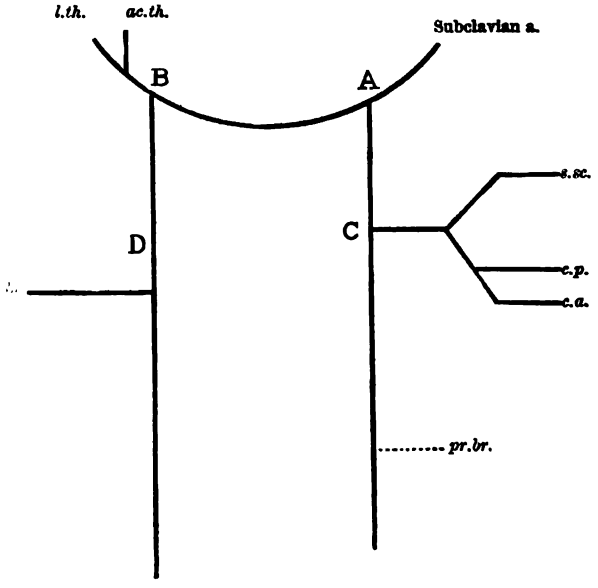

FIG. 5.—*Nictipithecus vociferans.* Fore-limb Arteries. *l.th.*, long thoracic; *a.th.*, acromio thoracic; *s.sc.*, sub-scapular; *c.p.*, posterior circumflex; *c.a.*, anterior circumflex; *pr.br.*, profunda brachii; *bi.*, branch to biceps; A,B,D, brachialis superficialis; A,C, brachialis profunda.

thoracic). So much of brachialis superficialis as lies beyond the common origin of the long and acromial thoracics is to be considered as the flexor arterial trunk.

The common trunk of origin of the sub-scapular and circumflex arteries is readily recognised as a common abnormality in Man.

Nictipithecus vociferans again exemplifies the primitive arrangement. The axillary artery divides as before into—

A. *Brachialis profunda* (embraced by the roots of the median nerve).

B. *Brachialis superficialis* (crosses the upper root of the median nerve).

Brachialis profunda branches:—

1. Common stem { sub-scapular. circumflex anterior. circumflex posterior.
2. Profunda brachii.

Brachialis superficialis branches:—

1. Common stem { acromial thoracic. long thoracic.
2. Muscular to biceps.
3. Ends as radial.

The arrangement is very similar to that of *Hapale penicillata.* The acromial thoracic now comes off by a common stem with the long thoracic.

In *Cebus hypoleucos* the formation is once more of a simple type.

Brachialis profunda branches into:—

1. Common stem { arteriæ circumflexæ. sub-scapular.
2. Profunda brachii.

The brachialis profunda having given off the profunda brachii, changes in position from lying posterior to the median nerve to a position external to the nerve. The two then pierce the supracondyloid foramen, and both come to lie on the flexor side, the continuation of the extensor artery being maintained by the downwardly directly collateralis ulnaris, given off just before the supracondyloid foramen is entered. This new formation, the supracondyloid change in position, is an important step onwards in explaining how, in the absence of a flexor brachialis in the upper arm, the forearm flexor supply comes to be supplied by a supracondyloid anastomosis from the dorsal extensor trunk.

In the present case the flexor brachialis is still present as in the primitive type. It crosses the upper root of the median nerve and divides into—

1. Pectoral and Alar branches.
2. Ends as the radial.

In one case of *Cebus hypoleucos,* described by Bayer, bra-

chialis superficialis (flexor vessel) existed only as a slender trunk, which, after giving off acromial and long thoracic branches, and supplying the upper arm flexors, anastomosed with a branch from brachialis profunda, which pierced the supracondylar foramen. So that Cebus illustrates the transition (not yet fixed) from the primitive state to the form of brachialis artery which is dorsal (extensor) till the supracondyloid foramen then by anastomosis becomes ventral (flexor).

Cebus hypoleucos illustrates, too, another point in connection with the tendency of the flexor trunk to disappear—namely, that the acromial thoracic also tends, *pari passu*, to shift its origin backward, and so we find it arising in *Cebus hypoleucos* in some

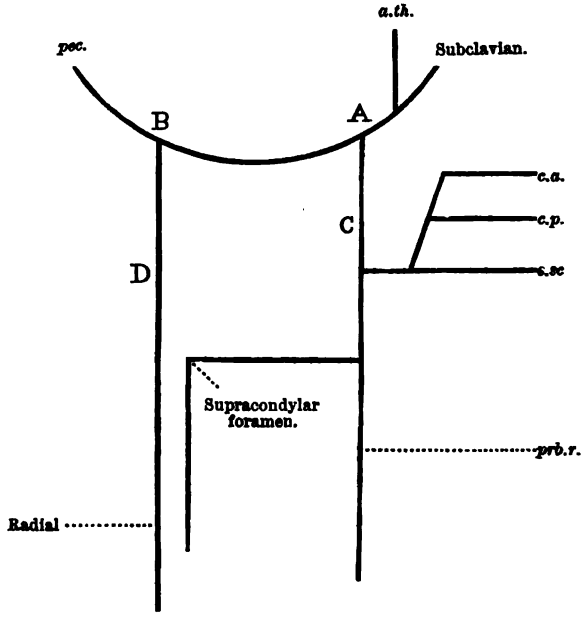

FIG. 6.—*Cebus hypoleucos* (A) Fore-limb Arteries. *a.th.*, acromio-thoracic; *pec.*, pectoral branches; *c a.*, anterior circumflex; *c.p.*, posterior circumflex; *s.sc.*, sub-scapular; *pr.br.*, profunda brachii; A,B,D, brachialis superficialis; A,C, brachialis profunda.

cases before the axillary divides into superficial and deep branches. This change in origin is strictly comparable to the occasional origin of its homologue, the obturator artery in Man, in connection with the extensor vascular supply.

Cebus capucinus and *Ateles arachnoides* mark a step in advance. The flexor brachialis trunk has now ceased to come off from the vessel "intercostal in plan." It first manifests itself just above the elbow joint, where it anastomoses with an anteriorly directed branch from the extensor trunk.

The axillary artery gives in *Ateles arachnoides*, firstly, the acromial thoracic and long thoracic by a common stem, then the circumflex common trunk is given off together with the subscapular. The artery is continued down the arm as the

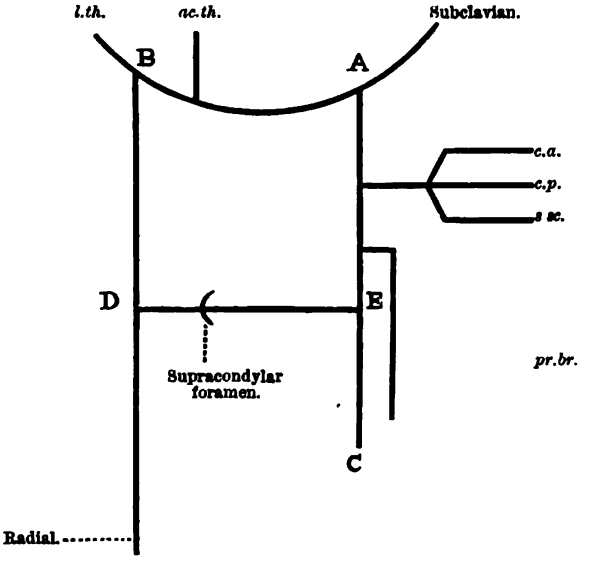

FIG. 7.—*Cebus hypoleucos* (B) Fore-limb Arteries. *ac.th.*, acromio thoracic; *l,th.*, long thoracic; *c.a.*, anterior circumflex; *c.p.*, posterior circumflex; *s.s.c.*, sub-scapular; *pr.br.*, profunda brachii; A,B,D, brachialis superficialis; A,C, brachialis profunda; D,E, anastomosis between brachialis superficialis and profunda.

brachialis, giving off at its commencement the two branches of profunda brachii. Just over the elbow joint the brachialis superficialis springs, and it is covered by the lacertus fibrosus (supracondylar process). The superficialis continues as the radial.

The interpretation of this arrangement is, then, that at A (fig. 8) the common dorso-appendicular and extensor trunk is given

off, which, after the dorso-appendicular branches are given off, is called the brachialis artery. A,B is the continuation of the artery "intercostal in plan," and ends ventrally in the ventro-appendicular trunk (common acromial thoracic and long thoracic trunk). The flexor trunk is absent until the region of the elbow is reached. This arrangement is almost identical with the normal human conformation. So far the anastomosis

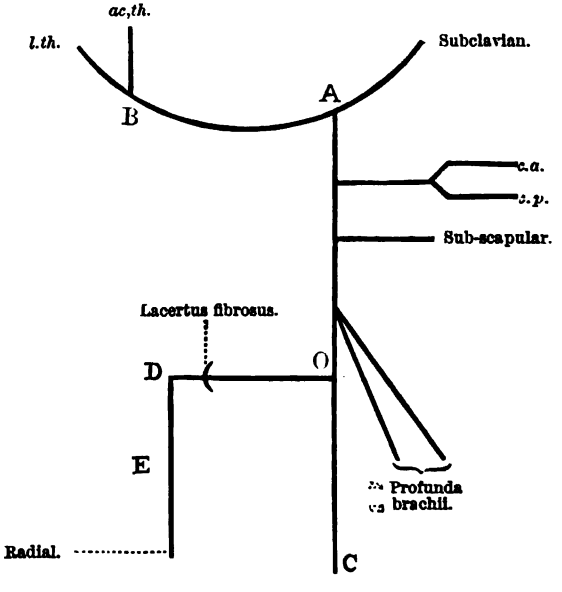

FIG. 8.—*Ateles arachnoides.* Fore-limb Arteries. *l.th.*, long thoracic; *ac.th.*, acromio-thoracic; *c.a.*, anterior circumflex; *c.p.*, posterior circumflex; A.C., brachialis profunda; O,D,E, brachialis superficialis.

between extensor and flexor trunks has been confined to the supracondylar type. But the junction is by no means confined to this region. In fact, the flexor brachialis trunk may persist for lengths varying in different animals from a state of total persistence to a state of total absence above the elbow.

In cases of high persistence the criterion whereby to determine a case of partial or total persistence is to observe whether the ventro-appendicular trunk (the long thoracic)

arises from the undivided axillary or from the brachialis superficialis. In the latter case there is total persistence, in the former partial persistence, with high flexor and extensor anastomosis.

As an instance of high persistence, in *Hapale rosalia* the flexor brachialis is found to arise from the extensor trunk at the level of latissimus dorsi tendon, the long and acromial thoracics having been given off as the first branches of the axillary, the origin of the flexor vessel being level with that of the profunda brachii.

In *Mycetes seniculus* the extensor flexor anastomosis occurs

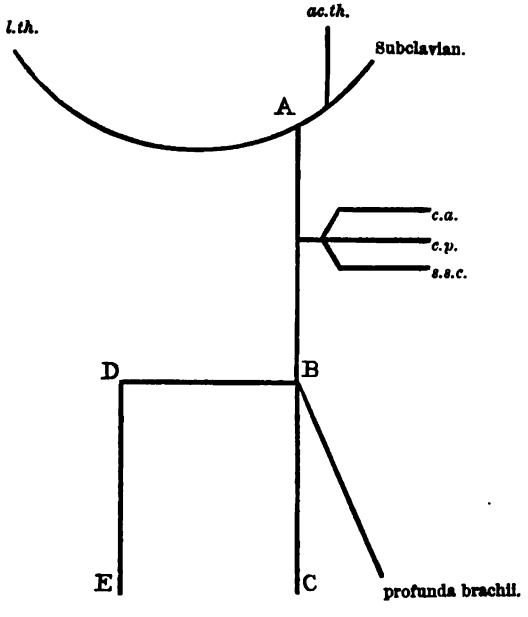

FIG. 9.—*Hapale rosalia.* Fore-limb Arteries. *ac.th.*, acromio-thoracic; *l.th.*, long thoracic; *c.a.*, anterior circumflex; *c.p.*, posterior circumflex; *s.s.c.*, subscapular; A,C, brachialis profunda; B,D,E, brachialis superficialis.

below the origin of profunda brachii at the junction of the middle and lower thirds of the elbow.

The importance of the two cases last cited is that they render possible a morphological classification of many cases of abnormality in Man known as high brachial division.

The apes then bridge over the gap between Man and the primitive type, so that the conditions, normal and abnormal,

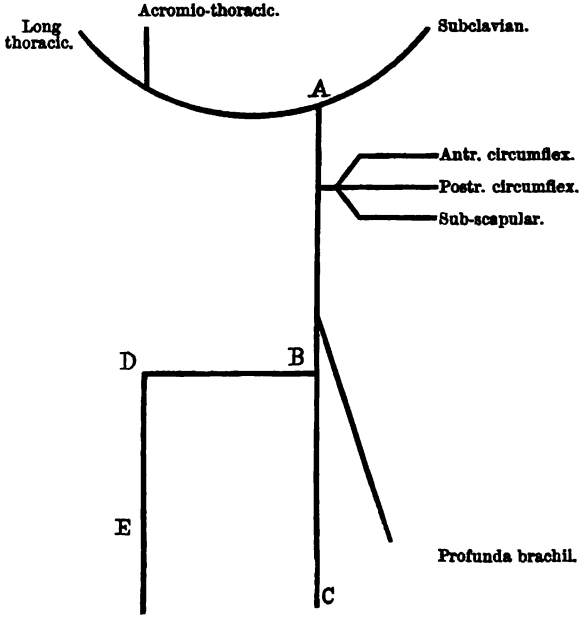

FIG. 10. — *Mycetes seniculus.* A,C, brachialis profunda; B,D,E, brachialis superficialis.

which exist in Man may now with little difficulty be readily interpreted.

THE NORMAL CONDITION IN MAN.

In Man the disposition of vessels bears very close resemblance to that of *Ateles arachnoides.* The main arrangement is the same, the difference consisting of increased development of previously described arrangements, such as the shifting dorsalwards of the acromio-thoracic and the division of the dorso-appendicular and extensor vessels into separate trunks. Both of these have been noted in the "higher" forms in the apes.

In Man the subclavian furnishes the first portion of the dorso-appendicular supply as the supra- and post-scapular vessels. The first of previously described vessels to be given off from the

axillary is the acromio-thoracic. The axillary also gives off a new ventro-appendicular vessel, the superior thoracic. Next the vessel "intercostal in plan" is given off as the long thoracic, which lies superficial to the inner cord of the brachial plexus and which gives off alar branches. These correspond to the rudimentary brachialis superficialis, and as reversion the alar trunk may enlarge into a brachialis superficialis. (Ruge, *op. cit.*) So

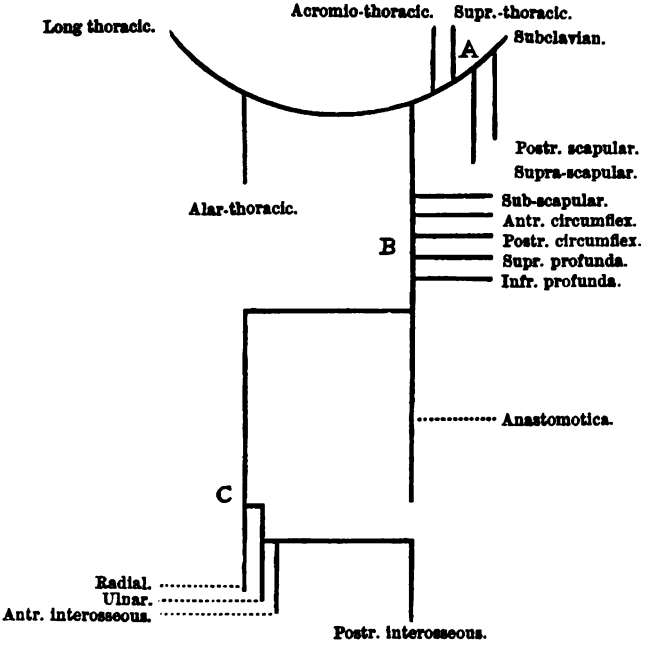

FIG. 11.—Man. Fore-limb Arteries. Normal; A, B, axillary arteries; B, C, brachial artery.

that the human long thoracic only corresponds to the simian long thoracic after the alar branches have been given off. The portion between the origin of the long thoracic from the axillary and the origin of the alar thoracic corresponds to that portion of vessel "intercostal in plan" which lies between the common dorso-appendicular-extensor trunk and the flexor trunk.

The common dorsal trunk gives off the sub-scapular and circumflexes separately, instead of, as in Hapale, by a common trunk. The profunda brachii also usually comes off by two

separate branches, though the single trunk is very common. As a separate trunk, too, an inferior ulnar collateral (anastomotica) is given off. *Ateles arachnoides* foreshadows this arrangement to some extent (see fig. 8).

Except as alar branches the ventral flexor trunk is absent along the upper arm, but reappears above the elbow joint after supracondylar junction with the brachialis profunda trunk. The brachialis superficialis at the antecubital fossa breaks up into the flexor supply for the forearm. From the deep flexor artery an anastomosis runs backwards to the persisting dorsal trunk (postr. interosseous).

Of the significance of the forearm flexor vessels very little can be definitely maintained beyond the fact that they are branches of the brachialis superficialis system. They arise normally at the elbow. Abnormally they may arise above or below this point, and in cases of high persistence of the brachialis superficialis trunk they may arise separately as high as the axilla.

Zuckerkandl[1] regards a median artery as the true continuation of the brachial. But there is something to be said for the ulnar as the true brachial vessel, for, in the first place, it forms the continuation for the flexor vessel in the *Testudo Europæa*.[2] Again, the ulnar is invariably the vessel which returns an anastomosis to the extensor trunk (to post. interosseous), and on this account is very probably the more primitive vessel. The Radial Artery is then probably the later vessel phylogenetically, and its importance is correlated with the phylogenetic accrement of muscular functions in the forearms of the mammal over those of the reptile.

Variations in Human Upper Limb Arteries.

After the preceding discussion the varieties in the arm vessels fall readily into classes of well-defined atavism, comparable in each case to simian conditions.

[1] Zuckerkandl, *Verhand. der. Anat. Gesellschaft*, Wien, June 1892. (Bardeleben.)

[2] Bojanus, *op. cit.*

I. *Varieties of the Dorsal Trunk.*

A. Those which are due to fusions of two or more of the dorsal trunk branches, so simulating the arrangement in apes. The following arrangements are the most common :—

(*a*) Fusion of the anterior and posterior circumflex trunks (cp. *Ateles arachnoides*, fig. 8).

(*b*) Fusion of the sub-scapular and anterior and posterior circumflex trunks. (Cp. *Cebus hypoleucos*, figs. 6 and 7.)

(*c*) Fusion of the profunda trunks—origin of the inferior profunda from superior profunda. (Cp. *Hapale penicillata*, fig. 4.)

(*d*) Fusion of the profunda with one of the higher trunks, usually the posterior circumflex trunk.

B. The extensor trunk continues beyond the elbow, giving rise to the common interosseous trunk, or forming a second infra-cubital anastomosis with the flexor trunk.

C. In cases of high persistence of flexor brachialis, the brachialis profunda may become a fine twig in the lower part of the arm. In such cases the brachialis superficialis reasserts itself and forms a pre-supracondylar brachialis artery.

II. The main interest of the present discussion, however, is centred around persistences, partial or total, of the archaic flexor trunk. As such are to be explained a series of indefinitely classified irregularities known as

Collateral vessels (Ruge).
Vasa Aberrantia.
High brachial divisions.
Insular formations (*Inselbildungen*, Ruge).
Pre-supracondylar brachials.

The Vasa Aberrantia, high brachial divisions, and the pre- and post-supracondylar arrangements have especially been the source of much speculation. The various forms of vassa aberrantia, (Collateralstämme, Ruge), have been recognised as not all possessing the same morphological value. The position now is, that

some definite statement can be made as to the nature of the differences observed.

The varieties due to the flexor trunk are then—

A. *Cases of total persistence.*

Instances of this class are, as one might expect from their primitive nature, of very rare occurrence. Remembering the primitive plan, they will be recognised as those cases in which a brachial artery is given off very high in the axilla—in fact, these cases are the forms of *highest brachial division;* and moreover, such a vessel must give off the ventro-appendicular supply in the form of the long thoracic artery.

A case of this form is described by Henle and quoted by Testut. The long thoracic artery in this case gave off a brachial artery, which descended the arm to become the ulnar below the elbow. In R. Quain's Plates, No. 30, fig. 2, a similar condition is figured.

In the normal state this branch (which in the variety under consideration becomes a complete brachialis superficialis) is retained as a very small twig supplying branches to the pectoralis and axillary glands. It is known as the alar thoracic —a normally described branch of the long thoracic. In its enlargement, then, the primitive form of brachialis superficialis is retained. In addition to Henle's case just cited, Ruge has mention of the same form of abnormality, as arising above the median nerve plexus "das Entstehen des Collateral-stammes proximal von der normal in der Achselhöhle gelagerten Schlinge des Nervus Medianus." (Ruge, *op. cit.*, 370, 371.) This highest form of brachial division is comparable with the supply in *Hapale penicillata* (see fig. 4). And by way of confirmation of the present theory, it must be mentioned that no case is described in which a flexor brachialis artery has originated from the axillary above the long thoracic.

B. *Cases of Partial Persistence of the Flexor Trunk.*

(a) *Retention of the Proximal Portion.*

This forms a class of variety very similar to the last, differing in fact only from it by being a much shorter vessel, extending

for a small distance (one-fourth; Ruge, *op. cit.*, 371) down the arm. In the phraseology of the text-books it would be described as an enlarged alar branch of the long thoracic artery.

(b) *Retention of the Distal Portion.*

Such cases embrace, with those described under section A. of flexor variations, the pre-supracondylar forms of brachial artery, and these may become vicarious for the normal post-supracondylar brachialis. As we have already seen in the apes, the partial distal persistence may originate by anastomosis with the extensor brachialis trunk at various levels, so that this mode of partial retention may be classified according to the spot at which the anastomosis occurs.

1. *Axillary Anastomosis.*—This occurs in those high forms of flexor brachialis which arise in the axilla after the long thoracic is given off, and before the profunda branches are given off. (Cp. *Hapale rosalia*, fig. 4.)
2. *Humeral Anastomosis* occurs in cases where the brachialis superficialis originates below the point of issue of the profunda vessels. (Cp. *Mycetes seniculus*, fig. 10.)
3. The formation of any such high anastomosis does not preclude the existence of the normal supracondylar anastomosis, so that in the several forms of variety known as Inselbildung (Ruge, *vide supra*) the condition found is one in which there is a high or low pre-supracondylar brachialis superficialis (flexor trunk), with a concomitant persistence of the normal supracondylar branch. This explains in a very simple manner what has heretofore formed one of the most unintelligible of varieties—the *insular formation.*

(c) In cases of high flexor trunks the vessel may continue, apparently without rule, into radial or ulnar, or both. Where the flexor persistence continues into one vessel only, the other vessel is supplied by the normal supracondylar anastomosis.

The significance of this point is, then, to support what was

previously indicated—namely, that beyond forming arteries on the flexor side, the radial and ulnar appear to possess little additional morphological value.

Having classed the forms of abnormality in the upper limb, it remains, before proceeding to consider the lower limb, to state, that so far from the cases mentioned occurring singly in a given specimen, that several forms may, and often do, occur simultaneously, and so give rise to very complex systems. As an instance, in Quain's Plates, No. 32, fig. 1, is figured the simultaneous occurrence of axillary anastomotic persistence of brachialis superficialis, together with fusion of the sub-scapular and posterior circumflex trunks. In Plate 30, fig. 2, of the same work, there is a total persistence of the flexor trunk giving off the acromial and long thoracics as in *Hapale penicillata*. This is complicated by an Inselbildung due to anastomosis at the elbow between the flexor and extensor trunks.

Lower Limb Arteries.

After reducing the upper limb supply to the form or derivation from some primitive intercostal type, the corresponding problem to meet the case of the lower limb offers no obstacle.

In any consideration of the lower-limb vessels, it must be borne in mind that even from *a priori* morphological knowledge, the usual division by descriptive anatomists of the common iliac artery into external and internal is anything but a scientific conception.

The first division given off from the common iliac—the external iliac—is a trunk of single function, the combined dorso-appendicular and extensor trunk of the thigh.

The internal iliac is a vessel of double function, and its division into two trunks—posterior and anterior—goes far to confirm this view. The posterior trunk comprises the gluteal ilio-lumbar and lateral-sacral arteries—that is to say, those vessels arising from the trunk "intercostal in plan," which supply the spinal cord, dorsal muscle plates, and part of the dorso-appendicular musculature.

In other words, the posterior trunk is to be regarded as standing in closer relation to the external iliac than to the

remainder of the internal iliac, and corresponding in fact to the retro-costal portion of an intercostal artery.

Then as far as the limbs are concerned, the external iliac and gluteal, which arise first from the trunk "intercostal in plan," are to be regarded as the combined dorso-appendicular and extensor supply. In support of this view it is only necessary to cite the very interesting case of abnormality quoted in Quain and Testut, in which the gluteal artery arose from the femoral and passed outwards and backwards to reach the gluteal muscles (F. T. Roberts, *Liverpool Medical and Surgical Reports*, 1867).

That portion of the internal iliac between the origin of the gluteal and the origin of the sciatic, forms the lateral position of the vessel "intercostal in plan" which lies between the extensor

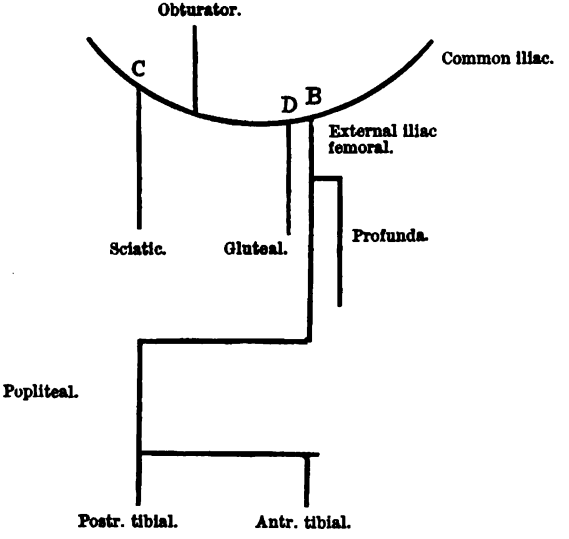

FIG. 12. Man. Arteries of lower limb, Normal. B,C, internal iliac; D, internal iliac splits into anterior and posterior divisions.

and flexor trunks. From this portion the obturator branch arises (*cp.* Acrom. thoracic, fig. 8, *Ateles arachnoides*). The sciatic forms a rudimentary flexor trunk, and corresponds to the enlarged alar thoracic vessel in the anomaly of the highest form of brachial division in Man. In *Testudo Europæa* (Bojanus, *op. cit.*) the

sciatic artery maintains its primitive function, and is found as the main flexor trunk, a condition found as a variety in the human subject, and comparable with the total persistence of the flexor trunk in the upper limb. The limb branches of the external iliac and femoral correspond as a whole to the circumflexes and profunda vessels of the arm, the gluteal simulating the subscapular. The superficial femoralis continues as extensor trunk in the anastomotica, after having fulfilled the condition similar to that of its homologue in the arm of furnishing, by anastomosis, the continuation of the flexor trunk in the form of the popliteal. The perforation of adductor magnus tendon corresponds to the piercing of the internal intermuscular septum in the arm (in which are found as abnormalities fibres of the third portion of the arm adductor coraco-brachialis). The popliteal continuation of the femoral corresponds to the antecubital continuation of the normal extensor post-supracondylar brachial, and this statement holds independently of any specific view as to the morphological nature of the supracondylar process.

The popliteal resembles the antecubital vessel in furnishing an anastomosis to the extensor side by which the extensor vessel persists in the form of the anterior tibial (*cp.* postr. interosseous). See fig. 12.

The Obturator and Acromial thoracic arteries demand conjoint consideration, from the many similarities they present, and from the light they throw on each other. In each case they supply homologous musculature, *i.e.*, those portions of the limb outgrowth where dorso- and ventro-appendicular elements come into contact superiorly: Pectoralis and Deltoid in the one case; Adductors and outward rotators in the other. In this may be found some explanation of the indifference of origin of either artery from the dorsal or ventral end of the vessel "intercostal in plan," for although the acromial thoracic is pretty constantly dorso-appendicular in origin in Man, yet in apes we have seen its origin varies from the extreme dorsal to the extreme ventral end; and here the tendency seems, for the more primitive forms, to yield a ventral acromial thoracic, while, with retrogression of the ventral supply, the acromial thoracic gradually takes up a dorsal position.

The extensor origin of obturator artery may, then, be attribut-

able to a similar retrogression of the ventral trunk. In *Testudo Europæa* the obturator is a large ventro-appendicular vessel. So that the cases of obturator originating from the extensor trunk may best be regarded as new formations consequent on the phylogenetic diminution of vessels on the flexor side of the thigh.

General considerations.

Having now reduced the arterial systems in limbs to something approaching a definite morphological basis, it becomes possible to review in summary the results made evident. In the first place, as far down the vertebrate scale as Reptilia, we can safely assert that there is no need for the supposition that the existing arterial systems are the result of mechanical operation of pressure upon a primary anastomosing vascular rete. One is only too eager to recognise the importance of mechanical factors as determining causes of the higher formations; but the view one would advance is rather that these factors have exerted themselves on two primitive sets of vessels—a dorso-appendicular-extensor, and a ventro-appendicular-flexor, arising from a primitive vessel "*intercostal in plan.*"

Whether each of these sets is primitively a single trunk or not it is premature to maintain, and is not essential to the integrity of the plan. In fact, the existence of gluteal and external iliac trunks, and of supra-scapular, post-scapular, and axillary-brachial trunks in Man, and of the "mehrere arteriæ thoracicæ" in crocodiles, Bronn[1], indicates that each set in either case is probably not single. Yet this is very different from postulating a haphazard network as the archaic limb supply.

In the case of the supply in each limb we obtain a clear insight into the morphological sphere of each of the larger vessels in either limb; and as shown above, the vascular varieties receive a simple explanation, and moreover a tangible classification. To some extent speculations as to whether, for instance, Inselbildung is due to splitting of the brachialis or to anastomotic development (Ruge, *op. cit.*, p. 360), or whether high or low brachial divisions are possibly due to a tendency to division upwards or

[1] Bronn-Hoffmann, *op. cit.*

downwards from the middle of the arm (Bayer, *op. cit.*, p. 28), will, it is trusted, be allayed.

Not the least value of the present discussion lies in the fact that from their aortic origin it becomes possible to compare the vessels of each limb homologically.

In each case it must be remembered that the homology limits itself to the limb supply. A further constraint is imposed on any system of homology by the fact that the analogy is homodynamic, and therefore possesses a value but secondary.

With these limitations, then, one may venture to state that of the iliac branches the external iliac and gluteal correspond to the axillary (after the long thoracic has been given off), together with the supra- and post-scapularis. The lateral portion of the arch "intercostal in plan" in the upper limb corresponds to the portion of long thoracic as far as the alar issue; in the lower limb the portion between the posterior trunk and the issue of the sciatic from the anterior trunk. The sciatic then corresponds to the alar, or rather to that form of alar above described as partial proximal persistence of the ventral trunk. The gluteal furnishes what most closely resembles the sub-scapular supply (*cp.* Macalister: *Human Anatomy*, p. 500), and the deep circumflex iliac to the supra- and post-scapularis. As to the arrangement of the other vessels, as far as homology is of any value, the superficial femoral giving off a dorsal branch (anastomotica) just before the anastomotic continuation to the flexor side would appear not to be a vas aberrans (*cp.* Macalister, *loc. cit.*), but rather of extensor nature, and so would correspond with the normal human brachialis in forming extensor supply as far as Hunter's canal, whereas the vas aberrans (Collateralstamm) has been shown to be ventral in origin.

The Profunda femoris seems to correspond to a combined circumflex and profunda supply of the arm, rather than to the brachialis. In this case the external circumflex is the equivalent of the posterior circumflex and superior profunda, whilst in the internal circumflex we have the homologue of the anterior circumflex. The continuation of the profunda trunk finds its analogy in the inferior profunda of the upper arm. The Obturator artery has been already considered. As to the vessel

homology in the leg, the plan before us is in concordance with the arrangement described by Macalister (Macalister, *op. cit.*, pp. 500 and 505). See also fig. 12.

With the question of vascular homology the present discussion closes; and in conclusion, I beg to offer my warmest thanks to Professor Macalister and Dr Hans Gadow, by whose help I was enabled to consult the literature necessary for the exposition of my plan.

ON AN ARROW-POISON FROM NEW GRANADA, AND ON ITS BOTANICAL SOURCE. By JOSEPH TILLIE, M.D., *Senior Assistant to the Professor of Materia Medica in the University of Edinburgh.*

PROFESSOR SIR WILLIAM TURNER lately handed to me for examination a gourd containing a quantity of the South American arrow-poison, Curara, and also several small pieces of stem, and a twig with leaves of plants said to be used to prepare the poison.

The specimens have been in Professor Sir William Turner's possession since 1863. They were brought to this country in that year by Dr James Whiteford, of Greenock, who resided in New Granada for several years, and had been requested by the late Sir Robert Christison to obtain information about the arrow-poisons of the country. I am indebted to Dr Whiteford for the following information regarding the locality. Both the poison (which was stated to be prepared only from climbing plants) and the botanical specimens were obtained in 1862 from the chief of a branch of the Rio Verde tribe of Indians, at a village named Musinga, situated about 50 to 60 miles to the west of the city of Antioquia, between the watersheds of the rivers Cauca and Atrato, in about 76° 36′ W. long., and 6° 40′ N. lat.

The poison is specially interesting, because it comes from the north-west of New Granada (Colombia), and we know nothing definite regarding the botanical sources of the poisons with which the darts used for the blow-pipe in these regions are smeared; nor, I believe, has the physiological action of any plant reputed to be a source of the poison been examined.

The pieces of stem are of two kinds, which differ considerably in size and external appearance.

One of the two pieces of stem is 6 cm. long and 1·5 cm. broad. The outer surface is greyish-brown, mottled here and there with irregular patches of ash-grey colour, and sparsely studded with wart-like projections, about 1 mm. high, and 1–2 mm. broad. Several large shallow longitudinal furrows extend the whole length of the stem, producing a slightly undulating

surface. Numerous small irregularly longitudinal furrows render the general surface finely rugose. The bark is only about 0·5 mm. thick. It shows under the lens three layers. The middle layer is pale, granular, and about 1½ time thicker than the layers which bound it, and which are conspicuous by their reddish-yellow colour. The bark is easily separable, and the surface next the wood is pale grey, and has, to the naked eye, the appearance of fine longitudinal striation. A transverse section of the bark shows under the microscope (1) a relatively thick exterior (suberous) zone, the outer cells deeply coloured yellowish-red, the inner only slightly coloured, and nearly rectangular in form. (2) A relatively thin (parenchymatous) layer of longitudinally arranged cells coloured reddish-yellow. (3) A very broad (sclerenchymatous) zone of large colourless polygonal irregularly-arranged thick-walled cells. (4) A relatively thin inmost (liber) layer, coloured reddish-yellow. The relative breadth of the layers is approximately, from without inwards, 3·5, 1, 6, 2·5. The wood has a diameter of 1·3 cm.; and an empty medullary canal, having a diameter of 4 mm., occupies a point nearly in the centre of the section. A sharply cut section shows a very large number of small openings, with here and there a large lacuna. The wood near the bark contains the largest number of openings, and they diminish greatly in size and number towards the medullary canal. The wood, especially near the medullary canal, shows numerous narrow unbroken streaks of a different shade from the pale-greyish ground tissue. The narrow streaks separate the ground tissue into relatively broad pale streaks, pierced by numerous openings, the different coloured streaks forming alternate layers arranged tangentially.

A second piece of stem (of which there were 3 similar pieces) is 7 cm. long, and 2·2 cm. broad. It is slightly curved, and the outer surface is of a dark rust colour, and shows no grey patches or wart-like projections. It has the shallow longitudinal furrows already described, but also a few deep transverse furrows on the side towards which it curves. The general surface is wavy, but is not covered by fine furrows, and, except for a very few flaky patches, the furrows and rounded ridges are smooth rather. The bark is only about 1 mm. thick, and the three layers previously described are ill-defined, owing to the small

amount of colouring-matter in the layer next the wood, which, however, is as broad as the other layers 1, 2, and 3 combined. The relatively narrow sclerenchymatous zone is also separated into two parts by an intermediate layer of cells resembling the inmost layer. The medullary canal is practically obliterated, and is excentric in position. The pale-grey coloured wood shows numerous small openings, and the large lacunæ are scattered equally over the whole section. The tangential arrangement of medullary rays and openings is seen under the lens, and a few irregular strips of tissue, passing here and there circumferentially, give a deceptive appearance of annual layers.

The twig is cylindroid; thornless; slightly furrowed longitudinally; pale green; branches opposite; the bases of the branches relatively thick from the persistence of the attachments of the petioles, and the finest branches covered with short brownish downy hairs, just visible to the naked eye. The leaves are opposite and without stipules. The petioles are 2 mm. long, and the largest leaves, of which there are five, have an extreme length of 10·4 cm., and an extreme breadth of 4·1 cm.; the smallest is 3 cm. long and 1·6 cm. broad; and the intermediate sizes average 5 cm. long and 2·8 cm. broad. The larger leaves are elliptical, with the base acute; the smaller sizes are ovate-elliptical; apices acuminate; margins perfectly entire and sparsely ciliated; membranous; upper surface light green, and under surface a paler green; glabrous on both surfaces, but veins on under surface are somewhat downy, especially the midrib; veins prominent on the under surface, and of a reddish-brown colour; prominently 3- but also less distinctly 5-nerved; a strongly marked midrib gives of at its extreme base two very fine, but in the smaller leaves sometimes very distinct, wavy veins, which follow the margin of the leaf at a distance of about 1 mm., but become faintly marked near its apex; two strongly marked veins arise opposite or almost opposite each other about 2 mm. above the base, and follow the margin of the leaf at a distance of about 5 mm., and run into the apex at its margin. Secondary veins, which are fairly well marked on the under surface of the leaf, pass almost transversely from the primary veins and from a network.

All the specimens, therefore, must be referred to the genus

Strychnos; but it is not known that the leafy twig was taken from either of the plants from which the pieces of stem were taken. In view of this circumstance, the absence of flowers and fruit, and the fact that the bark and wood of *Strychnos* plants often show, on microscopical examination, only relatively slight quantitative differences, the evidence is insufficient for the precise recognition of species.

The first described piece of stem resembles that of *Strychnos Gubleri* (Planch.),[1] the second that of *Strychnos toxifera* (Schomb.),[2] but the bark differs.

Some one or more of the characters of the twig and leaves—the downy hairs, absence of thorns, ciliated leaf margin, &c.—seem to distinguish the specimen from *Strychnos Hachensis*[3] (Krst.) (Venezuela); and also from plants known to be sources of the curara of other regions:—*S. Castelnæana*,[4] Wedd. (West Brazilian Guiana and Upper Amazon); *S. Gubleri*, Planch. (Venezuelan Guiana, Upper Orinoco); *S. toxifera*, Schomb. (British Guiana, Upper Essequibo); *S. Crevauxii*, Planch. (East Brazilian Guiana, Upper Paru), &c. It presents a very close resemblance to the *bejuco de Mavacure*, a *Strychnos* plant yielding the curara of the Upper Orinoco districts, collected by Humboldt and Bonpland[5] at Esmeraldas in Venezuelan Guiana at the beginning of the century, and described by Kunth, who inclined at that time to think that it was allied to, or the same as, the *Rouhamon Guyanense* of Aublet.[6] It is unfortunate that this historical plant, the first which was botanically recognised as the source of curara, is not precisely identified and named. It was later described by Kunth[7] as *Lasiostoma* (?) *Curare*, and by De Candolle[8] as *Rouhamon* (?) *Curare*. Planchon is of opinion, from an examination of Humboldt's specimens, that they do not agree with *R. Guyanense*. I notice

[1] *Comptes Rend.*, Jan. 19, 1880; *Journ. de Pharm. et de Chim.* [5], i. 293.

[2] Hooker, *Bot. Journ.*, iii. 240. [3] Karsten's *Flora Columbiæ*, vol. ii. p. 75.

[4] The literature and descriptions of the Curara-yielding Strychnos plants is collected by Planchon in a series of papers in the *Journ. de Pharm. et de Chim.* [5], vol. i. p. 19 *et seq.*, translated in the *Pharm. Journ. and Transac.*, 1880–1, 3rd Series, vol. xi. pp. 469, 492, 529, 589, 693, 754.

[5] *Voyage aux Régions Équinoxiales du Nouveau Continent*, Paris, 1814, T. ii. p. 549.

[6] *Hist. des Plantes de la Guiane Française*, 1775, vol. i. p. 94, pl. 36.

[7] *Nov. Gen. et Spec. Plant. Americ.*, vol. vii. p. 210. [8] *Prodromus*, ix. p. 17.

in Humboldt's work[1] that the similarity is only admitted apparently under the impression—"car les véritables Strychnos paroissent appartenir exclusivement aux Indes Orientales." On examining the representation in Aublet's work, I find that the shape and venation of the leaf (especially the secondary veins) are different in the specimen which I have described.

I have compared the specimens with the *Strychnos* plants in the Herbarium of the Royal Botanic Gardens of Edinburgh, but they do not correspond with any of them. On sending the specimens to the Royal Gardens at Kew, I learned, through the kindness of Mr Hemsley, that one of the specimens was identical with an unknown (flowerless) species of *Strychnos* collected by Jervise in New Granada.

The second bark which was described yielded to rectified and proof spirit 19·3 per cent. of a dark brownish-red extract in the form of a varnish, which was for the most part soluble in water. The solution was of a deep brownish-red colour, slightly acid in reaction, and distinctly bitter. The watery extract has the same characters.

The curara is almost black in colour, odourless, brittle, and easily powdered. It dissolves in water, leaving a slight residue. A 2 per cent. solution is dark red in colour, somewhat bitter, and has a slightly acid reaction. The physical characters of the curara are not opposed to the conclusion that it has been prepared from this bark.

On testing the pharmacological action of the watery and alcohol extracts obtained from both barks, I found the primary and only prominent action in brainless frogs to be a paralysing one upon the endings of the motor nerves. The curara from the gourd possessed, in small doses, a precisely similar action. The minimum dose which produced complete motor paralysis in the frog (R. temporaria) was found to be as follows:—

For the curara, . . .	0·000024 gramme per gramme weight of frog.
For the combined watery and alcohol extracts from the second bark which was described, .	0·000058 gramme per gramme weight of frog.

The extract of this bark has therefore less than half the

[1] *Loc. cit.*

poisonous activity of the curara, into the composition of which, as in the case of the curara of British Guiana,[1] several *Strychnos* plants probably enter.

The small quantity of extract of bark available did not allow of any further special examination. After the outer surface of the wood had been carefully filed to remove any traces of bark, it was found that the alcohol and watery extracts of the wood had, in the frog, no obvious pharmacological action in doses about 100 times greater than the paralysing dose of the extract of the bark.

A piece of the curara, or a few drops of a very concentrated solution, when applied to the cut surface of the spinal cord of a decapitated frog whose circulation had been arrested, produced no signs of local irritation, and after about 30 minutes the hitherto motionless animal exhibited feeble spontaneous and reflex spasms, partly tetanic and partly clonic. In a previous communication[2] I have shown that, when certain fallacies are guarded against, all curara specimens which paralyse the endings of motor, produce tetanus in large doses. This curara has only about $\frac{1}{80}$th of the paralysing and tetanising activity of the pure alkaloid, curarine. It is interesting to find that the same pharmacological actions are produced by the curara of the whole of the north of South America, and that it is obtained from plants of the same genus. New Granada has hitherto been the exception, as the only knowledge we possessed of its arrow-poisons was obtained nearly thirty-five years ago (shortly before the specimens which I have described were collected) by Hammond and Weir Mitchell,[3] who found that two poisons of unknown botanical origin, named Corroval and Vao, obtained from the Rio Darien, caused death by paralysing the heart, and, contrary to all other known curara, did not act upon the motor nerves. That cardiac poisons may also, however, enter into the composition of curara which acts upon the motor nerves is certain, since Boehm[4] has separated from some Venezuelan curara having the ordinary action an alkaloid which he has named Curine, and which I have found[5] to cause death by acting upon the heart.

[1] Reisen in *Brit. Guiana. Schomburgk*, 1840–41, p. 450.
[2] *Journ. Anat. and Physiol.*, 1889, vol. xxiv. p. 381.
[3] *Amer. Journ. Med. Sci.*, vol. xxxviii., Philadelphia, 1859, p. 25.
[4] *Chemische studien über das Curare*, Leipzig, 1886.
[5] *Op. cit.*, vol. xxv. p. 53.

THE ADDUCTOR MUSCLES OF THE THUMB AND GREAT TOE.

By DAVID HEPBURN, M.D., F.R.S.E., *Senior Demonstrator of Anatomy, University of Edinburgh.*

UNDER a title similar to the above, Professor Leboucq,[1] of Ghent, to whom I am indebted for a copy of his memoir, discusses the homologies of the adductor group of muscles in the thumb and great toe of Man. He records and figures a case in which the adductor muscle of the thumb of an adult man presented three distinct fasciculi, viz. :—

I. Carpal fasciculus—(Adductor obliquus).
II. Metacarpal fasciculus—(Adductor transversus).
III. Aponeurotic fasciculus.

In his figure, the metacarpal fasciculus is represented as subdivided into proximal and distal portions, of which the former is in close proximity to the adductor obliquus, while the latter is close to and partly overlapped by the aponeurotic fasciculus.

This condition of the adductor transversus pollicis is one which has come under my notice in the dissecting-room; but I have not seen what Leboucq describes as the aponeurotic fasciculus.

In the hand in which he found it,

"Une bandelette musculaire transversale passe superficiellement devant le chef inséré sur le métacarpien III et s'insère sur le ligament glénoïdien des articulations métacarpo-phalangiennes 3, 4 et 5, se continuant par son bord proximal avec l'aponévrose interosseuse."

This slip was inserted with the adductor, and Leboucq suggests that it be called Transversus manûs. This anomalous arrangement is not represented by any parallel condition among the hands of the anthropoid apes, so far as I have examined them.[2] On the other hand, there is always a tendency for the adductor transversus to become subdivided into proximal and distal portions, and in the Gorilla which I dissected this muscle had

[1] Leboucq, "Les Muscles Adducteurs du Pouce et du Gros Orteil," *Acad. Roy. de Med. de Belgique*, 1893.

[2] "Comparative Anatomy of the Muscles and Nerves of Anthropoid Apes," Hepburn, *Jour. Anat. and Phys.*, vol. xxvi.

fibres of origin from the palmar surface of the distal third of the shaft of the 2nd metacarpal bone, as well as from the palmar aspect of the proximal half of the 3rd metacarpal bone.

In the latter half of his paper Professor Leboucq records the results of his dissection of the foot of a chimpanzee. He interprets his dissection as showing that the adductor hallucis consists of three parts, which he distinguishes as follows:—

I. Adductor obliquus hallucis.
II. Contrahens I. (Transversus pedis.)
III. Adductor transversus hallucis.

Contrahens I is described as a large triangular lamella, whose origin extended from the sheath of the peroneus longus to the metatarso phalangeal articulation of the third and fourth metatarsal bones. Adductor transversus hallucis is situated at the distal border, and partly under cover of the preceding muscle. It arises by two slips from the plantar aspects of the distal ends of the second and third metatarsal bones.

Other observers have hitherto regarded the term adductor transversus hallucis as embracing the two portions here referred to by Leboucq under separate names.

In thus indicating at some length the principal features of a highly interesting paper brought specially under my notice by its author, who has also been good enough to refer to my published work in connection with these muscles among the anthropoid apes, I wish to point out that he says, in reference to the distinction which he makes between *Contrahens I* and *adductor transversus hallucis*,

"Il y a plusieurs observations présentant toutes les garanties d'exactitude dans lesquelles il n'est ni mentionné ni figuré."

Now it is quite true that I have not used the two names employed by Professor Leboucq in describing the muscular mass under consideration, but in my paper it will be seen that the adductor transversus hallucis was regarded as the distal segment of the great Contrahens, viz., the first, and that in all the apes I dissected its origin consisted of two parts. One of these arose from an aponeurotic raphé, extending from the tarsus to the metatarso-phalangeal joint of the third metatarsal bone, and the other consisted of slips which arose "from the heads of the

second and third, sometimes also the fourth, metatarsal bones, close to their articulation with the phalanges." Further, in Plate IX. both of these origins are indicated, although not distinguished by separate names.

Founding upon his observations and dissections, Professor Leboucq concludes, *loc. cit.*,—

(1) That the adductor obliquus pollicis is the homologue of the adductor obliquus hallucis.

(2) That the adductor transversus pollicis of Man is homologous with what he himself calls adductor transversus hallucis in the Chimpanzee, and which he maintains is, in its turn, represented in Man by a small slip—occurring in five per cent. of cases, and not always muscular—extending obliquely from the plantar aspect of the distal third of the second metatarsal bone, to be attached by a tendon to the peroneal side of the first metatarso-phalangeal joint, under cover of the transversus pedis.

(3) That the rare and abnormal transversus manûs is homologous with transversus pedis of Man, which, in its turn, corresponds to what he describes in the Chimpanzee as Contrahens I.

There can be no doubt regarding the ability and ingenuity with which Professor Leboucq has interpreted his facts; still it is open to discussion how far he is justified in placing the transversus pedis as the homologue of an avowedly rare abnormality, such as transversus manûs, especially as the latter is nowhere represented among the anthropoid apes.

Again, in the Gorilla, adductor transversus pollicis undoubtedly shows a tendency to become segmented, so as to form an attachment to the second as well as to the third metacarpal bones. Now, this muscle has been regarded as homologous with the adductor transversus hallucis of former observers, who looked upon the latter muscle as taking attachment to the heads of the second and third metatarsal bones, in virtue of its similar tendency to become segmented; and further, the adductor transversus hallucis of the apes has been considered to be homologous with the transversus pedis of Man, by reason of the well-known association of the latter with the second, third, and fourth metatarsal bones.

SOME OBSERVATIONS ON THE TEMPORAL BONE, CHIEFLY IN CHILDHOOD. By J. JACKSON CLARKE, M.B.

(Read before the Anatomical Society, February 1893.)

IT is with great diffidence I put before the Society some of the results of a piece of work interrupted by many pressing duties, and undertaken more with the view of preparing myself for the responsibilities of a surgeon than as a study of pure anatomy. Still I feel it may be of use to some who are working in the same field, and so I bring it before the Society, though conscious of its many defects. Of the latter, one of the gravest is a neglect to keep a record of the sex of all the subjects from which the bones were taken.

The general features of the stages of development of the temporal bone have been given by Dr Symington in his classical work on the Anatomy of the Child, so that I shall limit my observations to the points of interest in operations on the mastoid region.

The directions given by Barker, Birmingham, and others for opening the mastoid antrum are sufficient for practical purposes. I shall, however, venture to suggest a more precise definition of the term, "posterior border of the meatus." This part of the temporal bone is a curved surface, and therefore it is difficult to convey a definite meaning. If the posterior extremity of the tympanic bone be taken as the lower limit of this border, and its upper limit be fixed by the supra-meatal spine, which is always present in adults, and usually in children over 5, I think a better idea is given.

The tabulated series of observations which accompanies this paper shows that in infants and in most children a point ¼ in. vertically above the postero-superior angle of the tympanic bone is immediately over the best part of the antrum at which to begin the process of removing its outer wall. In adults a simpler guide is almost always to be found in the little depression

Age.	Thickness of the Outer Wall of the Antrum or of Accessory Air-cells.	Thickness of Bone between Antrum and Lateral Sinus.	Vertical distance above Posterior and Superior Point of Tympanic Bone from best spot for opening Antrum.	Other Features.
3 weeks, . . .	note-paper	$\frac{4}{16}$ in.	$\frac{1}{4}$ in.	
3 weeks, . . .	,,	$\frac{6}{16}$ in.	$\frac{1}{4}$ in.	
1 mo., ...	,,	$\frac{2}{16}$ in.	$\frac{1}{4}$ in.	
1 yr. (male), . .	$\frac{1}{32}$ in.	$\frac{1}{4}$ in.	$\frac{1}{4}$ in.	Foramen in tympanic bone nearly completed.
1 yr. (male), . .	...	$\frac{1}{4}$ in.	$\frac{3}{16}$ in. ($\frac{1}{4}$ in. safe)	
1 yr. (female), .	...	...	$\frac{1}{4}$ in.	
1 yr. 4 mos., . .	$\frac{1}{8}$ in.	$\frac{1}{8}$ in.	$\frac{1}{4}$ in.	Foramen in tympanic bone not quite completed.
$1\frac{1}{2}$ yr., ...	$\frac{3}{32}$ in.	$\frac{1}{8}$ in.	$\frac{1}{4}$ in.	
1 yr. 10 mos., .	$\frac{3}{32}$ in.	$\frac{3}{8}$ in.	$\frac{1}{4}$ in.	Tympanic foramen. Small spine.
2 yrs., ...	$\frac{3}{32}$ in.	paper	$\frac{1}{4}$ in.	Foramen in tympanic bone closed.
2 yrs., ...	$\frac{3}{32}$ in.	paper	$\frac{1}{4}$ in.	Foramen in tympanic bone present.
2 yrs. 4 mos. (L.),	$\frac{1}{16}$ in.	paper	$\frac{1}{4}$ in.	Small spine. Tympanic foramen present.
2 yrs. 4 mos. (R.),	$\frac{1}{8}$ in.	$\frac{1}{8}$ in.	$\frac{1}{4}$ in.	Small spine. Tympanic foramen present.
$3\frac{1}{2}$ yrs., . . .	$\frac{3}{32}$ in.	paper	$\frac{1}{4}$ in.	Spine well marked. Mastoid pneumatic throughout. Many accessory air-cells.
4 yrs., ...	...	...	$\frac{1}{4}$ in.	
5 yrs. 9 mos., .	$\frac{1}{16}$ in. hard bone	paper	$\frac{6}{16}$ in.	Many secondary air-cells. Mastoid pneumatic throughout.
6 yrs., ...	$\frac{1}{8}$ in. cancellous bone	paper	$\frac{1}{4}$ in.	Anterior $\frac{1}{3}$ of mastoid pneumatic.
6 yrs., ...	$\frac{1}{16}$ in.	$\frac{1}{16}$ in.	$\frac{6}{16}$ in.	Spine present. Anterior $\frac{1}{3}$ of mastoid pneumatic.
6 yrs., ...	$\frac{1}{8}$ in.	$\frac{1}{16}$ in.	$\frac{5}{16}$ in.	
6 yrs., ...	$\frac{1}{8}$ in.	paper	$\frac{3}{8}$ in.	Anterior part of mastoid pneumatic.
8 yrs. (female), .	$\frac{3}{8}$ in.	$\frac{3}{8}$ in.	$\frac{5}{16}$ in.	Small spine. Mastoid cancellous throughout.
9 yrs., ...	$\frac{1}{16}$ in.	paper	$\frac{1}{4}$ in.	Mastoid pneumatic throughout.
13 yrs., ...	$\frac{1}{8}$ in. by secondary cells	$\frac{1}{8}$ in.	$\frac{1}{4}$ in.	Mastoid pneumatic throughout; well-marked spine.
16 yrs. (male), .	$\frac{1}{4}$ in.	paper	$\frac{3}{16}$ in.	Upper and anterior part of mastoid pneumatic.
20 yrs., ...	$\frac{1}{4}$ in.	paper	$\frac{1}{4}$ in.	Mastoid pneumatic throughout.

Paper signifies ordinary note-paper.

The pair bracketed together were taken from the same subject.

behind the supra-meatal spine. Where a sinus exists from chronic disease, it is of course simpler to be guided by it.

I have no doubt that the gouge should replace the trephine in all operations on the soft, porous cranial bones of infants. In older children and adults a small sharp chisel is necessary, the chief precaution being to avoid giving it any upward or backward direction.

In the course of an examination of 120 adult temporal bones I have been able to confirm Birmingham's results as to the position of the lateral sinus (*Papers on the Mastoid Region of the Skull*, Dublin, 1891). After trephining a great number of times on the cadavera of adults, I can say that it would be safe to adopt the recommendation of this anatomist in trephining in adults for cerebellar abscess. To a practical surgeon, however, the occipital artery would offer no great difficulty; and with the small half-inch trephine recommended by Mr Barker I should prefer to follow his directions (1½ in. behind the centre of the meatus and 1 in. below the base-line). For temporo-sphenoidal abscess (an extremely rare event in adults), if it is thought desirable to expose the back part of the middle temporo-sphenoidal convolution, it would be well to allow for the possibility of the lateral sinus being higher than usual, and to trephine 1¾ in. or 2 ins. above the base-line, as Birmingham suggests.

As the result of many operations on the cadaver, I can add that, following Barker's directions[1] on infants of 1 year and under, the back part of the middle temporo-sphenoidal lobe in the one operation, and the middle of the under surface of the lateral surface of the cerebellum in the other, are always exposed without any danger of implicating the lateral sinus.

In all cases, before trephining and incising healthy meninges, it is advisable to open up the antrum and test with a probe whether there is a natural path for drainage which only requires the insertion of a tube to secure the evacuation of the abscess. Such a condition I have figured in Field's *Diseases of the Ear*, edit. 1892.

[1] For temporo-sphenoidal abscess, the centre of the trephine 1¼ in. behind and above the centre of the meatus. In cerebellar abscess, 1½ in. behind the centre of the meatus and 1 in. below Reid's base-line.

In preparing the bones from which the accompanying table is taken, I followed Politzer's directions for making transverse sections of the bone, and added afterwards a vertical section of the mastoid process. Before beginning the work, I tested Politzer's advice by making horizontal sections of several entire skulls, and found the result satisfactory. The saw is to lie on the upper edge of the zygoma, and the plane of section to pass through the uppermost parts of the external and internal meatus.[1]

[1] *The Anatomy of the Human Ear.*

REPORT ON RECENT TERATOLOGICAL LITERATURE. By

BERTRAM C. A. WINDLE, M.A., M.D., D.Sc., *Professor of Anatomy in Mason College, Birmingham.*

IN this third report on Teratological Literature, the writer has endeavoured as far as possible to proceed on the same lines as in previous reports; to give, that is, an account chiefly of those papers on the subject which are least accessible, omitting others which, though equally worthy of notice, are published in English periodicals, or in those generally consulted in this country. He has to thank those authors who have been kind enough to supply him with reprints of their papers, and to request them and others to be so good as to supply him with any further communications dealing with Teratological subjects, for use in the preparation of future reports.

GENERAL.—O. Hertwig (I.), in an important paper, gives the result of his experiments on the ova of Rana temporaria, and discusses their bearing on the origin of certain malformations. He considers that it is clearly proved that the monstrous frog larvæ, described in his paper, as well as the Mesodidymi of bony fishes, and those disturbances of development amongst monsters by arrest, which are known under the name of Spina Bifida, are due to a hindrance of closure of the primitive mouth, and the consequent cleavage of the axial organs. Discussing the influences of polyspermia, he also says that different factors must concur with one another in an over-fertilised ovum, powers which tend towards development, and others of a retarding and disturbing nature. The former are set in motion by fertilisation, even when that is multiple; the latter are the consequence of the injury which the ovum has received from being over-ripe, or from influences of various kinds prior to fertilisation. The final development of the ovum must be very different, according to which of the two influences is predominant. The problems which were discussed by His in a paper (I.) to which allusion was made in last year's report, have for some years been receiving attention from Giacomini, who deals in two communications (II. and III.) with certain points in connection with early-aborted embryos. The first treats of a complete ovum with an atrophied embryo, which is compared with the atrophic embryo of a rabbit, obtained experimentally, and the second of an abortive product of the nodular type. It is impossible adequately to deal with the three above-mentioned papers within the limits of this report, but the writer hopes to treat them more fully in a paper now in hand on these early failures of development. Klaussner (IV.), in a large and beautifully illustrated monograph, deals with multiple formations amongst vertebrate embryos. He gives a list of the species amongst which these forms have been observed, with a number of cases which he has himself recorded. Amongst fishes, these forms have been observed in the pike and in various members of the

Salmonidæ. Triple forms have been seen several times, and one instance is given as unique by the author, where four embryos coexisted on one ovum (Salmo fario). Amphibia, Rana fusca (Born), Rana esculenta (*ib.*), 3000 ova of one frog were artificially fertilised; of these about two-thirds developed, amongst which were twelve double forms, all Anadidymi. Pelobates fuscus (Bruch), a case with triply-divided chorda. Salamandra maculata (Braun), with two of the author's, viz., anakatidymus and one mesodidymus. Reptilia, Tropidonotus natrix (Braun), two embryos separate. Lacerta viridis, anadidymus, Coluber natrix, one anadidymus, and one case of two separate embryos. Amongst birds there are of course numerous instances, and the author adds of his own one each of Sturnus vulgaris and Passer domesticus, with four of Gallus domesticus. After considering the various theories of double monstrosity, and especially the bearing upon them of Roux's remarkable experiments, he states his opinion that, firstly, the multiple form may arise from primitive plurality of the formative substance, a condition leading to the development of twins, triplets, &c.; and secondly, from fission with post-generation, the halves of the embryo forming their missing portions not from themselves, but from the neighbouring material, as Roux has shown to be possible, in which case double monsters of various kinds are the result. A further contribution to the double-monster controversy is made by Wilson (V.), who states that when studying the cleavage of the ovum of Amphioxus, he was struck by the fact that the sixteen-celled stage occasionally appeared to be double, as if consisting of two eight-celled embryos, united along the line of the first cleavage. A study of these double embryos suggested that some disturbance of the two-celled stage might have caused each of the two blastomeres to enter upon an independent course of development, and he was thus led to experiment with two-celled stages, by Driesch's method of shaking apart the blastomeres. The experiments, successful from the first attempt, and often repeated afterwards under various conditions, showed that twin and double embryos could thus be produced in great numbers and with perfect ease. As in Echinus, complete separation of the blastomeres leads to the production of two quite separate and independent twins of half the normal size. Each of the isolated blastomeres undergoes a cleavage like that of a normal ovum (not a half cleavage), gives rise to a blastula of half the usual size, but otherwise normal, undergoes a normal gastrulation, and develops into a typical metameric larva, which even at the end of two days differs in nowise, except in size, from the normal forms. Incomplete separation of the two blastomeres gives rise to double embryos of many varieties, which form a complete series leading from scarcely bilobed forms to those in which two nearly perfect bodies are joined by only a narrow bridge of tissue. The double embryos develop into segmented free-swimming larvæ, but rarely live beyond the first twenty-four hours. Experiments with four-celled stages gave analogous results, but development never continued long after the closure of the blastopore and the first appearance of metamerism. (1) If the four blastomeres be completely isolated, each may give

rise to a dwarf blastula, gastrula, and oval free-swimming larva one fourth the normal size, but otherwise normal. (2) If, as frequently happens, the four-celled stage falls into two pairs of cells, each pair may give rise to an embryo of half the normal size (proved by isolation cultures). (3) If the four blastomeres be imperfectly separated, three types of multiple embryos (gastrulas) arise, namely, (*a*) double embryos (each half presumably arising from a pair of cells); (*b*) triple embryos, one body being twice the size of the other two; and (*c*) quadruple embryos, each body being one-fourth the normal size. He believes that the isolated blastomere of the eight-celled stage is incapable of producing a gastrula. The facts demonstrate, he believes, that the development of an isolated blastomere of the two-celled stage of Amphioxus is not, as in the frog, at first a half-development, afterwards completed by a process of regeneration ("post-generation," Roux). The isolated blastomere develops as a unit, not as a half-unit; and the cells to which it gives rise cannot be individually identified with those of a normal embryo-half. The development is transformed from the beginning.

Baudoin (VI.) gives a further account of the pygopagus Rosa-Josepha, contrasting their condition of genitalia with that of Millie-Christine and Helen-Judith. Millie-Christine had a double clitoris, and Helen-Judith a vagina double above, single below. In Rosa-Josepha, there is a single clitoris, but two vaginæ, with each its hymen and a single rectum. The author attributes the malformation to the union of two germs developed within the same chorion. A case of abcaudal fission in a cat is recorded by Landois (VII.), where union took place above the umbilicus. There were two bodies, eight limbs and two tails, two spinal cords and one brain. Pineau (VIII.) narrates a case of complete transposition of the viscera in a female who was left-handed, a fact which he thinks points to the probability of a transposition of the two hemispheres of the brain also. In an interesting monograph, Schmidt (IX.) gives the results of his examination of twelve dwarfs, the paper being illustrated with figures, and containing careful tables of measurements. The cases are as follow:—(1) F., æt. 19, 930 mm. (normal for 4 years): microcephalous. (2) F., æt. 16, 1160 mm. (normal for 8 years): had a serious illness at 8 years of age, since when growth has ceased. (3) F., æt. 26, 1083 mm. (normal for 7 years): an illness at 5 years, intellect very feeble. (4) F., æt. 11½, 979 mm. (normal for 5 years): good intellect, skull large, looking as if affected with hydrocephalus, limbs and especially arms very short. (5) M., æt. 63, 1262 mm. (normal for 9–10 years): grew until between 10 and 12 years of age. (6) M., æt. 19¼, 1280 mm. (normal for 10 years): idiot. (7) M., æt. 17, 1149 mm. (normal for 7 years): idiot. (8) M., æt. 20, 1320 mm. (normal for 11 years): hydrocephalic. (9 and 10) Two microcephalic idiot sisters. (11) M., æt. 21, 1212 mm. (normal for 9 years): hydrocephalic. (12) M., æt. 15½, 1199 mm. (normal for 8 years). Save in the case of 9 and 10 possibly, there was no history of heredity attached to any of these dwarfs. Houzé (X.) describes a female dwarf, aged 24, who was of normal size at birth, but subse-

quently was always backward in growth, which ceased at 4 years of age. Dental formula, $1\frac{2}{2}$, $C\frac{1}{1}$, $P\frac{3}{2}$, $M\frac{3}{1}$; weight $18\frac{1}{2}$ kg., height 81 cm. (normal for $2\frac{1}{2}$ years): cannot walk alone, and is quite idiotic. Has a persistent anterior fontanelle, and no nasal cartilages save the septal. Cyanosis probably dependent upon patent foramen ovale. Taruffi (XI.), in a paper on congenital struma of the thyroid body, gives a number of cases which he classes under the headings of adenomatous, parenchymatous, and congestive.

Head, Neck, and Nervous System.—Busachi (XII.) describes a case of facial cleft in a child aged 15 months, on the left side, and following the naso-labial fold. The lower part had healed in utero, leaving a fine scar, the line of which on the mucous membrane coincided with the interval between the incisor teeth. The ala of the left nostril was displaced upwards and outwards, so as to be almost attached to the angle of the eye, and the lower lid was cleft by the fissure. The same writer (XIII.) records a case of double harelip and cleft palate, with prominent inferior maxilla. Hirschberg (XIV.) describes a fœtus in which the aperture of the eyelids was small, and the lids firmly closed; the globes were small. There was harelip and cleft palate. In place of the pinnæ there were two skin appendages, each divided into an upper and lower portion. Busachi (XV.) describes a persistent branchial cartilage observed in a man aged 30. It was on the right side, and situated on the inner edge of the sterno-mastoid, at the level of the cricoid cartilage. It appears as a rounded sessile prominence. The cartilage, when removed, was found to be reticular in its structure. Paci (XVI.) describes a branchial fistula in a woman aged 22. There was a nodule on the side of the neck, at the level of the hyoid bone, with a small opening (a nephew was similarly affected). On excision, the fistula was found to be lined with pavement epithelium; near it there was a small piece of hyaline cartilage and some mucous glands. Triconi (XVII.) narrates a similar case occurring in a patient aged 24, on the right side of the neck, on the inner margin of the sterno-mastoid, and two cm. above the sterno-clavicular articulation. There was a round aperture 2 mm. in diameter, the margins of which were somewhat brown. A probe passed upwards, and fluid was seen to emerge in the pharynx from a small aperture situated on a papilla near the tonsil.

Beck (XVIII.) describes a case of double branchial cartilage, one on the inner border of either sterno-mastoid, at the level of the cricoid cartilage. On microscopic examination they were found to consist of reticular cartilage. Léjars (XIX.) calls attention to the diverticula which exist in branchial fistulæ, causing difficulties in their cure unless excision is practised.

Bichet (XX.), in a monograph on Microphthalmia, gives an account of a number of cases, and, on the vexed question of causation, states his opinion that sometimes microphthalmia constitutes a simple form of local arrest of development, coinciding with arrests of neighbouring organs. Sometimes it is the last stage of an intra-uterine inflammatory malady. Guinard (XXI.) mentions some cases of completely

anophthalmic guinea-pigs. A male which was kept for two years had a numerous progeny, with various normal females, twelve of the offspring exactly resembling their sire. An attempt to raise a blind race failed, apparently from the death of the parents. In all the anophthalmic cases the globes, optic nerves, and tracts were quite absent, and the anterior pair of corpora quadrigemina were smaller than normal. Kress (XXII.) gives an account of the literature of malformed pinnæ of the ear, with three cases observed by himself. (1.) Child æt. 6 months: left ear curved forward, covering and obliterating the external meatus. (2.) Child æt. 6 months: right ear smaller than left, and spirally curved forward over the concha. (3.) M. æt. 22: the right ear had a contracted pinna, and there was atresia of the meatus. In a series of papers (XXIII.–XXIX.), Gradenigo gives a full account of the various anomalies associated with the pinna of the ear. The account is too full to permit of a satisfactory abstract, but the following tables may with advantage be reproduced, the varying frequency of occurrence in the different classes being a point of special interest.

	Normal Pinna.	Lobule.		Fossa Scaph.		Too Prominent Ear.	Projecting Anthelix.	Helix.		Darwin.		Crus. sup. antih. badly formed.
		Simply United.	United with sharp angle.	Prolonged.	Interrupted.			A Broad Band.	Absent.	Macacus Ear.	Otious Point.	
MALES.												
Normal,	56·2	21·3	5·2	7·8	1·3	11·1	7·2	3	0·8	1·5	2	3
Insane,	36·5	16·6	9·7	15	1·5	26·0	18·0	3	3·8	2·6	2	5
Criminal,	28·2	17·5	7·6	18·0	4·0	25·2	18·0	4	4·0	1·5	1·8	6·7
FEMALES.												
Normal,	65·6	9·5	2·6	5·1	0·8	3·1	11·9	2.6	7·3	1·7	1·3	0·4
Insane,	46·0	25·0	14·3	9·0	2·6	4·2	26·0	3·2	8·0	1·0	1·7	1·8

From this it may be observed that anomalies of shape of the pinna of the ear occur much more frequently in the insane and criminal classes than amongst others, and that, whilst among the latter only slight deviations from the normal are usually observed, such as simply united lobule, scaphoid fossa continued towards the lobule, &c., among the former very much more remarkable malformations appear (excessively outstanding pinna, asymmetry of implantation, adhesions, lobe prolonged on to the cheek, &c.). The following table gives the relation of the anomalies to the different sides of the face.

A further table shows that the one-sided anomalies in general occur more frequently on the right side, both amongst men and women, with the exception of the outstanding ear, which is much more frequent amongst men on the left side. Variot (XXX.) has two cases

of malformation of the pinna. (1.) M. æt. $3\frac{1}{2}$: on both sides the fold of fibro-cartilage by which the antihelix commences, instead of sinking at the vicinity of the concha, keeps its prominence, branches and causes a prominence by which the concha is divided into two

MALES.			
	Normal.	Insane.	Criminal.
Bilateral anomalies, ...	67 per cent.	77 per cent.	68 per cent.
Right side only, ...	13 ,,	11 ,,	20 ,,
Left ,, ...	18 ,,	10 ,,	10 ,,
FEMALES.			
Bilateral anomalies, ...	71 per cent.	85 per cent.	
Right side only, ...	31 ,,	9 ,,	
Left ,, ...	14 ,,	5 ,,	

parts. (2.) Left pinna reduced to $3 \times 1{\cdot}5$ cm., lobule well formed: behind the tragus is a small elevation with four blind pits. Bianchi (XXXI.), in a study of the development of the squamous portion of the occipital bone, states (1.) that, as most observers assert, ossification extends from four primitive points in the squama. (2.) Besides the two giving rise to the supra-occipital, and the two producing the interparietals, two other nuclei may arise later in the connective tissue as Ficalbi has shown (2), the pre-interparietals of Chiarugi. (3.) These elements may be situated above the interparietals (most common), or in the middle of the interparietals. (4.) When, by an anomaly of development, the interparietals and pre-interparietals do not unite with the supraoccipital, they almost constantly atrophy. From variations in the development and position of these nuclei proceed the different anomalies of this region. Arnold (XXXII.) has a lengthy study of an anencephalous fœtus which lived three days. It sucked when a finger was placed in the mouth and when supplied with milk. Urine and meconium were passed normally. The pupils did not react. Stimulation, electrical and otherwise, of the exposed cerebral surface caused muscular movements, chiefly of the face. A full description of the nervous system is given. The most remarkable point in connection with the microscopic examination of the spinal cord is the observation that there was a decrease in size of the lateral columns, and in less degree of the anterior, the posterior columns and the grey matter being also reduced in size. It may be noted that Leonowa, in a paper (4) of which an account was given in the first of these reports, stated that the lateral pyramidal and the direct cerebellar tracts were wholly wanting in his case. Arnold states, with regard to the pyramidal tracts, that it is not the case that they are wanting in all instances of anencephaly; the extent of deficiency of the brain is different in such cases, and the condition of

the pyramids variable. As regards the posterior columns, these are normally developed up to their nuclei; from thence there is a decrease which especially affects the fibres rising to the brain, and those crossed at the corpora restiformia, whilst the uncrossed are better formed. Zilgien (XXXIII.) gives an account of the brain of a child of eleven years which was totally devoid of convolutions. The child was quite idiotic; and its twin, which died four years previously, presented the same mental condition, though unfortunately its brain was not examined. The brain in the case alluded to had no convulutions, pons, or corpus callosum, and the fossa Sylvii was barely indicated. The hemispheres did not cover the cerebellum. It weighed 195 grammes. Nerve-cells are stated to have been found in the cortex, but they are not more particularly described. Manges (XXXIV.) describes a meningocele of the root of the nose in a child of 15 months. It emerged at the point where the left nasal bone should have articulated with the frontal, and contained only cerebro-spinal fluid. Taruffi (XXXV.) describes an anencephalous fœtus, also affected with symmelia, which possessed two completely formed inferior maxillæ, placed side by side. The mouth aperture was single.

TRUNK.—Jaboulay (XXXVI.) gives notes of two cases of arrested torsion of the large intestine, one occurring in a fœtus of 35 cm., and the other in a woman aged 40. In both instances the transverse colon was only on the left side of the abdomen, and the ascending colon was in front of the small intestine, which it divided into two parts, one on either side of the abdominal cavity. Shepherd (XXXVII.) has an account of a fæcal fistula of the umbilicus, due to a persistent omphalo-mesaraic duct, which was cured by operation. V. Bardeleben (XXXVIII.) adds a supplement to a former paper (5) on hyperthelia. Of 192 soldiers examined, 27 possessed supernumerary breast warts, *i.e.*, 14 °/₀. The examination of two regiments gives the following figures for the side of occurrence,—1079 men, left 55; right 30; both 6: total 91. He remarks that these supernumerary warts not only appear in a regular line from the shoulder to the pubes, but take their places in regular positions, which can be arranged in distinct order; thus our normal breast is the fourth in series. It will be noticed that in this opinion he concurs with that expressed by Williams (6).

Testut (XXXIX.) describes a case of supernumerary mamma existing on the thigh of a female, aged 41. It was well formed, and placed on the antero-internal aspect of the right thigh, below the fold of the groin, in a line of the spine of the pubes. There was a conical nipple 12 mm. from base to summit, surrounded by a mass of glandular tissue, which could be moved about upon the aponeurosis of the thigh. The breast became turgid at the menstrual epoch and during pregnancy, but milk had not been observed to come from it. This case is similar to that published by Robert (7), where the breast was situated on the left thigh of a woman who had suckled several children at it. As to the atavistic character of these breasts, the discussion by Sutton (8) may be seen. A remarkable case of implanta-

tion is given by Tsortis (XL.): it was observed in a soldier aged 21. On an elevation situated below the left scapula, were placed an almost complete set of female external genitalia, lying with their long axis perpendicularly, 2·5 cm. in length. The labia majora were slightly open, covered externally with black hairs; the internal surface was smooth, soft, and resembled mucous membrane. They united above into a kind of Mons Veneris. There was a small cavity between the labia, resembling a rudimentary vagina, above which was a small tubercle like a clitoris; there were no labia minora. My colleague, Mr Oliver Pemberton, has shown me a picture of a patient of his, a male, on the centre of whose back, at the level of the upper lumbar region, was a well-formed penis with hair around it, and a structure beneath like a scrotum. Busachi (XLI.) describes a case where the penis was adherent to the anterior part of the scrotum for its entire length; it was also affected with hypospadias. Taruffi (XLII.) devotes a memoir to the consideration of abnormal penile canals, classed under the following headings:—(1) Seminiferous: there may be two openings at the glans—one for urine, the other for semen. (2) Blind canals lying between the corpora cavernosa, and therefore above the urethra. (3) Uriniferous, two canals, one situated above the other and separated from it by a membranous septum, both passing urine. (4) Fæcal canals. Nieberding (XLIII.) describes three cases of a congenital contraction of the centre of the vagina by a ring, the passage being thus hour-glass shaped, and consisting of an upper chamber containing the cervix uteri, and communicating by a narrow aperture with the lower, which was continuous with the vestibule. Tapie (XLIV.) mentions a case where there was absence of the right kidney, of the lower part of the Fallopian tube, and of the side of the uterus. There was a well-formed right ovary, to which the upper part of the tube was attached. The left ovary lay beneath the kidney, which was hypertrophied.

Extremities.—Busachi (XLV.) describes a case of absence of the fibula, with a summary of the literature relating to this malformation. The same writer has another paper (XLVI.) on absence of the tibia, which is a supplement to one published previously by him on the same subject (9). A third case narrated by the same author (XLVII.) is one of syndactyly in a boy aged 13 months. The whole right hand was smaller than the left, and the thumb (which is unusual) was united to all the fingers. Schæfar (XLVIII.) gives an account of five cases of *ectrodactyly*. (1) All four extremities affected; father, father's sister, and five of his own sisters similarly affected. (2) Only two metacarpals on the right hand, rest normal. (3) Both hands affected; right has three metacarpals, left two. (4) Three metacarpals to right hand. (5) Metatarsus and phalanges of right foot absent. Bédart (XLIX.) gives a case of similar kind in which heredity was well marked. The ectrodactyly affected the marginal digits, the feet being forked, and the hands of the lobster-claw type. The first-affected generation consisted of one affected male, who married a normal wife. They had one abnormal and one normal son and two abnormal daughters. The third generation consists of 13

children, viz., 5 normal and 2 abnormal males, and 6 females all abnormal. Thus the females of the family were more affected than the males. An instance of this occurred in the case of heterologous twins, born of one of the members, of whom, one twin, a girl, was affected, and the other, a boy, was normal. Rydgier (L.) describes a case of syndactyly of the four outer toes of both feet, also of the third and fourth digits of the left hand, the thumb of which was absent. In the same paper is a description of a case of ectromelia, in which all four extremities were imperfectly developed. Both fore-arms were absent, as also the entire of the right lower, which was represented by a fleshy appendage of the size of an apple, and all the left lower except the upper third of the thigh. A case where one upper extremity alone was affected is that given by Deboux (LI.). The patient was a young negress aged 14. The right hand has no minimus, and the left fore-arm is deficient from the elbow-joint. The right leg is shorter than the left, and there is a consequent lateral curvature of the spine. The author thinks that in these cases certain primitive cells, which should have developed into the missing portions, have been impeded, possibly by want of sufficient formative material. Humphry (LII.) deals with the interesting subject of macrodactyly. He gives an account of six casts and specimens in the museum of the University of Cambridge. The author discusses the bearing of these cases on certain pathological problems, and states that the cases obviously consist in an excess, an abnormally excessive growth of a normal part of the body—an excess not depending upon any superabundance of nutritive supply or any modification of nerve-influence, but upon an excess, a want of due restraint, of that developmental force by which the several organs and structures acquire and maintain their proper dimensions and relations to one another, and by which their relative growth at different periods of life and under different circumstances (as of the genital organs at puberty) is determined. The nature of this force is a mystery, perhaps past finding out. He lays stress upon the view that whatever may be their exciting causes, and however much they may differ in their characters and progress, macrodactyls and nævi, warts and tumors, simple and malignant, are essentially alike in the feature of being overgrowths of the parts or tissues in which they take origin. Prince (LIII.) gives a case where a portion of one of these macrodactyls was examined in a recent state. The patient was a boy aged 4 years, born of healthy parents. At birth and ever since, the right arm, fore-arm, thumb and index have been larger than the left. When examined, the circumference of the left arm was 7 in., of the right 9; while the measurements of the fore-arm were, left $3\frac{3}{4}$ in., right 7 in. The skin was smooth, and there was no sign of elephantiasis. The right index being bifurcate, one portion was removed; and when examined, the hypertrophy of that part was found to be seated in the cellular tissue.

In last year's report a summary was given of a paper by Jolly (10) on a case of fused hands, a similar case to which has now been described by Dwight (LIV.). The paper commences with an account

of the literature of the subject. The subject was a male aged 37, and the left arm was affected. The fore-arm consists of the normal left ulna, and of a right one in the place of the radius. The right or extra ulna is put on, hind side before; that is, the back of the olecranon projects forward over the front and outer aspect of the humerus. At the lower end of the humerus the internal condyle is normal; it is quite unmistakable, and is the most evident starting-point. On the posterior surface is an olecranon fossa containing the normal olecranon. Beyond this is a thick rounded swelling, which, however, can hardly have been prominent before dissection. This is the normal outer condyle of the humerus, plus another of a right humerus, applied to the normal bone at nearly a right angle. A prominence somewhat to the outer side of the front of the normal humerus represents the internal condyle of the right one. Between this and the fused external condyles is the joint for the right olecranon. There is but a faint trace of a fossa above it. Between the two internal condyles is a very small coronoid fossa on the front of the normal humerus. Thus it appears that to this left humerus is added a part of the lower end of the right one, so applied that the outer condyles are fused and the right internal condyle projects forward. The proximal row of carpal bones consists of three bones besides the two pisiforms. At either side of the wrist is a cuneiform, the dorsal surface of which is uncommonly large. Between them is a bone, which is evidently the result of the fusion of two semilunars. Its upper border is slightly notched. The pisiforms in the tendons of the ulnar flexors are displaced above the wrist on to the ulnæ. Extension of the hand would have brought them on to the cuneiform bones. At each end of the second row there is an unciform bearing the little and ring fingers. Each rests on the corresponding cuneiform, and touches the semilunar. Next come the two ossa magna, very symmetrically disposed, each bearing the metacarpal bone of the middle finger. Their anterior halves diverge so as to leave an interval between them, behind which they touch each other, their heads resting side by side in the middle bone of the first row. In the notch between these bones is the trapezoid, bearing the left index finger which belongs to the left hand. As regards the muscles, there were two tricipites; coraco-brachialis was small, and there was no well-defined brachialis anticus. The brachial artery, after a high division, gave off an ulnar which ran deeply, giving origin to the interosseous. The other branch at first ran superficially like a radial, and then changed into an ulnar, giving, as did the other, a characteristic deep branch to the palm. The musculo-spiral nerve gave off a branch, which, in place of a radial, became an ulnar.

Two cases of absent pectoral muscles may be added to those given in the first of these reports. Hagman (LV.): absent right pectoral in a boy aged 11. Féré (LVI.): this case was that of a male aged 30, in whom the right iris was browner than the left, the right side of the tongue thinner than its fellow, the hair was less well developed and whiter on the left side, and the sight and hearing were worse on that side. He was epileptic, and the convulsions were more marked

on the left side. At the P.M. the left cornu Ammonis was found to be harder than the right. The right pectoralis major consisted of three narrow digitations, separated by fibrous tissue, and there was no P. minor.

REFERENCES.

I. Hertwig, O., "Urmund und Spina Bifida," *Arch. f. Mikr. Anat.*, Bd. 39.

II. Giacomini, C., "Sulle Anom. di Sviluppo dell' embrione umano." Comm. iv. Ovolo completo con embrione atrofico.

III. *Ibid.*, Comm. v. Prodotto abortivo con forma nodulare.

IV. Klaussner, F., "Mehrfachbildungen bei Wirbelthieren, München," 1890.

V. Wilson, E. B., "On Multiple and Partial Development in Amphioxus," *Anatomischer Anzeiger*, Jahrg. vii. s. 732.

VI. Baudoin, M., "Le Pygopage Rosa Josepha," *Rev. Mens. de l'École d' Anth.*, année ii. p. 31.

VII. Landois, H., "Ub. ein Hauskatchen u. s. w.," *XIX. Jahresber. des Westfäl. Prov. Vereins f. Wiss. u. Künst.*, s. 9.

VIII. Pineau, A., "Inversion générale des organs," *Bull. de la Soc. Anat. de Paris*, 1892, p. 652.

IX. Schmidt, A., "Zur Kenntniss des Zwergwuchs," Inaugural Dissertation, München, 1891.

X. Houzé, E., "Description d'une Naine," *Bull. de la Soc. d'Anthrop. de Bruxelles*, t. 9.

XI. Taruffi, C., "Sulle Struma Congenita della Tiroide," Bologna, 1892.

XII. Busachi, T., "Fessura obliqua del viso non complicata," *Arch. di Ortop.*, anno ix.

XIII. *Ibid.*, "Fessura doppia del labbro superiore." Ref. as xii.

XIV. Hirschberg, L., "Eine Frucht mit Hydrocephalus u. s. w." Inaugural Dissertation, Königsberg, 1891.

XV. Busachi, T., "Avanzo cartil. congen. nel collo." Ref. as xii.

XVI. Paci, A., "Fistola Branchiale Esterna," Lo Sperimentale, an. xlv.

XVII. Tricomi, E., "Un Caso di Fistola Completa del Collo," *Rif. Med.*, 1891.

XVIII. Beck, C., "Branchial Cartilages," *Med. Rec.*, 1892, p. 169.

XIX. Lejars, "Fistules Branchiales à Parois Complexes," *Prog. Méd.*, 1892, p. 113.

XX. Bichet, M., "De la Microphthalmie Congénitale," Thèse, Lille, 1891.

XXI. Guinard, L., "Un Cobaye Atteint d'anophthalmus," *Lyon Méd. T.* 68, p. 155.

XXII. Kress, B., "Ueb. Missbild. des Aeuss. Ohres," Inaugural Dissertation, Marburg, 1890.

XXIII. Gradenigo, G., "Die Formentw. d. Ohrmuschel," *Centralbl. f. d. med. Wiss.*, 1888, Nos. 5 u. 6.

XXIV. *Ibid.*, "Ueb. die Conf. d. Ohrmuschel b. d. Verbrechrinnen," *Zts. f. Ohrenheilk*, xxii.

XXV. *Ibid.*, "Zur Morph. d. Ohrmuschel u. s. w.," *Arch. f. Ohrenheilk*, xxx.

XXVI. *Ibid.*, "Ueb. d. Formanom. d. Ohrmuschel," *Ibid.*, xxxii. s. 210.

XXVII. *Ibid.*, xxxiii.

XXVIII. *Ibid.*, "Das Ohr des Verbrechers," *Arch. f. Ohrenheilk.*

XXIX. *Ibid.*, "Sulle Anomalie nella Conformazione del Padiglione dell' Orecchio," *Giorn. della Reg. Acc. di Med. di Torino*, 1889–1890.
XXX. Variot, *Bull. de la Soc. d'Anth. de Paris*, 1892, 568 and 652.
XXXI. Bianchi, S., "Sulla Sviluppo della Squama Occipitale," *Monit. Zoolog. Ital.*, an. ii., Nos. 4, 5.
XXXII. Arnold, J., "Gehirn, Rückenmark u. Schädel eines Hemicephalus," *Beitr. z. Path. Anat. u. z. Allg. Path.*, Bd. xi.
XXXIII. Zilgien, "Etude d'un Cerveau sans circonvolutions," *Rev. Mens. de l'École d'Anth. Paris*, année ii. p. 131.
XXXIV. Manges, "Méningocèle à la Racine du nez," *Riv. Ven. d. Sci. Med.*, 1892, p. 429.
XXXV. Taruffi, C., "Feto Umano con Due Mandibole Simmetrice," *R. Acc. delle Sci. dell' Ist. di Bologna*, 1892.
XXXVI. Jaboulay, *Province Médicale*, 1891, p. 572.
XXXVII. Shepherd, F. J., "Umbilical Fæcal Fistula," *Arch. of Pediat*, Jan. 1892.
XXXVIII. v. Bardeleben, K., "Weitere Unters. üb. d. Hyperthelie bei Männern," *Anat. Anzeig.*, Jahrg. vii. s. 87.
XXXIX. Testut, "Mamelle Crurale Observé chez la Femme," *Bull. de la Soc. d'Anth. de Paris*, s. iv. f. 4, p. 757.
XL. Tsortis, D., "Organe Génitale Externe de la Femme sur le Dos d'un Homme," *J. Méd. de l'Armée*, Athènes, Jy. 1892.
XLI. Busachi, T., "Aderenza Congenita del Pene collo Scroto," ref. as xii.
XLII. Taruffi, C., "Sui Canali Anomali del Pene," Bologna, 1891.
XLIII. Nieberding, "Ueb. eine seltene Anom. d. Vagina," *Würz. Phys. Med. Ges.*, 1891.
XLIV. Tapie, "Anomalie Completè dans la Sphère Gènito-Urinaire," *Rev. Int. de. Bibl. Méd.*, 1892, p. 324.
XLV. Busachi, T., "Intorno alla Mancanza del Perone," *Arch. di Ortop.*, ix.
XLVI. *Ibid.*, "Mancanza Congenita della Tibia." Same ref.
XLVII. *Ibid.*, "Sindattilia Completa della Mano," ref. as xii.
XLVIII. Schäfer, W., "Ueb. einige Fälle v. Cong. Def. an Händen u. Füssen," Inaugural Dissertation, *Beitr. z. Klin. Chir.*, Bd. vii., Hft. ii.
XLIX. Bédart, "Malformations Héréditaires," *Rev. Mens. de l'École d'Anth. de Paris*, année ii. p. 244.
L. Rydgier, L., "Seltene Fälle v. Missbild." *v. Langenbeck's Arch.*, Bd. xlii., Hft. 4.
LI. Deboux, J. B., "Un cas d'Hémimélie," *Rev. Mens. de l'École d'Anth. de Paris*, année ii. p. 100.
LII. Humphry, Sir G., "Macrodactyly," *Med. Chi. Trans.*, lxxiv.
LIII. Prince, J., "Congenital Hypertrophy," *Med. Rec.*, 1891, p. 678.
LIV. Dwight, T., "Fusion of Hands," *Mem. of the Boston Soc. of Nat. Hist.*, vol. iv. No. x.
LV. Hagman, *Rev. d'Orthopédie*, Sep. 1892.
LVI. Féré, C., "Nouv. Inconographie de la Salpêtrièrë," 1891, p. 456.

SUB-REFERENCES.

(1.) His, W., "Offene Fragen d. Path. Emb.," *Internat. Beitr. z. Wiss. Med.*
(2.) Ficalbi, "Ossa Accessoria," *Mem. Soc. Tosc. Sc. Nat.*, Pise, 1835.

(3.) Chiarugi, "Delle Ossa Interparietali Accessorie," *Boll. Soc. Cult. Sc. Med. Sienne*, 1885.
(4.) v. Leonowa, *Arch. f. Anat. u. Entwick*, 1890, s. 403.
(5.) v. Bardeleben, K., "Die Häufigkeit Ueberzählige Brustwarzen," *Verh. d. Anat. Ges.* 1891, s. 247.
(6.) Williams, W. R., "On Polymastism," *Jour. of Anat. and Phys.*, xxv. p. 225.
(7.) Robert, *Jour. de Phys.*, t. vii. No. 2.
(8.) Sutton, J. B., "Evolution and Disease," p. 162.
(9.) Busachi, T., *Giorn. della R. Acc. di Med.*, 1886, Nos. 9–12.
(10.) Jolly, "Polydactylie mit Missbild. des Armes," ref. as i.

A PHRENIC NERVE RECEIVING A ROOT OF ORIGIN FROM THE DESCENDENS HYPOGLOSSI. By Professor Sir W. TURNER.

VARIATIONS in the roots of origin of the phrenic nerve have been recorded by Wrisberg,[1] Ludwig,[2] Cunningham[3] and myself.[4] Recently I met with a variety which, though Valentin in Sömmering's work *Hirn und Nervenlehre* states to be often present, has only once come under my observation.

On the left side of the neck of an adult male a branch of some size arose in the lower part of the neck from the descendens hypoglossi. It entered the thorax, passed in front of the vena innominata sinistra and the transverse part of the arch of the aorta, and joined the left phrenic nerve in front of the root of the left lung. This left phrenic received roots of origin from the anterior divisions of the fourth and fifth cervical, but not from the third. It is probable that in this neck the root of the phrenic from the third had accompanied the communicans hypoglossi arising from the third cervical, and through it had reached the descendens hypoglossi, with which it ran for about two inches before being given off to join the phrenic in the thorax, as above described.

[1] and [2] Quoted by Krause and Telgmann in *Die Varietäten des Nerven*, Leipzig, 1868.
[3] *Jour. of Anat. and Phys.*, vol. vii. p. 94.
[4] *Ibid.*, vol. vi. p. 102.

Notices of New Books.

Précis de Tératologie Anomalies et Monstruosités chez l'Homme et chez les Animaux. Par L. Guinard, *précédé d'une préface*, par M. le Dr Camille Dareste. Paris: J. B. Baillière et Fils, 1893.

THE writings of Et. and Is. Geoffroy Saint Hilaire, Vrolik, Gurlt, Förster, and Ahlfeld are familiar to all who are engaged in the study of the anomalous forms which from time to time present themselves in the human body and in those of the domesticated mammals. The beautifully illustrated monograph on Human Monstrosities, by Drs Hirst and Piersol of Philadelphia, the appearance of the first and second parts of which we noticed in this *Journal*, July 1892, whilst a third part has subsequently been published, has enabled those engaged in teratological study to become acquainted with the valuable collection contained in the Museum of the Medical Department of the University of Pennsylvania. In the writings of M. Camille Dareste on the production of anomalous forms, a number of curious and interesting observations on teratogeny have been recorded. But notwithstanding these and other contributions to this department of biological work, an exposition of the various forms of anomalies, and of the probable causes of their production, in a volume of convenient size, and with a proper amount of illustration, was a desideratum.

In the compact volume of 552 pages, the title of which heads this notice, M. Guinard has supplied this want, and M. Dareste, in the preface which he has written, has given it the stamp of his approval. In the earlier chapters of the work general questions are discussed, connected with such subjects as the causes of anomalies, the artificial production of monsters, general conditions affecting the production of monsters, probable explanations of the formation of the principal monstrosities, the laws of variation and of abnormal development, the limit and frequency of anomalies, the importance and the relations of teratology to the biological and medical sciences. A chapter is then written on the classification of anomalies and monstrosities, at the end of which the author intimates that he adopts almost exactly the great divisions of Is. Geoffroy Saint Hilaire, with a modification in the branch of the simple anomalies.

M. Guinard next proceeds to the consideration of the simple anomalies, and explains and illustrates the most important of those which affect the several organic systems. This is followed by an excellent chapter on the several kinds of hermaphroditism, and a short chapter on heterotaxy, or transposition of the viscera. A descrip-

tion of the various forms of monsters, and the origin and the conditions of formation of compound monsters, constitutes about one-third of the volume, which we may say is plentifully illustrated with 272 figures intercalated in the text. We can cordially indorse the opinion expressed by M. Dareste, that the book will be of great service to those who, for one reason or another, occupy themselves with the study of anomalies and monstrosities.

Éléments d'Anatomie Comparée. Par Rémy Perrier. Paris: J. B. Baillière & Fils, 1892.

In a substantial volume of 1208 pages, illustrated with 651 figures in the text and 8 coloured plates, and at the moderate price of 16s., M. Rémy Perrier has produced a text-book on the Elements of Comparative Anatomy. In the general plan of arrangement the author has to a large extent followed the anatomical and not the zoological method, the systems of organs being described and studied in the variations which they exhibit in the animal series. The work is written from the point of view of the doctrine of evolution, and the earlier pages are explanatory of the principles which have guided the author in the preparation of his work. He attaches himself to the school of the Neo-Lamarkians rather than to the Darwinists, in the more restricted sense in which the latter term is now employed; for he is convinced that the influence of the environment is the essential cause of the transformation of living beings, and that natural selection only intervenes secondarily to fix and limit the species.

In the descriptive part of the work a tabular view of the classification of the group precedes the account of the organs. Especial prominence is given to the Vertebrata, the description of the anatomy of which occupies the last 400 pages of the volume. The work is clearly written, and amply illustrated, and provides the student with an excellent resumé of the subject.

Human Embryology. By Charles Sedgwick Minot. New York: William Wood & Co., 1892.

By the publication during the last few years of several articles in the *Proceedings of the Boston Society of Natural History* and other American serials, Professor Minot of Harvard University has made himself known as a good observer, and an acute and intelligent thinker on many biological problems. The text-book on Human Embryology, published in the autumn of last year, will add to his reputation, both as an observer and an independent critic, though we cannot at all times side with his conclusions. In this handsome volume he deals both with the facts of development and

structure, and analyses with much vigour the modern theories and hypotheses which have been advanced in explanation of such general questions as the evolution of sex, heredity, differentiation; as well as the more special embryological questions involved in the consideration of segmentation, the production of the germ-layers, and the formation of the tissues and organs of the body out of those layers. The book gives ample evidence of research on the part of the author, both literary and observational. The alphabetical list of references at the end of the volume shows the wide range of his reading, and the chapters in which he describes the known human ova of the second and third weeks, and the growth and external development of the fœtus, afford proof of his capacity to arrange in logical order material collected from a variety of sources. The extent of the author's own investigations is to be measured both by the descriptions in the text and the numerous original drawings which are intercalated in it. In its illustrations, four hundred and sixty-three in number and in its typography, this treatise is most creditable to the American press.

Journal of Anatomy and Physiology.

LAW OF TRANSVERSE VIBRATIONS OF STRINGS APPLIED TO THE HUMAN LARYNX.

By ROBERT H. WOODS, M.B., *Demonstrator of Anatomy in the University of Dublin, and Throat Surgeon to the Richmond Hospital, Dublin.*

(Read before the Anatomical and Physiological Section of the Royal Academy of Medicine in Ireland, March 16, 1893.)

IT has frequently been attempted to compare the voice to one or other of the orchestral instruments, but no single instrument has been made to work on quite its principle.

In general it may be said that the voice depends for its production on the emission of a number of very rapidly-succeeding puffs of air causing disturbances at their place of origin, which disturbances are transmitted as vibrations, the number of puffs determining the number of vibrations per second, and so the pitch of the note.

Thus far the voice acts in exactly the same way as a reed-instrument, but here the analogy ceases. Reed instruments are of two kinds,—those in which the reed has no definite rate of vibration of its own, the rate being determined by the length of a resonance apparatus, as *e.g.* the bassoon; and those in which the rate of vibration of the reed is its own property, and is independent of a resonance apparatus, as *e.g.* a concertina or an American organ.

The voice has with the former variety nothing in common. It differs from the latter in the following particulars:—

(*a*) The disturbances are caused by the free margins of two elastic membranes mutually vibrating the one against the other, instead of by the vibrations of a metallic tongue against a fixed plate.

(*b*) The variations in pitch are produced by modifications in the conditions of the membranes, instead of by a separate apparatus for each note.

(*c*) In the reed the rate of vibration is determined by the mass of the tongue and the strength of the spring, while in the voice it is controlled by the tension on the membranes and some other elements which we shall presently discuss.

The note then, emitted by the voice depends finally for its pitch on the rate of vibration of the two chords the ends of which are fixed, and the centre of which is free as far as transverse movement in the vertical or nearly vertical direction—the only one which concerns us—is concerned. Let us then consider in what way this rate is influenced.

Since the chords vibrate as if they were strings, they must vibrate in obedience to the law governing the transverse vibrations of strings.

The law may be written—

$$n = \frac{1}{2l}\sqrt{\frac{t}{m}},$$

where n is the number of vibrations per second, or, in other words, the pitch of the note, l the length of the vibrating string, t the tension, and m the mass per unit of length.

In comparing two pairs of vocal chords of different lengths, the mean pitch of the notes produced by the longer pair is in general lower than that of the shorter pair, because, as seen from the equation, the pitch varies inversely as the length. This is the principal cause of the difference in pitch between a man's voice and that of a woman or child, and is too obvious to need further comment.

When considering a single larynx, l may be regarded as constant. This, of course, is not strictly true, because, when the tension of the chords is raised, their elasticity allows them to yield and become slightly elongated; but, for practical purposes, the length may be regarded as constant. Eliminating this factor, then, we have—

$$n \propto \sqrt{\frac{t}{m}}.$$

Let us first attend to the influence of the tension. This is one of the most important factors in the variation of the pitch —in fact, so far as I know, the only hitherto accredited factor.

Supposing the mass to be constant then, it follows that the tension required by the vocal chords, in order that they may emit a note an octave above a given one, is not in proportion to its rate of vibration with regard to the fundamental note which is as 2 : 1, but in the square of that ratio, or as 4 : 1. Hence the tension required in the vocal chords in order that they may emit a note two octaves above a given one—that is to say, of four times its rate of vibration—will be sixteen times the tension for the fundamental note; and if the third octave could be completed, the tension would have to be sixty-four times as great. The exertion required to produce these tensions will be approximately in the same ratio. This is the reason why the compass of the voice, no matter what its mean pitch may be, is so very nearly constant, being only exceptionally very much above two octaves, and is also the cause of the suddenness of its limitation.

The rapidity with which the voice gets tired when singing without frequent rests, even moderately high up its register, is at once clear when considered in this light.

The difficulty experienced even by trained singers of singing *piano* near the top of the register has here an explanation. The magnitude of the tension in the chords renders an unusually violent expiratory effort necessary in order to open the glottis, and so loudness is with difficulty avoidable.

This enormous and disproportionate rate of increase of the required tension must, if it alone modify the pitch, put a limit very shortly on the compass; and it is difficult to conceive how the voice could reach even up to much less beyond the second octave if the alteration in tension were the only modifying factor. We must therefore look for another, and our attention is attracted to m—the mass per unit length.

It has long been observed that chords with thick rounded edges accompany deep voices, other things being equal, and thin, sharp-margined chords high ones. This has been explained as follows:—A thick chord means greater development of the thyro-arytænoidei, and consequently less tension of the chords by more perfect opposition to the action of the crico-thyroid,

and, as a result of the lower tension, a lower pitch. This explanation leaves entirely out of count the mass of the vibrating chord—a factor which must enter and make itself felt. Now the thyro-arytænoideus internus, by which the shape of the chord is principally affected, is a feeble one in comparison with the externus, and the modifying effect of differences in its development on the total effect of both muscles would, under any circumstances, be negligible, and is certainly not sufficient to explain the difference in pitch between a thick and a thin chord on the assumption of its mere interference with the tension. Hence, I think it is much more rational to put its effect on the pitch down to the score of its mass, rather than its opposition to the crico-thyroid.

But a stronger argument against the theory is found in the fact that it runs immediately external to, and in very close connection with, the vocal chord, and must be looked upon as part and parcel of the vibrating chord itself; and consequently its contraction, instead of lowering the tension of the chord, must raise it. Clinical observation favours this view; for when the muscle is paralysed, the pitch of the voice, instead of rising, becomes lowered, which certainly could not happen if the muscle were an opponent, pure and simple, of the crico-thyroid.

Again, if force additional to that of the thyro-arytænoideus externus were required to oppose the crico-thyroid, which seems anything but likely, why should the muscle-fibres be laid down in the true vocal chord, whose function, on this assumption, ought not to be contractile, but purely vibratory, and when by their disposition on a higher level their moment round the crico-thyroid joints, and therefore their efficiency, would be greater? These considerations are entirely against the pure opposition of the thyro-arytænoideus internus to the crico-thyroid, and lead us to the belief that the theory was invented as a loose way of explaining as cause and effect two conditions which were known to be associated.

Why, then, does the muscle run in the substance of the chord? The reason is that the vibrating mass of the chord is not a constant quantity, but is determined by the thyro-arytænoideus internus. For when the muscle contracts, it not only raises the tension, but also, by means of its vertical fibres, fixes the base

or outer region of the chord, leaving merely the edge free to vibrate; and thus, by the twofold action of increasing the tension and reducing the mass, raises the pitch of the note, and conversely, when quite relaxed, it leaves the outer part of the chord, of which it is a constituent, free to vibrate, and by increasing the mass, as well as diminishing the tension of the chord, lowers the note. This can be observed clinically. The disturbance of the chords during the production of a low note is seen by the laryngoscope to extend much further out than during the production of a high one.

The vertically-running outer fibres of the thyro-arytænoideus internus, for whose existence a plausible apology has been so long wanting, will thus be seen to have a very important function.

The depth of the voice in laryngitis, and occasionally in other diseases—as, for instance, tertiary syphilis—affecting this part, is explained by the formula. The injection and swelling of the chord increases the mass and lowers the note.

No notice has here been taken of the falsetto voice, but it may be mentioned that the shortness of the vibrating chords and the narrowness of the area of disturbance appear to be more concerned in causing its high pitch than the tension.

ON CERTAIN EARLY MALFORMATIONS OF THE EMBRYO.

By BERTRAM C. A. WINDLE, D.Sc., M.D., M.A., *Professor of Anatomy in Mason College, Birmingham.*

FOR some years I have been engaged in the study of the earlier malformations produced by various methods of disturbing the process of incubation in hens' eggs. A preliminary note on this subject was published in the *Proceedings* of the Birmingham Philosophical Society (40), the researches having been carried out with the aid of a grant from the Endowment of Research Fund of that Society. In the present communication, it is my intention to give an account of some of the early malformations of the human embryo, and to examine them in the light of the results obtained by artificial teratogeny. In doing this, I propose first to describe the more important recently described human cases, and then to discuss the experimental evidence with its bearing upon the instances in point.

SECTION I.—EARLY MALFORMATIONS OF THE HUMAN EMBRYO.

It has long been recognised that early human ova when opened may exhibit either an apparent or real absence of any contained embryo, or a more or less ill-shaped, nodular, or cylindrical mass representing the product of generation. Although these conditions have been recognised, it is only recently that careful inquiry has been directed into the nature and causes of the malformations, and an accurate microscopical examination made. In his great work on the human embryo, His examined a number of these malformed cases, and classified them (20) into Nodular, Atrophic, and Cylindrical groups, a division which he uses also in a most suggestive paper (21), to which I shall have to allude more fully at a later period. This classification was, however, avowedly based only upon external characteristics, which, as will shortly appear, are or may be

highly misleading, since the outer form affords scanty information in the less developed cases of the condition of the internal organs. Giacomini, who has studied carefully some of these forms with the aid of an exhaustive microscopic examination, proposes a classification founded upon the characters thus revealed. He divides them (14) into Nodular embryos, which are those in which microscopic examination reveals no trace of organs; and Atrophic embryos, in which the organs, or some of them, though profoundly altered, are still recognisable. Acting in the main upon this classification, it will be convenient here to give a brief account of some recently described cases. Before doing so, it will be necessary to note two points. (1) There is a group of vesicular forms, the exact position of which is difficult to be ascertained. Such vesicular formations in the interior of the chorion have been described as normal embryos at an early period of development (Reichert), as monstrous embryos (His), or as productions of the chorion (Giacomini, Chiarugi). I have, therefore, thought it better to place them in a class by themselves provisionally. (2) It is evident that in the remaining groups there must be many cases the classification of which is doubtful, since it is difficult to say whether the organs are completely unrecognisable or not. Giacomini goes so far as to say that a nodular embryo described by him is the unique example of that class so far recorded. I have ventured to include two others with this in the following list.

Early Malformed Human Embryos.

A. *Vesicular.*—1. Reichert (32) described a very young human ovum without embryo, which was provided on the exterior with a chorion and villi. He regarded it as being a normal embryo of very early age, but Kolliker (23) is doubtful on this point, since the villi are not formed until after the amnion, and therefore the embryo, has developed.

2. Giacomini (14). An ovum at the end of the first month, provided with villi, containing a small distended vesicle in its interior. On microscopic examination, this was found to consist of two strata, viz., externally of connective tissue, and internally of a single stratum of flattened epithelial cells. The

author considers this to be a pathological production of the chorion.

3. Giacomini (15). 2½ months. A small amniotic vesicle, in which the product had entirely disappeared, from defect of development.

4. Giacomini (19). 1st month. Ovum covered with villi, and containing no trace of embryo.

5. Lachi (25). Ovum of 1–2 month. Chorion covered with villi, and containing two small vesicles. The author believes the atrophied embryo to have been represented only by its umbilical vesicle.

6. Chiarugi (4). A bilobed vesicle, one portion of which might be considered as an embryo much atrophied. In a note to another paper (5) the author states that Giacomini (14) has described a case similar to this, which he regards as a pathological formation. To this view Chiarugi gives his adherence, and believes his case to bear a similar interpretation.

B. *Nodular.*—1. Giacomini (18). Ovum of the second week, containing inside the chorion a small punctiform reddish body. There were no traces of blood-vessels in the chorion. There was a small solid body attached, which he regards as a unique instance of a nodular embryo. It contained no round cells such as are found in the atrophic forms. The explanation of this will be given in another place.

2. Valenti (38). A two month vesicular formation containing masses of cells, but no traces of embryonic organs. The author is doubtful whether these cells represent an embryo or not, and perhaps the case may belong to the first category rather than to that in which it has been placed.

3. Romiti (33). An oval vesicle covered with villi, and containing in its interior a small curved embryo. On microscopic examination, no traces of organs were discoverable, but two masses of cells at the extremity, supposed to be cephalic, might represent the optic vesicles, in which case the form would belong to the atrophic category. Many deeply staining cells were visible in the embryo.

C. *Atrophic.*—1. Giacomini (14). Ovum at the commencement of the 2nd month. Microscopic examination showed the existence of a completely disorganised medullary canal and

cerebral vesicles. There were no traces of blood-vessels in the cord or in the embryo, which latter contained masses of round cells.

2. Giacomini (17). A pyriform human embryo, resembling to the naked eye a very small rod-like tubercle, divided by two sulci into three dilatations. The anterior and largest of these consisted of lymphoid cells and spaces containing epithelium (? nerve tube). The middle consisted of round cells, and the posterior was a vesicle with broken down contents (? an appendage of the umbilical cord). In the amnion there were traces of vessels as masses of deeply staining nuclei. He notes the close resemblance between this atrophic embryo and those artificially obtained in the rabbit (13).

3. Giacomini (16). Tubal pregnancy of about two months. Consisted of a free cephalic and attached caudal extremities, and was reduced to a shapeless tubercle. The greatest volume of nervous system was observed in the cephalic extremity, but there was no trace of optic or auditory vesicles, nor of blood-vessels nor heart. (*Note.*—Lawson Tait (36) quotes a case of so-called ovarian pregnancy from Puech, in which, in a cyst of the ovary, there was a villous body, which on incision showed in its interior a cavity distended by a clear fluid, and in the fluid floated an embryo, in the form of a vermiform body, 1 mm. long, curved in the middle and swollen at one extremity. It was enveloped in an excessively delicate membrane, by which it was fixed to the presumed chorion. Mr Tait adds, "Of course, the whole conclusion in this case depends upon the assumption that this vermiform body, only 1 mm. long, was an embryo. It may have been one, but there certainly is no proof advanced in favour of this view; and although I am by no means prepared to deny its accuracy, I am certainly very doubtful about it. If it was an embryo, it could only have been one of a few hours' existence." The case just cited seems to show that this may well have been an atrophic embryo, and of much greater age than Tait is prepared to allow.)

4. Chiarugi (6). A two months embryo, with an amniotic sac, and a caruncle representing an embryo possessed of a rudimentary umbilical vesicle. Microscopic examination showed traces of a medullary canal and a rudimentary heart. Masses

of deeply-staining round cells infiltrated the embryo. The author regards the specimen as one of an atrophic embryo of an exceedingly advanced stage.

5. Giacomini (15). Ovum of two months, containing a slightly curved tubercle with an umbilical cord. The embryo showed externally crystalline lenses, the first pair of branchial arches, a tail, but no limbs. On microscopic examination, the medullary canal was visible, but no optic vesicles, two aortæ, with traces of blood-corpuscles. There were no traces of blood-vessels in the cord.

6. Kollmann (24). An embryo with hydrops of the cœlom, small ectopic heart, atresic veins and arteries of the heart, no blood-vessels on the yolk-sac, deficient development of the branchial arches and inferior extremities.

7. Kollmann (24). Embryo with partial ectopia of the heart, arrested development of head, eyes, nose, and branchial arches. No upper extremities. Blood-vessels very sparse, and none in the yolk-sac.

8. Phisalix (30). Embryo of six weeks, the shape of which was fairly evident. He sums up his description by saying that it exhibited "troubles of secretion between the chorion and amnion, with adhesions of the latter to the former and to the umbilical vesicle, absence of liquor amnii, stripping-off of the ectoderm, disappearance of the medullary canal, with foldings of its walls and alterations of the nervous elements, absence of nerve ganglia, absence of the Wolffian duct at its lower end, and general alteration of the epithelia. He especially notes that the epithelia are the tissues most readily affected by pathological processes.

9. His (21). A malformed embryo, in which the nervous tube was distinguished by its being particularly swollen. Several of the organs were distinguishable, but these organs and the cavities of the body were infiltrated with numerous small round cells, with deeply-staining nuclei. The author concludes with regard to these and similar forms, that

(1) Embryos which for any reason are arrested in their development, can, without completely degenerating or being absorbed, remain for weeks or even months within the membranes.

(2) The first changes in dead embryos consist in a marked swelling of the nervous system, as a consequence of which more or less remarkable transformations of the head appear.

(3) Very soon afterwards, there takes place an infiltration of the tissues with small wandering cells. The original limits of the organs are thus obliterated: the cells of the organs may remain for a long time, but appear finally to degenerate.

4. The externally visible consequences of these events are turbidity and whiteness of the embryo, and loss of definiteness of the original surface-markings.

With regard to these cases the most important points to be noticed in the present connection are (1) the absence of blood-vessels or their diminution in size (B. 1, C. 1, 3, 5, 6, 7).

(2) Infiltration of the tissues with small round deeply-staining cells (B. 2, 3, C. 2, 4, 9). Both of these points will appear significant in connection with the observations made in artificial teratogeny, which it will next be necessary to discuss.

Section II.—Early Malformations Artifically Produced.

Many observers have noted that it is possible to produce alterations in the area vasculosa, with consequent effects upon the embryo, by interfering with the process of incubation. Amongst these the work of Panum and Dareste first calls for notice. Panum (28), who lays especial stress upon the importance of examining early malformations of the embryo, gave in 1862 a careful description of the conditions which he had observed. Many of these are associated with more or less defective forms of the area vasculosa, coupled with deficient development of the embryo. A group called by him defective area vasculosa formations shows scanty blood-islands, without sinus terminalis. There is generally no trace of embryo, or it is only represented by a heaped-up mass of cells. He believes that the abnormal development of the embryo is associated with and caused by that of the area vasculosa, and concludes—(1) That the development of the embryo is not always brought completely to a standstill by a primary disturbance of the nourishment and of the area vasculosa, but that it can still

proceed even if the development of that part is deranged. (2) That the disturbed development of the vascular area is antagonistic to the normal development of the embryo, and produces malformations of the same. It should be mentioned that in another paper (29) the same author alludes to some of these changes, describing alterations in the embryo previous to the formation of the blood-vessels, which he calls parenchymatous inflammation, and others subsequent to their development, which he terms embryonic inflammation. In either of these cases he says the results are the same, viz., (1) abortive atrophy, or (2) heterologous agglutination. It is, however, obvious that the term "inflammation" cannot be accurately applied to the changes which he describes.

As early as 1883, Dareste (7) stated his opinion as to the malformations now under consideration. In the earliest times of embryonic life, he says, the embryo perishes through a peculiar anæmia of which I have described the mechanism. When an arrest of development attacks the islands of Wolff, the blood-corpuscles which are developed in their cavities cannot penetrate the circulatory apparatus. The blood, deprived of globules, causes more or less œdema of the embryonic tissues, and, as a consequence, their disorganisation. These views respecting the connection of deficient blood-formation with œdema are supported by Wernitz (39), who believes that, as a consequence of such a defect, a general anæmia of the embryo may be produced with subsequent hydrops. In the last edition of his classical work (8) Dareste develops the views above stated still further. In the account there given, he first shows that the simplest modification of the blastoderm is the formation of an elliptical instead of a circular figure. This is occasioned by so arranging the egg in an open incubator that its highest point and the point of contact with the source of heat do not coincide. This malformation is not in itself of much importance, save in so far as it serves as a simple example of a malformation of the annexes of the embryo, and the only one, according to the author in question, which can always be produced by a definite and distinct procedure. The more important deviations from the normal consist in a defective formation of the area vasculosa, with isolation of the blood-

islands from absence of anastomotic communications, and their consequent failure to communicate with the interior of the embryo. Hence the fluid circulating in the blood-vessels of the embryo is colourless. As a consequence of these circumstances, dropsy of the embryo takes place, with its subsequent degeneration, either total or into an amorphous mass.

The nature of this class of early malformation having been noted, it is next important to observe that these identical malformations of the area vasculosa and embryo are amongst the most common results following upon any of the various methods of disturbing development hitherto practised. The following observations will render this point clear:—

A. *Varnishing the Egg.*—Varnishing or otherwise covering the shell either completely or in part with a coating impermeable to air, is a proceeding which has been practised by various investigators. Amongst others, it has been tried by Panum, Dareste, and Gerlach and Koch (12), the last-mentioned stating that the decrease of oxygen causes dwarfing of the embryo with delay of ontogenesis. This proceeding, according to Tarulli (37), not only hinders respiration, but also affects pressure and temperature. The air-chamber regulates pressure, and the surface of evaporation regulates temperature. It is only when these two conditions are naturally fulfilled that respiration can remain normal. It is unnecessary to enter fully into the observations of different experimenters, and I shall only briefly summarise my own results, of which a sufficiently full account has already appeared. The incubator used in these and the other experiments was at first the ordinary bacteriological form, furnished with ventilators and water-dish, and the temperature was regulated by Dr Nicol's useful modification of the mercurial thermostat. Subsequently I used one of Hearson's Champion Incubators, with which I have had every reason to be satisfied. The eggs were coated with an impervious varnish, the position and size of the uncovered patch being varied in different experiments. Sometimes it was placed at the vertex, sometimes below; sometimes at the blunt end, at others at the sharp. I have left two or more small patches uncovered and have varied the shape of the patch, but the results obtained do not seem to have been appreciably affected

by these changes. The abnormalities with which I am concerned in this paper being those of the area vasculosa, I shall not at present deal with any others. I divide these into two classes—(1) irregular area vasculosa, without any evident embryo; (2) irregular area vasculosa, with a more or less ill-formed embryo, or an amorphous mass representing the embryo. In both these classes the area vasculosa consists of a more or less incomplete ring, often of abnormal size, of small blood-flecks occupying the position of the sinus terminalis. In its interior are other isolated blood-islands in greater or less number. Occasionally some of these are connected with one another, but not usually with the embryo itself. In other instances a few are connected with the embryo, but the greater part of the area vasculosa is unconnected. The number of eggs experimented with in this manner was sixty-four. Of these, twenty-three showed no sign of development, six had deficient areæ vasculosæ without evident embryo, and twenty-five defective areæ vasculosæ with a more or less altered embryo.

It would carry this paper beyond its proper limits if I were to describe the various modifications in the embryo, and I therefore reserve the consideration of some of the forms for the present. I will only say that sometimes it was represented by an apparently shapeless mass, and at others was dead, and showed that whiteness and loss of regular contour to which His has alluded in connection with human embryos. The defective formation of the area vasculosa which I have noticed as produced in these cases is so similar to that described and figured by Panum, Dareste, and Lombardini, that I need delay no longer over it, nor is it necessary to present any figure of the condition. The ten eggs not hitherto accounted for presented features not at present under consideration.

B. *Electricity.*—So far as I am aware, the first experiments of this kind were made by Prévost and Dumas, but the account of their observations is too scanty to be of any value (31). It is otherwise with the researches of Lombardini (26), which are given at considerable length in his book. The last mentioned experimenter applied the constant current to the eggs of the hen and of the frog during development. In the former, the treatment led to a number of malformations, amongst which

may be mentioned hyperæmia of the head, vascular tumor of the eye, with early anencephalus, deformity of the entire body, &c.

Speaking generally of his experiments, he says that the effects of the disturbance may be either general or local, and that in the former case there follows total atrophy, mummification, and death after a short period. He also remarks that the commonest occurrences at an early period are hydræmia, accompanied by atrophy. Processes of hypertrophy, atrophy, and necrobiosis may occur in the embryo, dependent solely upon changes in the material of nutrition. His most important remark in connection with the subject of this paper is, that he has not seen any malformed case in which the albumen, vitellus, and blood were not more or less altered. In his experiments, as in mine, the frequency of occurrence of vascular lesions, whether of anæmia or of hyperæmia, is especially noteworthy. I have not dwelt upon the former condition, because it is foreign to the purpose of this paper, in which early anæmia is the defect under consideration. It is, nevertheless, one of great importance, and I hope to deal with it on some future occasion when my observations on this point are more complete. In my experiments I used a battery which was devised for me by my colleague Professor Poynting, which he calls a sawdust Daniell. He was good enough to ascertain for me that such a battery was capable of transmitting a current through an egg, which could be distinctly recognised by its effect upon a Thomson galvanometer of low resistance. The egg-shell was perforated at its extremities by two extremely small holes, into which were introduced the platinum wires used for making connections between contiguous eggs and the battery. The wire in each case perforated the albumen for about one-quarter of an inch. The apertures being exceedingly small, were almost entirely closed by the wires, but in order to complete the closure, I used, in the earlier experiments, a drop of sealing-wax. In the later series, in case the heat of the wax should prove a disturbing factor, I substituted canada balsam dissolved in chloroform, which answers the purpose very well. I did not, however, notice any particular difference between the series conducted under the former as compared with the latter conditions.

The results obtained were briefly as follow. Not including batches which failed from one reason or another, chiefly on account of the difficulty of obtaining really satisfactory eggs in the centre of a large city, thirty-two eggs were submitted to the influence of the current from the commencement of incubation, in four series. Of these, five presented defective areæ vasculosæ with malformed embryos, and one without embryo. A number did not develop, and a larger proportion proceeded to normal development than in the varnished series.

There were other malformations noticed, notably one case in which the eye and orbit of one side were totally absent, whilst the other was normally formed. There did not seem to be any relation between the development and the position of the eggs with regard to the positive or negative poles or the centre of the circuit. It should be mentioned that of sixteen control eggs used in these experiments, two presented defective areæ vasculosæ with malformed embryos. I have tried one small series with the interrupted current. The eggs were wired as in the former experiments, and allowed to develop for twenty-four hours in the incubator without further disturbance. At the end of this period a weak current, unappreciable to the finger, was transmitted for fifteen minutes from a small single-cell bichromate battery. Four days afterwards the eggs were opened. The first showed a small defective area vasculosa without trace of embryo. The second, a small embryo, with umbilical vessels and blood-islands, well-developed, but small, white, turbid, and with small hæmorrhages at the posterior end. The third had no visible area vasculosa; the embryo was small, but to the naked eye normally developed. The heart and aortæ were full of blood, and a few twigs entered the body. The embryo was dead, turbid and white. The other three eggs had not developed. I hope to continue this class of experiments further. In connection with these electrical experiments, the well-known effects of currents upon blood-corpuscles under the microscope should be remembered. Dr Fell (10) states also that blood taken by himself from the temple of William Kemmler (electrocuted at Auborn prison in 1890), the first man executed by electricity, seven minutes after the electric force had been turned off, presented marked peculiarities. Fully one-

third of the field presented granular particles of protoplasm ranging from the full-sized corpuscle to the size of ordinary granules. Protrusion of the protoplasm from the corpuscles was frequently noted. He also states, "without further consideration of the influence of the electric current upon the lower forms of life, it may be seen that the influence is positive in its character; that we have with the weaker currents an undoubted electrolysis produced, and with the stronger or a long continued influence of the current a lowered vitality of the protoplasm."

C. *Magnetism.*—The effect of incubating eggs laid between bar-magnets has been tried by Maggiorani (27). The eggs were exposed during incubation to the influence of powerful magnets. A similar set of eggs, hatched in the same manner, but kept away from all magnetic influence, served as controls. Cases of arrested development were four times more numerous in the former than in the latter group. Microscopic examination showed that the sterilisation of the germs was probably due to an intense vascularisation of the yolk-sac. After the birth of the chickens this increased mortality continued, deaths being three times more numerous in the magnetised group. In view of these experiments, Slater (35) tried the effect of magnetic influence upon the development of caterpillars. Of three caterpillars of the common large white (cabbage) butterfly, two did not develop and the third was a cripple. It had merely rudimentary stumps in place of antennæ, the wings on the left side were expanded, and the legs on the same side were smaller than on the right. Three other caterpillars of the same batch, allowed to develop under similar conditions, but without the magnetic influence, exhibited no deviations from the normal. I have tried a few series of experiments with hens' eggs, but on account, possibly, of the magnets not being strong enough, without any very definite results.

D. *Light.*—Blanc (3) has tried the effect of submitting the embryo during incubation to the influence of a bright, cold light. He finds that the embryo is sometimes normally developed, but smaller than normal embryos of a corresponding age. Sometimes the development of the embryo is accompanied by an imperfect development of the area vasculosa, which is sometimes too small, at other times its vessels contain only a colour-

less fluid, or the blood-islands develop in an irregular manner, containing corpuscles only at certain points, or finally, the arrest may be complete. These imperfect conditions of the area vasculosa coincide frequently, but not always, with abnormal formation of the embryo or of the amnion, such as absence or atresia of the amnion, hydrops, heterotaxy, omphalocephaly, cyclops, atrophy of the head. Finally, but very rarely, the embryo is unformed, rudimentary, or dead. He concludes, therefore, that white light has a destructive effect on the cells of the blastoderm in the hen's egg.

E. *Experiments on Rabbit Embryos.*—It may, lastly, be mentioned that Giacomini (13) has conducted several series of experiments on the embryos of rabbits, his method of procedure being described in the paper referred to. The disturbance has been produced by (1) withdrawal of fluid from the blastodermic vesicle, (2) puncture of the same, (3) introduction of a foreign body into the same, (4) puncture with pressure, (5) ligature of a part of the uterus. The general effect of these experiments was to arrest development. In some cases an atrophic embryo was formed, the resemblance of which to those found in human abortive ova has already been alluded to.

From these observations it follows that a common, indeed it might with reason be said the most common, consequence of early interference with the processes of development is a derangement of the growth and progress of the area vasculosa and of the elements arising with it from the region around the body of the embryo. Though this is not the only effect produced, it is a very common one, and the frequency of its occurrence in the experiments of different observers and under varying conditions is remarkable.

SECTION III.—PRIMARY RESULTS OF THE DISTURBANCE OF THE DEVELOPMENT OF THE AREA VASCULOSA.

From the area around the embryo-proper develops that part of the mesoblast which is known as the parablast or mesenchyme, and from which is developed the vascular and lymphatic systems and the connective tissues. This view put forward by His and the Hertwigs, in a more or less modified form, seems to be gaining

general acceptance. Thus Ziegler (41) states that the blood and lymph vascular systems are phylogenetically derived from the lymph vascular system. In ontogeny it may be seen that some of the first vessels to arise are parts of the primary cœlom, and are gradually shut off from it. The red-blood corpuscles arise ontogenetically from the solid venous rudiments, and in histological regeneration they arise similarly from the venous capillaries; the red-blood corpuscles belong both in origin and function to the blood-vascular system; they do not arise from the white corpuscles in the blood, but have a similar origin with them, insomuch as they are derived from the histological foundation of all the mesenchymatous tissues. Again, Van der Stricht (34) states that the first blood corpuscles appear at the level of the area vasculosa, and at the expense of its mesoblastic constituents. These all have the characters of red-blood corpuscles. The white-blood corpuscles arise later, and are also mesoblastic. Interference with the development of the region from which the mesenchymatous elements are derived, such as appears to take place in the experiments detailed above, will produce (*1st*) a failure in the development of the blood-vascular system in the manner described by Dareste; (*2nd*) irregular development of the connective tissue elements also derived from the mesenchyme. This second fact gives an answer, I think, to His's question as to whence the round cells come which he noticed in such numbers infiltrating the tissues and filling the cavities of the embryo which formed the subject of his paper. That these round cells are derived from the mesenchyme will, I think, seem the most probable explanation. This has, indeed, in part been suggested by Giacomini in explaining the reason why his nodular embryo does not present the masses of round cells which are found in the atrophic forms. He says that at the period at which the embryo perished, the mesoblast had not arrived at the importance in development which it afterwards attains, and that consequently the small, round lymphoid elements which are mesoblastic in origin are not present in this embryo. These round cells have been found, as has already been noted, in a number of the malformed human embryos, and are regarded by His as of especial interest. I have also found them in microscopic sections of the atrophic chick embryos

obtained artificially in the incubator. These embryos contain remains of the nerve-tube, of some of the organs, and masses of round cells. They thus belong to the class described by Giacomini as atrophic, and the similarity of the appearances presented under the microscope is another proof of the identity of the malformations and of the proximate causes which produce them. Summing up the facts of this section, it may be concluded—1*st*, that the amorphous (atrophic) embryos found in hens' eggs as the result of a disturbance of some kind of the process of development are due to (*a*) an irregular development of the vascular elements which consists in imperfect formation and isolation of the blood-islands, their failure, either total or partial, to connect with the vascular system of the body of the embryo, together with (*b*) the formation in large numbers of round cell elements which infiltrate the tissues of the embryo; 2*nd*, that similar causes lead to the formation of the irregularly shaped atrophic human embryos, as shown by the faulty development of the blood-vascular system in these forms, and their infiltration with numerous round cell elements.

Section IV.—Later Malformations due to Deficient Vascularity.

The cases which have been considered in this paper are those in which the interference with the development has been so early in date and so serious in nature as to lead to grave changes in the mesenchymatous tissues, having as a consequence the early death and degeneration of the embryo. I have, however, been able to make some observations which lead me to believe that a partial occurrence of similar changes, insufficient to cause the death of the embryo, may afford a clue to the etiology of some of the malformations exhibited by the embryo at term, or at least at a period when the various organs and parts have become fully differentiated. My observations on this point are not yet complete, but I hope that the experiments upon which I am now engaged will enable me to speak with more certainty upon this point in a later paper. At the present time, therefore, I will only note the following points as probably bearing upon

this part of the question. (1) The probable association of a local dropsy with some of the forms of body cleft. (2) The existence of a single umbilical artery in cases of sirenomelia and its allied conditions, a fact now well established (Förster (11), Ahlfeld (1)). (3) Wernitz's collection of cases (39), showing that certain malformations may co-exist with arterial deficiencies, of which the following may be mentioned,—(*a*) Duncan (9), anencephalus, with carotid arteries ending at the base of the skull; (*b*) Budin (2), hydrocephalus, with small carotid arteries; (*c*) Klebs (22), atrophy of right temporal and parietal lobes, with small arteries; (*d*) *ib.*, hydroanencephalus, with no right internal carotid artery; (*e*) *ib.*, microanencephalus, with closure of vessels. To these might be added other cases which I reserve for the present.

SECTION V.—CONCLUSIONS.

It is necessary to exercise caution in drawing conclusions in so large a subject, and one where there are so many possibilities of mistake, but I think the following points may be at least tentatively put forward as following from the facts described in the foregoing pages:—

1. That whatever the nature of the disturbance applied to the developing embryo, the results which follow are in many if not most of the cases absolutely identical.

2. That these effects for the most part manifest themselves in connection with the area vasculosa and the mesenchymatous region.

3. That they consist in faulty development of the blood-islands, and frequently to their failure to connect with the blood-vessels of the embryo.

4. That, further, they lead to the irregular development of numerous round cell elements which infiltrate the tissues of the embryo.

5. That the results are dropsy or degeneration of the embryo, which is found to present deficient vascular development and an infiltration with round cells, the embryo itself being ill-shaped, and many of its parts so ill-developed that its normal shape is not recognisable by the naked eye.

6. That, finally, it is probable that partial failures of a similar kind may lead to the production of some of the later types of malformation of the embryo.

REFERENCES.

(1) Ahlfeld. Die Missbildungen des Menschen.
(2) Budin. *Progrès Médicale*, 1875, No. 34.
(3) Blanc. Note sur les Effets Tératogéniques de la Lumière Blanche sur l'Oeuf de Poule, *C. R. de la Soc. de Biol.*, Dec. 17, 1892.
(4) Chiarugi. Di un uovo umano del principio della seconda settimana. *Boll. della Soc. tra i Cultori di Sc. Med.*, Anno v. 1887.
(5) Ib. Anatomia di un Embrione Umano. *Atti della Soc. Tosc. di Sc. Nat.*, vol. x.
(6) Ib. Intorno a un Uovo Umano Mostruoso. Lo Sperimentale A. xlv.
(7) Dareste. *Comptes Rendus*, 1883, I. p. 1673.
(8) Ib. Récherches sur la Production Artificielle des Monstruosities. Ed. 2. 1891.
(9) Duncan. Ref. by Wernitz to *Oest. Jhrb. f. Pädiatrik.*, 1876, I.
(10) Fell. The Influence of Electricity on Protoplasm. *Am. Monthly Mic. Jl.*, Aug. 1890.
(11) Förster. Die Missbildungen des Menschen.
(12) Gerlach und Koch. Ueb. die Production v. Zwergbild. im Hühnerei auf Experiment. Wege. *Biol. Centralbl.*, Bd. II. Nr. 22.
(13) Giacomini. Teratogenia Sperimentale nei Mammiferi. *Gior. d. Reg. Acc. di Med. Torino*, An. 1889, Num. 6–7.
(14) Ib. Su Alc. Anom. di Sviluppo dell' Emb. Umano. *Atti della R. Acc. delle Sci. di Torino*, vol. xxiii.
(15) Ib. ib. Communicazione ii. ib. vol. xxiv.
(16) Ib. ib. ,, iii. ib. vol. xxvii.
(17) Ib. ib. ,, iv. ib. ,, ,,
(18) Ib. ib. ,, v. ib. ,, ,,
(19) Ib. ib. ,, vi. ib. ,, ,,
(20) His. Anat. Menschlicher Embryonen, Bd. ii. s. 98.
(21) Ib. Offene Fragen der Pathologischen Embryologie. Int. *Beitr. z. Wiss. Med.*, Bd. i.
(22) Klebs. Ref. by Wernitz to *Oest. Jhrb. f. Pädiatrik*, 1876, i. s. I.
(23) Kolliker. Entwick. d. Menschen u. d. höheren Thieren., s. 304.
(24) Kollmann. Körperform Mensch. Norm. u. Path. Emb. *Arch. f. Anat. u. Path.* Jahrg. 1889, s. 105.
(25) Lachi. Di un Uovo Umano Mostruoso. *Monit. Zool. Ital. An.* ii. No. 10.
(26) Lombardini. Forme Organiche Irregolari negli Uccelli e ne' Batrachidi. Pisa, 1868.
(27) Maggiorani. *Atti. R. Acc. dei Lincei, Trans.* viii. (1884) p. 274. (*Jl. Roy. Mic. Soc.* iv. 861.)
(28) Panum. Untersuchungen üb. die Entstehung der Missbildungen, 1860.
(29) Ib. Beitr. z. Kenntn. d. Phys. Bedeut. d. Angeb. Missbild. ii. *Virch. Arch.*, Bd. 72.
(30) Phisalix. Contrib. a la Path. de l'Emb. Humain. *Jl. de l'Anat. et de la Phys.*, T. xxvi.
(31) Prévost et Dumas. Mém. sur le dev. du Poulet dans l'Oeuf. *Ann. de Sci. Nat.*, T. xii. (Ser. i.) p. 417.
(32) Reichert. Besch. einer Frühzeitigen Mensch. Frucht in Bläschenförmigen Bildungzustande. *Abh. d. Ber. Akad.* 1873.
(33) Romiti. Nota di un Uovo Umano Mostruoso. *Atti Della Soc. Tosc. di Sc. Nat.*, 1888.

(34) Stricht van der. *Arch. De Biol.*, 1892, 199. (*Roy. Mic. Soc.*, 1892, 589).
(35) Slater. *Trans. Entom. Soc.*, Lond. 1885. *Proc.* p. xv. (*R.M.S.*, v. 988).
(36) Tait. Lectures on Ectopic Pregnancy and Pelvic Hæmatocele, p. ii.
(37) Tarulli. *Atti Acc. Med.—Chi. Perugia*, 1891, p. 121. (R.M.S. 1891, p. 21).
(38) Valenti. Intorno ad una anomalia di Sviluppo dell' Uovo Umano. *Atti Acc. Med.—Chi di Perugia*, vol. iv., 1892.
(39) Wernitz. Die Spina Bifida. *Inaug. Diss.* Dorpat. 1880.
40) Windle. Investigations in Artificial Teratogeny. *Proc. Birm. Phil. Soc.*, 1891.
(41) Ziegler. *Ber. Naturf. Ges. Freiburg.* iv. s. 171. (R.M.S., 1889. 725).

CYSTIC DEGENERATION OF THE HEART, SPLEEN, LIVER, AND KIDNEYS. By ARTHUR V. MEIGS, M.D., of Philadelphia.

THE history of the patient is as follows:—He was seventy-seven years of age, and was born in England, but had been fifty years in America. By trade he was a printer, and had stopped work only six weeks before coming to the Pennsylvania Hospital. There was obtained no history of hereditary disease in his family. He denied having had syphilis, but said he had drunk pretty freely all his life. Ten years before coming to the hospital he had had much bleeding from the nose, and for several years dyspnœa on going upstairs, and had passed very little urine. For six weeks he was ill; having had vomiting, aching all over the body, very infrequent micturition, and dyspnœa. He said his feet had never swollen. The attack was at first supposed to be sunstroke; for when it came on, six weeks before his admission to the hospital, the weather was excessively hot, and he was taken sick on the street. He came to the hospital August 8th, 1892, exceedingly ill. By the 12th he was much worse, dyspnœa and hebetude having increased until they were excessive. August 13th, there was retention of urine, and forty ounces were drawn with the catheter. The urine contained no albumen, but there was a decided urinous odour of the body. There was bloody expectoration, and the stools were bloody. August 14th, as no urine was passed, the catheter was again used, but the bladder was found to be empty, though blood was passed from the urethra, and there was pain over the bladder. There was on this day very profuse diarrhœa, the stools being bloody. Later, he died.

No careful physical examination was made while he was in the hospital, as he was at all times too ill to be disturbed. The temperature was always sub-normal, except that for a short time on the 11th it was as high as 99⅖°.

Post-mortem examination was made fourteen hours after death. *Lungs.* The pleural sacs were obliterated by adhesions, and the lungs themselves intensely injected. *Heart.* The pericardial sac was also

obliterated by adhesions. The walls of the heart were thin and flabby, and the cavities dilated. The valves were natural. The arteries were in places calcareous, and there was some chalky deposit in the diaphragm. *Liver* was enlarged, hardened, dark in colour, and firmly adherent to the surrounding parts. *Spleen* was enlarged, and firmly adherent. *Kidneys* were buried in dense fat. Externally they looked about normal in size, but on section it became apparent that they were reduced by about one-third, the central spaces being filled with masses of fat. There were numerous small cysts and two

Fig. 1.

quite large ones. The surface was rough and the capsule somewhat adherent. *Bladder* was thickened, and contained a small amount of bloody urine. Pieces of the heart, liver, spleen, and kidney were placed in 70 per cent. alcohol for microscopical examination.

Unfortunately, I was unable to be present at the time the *post-mortem* examination was made, and nothing was noticed at that time beyond what has already been described. When I came, however, to examine the pieces of heart, liver, spleen, and kidney which had been saved for me for microscopical examination, a very unusual appearance became at once evident. There were pieces from 1 to 2 inches across of each of the four previously mentioned organs. On section in any direction they are seen to be absolutely riddled with cavities, a surface $\frac{3}{4}$ of an inch square containing quite commonly as many as fifty. Some of the cavities are as much as $\frac{1}{8}$th of an inch in diameter, and from this size downward to the very smallest. In the

liver, spleen, and kidney the cavities are spheroidal, or irregularly so at least, while in the heart the shapes are very variable, being often two or three times larger in one diameter than in another. This



Fig. 2.

does not seem at all surprising when the nature of the heart tissue is remembered, the muscular fibres running in parallel bands, so that if

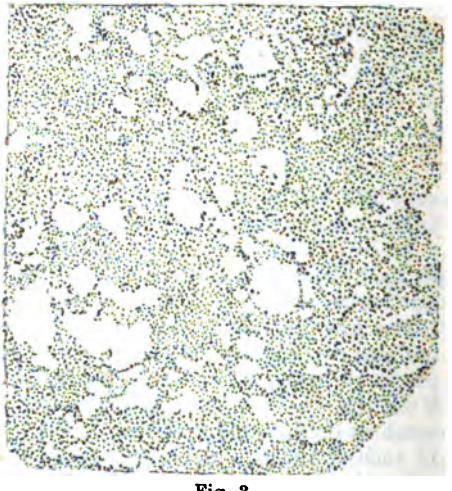

Fig. 3.

any force was brought to bear to tear them, the fibres would separate from each other much more easily than break across their length.

The cavities were all filled with liquid, which to the naked eye appeared to be clear.

These cavities in all four of the organs have the ordinary appearances of minute cysts, none of them appearing to have anything in the most distant way resembling solid contents. In many places the

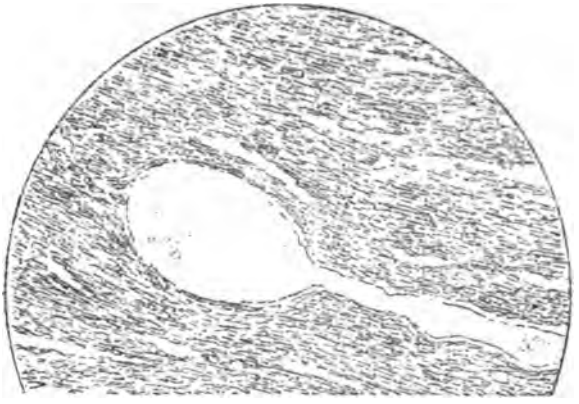

Fig. 4.

cysts are so close to each other that they are separated only by a thin membranous wall, and again there are openings from one to another.

Sections were cut of the organs for microscopical examination. The muscular fibres of the heart are rather opaque-looking, and the cross striæ are hardly distinguishable. The fibres are separated more

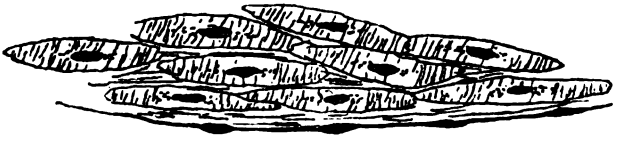

Fig. 5.

widely from each other than is natural, and there is very decided increase of the intermuscular connective tissue. The fibrous or connective tissue increase is especially marked near the endocardium and around the portions of papillary muscle in the sections. Around the papillary muscles there is also some fatty tissue. Near the endocardium and around the papillary muscles there are a great many brightly stained connective tissue nuclei. The cysts at most portions of their circumference are directly surrounded by the muscular tissue of the heart, there not being in most places a differentiated cyst wall, and in many places the muscular fibres are not even more densely pressed together around the cysts than elsewhere. Careful examin-

ation, however, brings to light the fact that in some places there is a most distinct cyst wall, quite different in its constitution from the muscles. In positions where this has been cut through perpendicularly so as to display it in the sections to the greatest advantage for study, it presents appearances precisely similar to those of the capillaries of the heart which I described a year or two ago.[1]

There is a fine structureless or fibrous membrane, the so-called basement membrane, and in it, here and there, small somewhat flattish nuclei, like the common endothelial nuclei of capillaries and of the intima of arteries. This differentiated cyst wall is much more commonly distinguishable in small cysts than in the larger ones; and if it is seen in those of large size, it is usually only small bits of it, thus giving the impression that the membranous walls had been torn through and destroyed as the cavities grew larger from the increase of the quantity of liquid contents. In places there is marked condensation of the muscular tissue around the cysts, and in many of the sections, here and there, portions of cyst contents have been caught, this consisting of a grumous structureless material, hardly taking the carmine stain. The amount of cyst contents must have been very small, a little flaky material hanging or floating in the liquid, hardly sufficient to make the liquid turbid, much less to give it the slightest appearance of solidity.

The liver cells are shrunken, distorted, and granular, none of them being natural in appearance. In many places only fibrous tissue is visible, but the appearance of such areas suggests rather that the liver cells had degenerated and disappeared, than that the amount of fibrous material was increased. The appearance is much like what may be seen in abscess of the liver when the secreting cells have rapidly broken down and disappeared, leaving behind only the fibrous network, and even it being misshapen from being pressed together. The blood-vessels are thickened, the branches of the hepatic artery especially being in places so thick as to be almost solid cords, there remaining only a very small opening. The bile ducts are not at all enlarged. The epithelial layer in some of them is still present, and outside of it the ducts consist of dense and thickened fibrous material. The cysts are principally surrounded by liver tissue; and as throughout the whole organ the secreting cells are small, and the amount of connective tissue visible great, this holds good around the cysts as elsewhere, and the fibrous framework as well as secreting cells are visible at the periphery of the larger cysts. In some of the larger cysts quite dense fibrous material may be seen at their periphery, and it is impossible to say whence this fibrous tissue had its origin. It frequently happens that many cysts of smaller size may be seen close to each other, and these are generally surrounded by a cyst wall of fibrous material, broken through in places, the cysts thus often communicating with each other. A distinguishable cyst wall is generally the rule in small cysts, and on the other hand generally

[1] "The Microscopical Anatomy of the Human Heart," *Trans. of the Col. of Phys. of Philadelphia*, April 1891, and *The Amer. Jour. of the Med. Sciences*, June 1891.

absent in large ones. Flattened cells are often visible in these membranous partitions, but they are quite large, and by their appearance suggest rather that they are altered and distorted liver cells than connective tissue cells.

The spleen shows great thickening of the capsule, and in places the remains of the inflammatory adhesions to the surrounding parts are plainly visible. The trabeculæ are thick, and so are the blood-vessels. In places the thickening of the blood-vessels is so great that the calibre of some of them is almost occluded, and the walls have a homogeneous appearance, the differentiation of the coats being lost. The cysts are in many places surrounded by a definite differentiated membranous wall, and again there is none. The presence of a wall is more common in the smaller cysts. The cyst walls have much the same appearances as have already been described as present in the heart.

The kidney exhibits a high degree of contraction, no portion of the sections containing any normal tissue. There is great increase of connective tissue, the cells are in various stages of extreme degeneration, and the blood-vessels are fibrous and thickened, and their calibres reduced. The cysts present the ordinary characteristics of renal cysts. Sometimes there is a differentiated cyst wall, but more commonly there is not, the renal tissue constituting the edges of the cavities. The presence of a specialised wall is much more common in small than large cavities. Structureless cyst contents are often visible in the sections, and again loose festoons hang from the walls into the cavities. It looks in many places as if some of the smaller cavities were cysts commencing in the Malpighian capsules. The capsule of the kidney is moderately thickened, and upon its surface can be seen the remains of fatty tissue in which it was imbedded, and to which it was fastened by adhesions.

Remarks.—The presence of cavities such as have been described in the four important organs, heart, liver, spleen, and kidney, must certainly be a very rare occurrence. In looking for a cause of the condition, the first things that suggest themselves to the mind are—Could the change be a *post-mortem* one, or is it Trichinosis? That it should be Trichinosis seems quite impossible, for a careful examination of the pieces of the organs which were retained, both the naked eye appearances and of sections with the microscope, fails to reveal anything resembling solid bodies in any of the cavities, much less anything that could be taken to be the parasites or remnants of them. That the cavities could be the result of changes which had taken place after death, is emphatically negatived by their appearance, which is that of ordinary cysts, and by the fact that conditions of disease were present in an unusual degree of development

which are common in cystic degeneration, or certainly in cases of cystic kidney. The kidneys were, as has been stated in the history, extremely contracted, and the heart fibroid, beside there being adhesion of all four of the organs to all the surrounding parts, the adhesive inflammation of the pleura and pericardium having been so extensive as to cause entire obliteration of their cavities.

It is much to be regretted that the *post-mortem* examination was not more thorough, for then search might have been made to ascertain if there was a parallel cystic condition of any of the other organs or tissues. If careful examination of the voluntary muscles had been made, and no evidences of disease found, this would have constituted a complete answer to anyone who might say the disease was Trichinosis.

To my mind, as a result of study of the case, has come the conclusion that the cavities in the organs are cysts. Cysts in the kidney are very common, and in the liver not very rare, but of cystic disease of either the spleen or heart I have not as yet been able to find any account. It is highly improbable that in a case of cystic degeneration of four of the most important organs in the whole economy they had different modes of origin, or are in any way different from each other, further than that they are in different sorts of tissue. That cause, therefore, which produced them in one organ, probably produced them in all. With regard to the ordinary cysts of contracted kidney, there seems to be no doubt amongst pathological authorities that they always arise either in the Malpighian capsules or in the uriniferous tubules, and it is very generally accepted that cysts in the liver originate in the bile ducts. Cysts are classified in two great divisions—true cysts, and pseudo-cysts or spurious cysts. The latter are those which arise in the substance of the organs or tissues as the result of hæmorrhage or disintegration, or other pathological process, while true cysts have their origin in the abnormal dilatation of a pre-existing tubule or cavity. It does not seem likely that the cavities which have been exhibited are spurious cysts, for such an assumption is negatived both by their appearance and by the fact that cysts precisely like these are so well known to occur in the kidneys and liver, which, so far as the kidneys are concerned, certainly are universally conceded

not to have had that mode of origin. It is probable, as has already been said, that the cavities in the four organs had a common mode of origin; but so far as the spleen and heart are concerned, there are neither pre-existing tubules nor cavities which could undergo abnormal dilatation except the blood-vessels and the lymphatics.

My endeavour in what has been said has been to lead up to the enunciation of these two propositions—first, that true cysts do sometimes have their origin in capillaries; and second, that the commonly accepted explanation of the mode of origin of renal and hepatic cysts does not rest upon any tangible evidence which is accessible to the ordinary pathologist, and that therefore it is at least open to doubt.

So far as the first proposition is concerned, it may be well for me to say that this case has been of great interest to me in that it has seemed to furnish more evidence toward proving the assertion I made a year ago,[1]—that certain cavities in the muscular fibres of the heart, the presence of which I pointed out, were cystic in their nature, that they were true cysts; and further, that they had their origin in the capillaries that I had described as lying within the muscular fibres. If it be conceded that these cavities are true, and not spurious cysts, and that such could only originate in the spleen and heart in either the blood-vessels or lymphatics, a long step would seem to have been taken toward the conclusion of their having originated in the blood-vessels.

The origin of cysts in lymph-vessels is a thing as yet almost unknown; and, on the other hand, dilatations of blood-vessels, arteries, veins, and capillaries, forming aneurism, varix, or capillary aneurism, is a most common pathological appearance. For my own part, I am unable to see why vascular tumors of either of the three sorts should be classified, as is commonly done, among the spurious cysts, for it is more easy to be sure that their origin was in a pre-existing duct than in the case of almost any of the cysts which are ordinarily classed as true cysts. Whatever may be the condition of the inner wall of the vascular

[1] "Cystic Degeneration of the Muscular Fibres of the Heart," by Arthur V. Meigs, *Trans. of the Col. of Phys. of Philadelphia*, 1892, and *The Amer. Jour. of the Med. Sciences*, May 1892.

tumor as a result of the stretching force which is exerted from within, there can be no manner of doubt of the place in which it originated. If, then, it is so well known that cysts do originate in blood-vessels, and we know but little of their origin in lymphatics, does it not seem just to assert that the cavities that have been shown to be present in the spleen and heart are true cysts, and that their origin was within the blood-vessels.

With regard to the second proposition, my mind has long been disturbed by a feeling of dissatisfaction with the ordinarily accepted explanation of the mode of origin of renal cysts—that they arise in the Malpighian capsules, or in the uriniferous tubules. That they arise in the uriniferous tubules, of course, may be the case, but I have never been able to find any evidence which would go to show that such is the case. So far as their originating in the Malpighian capsules is concerned, it would seem to be borne out by the fact that often in cases of contracted kidney (and it was so in this case) the Malpighian bodies can be seen in various stages of degeneration and destruction. and the capsules dilated; but there is no more reason for supposing that this dilatation is due to obstruction to the uriniferous outlet, than that disease of the capillary loop had occurred, and the dilatation had its origin within the blood-channel. What reason is there for saying that cysts in the kidney originated in the secreting structure, any more than that they may have had their origin in the blood-vessels?

EXPLANATION OF FIGURES IN TEXT.

Fig. 1. Camera drawing of a section of the heart, delineating accurately the size, relative positions, and outlines of the cysts. Magnified five (5) diameters.

Fig. 2. Section of the liver drawn under the same circumstances as the heart in No. 1. Amplification, the same as that of the section of the heart.

Fig. 3. Section of the spleen drawn as the heart in No. 1. The tissue having been softer than that of the heart and liver, the cysts are smaller than they were when the organ had just been removed from the body, it having shrunk somewhat in the dilute alcohol used to preserve it. Amplification, five (5) diameters.

Fig. 4. An accurate camera drawing of one of the smaller cysts in the heart multiplied fifty-seven (57) diameters. It exhibits the irregular shape of the cyst, and the manner in which the larger portion runs off into a channel, which is in many respects like a dilated capillary. It is seen also that the tearing apart of the muscular tissue in the process of formation of the cyst has been much more in the direction of the fibres than across them. Along the channel, upon both sides of the greater portion of its length, can be seen a fine line, which is precisely like the endothelial lining of ordinary capillaries. This fine membrane extends into the larger rounded portion of the cyst, but is there more broken and irregular than in the narrow channel.

Fig. 5. A somewhat diagrammatic representation of a portion of the channel or narrow part of the cyst drawn in fig. 4. The amplification used was about five hundred (500) diameters, and the proportions were sketched-in with the camera. The only purpose of the picture is to demonstrate the presence, in the fine membrane lining the channel, of nuclei, and its general resemblance to the ordinary walls of the capillaries of the heart. In the text will be found a fuller description of the appearances represented in figs. 4 and 5.

CASE OF CONGENITAL MALFORMATION OF THE HEART; WITH TRANSPOSITION OF THE AORTA AND PULMONARY ARTERY. By GORDON SANDERS, M.B., M.R.C.P. Ed.

CONGENITAL deformities of organs are of great interest from many points of view. Clinically, the recognition of such defects is of extreme importance, and especially so in the case of the heart, where it is possible to separate the condition from the diseases incidental to post-natal life; thereby frequently modifying both prognosis and treatment, sometimes profoundly.

But the etiological point of view is of even deeper interest, since the presence of malformations often serves to shed a light upon the obscure problems of development. In the heart, as in other organs, a condition may be thus perpetuated which otherwise is merely transient, and yet which is full of suggestiveness as to events occurring in intra-uterine life.

With this in view, it is both interesting and profitable to examine cases of congenital alteration of the heart; and viewing them in the light of the most recent work on development, to endeavour to understand the process which has produced them.

The following example of a not very common condition was obtained from the body of an infant dying at the age of seven months. It is not intended here to refer fully to the clinical facts of the case; but it will suffice to say that the presence of congenital disease was recognised during life by the presence of some degree of cyanosis, and the detection of a murmur, systolic in time, audible to the left of the sternum. There was no definite cause to be traced in the health of the mother, or the facts of heredity. The child died eventually of exhaustion, and the examination was made the following day.

Post-mortem Examination, Dec. 8, 1892.

General Appearances.—Body emaciated; no observable deformity; slight general lividity, especially back, hands, and feet. Ears, features, limbs fairly symmetrical.

Abdomen.—Except for some marked lobulation in the kidneys, the organs of the abdomen presented no alteration.

Thorax.—On opening the thorax, the heart was seen lying in its normal position, but showed a considerable increase in the size of the right ventricle, which passed 1½ inch to the right of the middle line of the body. The left border lay almost in the left nipple line, just internal to it and behind the fifth rib.

The lungs were somewhat retracted, but not markedly so, overlapping the right and left borders to a slight extent.

The right ventricle occupied almost the whole anterior surface of the heart; the left ventricle appearing as a narrow rim at the left border.

From the base of the heart arose one large vessel, lying immediately behind the left edge of the sternum, about the level of the 3rd cartilage, or a little higher. It passed almost vertically upwards, with a slight inclination to the right, and then bent sharply round and backwards to the left. This was evidently the aorta, and apparently rose from the right ventricle. No other vessel was apparent without disturbing the relations of the organ.

The right auricle was greatly enlarged, and curved round the base of the vessel referred to; the left auricle was very small, its top being only just apparent; partly overhung by lung.

On displacing the lungs, and more minutely examining the structures, a second vessel, evidently the pulmonary artery, could be seen lying directly posterior and slightly to the left of the anterior vessel (aorta). This vessel also passed almost vertically upwards, and soon bifurcated in the usual manner of the pulmonary artery. Just before the bifurcation occurred, the vessel was connected to the under surface of the aorta by a narrow ductus arteriosus.

No abnormality was detected in the distribution of either vessel, nor in the venæ cavæ, nor the pulmonary veins, nor in the vessels of the rest of the body, so far as examined.

The heart was removed from the body with the lungs attached.

The *lungs* were somewhat small and collapsed at their lateral aspects. These changes were, however, evidently recent. There were no areas of congenital atelectasis.

External Examination of Heart and Vessels.

Vessels.—The aorta rose from the left superior and anterior angle of the right ventricle, and passed, as above described, almost vertically upwards. From its left base rose the anterior coronary artery, which then travelled towards the apex of the heart, parallel to the septum. The posterior coronary artery rose posteriorly and to the right, between the root of the aorta and the root of the right auricle. It was distributed mainly to the posterior aspect of the right ventricle.

The aorta was otherwise normal in appearance; it measured 1·5 cm. in breadth.

The *innominate* vessel arose from the front of the aorta, at a distance of 2·8 cm. from the root of the aorta.

The *left carotid* arose 3 mm. from the innominate, while the left subclavian arose 5 mm. from the carotid.

Immediately beyond the last vessel, but on the lower border, the ductus arteriosus joined the aorta.

The *pulmonary artery* arose immediately behind the aorta, and very slightly to the left. It had an almost vertical direction to its division, and measured 2 cm. in length. The ductus arteriosus sprang from the right upper end, just before the bifurcation of the artery.

There was no other abnormality of the vessel.

Ductus arteriosus measured 1·6 cm. in length; admitted a No. 2 catheter. It was pervious throughout. The aortic end was larger than the pulmonary. (Aortic, 4 mm. broad; pulmonary, 25 mm.)

Superior vena cava, 1·3 cm. broad where it joined the right auricle. It showed no abnormality. Inferior vena cava and pulmonary veins normal.

Heart, measured transversely, 6·2 cm.; vertically, 6·8 cm.

Auricles—right, markedly hypertrophied and dilated. Extreme length, 4·5 cm.; breadth, 2·1 cm.; appendix, 1·5 cm. in length.

The wall was thickened, the columnæ carneæ being in some parts 4 mm. broad; even in the appendix the columnæ were very prominent.

The foramen ovale, though evident, was impermeable.

Left auricle.—Length, 2·5 cm.; breadth, 1·3 cm.

Appendix.—Length, 1·2 cm.; breadth, 4 mm. Much diminished in size. Contrast with right auricle marked. Walls thin and transparent. Columnæ carneæ small and flat.

Ventricles.—On opening the ventricles in the usual way, a deficiency was found to exist in the interventricular septum, lying in the middle from before backwards, and in the upper third of the septum from above downwards.

Right ventricle.—Length, 3·7 cm.; breadth of muscular wall 3 mm. There was obviously great hypertrophy of the wall, and

some increase in the chamber. The size equalled apparently that of the left ventricle. The columnæ carneæ were very prominent, and the papillæ somewhat hypertrophied. The auriculo-ventricular orifice lay in its normal position, while at the anterior and left corner of the chamber lay the aortic orifice. In the septum was evident the deficiency referred to, somewhat anterior to the tricuspid orifice, but quite posterior to the aortic orifice. The edges of the deficiency were smooth and somewhat bevelled, while at its lower edge two chordæ of the left tricuspid segment were attached by a small musculus papillaris.

Tricuspid valve.—Segments normal in number and position. There was a slight adhesion between the margins of the left and anterior segments, but hardly more than is not unfrequently seen in the heart at this age. Except for the attachment to the lower edge of the septal deficiency, the valve presented no abnormality.

The aortic valve lay anteriorly, immediately to the right of the well-marked anterior septum ventriculi. The cusps were normal in place and form.

Left ventricle.—Length, 3·5 cm.; breadth of wall, 3·5 mm. Almost equal in size to right ventricle, but, internally, columnæ less evident; no obvious hypertrophy. The septal wall was strikingly smooth, especially for distance of 1·5 cm. around the deficiency, which is still more evident from this chamber.

The auriculo-ventricular orifice lay in its normal position posteriorly, but the pulmonary artery, which, as above described, arose from the left ventricle, was placed at its origin close to the septum, immediately anterior and to the left of the anterior cusp of the mitral valve, and with the right wall of the artery in the same plane with the septum of the ventricles.

Mitral valve consisted of two segments, normal in position, size, and attachments. In addition, however, on the anterior aspect of the anterior segment were two irregular attachments, (1) by a thin chorda tendinea to the left surface of the interventricular septum, midway between base and apex, and (2) a short, thick chord attached to anterior lip of the deficiency of the septum.

There is also a thick band passing behind the latter, but parallel to it. Its anterior margin is free, but posteriorly it is

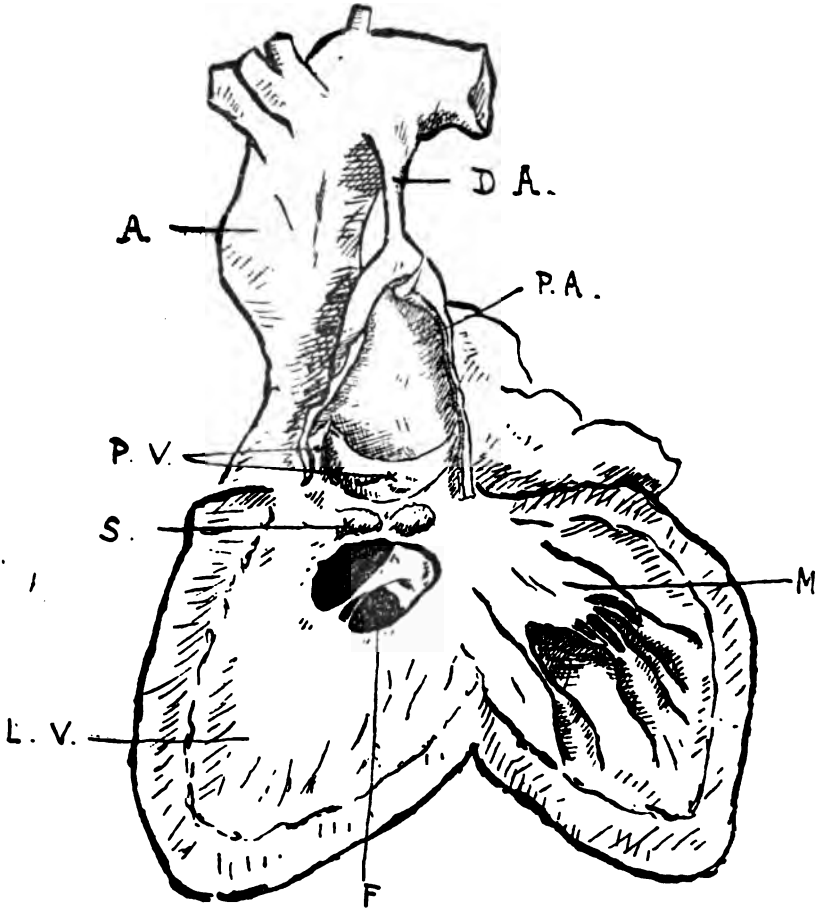

Heart, with Left Ventricle and Pulmonary Artery opened, seen from Left side. From a photograph.

A. Aorta arising from right ventricle.
P.A. Pulmonary artery arising from left ventricle.
P.V. Segments of pulmonary artery: right, seen in entire length; left, on reflected wall of artery.
S. Membranous septum, with two fibroid nodules attached.
F. Foramen leading into right ventricle; through the aperture is seen a portion of the tricuspid valve.
L.V. Left ventricle.
M. Mitral valve.

continuous with a fleshy ridge which unites it to the septum and to the valve.

Septum ventriculi regular and well-formed in all parts except at a spot lying immediately below the pulmonary artery, where a large aperture exists.

This defect or foramen lies 1·2 cm. distant from the anterior surface of the heart, and 1·5 cm. from the posterior. It further lies immediately below the plane of the auriculo-ventricular septum. The mitral and tricuspid orifices lie on each side, but somewhat posterior; the aortic quite anteriorly and on the right; while the pulmonary is directly above, to the left.

The foramen is quadrilateral in shape; the opposite margins are parallel, the upper being parallel to the plane of the auriculo-ventricular septum.

The anterior, posterior, and inferior margius are thick and muscular; the superior is formed of a thin membrane 3 mm. in depth which projects downwards from the auriculo-ventricular septum.

On the left aspect of this membrane are situate three rounded or oval bodies,[1] about the size of hempseeds or larger, sessile, firm, and covered by same membrane as that on which they are situated. A similar but smaller nodule lay on the anterior aspect of the anterior cusp of the mitral valve, below the anomalous chordæ (i.) (ii.) (iii.) above referred to. Behind this nodule lay a small canal, which passed to the left auricle to a spot above and to the right of the anterior cusp of the mitral valve.

The pulmonary artery exhibited only two valves of equal and normal size. Tested carefully by water, seemed quite competent. The valves lay almost right and left; they were of normal size, and at the left extremity were attached in the usual manner. At the right, however, they were separated slightly, about 1–1·5 mm. Across this gap stretched a thin membrane, continuous with the tissue of the cusps, which was somewhat thickened and reddened at that part, especially at their free margins. Within this space a deep depression existed, which led downwards and forwards towards the right ventricle, but whose exit was blocked. The right wall of the artery, to which these cusps were united, passed directly down-

[1] On microscopic examination, the structure of these bodies was composed of fibrous tissue, with numerous nuclei.

wards into the membrane referred to. But the nodules above described had no apparent connection with the thickening of the pulmonary valves.

The diameters of the orifices were—aorta, ·35 in.; tricuspid, ·45 in.; foramen, ·4 in.; pulmonary, ·22 in.; mitral, ·35 in. All the valves were competent.

REMARKS.—Congenital defects of the heart may be roughly divided into two groups—those which are due to an arrest of development at some particular stage of embryonic life, and those which are caused by a radical perversion of the normal relations of parts.

For example, patency of the ductus arteriosus is a normal condition up to the time of birth: its persistence afterwards is thus merely a normal event, becoming a permanent condition. On the other hand, a transposition of the vessels, *e.g.*, the aorta arising from the right ventricle, is at no time an event of normal intra-uterine life. Hence such a condition must be placed in quite a separate category.

But obviously the two classes are not mutually exclusive; since the presence of one of the latter conditions may cause the appearance of one of the former. And we may therefore add a third class, in which part of the condition is normal and part abnormal in origin.

With regard to the case here described, we have, to sum up shortly, to explain the following:—

(*a*) Transposition of the vessels.

(*b*) Stenosis and malformation of the pulmonary artery.

(*c*) Patency of ventricular septum.

(*d*) Patency of ductus arteriosus.

(*e*) Hypertrophy of right heart.

It is at once obvious that the presence of patency of the ductus arteriosus and of the septum ventriculi bring the condition under the first group of defects; while the stenosis of the pulmonary artery and the transposition of the vessels would include it in the second. The co-existence of these abnormalities entitles us to place it under the third or mixed group.

In order to explain the origin of these conditions, brief reference must be made to the leading facts of development. The heart of the embryo is at a very early stage a tube bent upon

itself like a horseshoe, and is divided into three chambers—atrium, ventricle, and bulb, by transverse constrictions. The further development of the atrium need not be referred to here; but that of the ventricle and bulb is of extreme importance.

The bulb becomes bent upwards, and applied to the anterior aspect of the ventricles. At its upper end the bulb becomes continuous with the branchial arches.

Within the ventricles a muscular septum grows from its lower aspect and from the anterior and posterior walls, and advances upwards towards the point at which the cavity of the ventricles becomes continued into that of the bulb. This septum is not at once complete, but permits of the passage of blood from one ventricle to another for some time.

The bulb now divides: the septum bulbi starts, according to some authors (His and Born), from two opposite points, on the left or posterior, and right or anterior walls, which advance to meet each other, or, according to Rokitansky, from a single point on the left or posterior wall alone.

The septum bulbi starts above from the point of origin of the 5th branchial arch, and stretches downwards till it meets the septum ventriculi.

But, owing to the continuation of the slow twisting movement of the original vascular tube, which primarily threw the heart-proper into a horseshoe shape, the bulb becomes spirally twisted upon itself. So that, while the septum divides the bulb above into anterior and posterior vessels, below the relation of the resulting vessels is right and left.

The anterior and right of these vessels is the pulmonary artery, the posterior and left is the aorta.

The septum bulbi joining the ventricles comes to coincide with the septum of the ventricles; and the previous deficiency in the septum ventriculi then becomes closed in a twofold manner, by prolongations from (1) the septum bulbi, and (2) the endocardial cushions, forming the auriculo-ventricular septa. Subsequently, thickenings occurring in the base of the vessels so divided, give rise to the valves of the aorta and pulmonary artery.

Applying these facts—which have been gathered from the researches of His, Born, Lindes, and von Rokitansky—to the

particular case, it is easy to understand how part at any rate of the defects may have arisen. If there occur any obstruction at the pulmonary orifice after that vessel is formed, but before the septum ventriculi has closed, we can easily comprehend the sequence of events. The narrowing of the pulmonary orifice obstructs the current of blood passing from the related ventricle. The stream will, therefore, tend to pass through the aperture of the septum ventriculi, and flow through the aorta. Hence occurs the persistence of the patency in that septum, and hence results the hypertrophy of the ventricle related to the aorta.

Again, the patency of the ductus arteriosus is explained also. The same obstruction to the outflow of blood by the pulmonary artery to the lungs will after birth render the flow of blood from the aorta by the ductus still possible, and indeed imperative.

But when we come to explain the origin of the transposition of the vessels, and the stenosis of the pulmonary artery, we are in much greater difficulty.

The evident theory that an intra-uterine inflammation occurred in the pulmonary orifice, accounts indeed for the narrowing of the vessel and the obliteration of one of the cusps; but it does not account for the transposition. All authors admit the difficulty, but most suggest it is due to original mal-position of the septum bulbi, which arising too anteriorly, brings the vessels into union with the opposite ventricles. They suppose the inflammation to be the result, and not the cause, of the mal-position.

But there are obvious difficulties in the way of accepting such a view, and to fix the cause as mal-position is merely putting the question a step further back. Organisms, like crystals, apparently tend to develop according to an undeviating pattern, unless some extrinsic force disturbs their evolution. Moreover, in conditions such as the one described, the absence of the normal twist of the aorta and pulmonary arteries at the base of the heart, often so marked a feature in young children, was very evident.

Other questions of equal difficulty and importance arise in this connection. For instance, as regards the patency in the septum. Most English authors assume that it is the undefended space—or pars membranacea septi—that is deficient. Space forbids a full examination of this point, but one authority at least, Rokitansky, has very definite views against this. He asserts

that in most cases it is the part of the septum anterior to the pars membranacea which is deficient. And in those cases where the pars membranacea is pervious, the condition is due to a real perforation by aneurism, or otherwise, of a membrane previously formed, not a defective formation.

Again, the origin of this pars membranacea is interesting, and also the subject of controversy. Its consideration, however, would lead too far in the direction of embryology for the object of this paper.

The literature on the subject is extensive both in English and German, though, curiously, little space is afforded to it in most text-books of medicine.

Peacock's well-known work gives excellent information, both clinical and pathological, with a full account of the earlier literature of the subject. But writing at a time when embryology was still in its infancy, his remarks on etiology have somewhat lost their value.

The recent work of Rokitansky is of extreme importance; but his views seem hardly to have received the recognition they deserve in this country. Many of the points raised in his monograph have been discussed in short papers by Preisz and others.

The following are among the more important references to recent works on the subject:—

LIST OF REFERENCES.

1. PEACOCK, "Malformations of Human Heart," London.
2. ROKITANSKY, "Die Defecte des Scheidewände des Herzens," Wien, 1875.
3. RAUCHFUSS, "Gerhardt's Handbuch f. Kinderkrank," vol. iv.
4. HIS, "Anat. menschlicher Embryonen," 1885.
5. LINDES, "Beitrag zur Entwickelungsgeschicte des Herzens," 1865.
6. BORN, "Entwickelung des Saügerthier-herzens," *Archiv. f. mikros. Anat.*, Bd. 33, 1889.
7. GREENFIELD, *Journ. Anat. and Phys.*, 1890.
8. KRZYWICKI, "Das septum membran. ventric. cordis," *Ziegler's Beiträge*, vol. vi. p. 463.
9. MAX MANN, *ibid.*, p. 485.
10. HUGO PREISZ, *Ziegler's Beiträge*, vol. vii.

THE STRUCTURAL CHANGES OBSERVED IN THE TESTICLES OF AGED PERSONS.

By JOSEPH GRIFFITHS, M.A., M.D., F.R.C.S., *Assistant to the Professor of Surgery in the University of Cambridge.* (PLATE XXIII.)

DURING the last two years I have collected and examined microscopically numerous testicles removed from persons of different ages between fifty and eighty years.

This was done with the object of determining, if possible, what, if any, are the changes that this organ undergoes in the aged, and whether it is naturally subject to a regular process of decay similar to that affecting the mammary gland after the cessation of the menstrual function.

Such structural changes as would indicate a natural process of decay arise in the testicles; but the time at which such changes begin to manifest themselves varies within wide limits. For in some men the testicles show the initial changes of this decay and loss of secreting function soon after the age of fifty years, while in others, at the age of seventy or more, the testicles are in full vigour and actively producing and reproducing spermatozoa. Therefore, there is no such fixed date beyond which the testicle may be said to be in its natural process of decay, as can be said of the mammary gland in the female. Hitherto but little attention has been paid to this subject, although anatomists have, from time to time, established by measurement and weights the fact that the organ tends to diminish in old age; and, besides the researches of Arthaud,[1] there is no account of the histological changes that arise in the testicle and epididymis in old age.

Curling[2] seems to have been the first to give a definite description of the changes that occur in the testicle during and as a consequence of old age. These are his words:—

"And that as old age advances and the generative functions

[1] *Étude sur le testicle senile*, Paris, 1885.

[2] *Diseases of the Testis*, 4th ed.

cease to be called into action, they [testicles] undergo a diminution in size, their vessels grow less, and the seminiferous tubules become small, contracted, and partially obliterated, their place being supplied by fatty matter." In a foot-note he makes the following additional remark:—"In the testicles of old men the tubules are commonly found loaded with a dark granular substance, the result of fatty degeneration."

No other person seems to have paid much attention to this subject until Arthaud, who, in 1886, published a thesis on the senile changes in the testicle. After describing briefly the changes that arise in the testicle during old age, he devotes his attention chiefly to the cystic formations that are found in many old persons in the globus major, or head of the epididymis. I may return to these and the like cysts in this neighbourhood in a subsequent paper.

The changes that I have found in the testicles are the following:—The bulk of the organ is in most cases not much altered, though in some it is so considerably, and I have now under my care a man above ninety whose testicles are of quite the usual size. They usually become softer and more flaccid, and their tunics tend to become wrinkled as if too large for their contents. The internal structure, in those instances that are not much reduced in size, is either soft and yellowish, or granular and somewhat more firm than natural, the seminal tubules being less easily disentangled;—those instances in which the body of the testicle is much reduced in size there are large irregular-shaped fibrous patches here and there, apparently containing no seminal tubules. The epididymis retains its normal size to the testicle; but commonly, in small well-defined areas, its tubules (coni vasculosi) are of a yellowish colour, like those of the seminal tubules; and occasionally in these altered patches, and also in other tubules of the head of the epididymis, are minute, translucent cysts, holding clear fluid devoid of spermatozoa. This yellowish appearance in the tubules of both testicle and epididymis is due to fatty degeneration of the epithelial contents of the tubules; and when the fatty change is observed in the one part it is usually present in the other. Thus the chief and commonest change met with in the testicles of the aged, so far as can be determined by the naked eye, is fatty transforma-

tion of the epithelial contents of the seminal tubules, and this applies equally to the epididymis; but occasionally testicles are found that show transformation of their internal structure into patches of fibrous connective tissue, which are of irregular shape and size, and sometimes these replace the greater part of the tubular structure.

Before describing the microscopic changes in the testicle of the aged, it may be well to give an account of the minute structure of the tubules as they may be usually found in the normal human adult testicles; for purposes of comparison with the other figures a section has been drawn to illustrate this (see fig. 1).

The normal seminal tubules are surrounded by a thin layer or tissue, "tunica propria," which is composed of two or more layers of flattened connective-tissue cells with rod-like nuclei, or in some instances, of several layers of such cells with a small amount of intervening fibrous connective tissue. The epithelium within this tunica propria is arranged thus:—

Lining the "tunica" is a continuous layer of small cubical cells with round nuclei, and not much protoplasm; several of these nuclei may be seen in the process of division, or of having divided into two nuclei which still remain side by side; within this outer layer there are at least two strata of much larger cells that have large nuclei which are occupied with a network of thread-like filaments; the protoplasm is large in amount, and often finely granular. In many of the nuclei of the innermost stratum of these cells the heads of the spermatozoa are clearly visible, and these are arranged with their long axes towards the lumen. Occupying the lumen of the tubule are numerous spermatozoa scattered irregularly, and between them granular débris and a few partially degenerated free cells.

Connecting these tubules together is a small amount of delicate, loose, fibrous connective tissue, in which there are a few interstitial cells, and in which the vessels and nerves lie. The connection of this tissue with the tunica albuginea on the one hand, and with the tissue of the rête testis on the other, is quite familiar, and therefore needs no comment.

A microscopic examination of that variety of the testicles of the aged which is the commonest, and in which the organs are

not much reduced in bulk, indicates two distinct stages in the retrogressive or involution changes in this organ. The accompanying drawings (figs. 2–5) have been selected with a view to illustrating these stages.

In the earlier of these two stages the changes in the tubules, both of the testicle and of the epididymis, are but slight, except that fatty degeneration of the epithelial cells filling the seminal tubules, or as in the epididymis lining them, is more or less pronounced. In fig. 2, transverse sections of a seminal tubule and a part of another are shown, in which there is entire absence of the formation of spermatozoa in the cells and of spermatozoa in the interior; and there is a diminution in the number of the layers of cells lying within the continuous peripheral one. The most central cells are large and irregular in shape; in some of these there is a large, clear, ring-like space around the nucleus, which is large and highly granular, but not showing the threads of division. The protoplasm of the cells is ill-defined and slightly granular, the granules being composed of fat. The degree of this fatty degeneration is most pronounced in the cells lying just within the outer peripheral layer, in which latter degenerative changes are very slight (see fig. 2). In the more central cells the degeneration is also not so marked, but this may be due to the fact that more complete disintegration of the protoplasm of the cells has taken place, and that the granules of fat have either escaped into the lumen, from where they would have fallen out in the preparation of the section, or have been absorbed. In addition to this change, which is universal throughout the gland, there is another which accompanies it. It is the thickened and convoluted state of the tunica propria. In the normal testicle the tunica propria is a very thin membrane, composed as a rule of a single, or at most two, layer of cells, with a slight amount of intervening fibrous connective tissue; whereas, in the testicles of old men, this membrane becomes several times thicker than its original, and also becomes more fibrous in character. The convoluted disposition of this membrane corresponds with the diminution in the epithelial contents of the seminal tubules. There seems to be no increase in the intertubular connective tissue, but there is fatty degeneration of a few of the connective-tissue cells, and of those cells that

may be regarded as the remains of the peculiar *interstitial* cells of this organ.

In the epididymis the tubules are smaller than natural, and are bound together by intertubular connective tissue, which is here denser and more fibrous than natural. Most of the tubules are empty, a few containing a mass or plug of granular and fatty débris, in which there may be seen a few heads of persistent spermatozoa. The columnar epithelium, naturally lining the tubules at this part, has lost its regularity of form and arrangement, as well as its cilia; and the cells are reduced in size, and partially filled with fat granules which are mainly disposed towards the attached or basal part of the cells, and which, in consequence, obscure the nucleus (see fig. 3). The walls of the tubules, which, unlike those of the seminal tubules, are in the normal state mainly composed of layers of non-striped muscular fibres, are transformed in part, if not wholly, into fibrous connective tissue—the muscle cells having disappeared, while the connective tissue increased and replaced them. This altered wall of the tubule merges without any line of distinction into the intertubular connective tissue, which is in all these cases dense and fibrous, and very unlike the loose connective tissue found in this situation earlier in life.

The next, or second, stage of degeneration is well illustrated in figs. 4 and 5. The changes are mainly confined to the testicle, the structural alterations of this stage in the epididymis being but an exaggeration of those described in the first stage. In the testicle the seminal tubules are much reduced in size, the epithelium having in great part disappeared, while the tunica propria has acquired considerable thickness; the intertubular connective tissue is relatively increased, and it often presents numerous cells, and is loose in texture. In fig. 4 the changes that the tubules have undergone may be studied. There is only a single layer of cells which appear to be long columnar cells, arranged in a somewhat radial fashion, converging towards the centre of the tubule. These cells, which evidently represent the single layer of cubical cells lying on the inner surface of the tunica propria of a normal tubule, have large roundish nuclei, which are, almost without exception, surrounded by a clear ring-like space, and are placed near the

attached end of the cells. The protoplasm is delicately fibrillated, the fibrils corresponding with the long axis of the cell, *i.e.*, running from the periphery towards the centre of the tubule. Among these cells the remains of a few further degenerated cells, of which the nuclei still remain the protoplasm having disappeared, may be seen. The tunica propria is much thickened, but not much convoluted. It is several layers in thickness, and is composed of dense fibrous connective tissue, arranged in concentric lamellæ.

The fibrillated protoplasm of the epithelial cells in the interior of the tubule often appears at first sight, as if it were a continuation, or rather a prolongation, inwards of the fibrillated matrix of the tunica propria; but a careful examination will not fail to detect a sharply-defined line between the bases of the epithelial cells and the inner layer of that tissue.

The intervening intertubular connective tissue is, as has been said above, relatively increased, is cellular and loose. The cells it contains are large connective-tissue cells, with highly granular protoplasm which is in large measure transformed into fat granules. These cells are often grouped together in clusters in the angles left between the tubules.

Between these two stages there is every gradation, as may be expected.

The external appearance of the testicles is no sure guide to the state of the seminal tubules; and even when the organs are not much reduced in size, the structural changes in their essential constituents may be profound.

The changes that arise in the testicle of old men are chiefly, as one would expect, confined to the epithelium of the seminal tubules. It diminishes in amount from fatty and other disintegrative degenerations of the cells which in great part disappear, leaving only a single layer of columnar cells occupying the lumen. This layer of cells, there can hardly be any doubt, represents the outer cubical layer seen in the normal tubule; but why the cells should assume columnar shape, and their protoplasm show such distinct fibrillation, is more than I can even attempt to explain. Similar structural alterations occur in the testicle in other atrophic conditions, which I hope shortly to describe, and which may be found in the undescended organ.

Besides the above, I have found among the testicles of the aged, one in which the testicles are much reduced in size and their tunics much wrinkled. Both organs are usually affected, though not to an equal degree. If these be first hardened in alcohol and then sliced, it will be observed that the internal structure of the organ is replaced, in patches of irregular size and shape, by fibrous connective tissue which appears to contain no seminal tubules. These patches are not, so far as I have noted, confined to any particular area, but are scattered throughout the substance of the gland. Rarely is the greater part of the gland thus altered. The minute structure of these patches of fibrous connective tissue is well depicted in figs. 6, 7. The seminal tubules contained in them are reduced to their minimum size, and the intertubular connective tissue is increased, dense and fibrous. In each tubule the lumen is narrow and fissure-like, with many radiating branches; in some of these fissures remains of the epithelial cells still persist, as seen in fig. 7. The tunica propria of the tubules is thickened, fibrous, and wavy. Between this and the fissure-like lumen is a thick layer of almost transparent, delicately fibrillated matrix of fibrous connective tissue, in which there are interposed, here and there, a few flattened connective-tissue cells. It is the manner in which this latter has formed that gives the peculiar branched, fissure-like lumen to the tubule.

The parts of the gland that are not thus transformed into patches of fibrous-looking tissue, contain seminal tubules that present the characters of the tubules found in either the first or second stage in the commoner variety of testicle met with in the aged.

Such is the change observed in the small and atrophied testicles of old men. They so much resemble the changes met with as the result of chronic inflammation, that I have sometimes felt disposed to attribute them to that cause.

Further, the vessels in the stroma of the testicles of the aged have been carefully examined, but they show no other than the sclerotic changes so commonly found in the vessels of other organs and tissues in elderly persons.

Conclusions.

In the testicles of the aged, two distinct stages may be recognised in the process of involution or decay to which they are liable.

In the *one*, the epithelium of the seminal tubules, and also that of the tubules of the globus major of the epididymis, undergoes, more or less, complete fatty degeneration and partly disappears, the tunica propria of the tubules of the testicle becomes somewhat thickened, but the intervening intertubular connective tissue remains practically unaltered. In the epididymis the muscular wall of the tubule is replaced by fibrous connective tissue, and the intertubular connective tissue is increased, dense, and fibrous. In the *other*, or *second* stage, the seminal tubules are much reduced in size, the epithelium having in great part disappeared, leaving only, in many instances, a single layer of long, tapering, columnar cells, lining and filling the tubule, the central spermatozoa-producing cells having completely disappeared, while the tunica propria is greatly thickened from proliferation of its own connective-tissue cells and the formation of a fibrous matrix. The intertubular connective tissue is in this *second* stage relatively increased, owing perhaps to the diminution in the size of the seminal tubules, but it still remains of loose texture, and contains, as in the normal, many connective-tissue cells. The epididymis shows no other changes than those incident to the *first* stage.

Besides the above, there is a *third* change, which is more partial, and much resembles the result of the inflammatory process. It is usually observed in the small or shrunken testicles of old men, and affects both organs. In the altered patches, the seminal tubules, in the majority of instances, are completely transformed into fibrous rods or cords; but in some there still remain in the central fissure that represents the original lumen, traces of epithelial cells derived from the degenerated cells of the seminal tubes. The intertubular connective tissue is increased in amount, and converted into a dense fibrous variety.

EXPLANATION OF PLATE XXIII.

Fig. 1. Section of a portion of a natural seminal tubule from the testicle of a middle-aged man. Outside is the tunica propria, composed of fibrous tissue, in which there are a few flattened connective-tissue cells; within this a continuous layer of more or less cubical cells, with large, highly granular nuclei and clear protoplasm; within this layer two or more layers of large irregular-shaped cells, the nuclei of which are in the process of division, preparatory to the formation of spermatozoa; and still within these, groups of developing spermatozoa between cells which are evidently breaking down and passing into the lumen with the spermatozoa. × 450.

Fig. 2. Section of one seminal tubule and part of another taken from an aged person, and stained with osmic acid. It shows the first stage of the changes characteristic of the degeneration accompanying old age, namely, disappearance of most of the spermatozoa-producing cells and fatty degeneration of the remaining cells, especially those lying within the outer peripheral layer of cells, which show as yet but little change. The tunica propria is slightly thickened. × 120.

Fig. 3. A section of the tubules of the epididymis from the same person. The epithelium lining the tubules has lost its regular columnar appearance as well as its cilia, the cells having become small, less distinct, and in many instances filled with fat granules, which are so numerous as to obscure the nucleus.

Fig. 4. A section of testis showing the *second* stage in the changes that occur in old age. The seminal tubules are much reduced, the epithelium being only represented by a few cells, the tunica propria much thickened, and an increase of the intertubular connective tissue which is in the main cellular. × 100.

Fig. 5. One of the above tubules highly magnified. It shows the thickened tunica propria, the complete disappearance of the central or spermatozoa-producing cells of the tubule and the formation of columnar fibrillated cells from the continuous peripheral layer lining the tunica propria, the lumen being occupied by the prolongations of these cells. × 400.

Fig. 6. Section of a fibrous patch in the testicle of an aged person. The tubules are greatly reduced; their lumen reduced to a chink, and the tunica propria much thickened. The intertubular connective tissue somewhat increased and fibrous. × 40.

Fig. 7. One of the tubules seen in fig. 6 more magnified. The tunica propria is composed of an outer dense thin layer and of an inner transparent layer of wavy fibrous tissue, in which there are no connective-tissue cells: the lumen which radiates, contains a single atrophied epithelial cell.

THE STRUCTURAL CHANGES IN THE TESTICLE OF THE DOG WHEN IT IS REPLACED WITHIN THE ABDOMINAL CAVITY.

By JOSEPH GRIFFITHS, M.A. Cantab., M.D. Edin., F.R.C.S. Eng., *Assistant to the Professor of Surgery in the University of Cambridge.* (PLATES XXIV. and XXV.)

SINCE the publication of John Hunter's[1] observations upon the state of the testicle when retained within the abdomen, many investigations of a similar nature have been conducted in Man and in some of the domesticated animals, both in this country and in France; but so far as I am aware, no attempt has ever been made to determine, by means of experiments, (1) whether, when the testicle is replaced within the abdomen in young animals, it is capable of attaining its full size and mature structure and of producing spermatozoa; and (2) whether, when replaced within the abdomen in a full-grown animal, a dog for instance, in which the testicles have reached their full and mature size, it is capable of maintaining that full size and its powers of producing spermatozoa.[2]

It was with the object of determining these two points that the following experiments were conducted. Dogs were chosen, being easily procurable.

Before a detailed account of each experiment is given, it would be well to review briefly the opinions and observations of the more important writers on this subject.

Hunter, in the monograph to which reference has already been made, states as his opinion, that "when the testicle fails to descend from the abdomen, the organ is imperfectly formed, and that, in consequence of this imperfection in development, it is incapable of giving the necessary stimulus to the mechanism by means of which it descends." Accordingly, Hunter regards the undescended testicle as imperfectly formed, even during early embryonic life. He also considers, as may be gathered from another part of the same monograph, such a testicle incapable of producing spermatozoa, and a man

[1] Hunter, *Obs. on certain parts of the Animal Œconomy.*

[2] I find Curling suggests this method as one likely to lead to good results, in his 4th edition of the *Diseases of the Testis.*

whose testicles remain undescended as sterile. Hunter, it will be remembered, was the first to describe the mechanism of the descent of this organ, and to point out that when the mechanism failed in its appointed duty, the testicle was at fault, as shown by the smallness in its size, and the absence of spermatozoa in it, and in the corresponding *vesicula seminalis*.

Sir Astley Cooper [1] agrees with Hunter, and found nothing in his extensive experience to throw any doubt upon the accuracy of these observations. But not many years after the publication of Cooper's *Diseases of the Testis*, Curling [2] took up this subject, and after much labour came to a totally different conclusion, namely, that when the testicle is undescended and remains in the abdomen, it is not *ab initio* imperfectly formed or developed, but simply fails to reach beyond a certain stage in its development, and that its structure is perfect for that stage which is obtained prior to puberty; further, he attributes failure in descent to some defect in the mechanism itself, and not to any want of stimulus from an imperfectly formed testicle. As it is not my intention to enter into a discussion upon the prime mover in the mechanism of descent, nor upon the various causes of partial or complete failure in its action, I shall make no further references to that subject here.

Curling, however, agrees with Hunter and Cooper, inasmuch as he considers the testicle incapable under these conditions of producing its special secretion.

He, however, mentions an instance in which he understood that spermatozoa were found by a colleague in a testicle which had been retained in the inguinal canal.

Soon afterwards Godard,[3] in France, published a communication in which he showed that the testicle, when retained within the abdomen in Man, is capable of producing spermatozoa; and he cited instances which he had met with, and in which, after careful examination with the microscope, he found spermatozoa.

Just at the same time Follin and Goubaux [4] made extensive investigations both in Man and in horses; and they collected between them numerous instances of retained testicles, in none of which could they find any trace of the formation of spermatozoa, spermatogenesis, or of spermatozoa themselves. In spite of the observations of Godard, it has been generally accepted for many years that when the testicle fails to reach the scrotum and is detained in or near its original position below the kidney, in the iliac fossa, or in the inguinal canal, it is not fully developed; that is, it is smaller and softer than natural, and its internal structure differs from that of a natural organ in so far that the seminal tubules cannot be easily distinguished; that they are atrophied, and that they show no trace of

[1] Cooper, *On the Structure and Dis. of the Testis.*

[2] Curling, *Diseases of the Testis*, 4th ed.

[3] Godard, *Recherches sur la Monorchidie et la Cryptor. chez l'Homme.*

[4] Goubaux et Follin, "De la Cryptorch. chez l'Homme, et les principaux animaux domestiques," *Mem. d. la Soc. de Biol.*, 1855.

the formation of spermatozoa, these being also absent from the tubules of the epididymis, and the corresponding *vesicula seminalis.*

Although the above view of the state of the testicle when retained within the abdomen is the one most generally accepted, yet the observations of Godard have recently received considerable support from the researches of Monod and Arthaud,[1] who in 1887 published a conjoint paper. They maintain that the detained testicle does acquire its full and mature spermatozoa-producing structure; and that, owing to its abnormal position which in some obscure manner prevents it carrying out its function, the testicle soon shows signs of atrophy of the seminal tubules. This atrophy is progressive, and ultimately leads to a more or less complete transformation of the tubules into fibrous cords, and the intertubular connective tissue into a fibrous stroma.

There are therefore three views held regarding the state of the testicle when detained within the abdomen, namely, (1) that the testicle is imperfectly formed from the beginning (Hunter); (2) that the testicle is natural, but that at puberty it fails to reach its full size and mature structure (Curling), and thus remains in the pre-puberty stage; and (3) (Monod and Arthaud) that the testicle does acquire its full size and spermatozoa-producing powers at the time of puberty, but that, owing to its abnormal position, it soon undergoes retrogressive changes, which sooner or later end in complete atrophy of the seminal tubules.

In the following experiments the testicle in all instances, whether in young puppies or in full-grown dogs, was of natural size (natural to the age of the animal), shape, and consistency; and the greatest care was exercised in the handling requisite for its replacement within the abdomen, for anything like an attack of inflammation of the body of the testicle from rough handling at the operation, or from any other damage, would render the results of the experiment valueless. In no instance have I had any trouble either from inflammation or other cause, and the dogs have usually been running about in a pretty lively manner on the third or fourth day after the operation. In all the experiments morphia and chloroform were used, and anæsthesia throughout maintained; and all antiseptic precautions were adopted in order to ensure an aseptic state of the peri-

[1] Monod et Arthaud, "Contrib. a l'étude des alterations du testicule ectopique, etc.," *Arch. Gen. de Med.*, 1887.

toneal cavity into which the testicles were replaced. In the greater number of the dogs the testicle acquired new adhesions, and this, at its lower end, in the iliac fossa. The vas deferens was found coiled, but the spermatic vessels did not seem to be in any way interfered with. In one or two the testicle could be freely moved, and must have changed its position with the movements of the neighbouring bowel.

The experiments naturally divide themselves into *two* groups, namely, (1) those conducted on young animals, in which the testicles were immature and undeveloped; and (2) those conducted on full-grown animals, in which the testicles were of their full size and mature structure.

Accordingly, the following experiments are collected together under these two groups:—

I. Experiments on Young Animals (Dogs).

Experiment I.—A black-and-tan terrier, about nine to ten months old. The testicles were still of small size, and not fully developed. On December 3, 1891, the *right* testicle, which measured 15 mm. in length by 12 mm. in breadth (from the dorsum, exclusive of the epididymis, to the ventral border), was replaced in the abdominal cavity. The dog did well, and was soon running about.

On December 10, seven days after replacement of the organ, the animal was killed. The *right* testicle was somewhat smaller in size than the left, and it appeared as if its vessels were more turgid and congested, though the average size of the spermatic veins was decidedly smaller than normal. The *left* testicle measured 17 mm. in length by 12 mm. in breadth, and was of natural appearance.

Under the microscope the seminal tubules of this, the *left*, testicle were seen to be in an early stage of transition between the state of the organ before the onset of puberty, and that when it has reached maturity and is capable of producing spermatozoa. The tubules, that is to say, were somewhat larger than they are in the quite immature state, and they contained more small round cells; besides, in the majority of them, a central lumen had already made its appearance, but as yet there were no evidences of the formation of spermatozoa.

In the *right* testicle, that which was replaced in the abdominal cavity, the seminal tubules were solid rods of small polygonal cells, just as they are in the testicle before the occurrence of growth at puberty. In this organ no trace of the further development which the tubules undergo at puberty could be detected.

In this instance, therefore, the testicle which had been replaced in the abdomen remained in the state in which it probably was before

being replaced, while the one left undisturbed in the scrotum began to grow, and show distinct signs of active cell proliferation. I would here remark that I have found it not unfrequently happens that the testicles attain their full size during a short period of three to four weeks from the time at which the impulse to growth originates.

Experiment II.—A fox-terrier, three months old. On May 22, 1891, the *left* testicle, which measured 15 mm. in length by 12 mm. in breadth, was replaced in the abdominal cavity by the same method as in the former experiment. At the beginning of October in the same year the *right* testicle, which had not been interfered with, began to show signs of growth, and by the beginning of March it had reached its full size. The dog was killed on March 9, 1892, when the *right* testicle measured 30 mm. in length by 20 mm. in breadth, this being the usual size for a grown-up dog of this breed. The *left* testicle was found attached to the peritoneum at the brim of the pelvis, and hanging down into that cavity; the vas deferens was coiled, but the spermatic vessels, though somewhat smaller than those of the opposite side, were normal, and not in any way interfered with in their course. The body of the testicle measured 17 mm. in length and 13 mm. in breadth, was small and roundish, but of natural appearance, though softer than its fellow (see fig. 1, Plate XXIV.). The epididymis was small, though relatively larger than the testis, as is usually the case in young animals.

The *left* testicle showed under the microscope that the seminiferous tubules were only about one-half of the size natural in a full-grown organ. The tunica propria of each tubule was somewhat thickened, and the tubules were widely separated from one another (fig. 1, Plate XXV.).

The epithelium lining these tubules was composed of a single layer of columnar cells resting upon the inner surface of the tunica propria. These cells contained large, round, clear nuclei, which were found near the basal or attached ends of the cells; their protoplasm was delicately fibrillated in the long axis of the cells, and was comparatively free from granules (fig. 2, Plate XXV.).

The cells themselves were prolonged to the centre of the tubule in fine radiating processes composed of the delicately fibrillated protoplasm of the cells. There were no spermatozoa, nor any trace of their formation, in any of the tubules. The tunica albuginea of the testicle, together with the septa and the intertubular connective tissue, were not changed beyond a relative increase from diminution in the size of the seminal tubules. In the epididymis the tubules were small and contracted, but they were all lined by the usual single layer of columnar epithelial cells bearing fine long cilia.

In the central lumen which was correspondingly small, there were no spermatozoa, but in their place a few coarse clear granules.

The *right* testicle and epididymis were normal. In the seminal tubules of this testicle there was abundant evidence of the formation of spermatozoa, the tunica propria being lined by cubical cells, and

the cells nearer the lumen, which were altogether absent in the left testicle, showed the division of their nuclei preparatory to the formation of spermatozoa; and in the tubules of the globus major of the epididymis there were numerous spermatozoa.

It may be here noted that in this experiment the testicle that was replaced in the abdomen increased somewhat in size while in the abdominal cavity.

It will be further observed that the testicle that was left undisturbed in the scrotum had just attained its full size and functional powers when the animal was killed, whereas the replaced testicle had not undergone this change, but was found small and ill-developed, with altered seminal tubules which showed no indication whatever of the formation and production of spermatozoa. This is contrary to the opinion expressed by Godard, Monod, and Arthaud, that the detained testicle does continue to undergo the changes incidental to on-coming puberty.

Experiment III.—A fox-terrier, about four months old. On June 21, 1891, the *left* testicle, which measured 15 mm. in length by 12 mm. in breadth, was replaced in the abdominal cavity. The wound healed quickly, and the dog was soon about and well. On Nov. 8, 1891,—before, therefore, the period at which the testicle would have acquired its full size,—the animal was killed, when the *left* testicle, which measured 18 mm. in length by 12 mm. in breadth, was found lying in the iliac fossa, and adherent by its lower end to the peritoneum of that part. Its body was somewhat flaccid and soft. The epididymis was also small, but relatively large to the body of the testicle.

The vas deferens was coiled, but the spermatic vessels, although small, were otherwise natural. The structure of this testicle, as well as that of the epididymis, was precisely the same as is described in Experiment II., of which a description immediately precedes. The *left* testicle of this animal was of the same size as that of the dog in Experiment II., both dogs being of the same litter.

The right (opposite) testicle could not be used for comparison, forasmuch as I had, on July 21, 1891, ligatured the spermatic vessels on that side.

In this experiment the replaced testicle grew while in the abdominal cavity; and although it had not undergone much change, yet the seminal tubules were altered in their structure.

Experiment IV.—A well-grown fox-terrier of about 9–10 months old, the testicles not being fully developed. On Sept. 24, 1891, the *right* testicle was replaced in the abdominal cavity, and it then measured 15 mm. in length by 12 mm. in breadth. The wound healed quickly, and the dog was soon well and about.

During October and November the left testicle acquired its natural size (30 mm. in length by 20 mm. in breadth) and the normal histological structure of the functional testis. On Nov. 30, 1891, the animal was killed. The *right* testicle, which now measured 17

mm. in length by 12 mm. in breadth, was found in the iliac fossa, attached as usual to the peritoneum by its lower end. Its body was small, almost globular, and soft. The epididymis was also small. The vas deferens was coiled and shortened, but the spermatic vessels appeared natural. The histological structure of this *right* testicle and epididymis was precisely the same as that fully described in Experiment II.

There was no evidence whatsoever of the formation or presence of spermatozoa in any of the seminal tubules.

In this instance also the replaced testicle increased to some extent in size during the two months it lay in the abdominal cavity; yet it failed to keep pace in growth with its fellow the *left* testicle, which was left undisturbed in the scrotum and had during that time acquired its full size and spermatozoa-producing powers. It is further highly improbable that the replaced testicle acquired its full size and mature structure earlier than that left in the scrotum, and that it quickly underwent the degenerative changes which the full-grown organ, as will be presently shown, is liable to when replaced within the abdomen.

Experiment V.—A young black terrier, about six months old. On Dec. 10, 1891, the *left* testicle, which measured 12 mm. in length by 10 mm. in breadth, was replaced in the abdominal cavity. The wound did well. During February 1892 the right testicle grew normally, and on March 8, 1892, the animal was killed. The right testicle was of natural size, and measured 25 mm. in length by 20 mm. in breadth; whereas the *left* testicle, which was found attached to the peritoneum, and lying in the iliac fossa, measured only 16 mm. in length and 12 mm. in breadth. The left epididymis was also small; the vas deferens was coiled, but the spermatic vessels apparently natural.

In structure the left testicle was like that of the replaced organ in Experiment II., but the right was fully developed and capable of producing spermatozoa, which could be found in the seminal tubules as well as in those of the epididymis.

Here again the replaced testicle grew while in the abdominal cavity; and as the testicle was very small when replaced, the amount of growth is more apparent in this instance than in any other of the experiments. But although the animal was killed as soon as the right and undisturbed testicle reached its full size, yet the organ in the abdomen was small, and showed no signs whatever of producing spermatozoa.

We see, therefore, that when the testicle of a puppy is replaced in the abdominal cavity it undergoes but little change, being a little less plump than its fellow. It continues to grow with the body until the onset of puberty, but its growth is not so great as that of the undisturbed organ in the scrotum. At

puberty it, unlike its fellow, does not pass through the structural changes preliminary to the formation of the mature spermatozoa-producing tubules; nor does it remain stationary, retaining its pre-puberty structure, but it undergoes a change that is peculiar to a retained or replaced testis, the seminal tubules becoming altered. They are of small size, and in most instances a small central lumen; all being lined by a single layer of delicate columnar cells, which are derived from a modification of the single layer of the peripheral cubical cells seen before and after puberty, the central cells having disappeared.

Thus the seminal tubules are incapable of producing spermatozoa. They undergo, indeed, a degenerate change, being no longer like the tubules which characterise the pre-puberty state of the testicle, inasmuch as they no longer remain solid, but the central cells disappear, while the peripheral ones are converted into a layer of columnar cells which taper towards the centre of the tubule instead.

II. Experiments on Full-Grown Animals (Dogs).

Experiment VI.—A small full-grown fox-terrier. On December 7, 1892, the right testicle, which measured 22 mm. in length by 16 mm. in breadth, was replaced in the abdominal cavity. On December 14, 1892, the animal was killed. The testicle remained quite free in the abdominal cavity, and was found in the pelvis. It was reduced to 17 mm. in length by 13 mm. in breadth, and it appeared congested on the surface; the spermatic veins being if anything diminished in size, but in consistency the organ remained natural or nearly so. In none of the tubules could any trace be seen of the formation of spermatozoa, nor could any spermatozoa be detected, although only a week had elapsed since the replacement.

In some of the tubules, which were, without exception, reduced in size, the central canal or lumen was occupied in part by detached granular epithelial cells with ill-defined nuclei, and also by larger granular masses composed of fused degenerated cells (see fig. 3, Plate XXV.). These cells are the products of the cells which naturally occupy the circumferential part of the tubule, and which are derived from the peripheral layer of cells lining the tunica propria (see fig. 4). In other tubules these degenerated products of cells had entirely disappeared, the lumen being contracted and occupied by a single layer of slender columnar epithelial cells which line a somewhat thickened tunica propria, and which are the representatives of the single layer of the peripheral cubical epithelial cells of the normal tubule. There was no increase nor any alteration in the nature of the intertubular

connective tissue, except that where the tubules were much diminished in size it appeared relatively increased.

Experiment VII.—A full-grown fox-terrier. On August 13, 1892, the *left* testicle, which measured 30 mm. in length and 20 mm. in breadth, was replaced in the abdominal cavity. The animal soon got well and was running about as usual. On September 13, thirty-one days after the replacement, the dog was killed. The *left* testicle was found attached by its lower end to the peritoneum in the left iliac fossa. It was much reduced in size, measuring only 20 mm. in length by 15 mm. in breadth, was soft and flaccid. The epididymis was also reduced, but not so much as the body of the organ. On microscopic examination the seminal tubules were much reduced in size, and in many of them the epithelium was represented by a single continuous layer of small cubical cells with large nuclei lying on the inner surface of the tunica propria; within this layer were other less defined cells with granular protoplasm. The latter occupied the greater part of the lumen. In other tubules there was only a single layer of cells which had become columnar in shape. These lined the tunica propria, and were prolonged by delicate processes into the central part of the lumen. In this testicle the degenerative changes consequent upon replacement had in great part disappeared, so that the stages in the process could not be observed as in Experiment VI., in which the testicle had only been replaced for seven days.

It showed, however, that the inner cells of the tubules undergo degenerative changes and disappear, while the peripheral cells gradually elongate and become changed from a cubical to a columnar variety, and project into and fill the lumen.

The right testicle remained of natural size and of normal structure, and continued producing spermatozoa, which were found in great numbers in the seminal tubules after death.

Experiment VIII.—A small full-grown terrier. On December 1, 1891, the *left* testicle, which was of full size, and which measured 30 mm. in length and 20 mm. in breadth, was replaced in the abdominal cavity, the inguinal canal being enlarged, as in all the other cases, and afterwards carefully closed by numerous sutures. The wound quickly healed, and the dog was soon about and well. On March 7, 1892, ninety days after the operation, the dog was killed.

The *left* testicle was small, having been reduced in its size to 18 mm. in length by 12 mm. in breadth, but it was otherwise healthy-looking (see fig. 3, Plate XXIV.); it had become attached by its lower end to the peritoneum covering the iliac fossa. The epididymis was diminished, though not in the same proportion as the testicle, and the vas deferens was coiled and short; but the spermatic vessels, though not so large as when the testicle was replaced in the abdomen, or as those of the opposite organ, were quite normal in their appearance; nor were they in any way interfered with in their course.

A section of the body of the testicle revealed to the naked eye

nothing abnormal beyond a certain degree of compactness in its structure. For a comparison between the two testicles see the drawing (fig. 3, Plate XXIV.) taken from the specimen, after being hardened in alchohol.

The seminal tubules of the *left* (replaced) testicle were reduced to one-half their natural size. The tunica propria of the tubules was somewhat thicker than natural; but the chief changes that could be seen were in the epithelium, which was much altered. It had in great part disappeared, leaving only a single layer of cells with large round nuclei placed near the attached ends of the cells; some of these nuclei (fig. 4, Plate XXV.) contained nucleoli, as if they were in process of division, whereas others had become vesicular or vacuolated.

The cells were of columnar shape, with tapering inner free ends, the delicate filamentous processes of which passed into and filled the lumen.

The protoplasm of each cell was delicately fibrillated in its long axis. There seemed to be no remains of other cells between the filamentous processes, nor could spermatozoa, or traces of their formation, be found anywhere.

In the epididymis of this testicle, which was somewhat diminished, though not in the same proportions as the body of the organ, the only change observable was that of contraction of the tubules at the upper end, or globus major, with a diminution of the lumen. No spermatozoa were to be found but only a few clear granules. The columnar epithelium lining these tubules appeared natural, and the cilia were normal.

Neither in this specimen nor in any of the preceding were there any signs, either in the intertubular connective tissue nor elsewhere, of the inflammatory process having accompanied or preceded this atrophic change in the seminal tubules; and the tunica albuginea, together with the supporting connective tissue of the organ, showed no further changes than would result from the general diminution of the size of the seminal tubules.

The *right* testicle, which had been left undisturbed in the scrotum, was quite normal in size and structure, and showed the usual presence of spermatozoa in its tubules.

From the last series of experiments it will be gathered that when a full-grown testicle is replaced within the abdominal cavity with due care, it undergoes definite changes, and dwindles to a considerable extent.

The testicle after a period of a month or so becomes reduced to two-thirds or half its original size, but the epididymis not nearly to the same extent. The organ is of a somewhat darker colour, and the blood-vessels, especially the small venules on the surface of the testicle, appear as if they were engorged or congested; but the remaining spermatic vessels, although

they seem smaller than those of the normal side, appear natural, and in no way disturbed in their course. The seminal tubules are much reduced and contracted—in most instances to about half their natural size; and they are lined by a single layer of columnar cells, which are prolonged into fine filamentous processes, converging towards the centre of the tubule, there being no trace of the formation of spermatozoa in any of the tubules. The central cells—namely, those which give origin directly to the spermatozoa in a natural tubule—disappear completely by means of a peculiar granular degeneration of the protoplasm, which shows no tendency to fatty transformation. All the above changes take place without the slightest evidence of the inflammatory process accompanying them.

Judging from the last specimen (Exp. VIII.) which had been replaced in the abdomen for ninety days, I should infer that the testicles do not undergo further change.

In order to illustrate this subject still more, I will introduce here two observations I recently made upon dogs, in one of which the right testicle was retained in the groin, and in the other within the abdomen, by some failure in the mechanism of descent.

Undescended Testicles in the Dog.

The *first* was a small fox-terrier, of about two and a half years old. The *right* testicle was found to have been retained in the groin, just outside the external ring. It was of small size, measuring 16 mm. in length by 11 mm. in breadth, (the *left* being 20 mm. in length by 15 mm. in breadth,) and it could neither be pulled into the scrotum nor pushed into the inguinal canal. It appeared natural, except in its size. Under the microscope the seminal tubules were undistinguishable from those already described and figured as occurring after replacement of the fully-developed organ, and therefore there is no need for further comment.

The *second* was also a fox-terrier, of about eighteen months old. The *right* testicle was found in the right iliac fossa, freely movable, and attached by a slender cord, which passed into the same side of the pelvis. The organ was small, measuring 15 mm. in length by 10 mm. in breadth, (the *left* being 25 mm. in

length by 18 mm. in breadth). The epididymis was correspondingly small.

Under the microscope the seminal tubules of this organ were precisely the same as those in the above instances, and in none of them could any trace of spermatozoa or of their production be detected.

Thus, in each of the above instances—the testicle retained in the groin in the one and in the abdominal cavity in the other—the organ was small, of about $\frac{2}{3}$–$\frac{1}{2}$ size of the healthy and descended testicle; and under the microscope the seminal tubules presented histological characters, undistinguishable from those found in the testicles, whether young or of full size, that were replaced in the abdominal cavity.

It would seem, therefore, that the experimentally replaced testicle behaves in precisely the same manner as one retained by imperfections in the mechanism of descent or transition.

Answers to Questions set forth at the beginning of this Paper.

From the results of the following experiments, the two questions which induced me to make them may now be answered.

The *first* question was, *Whether, when the testicle is replaced within the abdomen in a young animal, it is capable of attaining its full size and mature structure, and of producing spermatozoa?*

It is clear from the results of the first set of experiments that the testicle of a young animal, when replaced in the abdominal cavity, does neither acquire its full size or its mature structure, nor does it acquire the power of producing spermatozoa. Though it does to some extent partake of the general growth of the body, it does not do so to the same extent as the organ which acquires its natural position.

The *second* question was, *Whether, when the testicle is replaced within the abdomen in a full-grown animal, it is capable of maintaining its full size and mature structure, and its powers of producing spermatozoa?*

Again, it is pretty obvious from the results of the second set of experiments that the testicle of a full-grown dog, when replaced within the abdominal cavity, dwindles to $\frac{2}{3}$–$\frac{1}{2}$ its natural

size, and remains in this state for some time at least. It loses its powers of producing spermatozoa and the seminal tubules are much degenerated in their structure.

The Views held regarding the State of the retained Testicle.

These views, already referred to, have special reference to Man, and some would perhaps think them inapplicable to the Dog, the animal selected for the preceding experiments. Hunter first pointed out that a retained testicle was imperfect in its development, and that it was incapable of producing spermatozoa, and that when both organs were retained the person was sterile. This imperfection in development was regarded by him as the result of a fault in the organ itself, a fault that had arisen, at any rate, before the commencement of the process of descent, for it was this he conceived to be the cause of the failure in that process.

Curling, indeed, recognised this, and pointed out that the retained testicle presents the same structure as that of the descended organ before the onset of puberty, and simply that at this period it does not participate in the growth that takes place in the properly descended organ.

In Experiments II.–V. it may be seen that the retained, or rather replaced, organ not only does not participate in this natural growth at the time of puberty, but that the seminal tubules lose their what may be called infantile character, and acquire a structure that is peculiar to the replaced and also the undescended organ; that is to say, the seminal tubules during early life are solid rods of small polygonal cells (fig. 5, Plate XXV.), whereas those of the retained testicle at and after puberty are lined by a single layer of delicate columnar cells, which project as fine processes into and fill the lumen, the central cells of the tubule having disappeared.

Therefore Curling's view of the state of the seminal tubules in an undescended testicle falls short of correctness, for they are not like those found in the organ of the young, but have acquired features and characteristics of their own.

All I need say with regard to the view maintained by Godard, Monod, and Arthaud, that the retained testicle does

acquire its full size and powers of producing spermatozoa at and soon after puberty, is that I have not found any evidence in its support; and all my own results in the foregoing experiments, and observations made on Man—which are but few, it is true—show the contrary to be the case. There has never been brought forward an indisputable case of the detection of spermatozoa in retained testicles; and what Monod and Arthaud have depicted in their conjoint paper as a section of the testicle in which the seminal tubules are said to be in the act of producing spermatozoa is indeed, without the text, unrecognisable even as a section of that organ at all.

I would, in addition, remark that the results of the experiments related coincide so entirely that I have not thought it worth while to make further experiments of a similar kind.

No wonder the idea that the retained testicle would be functional should have arisen, seeing how varied is its permanent position. In the Monotremes, Cetacea, Sirenia, and Proboscidia it is permanently abdominal, in some Perissodactyla it descends so far as the abdominal ring; in other animals it enters the scrotum which may be inguinal or perineal. In some of these latter Rodentia and Insectivora the cavity of the tunica vaginalis freely communicates with that of the peritoneum, so that the testis may pass to and fro between the abdominal cavity and the scrotum, while in the remainder the canal of communication becomes very narrow, as in Carnivora and most of the Anthropoid Apes, or completely obliterated as in Man. Yet in all these different positions the testicle acquires perfect structure and function. In some animals, such as Rodents, Insectivores, the testis descends into the scrotum during the period of rut, but in others, as the elephant, it remains at all times in the abdominal cavity. What, then, can be the reason that in some, a limited number of animals, the scrotal position is essential to structure and function?

Why should the testicle be required to depart from its comfortable quiet position in the abdominal cavity to a more turbulent region where it is of some inconvenience, and during its transit causes a weakening of the abdominal wall so serious in the erect attitude? Can it be that the very turbulence of this

region is requisite for its perfect development and the maintenance of its functions in certain animals?

Furthermore, its corresponding organ, the ovary in the female, remains in all animals in the abdominal cavity.

So far as I am aware, no satisfactory answer has ever been offered to this most interesting question.

It is possible that the cremaster muscle might, by its compression of the organ, exercise some obscure influence upon the testis, and thus keep it in a state of functional activity, but the complete removal of this muscle, which I carried out in one experiment, seemed to make no difference whatever to the efficiency of the organ, for after a period of thirty-one days, this being ample time for the testicle to show signs of atrophy, the organ was of the same size as before; it was quite normal, and actively producing spermatozoa: the details of the experiment are as follows:—

The Testicle deprived of its Cremaster Muscle.

A fox-terrier three to four years old. On August 15, 1892, the right testis was deprived of its cremaster muscle by exposing the organ and carefully dissecting the muscular fibres off the parietal layer of the tunica vaginalis. The testis was then measured, and was found to be about 27 mm. in length by about 17 mm. in breadth. Exact measurements could not be taken, as the tunica vaginalis was not laid open. The organ was replaced in the scrotum, and all the parts healed quickly, the animal running about on the day, and no changes were afterwards observed in the testicle. On Sept. 15, 1892, thirty-one days after the operation, the dog was killed. The right testicle—namely, that deprived of its cremaster muscle—was of the same size as before, that is, 27 mm. in length by 17 mm. in breadth, and it looked quite healthy and natural.

On microscopic examination the seminal tubules were of natural size, the formation of spermatozoa could be seen in most of them just as under normal conditions, and the organ was in every way similar to its fellow on the left side, which had not been disturbed.

Conclusions.

The following are the chief conclusions from the foregoing experimental investigations and observations:—

1. When the testicle of a young animal is replaced within the abdomen it undergoes but little change, growing somewhat, but not so much as the undisturbed organ, until the onset of puberty.

2. A testicle so replaced after the onset of puberty continues to grow to some extent, though but little; the seminal tubules are seen to be lined by a single layer of columnar epithelial cells lying upon the tunica propria, with delicate prolongations extending into and occupying the lumen of the tubules; the central cells, from which in the normal state spermatozoa are produced, do not exist, and spermatozoa, accordingly, are not forthcoming.

3. The testicle remains in this state; at least, we have no evidence that it undergoes further change.

4. The testicle of a full-grown animal, when replaced in the abdominal cavity, soon dwindles to two-thirds or one-half its natural size, and after a short time presents precisely the same structure as that which is found in the replaced testicle of a young animal above noted.

5. The testicle, the descent of which has been arrested in the dog, either in the groin or in the abdominal cavity, shows the same histological characteristics as the organ which has been replaced by experiment.

6. Replacement of the testicle can, with ordinary care, be effected without injury to the organ, and without setting up inflammation in its structure, the occurrence of which would be detrimental to an experiment.

DESCRIPTION OF PLATES XXIV., XXV.

Plate XXIV., fig. 1. Testes, epididymes, vasa efferentia, &c., of a dog one year old (Exp. II.), showing the *right* organ of natural size, and the *left*, which was replaced when the animal was three months old, small, and hardly half the size of its fellow. The left epididymis is also small, and the vas deferens shorter (nat. size).

Fig. 2. Testes, epididymes, vasa efferentia, &c., of a dog ten to twelve months old (Exp. V.).

The *right* testicle is of full size, this size having been attained during the month preceding the day on which the animal was killed. The *left* testicle, which was replaced three months previously, and which was then of small size, remains small, having grown but little, as was the case with that in Plate I. (Exp. II.). The animal was killed as soon as the *right* testicle had attained its natural size, in order to determine whether the replaced organ had undergone the same changes as that which was left undisturbed in the scrotum. Obviously these changes had not taken place (nat. size).

Fig. 3. Testes, epididymes, vasa efferentia, &c., of a full-grown dog (Exp. VIII.). The *left* testicle had been replaced in the abdominal cavity for a period of three months. At the time of replacement the organ was of the same size as its fellow, which was left undisturbed in the scrotum. The left testicle very small in comparison with the *right*, and so is the epididymis (nat. size).

Plate XXV., fig. 1.—A section of the replaced (left) testicle seen in fig. 1, Plate XXIV. The seminal tubules are small and atrophied, but the intertubular connective-tissue is not increased. × 45.

Fig. 2. Transverse section of one of the seminal tubules seen in fig. 1, showing the absence of the central cells, elongation and fibrillation of the cubical cells at the periphery, the lumen being chiefly occupied by the prolongation of these cells. × 300.

Fig. 3. A transverse section of an atrophied seminal tubule taken from the replaced testicle (Exp. VII.), which was replaced thirty days before death, and which was then of full size. It shows the large granular masses formed by the degeneration of the central cells of the tubule prior to their ultimate disappearance; also the elongation and fibrillation of the cells at the periphery; also the total absence of spermatozoa-producing cells and spermatozoa. × 450.

Fig. 4. A transverse section of a seminal tubule taken from the left testicle (Exp. VIII.), fig. 3, Plate XXIV., which was replaced in the abdomen about three months before death, and which was then of full size. The central or spermatozoa-producing cells have completely disappeared, the peripheral cells having become elongated into a columnar variety projecting into and filling the lumen, the protoplasm of the cells is much fibrillated in the long axis of the cells. × 350.

Fig. 5. Sections of the tubules of the testis of a boy four to five years old, longitudinal and transverse; each is seen to be composed at this time of life of solid rods or columns of cells, which all present much the same appearance. In process of development these cells would differentiate themselves into circumferential cubical cells and central polygonal spermatozoa-producing cells.

Table of Results of Experiments.

No.	Description of Dog.	Date.	Nature.	Date of Death.	Size of Testicle before Experiment.	Size of Testicle after Death.	No. of Days Dog kept Alive.	Observations.
1	Fox-terrier puppy, about 9 mons. old	3. xii. 92	Replaced right testicle in abdomen	10. xii. 92	15 mm. × 12 mm.	15 mm. × 11 mm.	7	Soon about, and well.
2	Fox-terrier puppy	21. vii. 91	Replaced left testicle in abdomen	8. xi. 91	15 mm. × 12 mm.	18 mm. × 12 mm.	139	Remained quite well and lively.
3	Fox-terrier puppy, 3 mons. old	22. v. 91	Replaced left testicle in abdomen	9. iii. 92	15 mm. × 12 mm.	17 mm. × 13 mm.	293	Ditto.
4	Full-grown fox-terrier (Testicles small)	24. ix. 91	Replaced right testicle in abdomen	30. xi. 91	15 mm. × 12 mm.	17 mm. × 14 mm.	67	Soon well and running about.
5	Black terrier, about 6 mons. old	10. xii. 91	Replaced left testicle in abdomen	8. iii. 92	12 mm. × 10 mm.	16 mm. × 12 mm.	89	Soon running about.
6	Full-grown fox-terrier (Small)	7. xii. 92	Replaced right testicle in abdomen	14. xii. 92	22 mm. × 16 mm.	17 mm. × 13 mm.	7	Wound healed quickly.
7	Full-grown fox-terrier	13. viii. 92	Replaced left testicle in abdomen	13. x. 92	30 mm. × 10 mm.	20 mm. × 15 mm.	31	Remained well.
8	Small terrier	1. xii. 91	Replaced left testicle in abdomen	7. iii. 92	30 mm. × 20 mm.	18 mm. × 12 mm.	90	Quickly recovered, and as lively as ever.
9	Fox-terrier	15. viii. 92	Removed cremaster muscle	15. ix. 92	27 mm. × 17 mm.	27 mm. × 17 mm.	31	Dog was soon lively and well.

SYMMETRICAL DEPRESSIONS ON THE EXTERIOR SURFACE OF THE PARIETAL BONES (WITH NOTES OF THREE CASES).

By FRANCIS J. SHEPHERD, M.D., *Professor of Anatomy, M'Gill University, Montreal.*

THE occurrence of symmetrical depressions of the parietal bones has occasionally been noticed, but to Sir George Humphry we are indebted for bringing the subject prominently before Anatomists—first in his able work on the human skeleton (p. 242), and secondly (vol. viii.) of the *Journal of Anatomy and Physiology* (p. 136), in an article entitled "Depressions in the Parietal Bones of an Orang and of Man."

The occurrence of these depressions Professor Humphry could not explain: they are certainly not the result of accident or disease, nor are they always the result of senile changes, for the case of an infant born with a parietal depression is cited in the treatise on the human skeleton, and in my third case the patient had always had the depressions.

In addition to the parietal depressions, which are usually of large size, measuring nearly 7 c.mm. in length by 5 or 6 in breadth, and situated parallel to and half an inch from the sagittal suture, there is often a thinning of the sagittal suture itself, and, as in a case of my own reported below, the lambdoidal suture as well.

These changes in connection with the sutures are probably senile, for all the cases reported were in old women.

Paget regards the condition as due to atrophy, and Mair (*Virchow's Archiv*, vii. 338) looks upon it as one of senile osteoporosis.

In Professor Humphry's treatise on the human skeleton, six cases are referred to, four of which were in the Dupuytren Museum in Paris, one at Cambridge, and one in Berlin, but at present specimens of this condition are not uncommon, and are found in most museums. The depressions are at the expense of the two outer tables, ovoid in form, smooth, and situated

between the sagittal suture and the parietal eminences. The depressions extend forwards to a short distance from the coronal suture. When seen as a dry preparation, the skull has an appearance as if the two outer tables of bone had been sliced out, leaving only the inner table, which is of the thickness of parchment and quite translucent. On looking at the inner surface of the skull opposite to the depressions we find the bone perfectly normal in appearance and quite smooth, showing no evidence of external indentation.

It has been my fortune to meet with no less than three cases: two in the dissecting-room, and one in a living individual.

CASE I.—This has already been published (*Montreal General Hospital Report*, vol. i. p. 72). The case occurred in a female subject aged forty; the depressions existed on each parietal bone, were ovoid in shape and symmetrical, measuring 7 c.mm. in length by 5 in breadth.

The depressions were quite smooth, and "had the appearance of having been scooped out by some sharp instrument." The bone at the bottom of these depressions was of the thickness of paper.

CASE II.—This also has been reported (*Annals of Anatomy and Surgery*, vol. vi. 1882). I transcribe the description of the case:—

"The skullcap of an old woman over seventy presented a remarkable appearance. In each parietal bone, 1 c.m. from the sagittal suture, is an oblong, ovoid, smooth depression, measuring on the right side 7 c.mm. in length by 5 c.mm. in breadth, and on the left 8 c.mm. in length by 5·5 in breadth.[1]

"These depressions are about one centimetre in depth, and as they approach the coronal suture they increase their distance from the sagittal. They terminate anteriorly 3 c.mm. from the coronal suture. The deficiency of bone is evidently at the expense of the outer and middle tables, for the inner surface of the skullcap is perfectly smooth, the bone at the bottom of the depressions is quite transparent and of the thickness of parchment. In addition to the above described depressions, others are seen in the course of the lambdoidal suture." These depressions were similar to the parietal ones, and measured 5 c.mm., by 1·5 c.mm.

All the bones of the body in this old woman were atrophied, and of almost papery thinness. There was an intracapsular fracture of the right femur.

CASE III.—This is the most interesting of all the cases, because it occurred in a living person, and the congenital history is well established.

[1] This specimen is in the Medical Museum, M'Gill University.

The patient, Mrs B., aged sixty-two, came to me in 1890, suffering great agony from long-continued paroxysmal neuralgia of the superior maxillary division of the fifth nerve, for which I stretched the infraorbital branch with good effect. As soon as she was under ether I noticed a remarkable depression on each side of the sagittal suture, extending outwards as far as the parietal eminence; these depressions, owing to the great emaciation of the woman from long years of suffering, were well seen, and could be easily measured. Each one was 6 c.m. wide by 8 c.m. long, and apparently of the depth of the thickness of one's finger, say 1·5 c.m. The patient, on my subsequently questioning her regarding these parietal depressions, was much amused, and said I was the first medical man who had ever noticed them. She then went on to say that ever since she could remember they had existed, but were more apparent now on account of the emaciated condition in which she was. She also said that her father had had similar depressions on his head.

Now, this case supports the congenital theory of some of the cases, and also would suggest its hereditary nature. This patient I saw a short time since, and again measured the depressions; they were exactly the same size as three years before. These parietal depressions do not occur at the centre of ossification, and must not be confounded with the cases described by Sir James Paget, where at each parietal eminence there is a depression "such as the thumb would make if pressed in soft clay." In the cases above described, which I have no doubt are congenital, the depressions are of large size, and do not involve the centres of ossification.

Now, what is the significance of these depressions, and how are they produced? No doubt many of the cases which occur in very aged females are due to senile atrophy, and Professor Sir George Humphry has thrown out the suggestion that the formation of these parietal depressions may be due to the effect of pressure of the occipito-frontalis tendon, but the comparative rarity of the condition would, it seems to me, be strongly against this explanation.

It is more probable that the more advanced senile changes in the arteries (temporal) going to this part, uncovered by muscular tissue, would interfere with the nutrition of the external surface of the bone, whilst the inner surface supplied by the middle meningeal would remain normal, chiefly from the fact that the senile changes in this vessel would not be so extreme.

In some of the cases, however, senile changes will not explain the condition, for cases have been recorded as occurring in infants and children, and Professor Humphry has observed somewhat similar depressions on the skull of the orang.

In the third case reported above, the condition was evidently congenital and hereditary. Whether these cases are reversions to an earlier condition or not I cannot say, but I think the congenital and perhaps hereditary nature of these depressions in some cases, at least, is fairly proven.

From a medico-legal standpoint, these cases are especially interesting, for it can be easily imagined that with the slightest amount of injury the most serious results might ensue.

ON THE MORPHOLOGY OF THE MUSCULUS STERNALIS. By F. G. PARSONS, F.R.C.S., *Lecturer on Comparative Anatomy and Demonstrator of Human Anatomy at St Thomas's Hospital.*

THE morphological significance of the musculus sternalis has given rise to such great difference of opinion among Anatomists that every point seeming to bear out any of the existing hypotheses is worth recording and subjecting to criticism.

The main facts hitherto noticed about this muscle are—

1. That it occurs in from 3 to 5 per cent. of human subjects, though much more commonly in anencephalous monsters.

2. That it occurs in nearly the same proportion in male and female subjects.

3. That it is not found as a definite muscle in any of the lower animals.

4. That it always lies superficial to the pectoralis major.

5. That it is very frequently continuous with the sterno-mastoid above.

6. That below, it is usually attached to the aponeurosis of the external oblique, or at all events to the sheath of that muscle, which is blended with the aponeurosis.

7. That it may be uni- or bi-lateral.

8. When it is unilateral, it may cross the mid-line obliquely. When it is bilateral, the two muscles are frequently connected across the middle line, or they may cross one another obliquely, forming a × in front of the middle line.

9. That it is usually supplied by one of the anterior thoracic nerves (Cunningham[1] and Shepherd[2]), or by the intercostal nerves (Bardeleben).

10. That it very occasionally has tendinous intersections.

11. That when a well-developed platysma coexists with it, the platysma is always on a plane superficial to it.

12. That it frequently pushes the anterior cutaneous branches

[1] *Journal of Anatomy*, vol. xxii. p. 392.
[2] *Ibid.*, vol. xxiii. p. 303.

of the intercostal nerves inwards, so that they form loops round its inner margin.

From these facts the following are the chief theories that have been suggested:—

1. That it is a prolongation upwards of the rectus abdominis.

2. That it is a muscle peculiar to Man, corresponding to nothing in the lower animals (Halbertsma).

3. That it is a continuation of the sterno-mastoid above and of the external oblique below (Testut).

4. That it is a continuation downwards of the sterno-mastoid (Bourrienne, Theile, and Henle).

5. That it is formed by fibres of the pectoralis major, which have become rotated at right angles to the generality of the fibres (Cunningham).

6. That it is a remnant of the panniculus carnosus (Wilde, Hallet, and Turner[1]).

The points for and against these various theories have been so fully discussed by Turner and Cunningham in the papers already mentioned, as well as by Testut in his *Anomalies Musculaires*, that to recapitulate them is unnecessary.

To my mind, the theory advocated by Sir William Turner, that the sternalis is a remnant of the panniculus, carries most weight, though until lately it has been attended by two objections. These are, firstly, the fact that the sternalis is so frequently connected with the sterno-mastoid; and, secondly, that the platysma lies on a superficial plane to the sternalis. I should like to point out one or two facts that I have noticed in dissecting lower animals, which seem to bear on these points.

In many of the rodents, especially in the guinea-pig, there are two distinct planes of panniculus in the neck. The most superficial runs over the pectoralis, as in ourselves, and corresponds to the platysma. The deeper plane passes from the region in front of the ear to be attached to the anterior and ventral part of the sternum, lying on, and having the same direction as, the sterno-mastoid.

The abdominal panniculus of the Agouti I described in the

[1] *Journal of Anatomy*, 1867.

Proceedings of the Anatomical Society for February 1892, and I have since found that the description applies to some sixteen other rodents.[1]

On reaching the axillary border of the pectoral this muscle divides, and passes, both superficial and deep, to it. Moreover, the ventral panniculus is supplied by a large nerve, which also supplies the pectoral, and represents the internal anterior thoracic of Man.

In Man the deep abdominal panniculus has probably become the fascial sheath over the external oblique, and it is quite possible that the deep part of the cervical panniculus which lies over the sterno-mastoid, and deep to the platysma (superficial cervical panniculus), may have become incorporated with the sterno-mastoid. If this is granted, nothing is simpler than to regard the sternalis as the remnant of a connection between the deep cervical and the deep abdominal panniculus, seeing that it is attached so often to the sterno-mastoid above and to the external oblique or its sheath below.

The nerve supply of the sternalis bears out this view, as Professor Cunningham and others have found that it is very often supplied by the internal anterior thoracic, the same nerve that supplies the abdominal panniculus.

This theory, moreover, accounts for the coexistence of the platysma with the sternalis, though on a more superficial plane.

I have given my reasons[2] for regarding the pectoralis major as derived from the panniculus; if these are accepted, it matters very little whether we regard the sternalis as part of the panniculus or as part of the pectoralis major.

[1] In the *Proceedings of the Anat. Soc.* for February 1892 (this *Journal*, April, vol. xxvi.) I showed that there was a superficial and a deep layer of abdominal panniculus.

[2] *Anatomical Society*, February 1892.

CONTRIBUTIONS TO THE HISTOLOGY OF THE HEDGEHOG.

By E. W. CARLIER, M.D., B.Sc., F.R.M.S., *Physiological Laboratory, University of Edinburgh.*

(PLATES XXVI., XXVII.)[1]

PART V. THE SO-CALLED HIBERNATING GLAND.

THIS organ, which, for want of a better name, is usually termed the "hibernating gland," is a bilateral, lobulated organ of an orange-brown colour, situated chiefly in the axillary, cervical, and dorsal regions. It does not appear to extend along the aorta into the chest and abdominal cavities, as in the case of the marmot and of some other hibernating animals—at least in the individuals that have come under my notice.

The axillary portion, which is the most voluminous, is roughly triangular in shape, with the apex directed upwards and forwards, to become continuous over the sternal end of the clavicle with another similar mass lying on the surface of the sterno-mastoid muscle, in the septa between it and neighbouring muscles, and also closely investing the external jugular vein. On cutting through the sternal attachment of the sterno-mastoid a prolongation of the organ may be seen beneath it, extending downwards behind the scapula to the middle line posteriorly, where it comes into relation with the spinal column, along which it passes downwards for some distance, giving off small lobules that lie between the various muscles of the back. Another portion passes upwards between the erector muscles of the back of the neck, reaching almost to the occipital bone. In this way small lobules may be found between nearly all the muscles of the back and neck, giving the organ a very wide area of distribution along the lines of the inter-muscular septa, from the connective-tissue cells of which it seems to arise, so that it may be regarded as a modification of connective tissue. Although its cervical lobes come into close anatomical relation with the thymus and thyroid bodies, the hibernating gland has

[1] Parts I., II., III., and IV. appeared in vol. xxvii. of this *Journal.*

no connection with nor structural resemblance to them, as has been stated by some authors, nor does it in any way resemble a lymphatic gland.

The hibernating gland varies in size at different periods of the year, being most voluminous towards the end of October; that is to say, at the commencement of the winter sleep, when it is equal to about 3·04 per cent. of the total body-weight. It rapidly diminishes in size during the early part of the hibernating period, and at the beginning of January only equals 1·5 per cent. of the total weight of the animal, which, if we take into account the great loss of weight sustained by the whole body, means that it has diminished to a little less than a third of its original weight. By the end of March it has decreased still further, representing only 0·9 per cent. of the body-weight. After the animal awakes in spring it undergoes still further atrophy until about the beginning of June, when its only remanent may be a few fibrous cords. By the end of the same month these begin to enlarge, and the gland is practically redeveloped in time for the winter sleep.

The period of year, however, is not the only cause of variation in size of the organ, for the age of the animal and the abundance and nature of its food govern the maximum size attained in any particular case.

The nerve-supply of the axillary part of the gland is derived from the cutaneous branches of the 3rd, 4th, and 5th intercostal nerves, which are of considerable size, and have a large ganglion developed in connection with them. The remainder of the organ derives its nerves from the cutaneous branches of the cervical and upper dorsal nerves. The blood-vessels, which are very abundant, are derived from the corresponding intercostal and cervical vessels, and form the inferior thyroid artery. There is also an abundant supply of lymphatic vessels.

Minute Structure—Literature.—Both Jacobson[1] and Marshall Hall[2] regarded this organ as consisting chiefly of a mass of fatty tissue, while Prunelle[3] and Mangili[4] looked upon it

[1] *Meckel's Archiv*, vol. iii. pp. 151–152. [2] *Phys. Trans.*, 1832.

[3] "Recherches sur les phénomènes et sur les causes du sommeil hivernal de quelques mammifères," *Annales du muséum d'histoire naturelle*, vol. xviii. p. 302.

[4] "Memoire sur la léthargie des marmottes," *Annales du muséum d'histoire naturelle*, vol. ix. p. 106.

rather as an outgrowth from the thymus gland. Ecker[1] described it as consisting of polygonal cells of varying size embedded in a structureless stroma, surrounded by a dense network of minute capillary blood-vessels. He found that in young animals the cells contained much proteid matter, soluble in potash, and small nuclei, and that in older animals and during summer they contained fat. He recognised that the organ has nothing in common with the thymus or any other blood-gland.

Valentin[2] in 1857 stated that he found the lobules rich in nuclei, unaffected by acetic acid, the whole structure reminding him of the thymus. Leydig[3] regarded it as a sort of lymph-gland. Hirzel and Frey[4] studied the structure of the organ in several hibernating animals. They denied the existence of Ecker's cells, and described the inter-capillary spaces as filled with an extremely delicate network of minute fibrils, in the interstices of which the fatty contents lie; and that, therefore, there is no similarity of structure either with the thymus or with lymphatic glands. In fact, they were unable to make out any glandular structure.

My method of observation has been the following: The tissues were fixed at death either in Flemming's strong chromo-osmo-acetic acid, or in 0·75 per cent. salt solution saturated with corrosive sublimate, and taken through the alcohol series, and embedded in paraffin in the usual way. The sections were stained on the slide either with some of the anilin dyes, or with eosin and hæmatoxylin, or with Heidenhain's iron alum hæmatoxylin,[5] and mounted in balsam; of these Heidenhain's hæmatoxylin gave the best results. In some cases portions of the tissue were teased out, either in the fresh condition or after treatment with osmic acid, stained in picro-carmine and mounted in Farrant's solution. The preparations were examined with the $\frac{1}{18}$ oil immersion lens and compensation eyepiece No. 4 of Zeiss.

[1] "Blutgefässdrüsen," in Wagner's *Handwörterbuch der Physiologie*, Bd. 4, s. 121.

[2] *Moleschott's Untersuchungen*, Bd. 2, s. 12. [3] *Leydig's Lehrbuch*, s. 431.

[4] "Einiges über den Bau der sogenannten Winterschlafdrüsen," in *Zeit. f. Wissenschaft. Zoologie*, Bd. 12, pp. 165–173.

[5] *Festschrift für v. Kölliker*, Würzburg, 1892.

If the organ be examined in October,—that is, when it has attained its maximum development,—all its lobes present exactly the same microscopical characters. Each lobe is surrounded by a fibrous capsule of varying thickness, and is subdivided into lobules by fibrous septa. In these septa the larger blood-vessels, lymphatics, and nerves ramify; the capsule often contains much adipose tissue, and its variations in thickness are mainly due to the number of fat-cells which it contains. Occasionally small masses of lymph follicular tissue are present, both in the septa and capsule, as well as a few "plasma"-cells.

The lobules consist of somewhat elongated polyhedral cells, each with a distinct envelope enclosing protoplasm with a wide-meshed network, in the interstices of which various-sized droplets of fat may be seen (fig. 2, Pl. XXVI.). The globules of fat vary in number and size in different cells; sometimes many small spherical or elliptical droplets are present, or there may be only a few larger ones, or even only one very large drop, occupying nearly the whole cell, in which case an appearance not unlike that of a fat-cell is produced; but there is always this difference, that, whereas in a fully-formed fat-cell the protoplasm has almost entirely disappeared and the nucleus has become flattened against the envelope, in the hibernating gland a considerable amount of protoplasm always remains between the fat and the envelope, and the nucleus retains its spherical shape.

If isolated cells be examined, they appear rounded or oval in shape and measure 30 μ to 33 μ in diameter (fig. 1, Pl. XXVI.). Most of the cells have a single spherical nucleus 5.7 μ in diameter; in some cells there are two nuclei. The nucleus has a definite membrane and is very rich in chromatin, so that its nucleolus is much obscured. The nucleus usually occupies the centre of the cell, with the fat-droplets round it, leaving the periphery of the protoplasm almost free from fatty matter. The organ is entirely devoid of ducts, so that the only channels by which its products can escape are the veins and lymphatic vessels.

The blood-supply is very rich; the large arteries ramify in the septa and give a branch to each lobule. The capillaries form a close network and come into contact with the cells, as in

the case of adipose tissue. The blood of each lobule is returned by a single vein that accompanies the artery and opens into larger veins situated in the fibrous septa. If the vessels of a lobule be injected, it resembles a lobule of adipose tissue. Numerous lymphatic capillaries also ramify throughout the lobule in close relation to the cells, and open into large lymphatic vessels situated in the septa between the arteries and veins (fig. 1, Pl. XXVII.).

The innervation of the arteries is especially interesting, as they exhibit, in addition to the plexus of non-medullated nerve-fibres described by Beale[1] between the tunica adventitia and tunica media, a second fine plexus of non-medullated fibres between the media and intima, the two plexuses being connected at somewhat wide intervals by short communicating fibres that pierce the tunica media. The inner plexus is much closer and finer than that of Beale, and exhibits small ganglion cells at intervals (fig. 3, Pl. XXVII.). It is best studied by staining the ganglion of the axillary part of the organ with gold chloride, by Löwit's method, modified by Ranvier,[2] teasing out the vessels, and endeavouring to tear them so as to rupture their outer and middle coats, and leave their inner coat intact. This is somewhat difficult to accomplish, and requires patience. The function of this plexus is undoubtedly vaso-motor.

The ganglion in connection with the axillary lobe consists of a multitude of very small pyriform unipolar ganglion cells, with very long stalks that usually exhibit one or two loops; the cells are closely packed together, and each of them has a single nerve-fibre, its axis-cylinder describing one or more curves inside the envelope before finally entering the protoplasm. The envelope surrounding the cell is merely part of the grey sheath of the nerve especially enlarged; there is no lymph space lined by endothelial cells between it and the protoplasm of the cell, as is the case in peripheral ganglia generally. The cell-protoplasm is granular, and contains a single rounded vesicular nucleus with a minute nucleolus. Although many nerves enter the ganglion before being distributed to the various parts of the organ, all do not do so; some pass directly along the blood-

[1] *How to Work with the Microscope*, London, 1880, p. 147 *et seq.*
[2] *Traité Technique d'Histologie*, Paris, 1875, p. 826.

vessels to which they are probably vaso-motor, while others are directly traceable to the vicinity of the gland-cells near which they terminate.

Origin of the Cells of the Gland.—It may be observed, during the growth of the organ, that the cells arise at the margin of the lobules from small, round, uninucleated granular connective-tissue cells, very similar to those that usually give rise to adipose tissue (fig. 1, Pl. XXVI.). These small cells slowly enlarge, the nucleus as well as the protoplasm participating in the growth, a cell network gradually becomes apparent, and the cells begin to stain of a dark olive-brown colour with osmic acid, indicating either the presence of fat diffused throughout, or of some antecedent substance; presently, tiny droplets of fat make their appearance, which increase in size and number with the growth of the cell, or by coalescence produce several or even one large droplet, filling the whole cell; a little protoplasm only remaining under the capsule, in which is the slightly flattened nucleus. The latter appearance is rare, and the protoplasm is never so reduced as in ordinary fat-cells, a hollow sphere of some thickness always being present, which renders them readily distinguishable from typical fat-cells. As the cells increase in size they lose their rounded shape, becoming polyhedral by mutual pressure.

From the foregoing it will be seen that Ecker's cells do in reality exist, and that the felted mass of fibrils described by Hirzel and Frey probably resulted from the imperfect methods then in use. The nuclei described by the latter investigators, in the case of the bat, in the middle of "areas," are no doubt the nuclei of the cells either swollen by their reagents, or in an advanced stage of transformation towards their final disappearance, as will be presently explained.

Further, the organ differs so entirely in structure from the thymus and other blood-glands that it cannot be mistaken for them under the microscope; it resembles the blood-glands only in being ductless. There is not the slightest trace of any formation or destruction of blood-corpuscles to be found in it.

If the organ be examined in January, many changes will be found to have supervened in the cells and in the appearance of

the tissue generally. The changes seem to originate in the cell-protoplasm, the network of which appears to become coarser and less regular, resolving itself into large more or less isolated granules, and the fat stored in the cell is gradually absorbed. A coagulable material, derived, I believe, from the protoplasm, makes its appearance among the granules, which in hardened preparations is homogeneous and celloid-looking (fig. 4, Pl. XXVI.); at present I am unable to state the nature of this product, which, however, I can say is certainly not glycogen. It is insoluble in water and in alcohol, but is sparingly soluble in ether. From the spaces in the cell it passes into and distends the lymph-capillaries between the cells and also the larger lymphatic vessels situated in the fibrous septa (figs. 1 and 2, Pl. XXVII.). The whole cell-protoplasm appears eventually to be converted into this material and to be carried away by the lymph-stream, and is probably of service in the nutrition of the body. The production of this material begins with hibernation, and may even be seen distending the lymphatics as early as October. The cell wall, which for a short time remains distinct, is presently lost to view, when it becomes extremely difficult or quite impossible to distinguish one cell from another.

Whilst these changes are occurring in the cell-protoplasm, other changes of no less importance are taking place in the nuclei, which are probably produced by excess of nourishment, since the nucleus lies in the centre of a mass of nutrient material. They gradually swell up, and assume a more perfectly spherical shape. In so doing the chromatin either actually diminishes in amount, which it certainly does a little later, or, being spread over a larger surface, appears to be diminished, thereby revealing its net-like arrangement and the structures situated within it. These consist of a nucleolus of considerable size which stains deeply, in which one or more minute endo-nucleoli may be seen as colourless rounded bodies (fig. 3, Pl. XXVI., and fig. 4, A and B, Pl. XXVII.). Presently the nucleolus may be observed to give off one or sometimes two masses of nucleolar material of homogeneous appearance, which may be termed para-nucleoli (fig. 4, C, Pl. XXVII.), similar to those sometimes observed in the ovarian cells of certain animals. These would appear to result from an unequal division of the nucleolus; the smaller

portion or portions producing the para-nucleoli gradually make their way towards the nuclear wall, through which they pass into the cell-protoplasm, where they eventually break down and disappear (fig. 4, D, Pl. XXVII.). This process may be repeated several times, until the nucleus itself begins to degenerate. More endo-nucleoli make their appearance in it, followed by the migration of the nucleolus towards the nuclear wall, which it pushes out before it, finally producing a rupture through which it escapes into the cell contents, the ruptured nuclear bag still containing a few chromatin filaments remaining behind in a more or less collapsed condition (fig. 4, E, F, G, H, and I, Pl. XXVII.). The nucleolus travels some little way from the collapsed nuclear bag, degenerates rapidly, the margins being first affected, till finally it disappears, followed eventually by the entire disappearance of the nuclear bag.

Sometimes the nucleolus at first divides into two equal halves, which is followed by the division of the nucleus, thereby giving rise to two nucleoli situated side by side in one cell, in each of which para-nucleoli soon make their appearance, the processes continuing as above till both have disappeared.

These changes give rise to peculiar appearances in the tissue, the more so as they occur in patches, all the cells of one lobule not participating in the change at one and the same time, but successively. Therefore in the same lobule we may observe the normal cells with their nuclei rich in chromatin, and immediately adjacent to them a group of cells all fused together, with nuclei in different stages of transformation; further, as the cells become absorbed the blood-vessels come closer together, giving rise to a worm-eaten appearance; they also appear somewhat distended, and with Heidenhain's method of staining exhibit in their interior numerous small particles of deeply-stained material, that may or may not be blood-plates, though they resemble them closely in size and appearance.

Here and there, also, one may find a cell with a very large nucleus, twice or even thrice the size usually attained by the swollen nuclei. No doubt, in this case, the cell, situated as it is in the centre of a rich supply of food, takes some of it up, to the immense advantage of its nucleus, from the nucleolus of which large para-nucleoli are freely given off; this, however,

does not save the cell from ultimately undergoing the same changes as its neighbours.

Finally, shortly after the awakening of the animal, the organ appears reduced to a network of capillary vessels, surrounding small open spaces, from which all or almost all cell-structure has disappeared (fig. 5, Pl. XXVI.). Any cells that may yet remain exhibit a condition of advanced fatty degeneration.

It is a remarkable fact that phagocytes, which are so commonly associated with removal of tissues, are entirely absent from this organ, the more so since, as I have elsewhere shown, they exist in vast numbers in almost every tissue during hibernation.

The variations above described are probably brought about by some trophic change in the cell, whereby it is induced to manufacture a nutritive material. The nucleus of the cell would naturally, from its position, be the first to profit by this supply of suitable food, and would consequently grow larger, its achromatic portion being apparently the part to increase. The nucleolus situated in the centre of this well-fed nucleus could hardly fail to benefit by its prosperity, and so increase in size, resulting eventually either in equal division, or in the throwing off of portions of its substance, *i.e.*, the para-nucleoli, as nucleoli are known to do in other well-nourished animal and vegetable cells,—for example, in ova. At a later date the same cause, whatever it may be, that produces the migration of the para-nucleoli, may be supposed to act on the nucleolus itself, resulting in its migration and ultimate death by starvation in the cell-protoplasm, where, owing to the absence of chromatin, it is unable to procure suitably elaborated food, as has been pointed out by Dr G. Mann.[1]

It seems to me, therefore, that one may safely conclude that the so-called hibernating gland, which is found largely developed in all hibernating animals, acts first as a storehouse for fat, which increases in it so long as the animal obtains food, but undergoes no further increase as soon as the animal begins to hibernate; and also that the gland directly serves to nourish the animal during its long period of fasting by giving up its

[1] "The Embryo-sac of *Myosurus minimus*," *Trans. and Proc. Bot. Soc. Edin.*, 1892.

stored fat, and by becoming transformed, a few cells at a time, into a material of high nutritive value, which transformation is probably regulated by trophic nerves directly under the control of the central nervous system; and this is rendered the more probable by the well-known fact that fat alone is quite insufficient for the nutrition of the animal body.

EXPLANATION OF PLATES XXVI., XXVII.

Plate XXVI. fig. 1. A group of cells of the hibernating gland, isolated after fixing in Flemming's strong chromo-osmo-acetic acid solution.

a and *b*. Young cells almost devoid of fat.

c. A young cell, showing small fatty particles appearing in the protoplasm.

d, *e*, *f*, *g*. Various successive stages in the growth of the cells, showing the gradual increase in the amount of fat.

h. A typical fully developed cell.

Fig. 2. Section of the gland, fixed in October in Flemming's strong solution.

The envelopes and protoplasmic networks of the cells are well seen. The fat droplets (*f*) arranged near the nuclei, rich in chromatin (*n*). Nucleoli can just be seen in them.

(*c*) Capillary blood-vessels between the cells.

Fig. 3. Section of hibernating gland fixed in January in corrosive sublimate.

Most of the cell-walls have now disappeared, and the protoplasmic network become indistinct; the fatty contents have for the most part disappeared from the cells.

The nuclei (*n*) are swollen and poor in chromatin, but exhibit a distinctly marked nucleolus, and in one case (*p*) a para-nucleolus also.

(*c*) Capillary blood-vessel.

Fig. 4. Section of gland at about the same period as that of fig.(3), fixed in corrosive sublimate.

The capillary lymph-vessels (*l*) and spaces (*s*) in the cell protoplasm, which is rapidly breaking down, are seen filled with colloid material.

Fig. 5. Section of gland at the end of hibernation, fixed in Flemming's strong solution.

The cells have become reduced to mere granular debris aggregated round the capillaries, in some of which nuclei may be seen, leaving large empty spaces in the tissue.

Plate XXVII. fig. (1). Section of gland fixed in Flemming's strong

solution showing a lymph-vessel distended with colloid material, and situated in a fibrous septum between two blood-vessels.

Fig. (2). A portion of the distended lymph-vessel of fig. (1) more highly magnified.

Fig. (3). An artery of the ganglion of the hibernating gland, stained with gold chloride, showing a fine non-medullated nerve-plexus under the tunica media (*m*), a portion of which still remains adhering to one side of the vessel.

(*g*) Ganglion cell of the nerve-plexus.

Fig. (4). A series of drawings illustrating the changes occurring in the cell nuclei during hibernation.

b, nuclear wall; *n*, nucleolus; *e*, endo-nucleolus; *p*, para-nucleolus.

A. Nucleus much swollen, poor in chromatin, nucleolus distinct.

B. A similar condition, showing an endo-nucleolus.

C. Nucleus, showing a para-nucleolus migrating towards the nuclear envelope.

D. Para-nucleolus after passing through the nuclear wall, lying in the cell protoplasm, in which it will break down and disappear.

E. Passage of the nucleolus, in which are several endo-nucleoli towards the nuclear wall.

F. Nucleolus in the act of passing through the nuclear wall.

G. Nucleolus just after leaving the nucleus.

H. Collapse of the nucleus.

I. Degeneration of the nucleolus and remains of the collapsed nuclear bag.

NOTES ON THE DEVELOPMENT AND VARIATIONS OF THE ATLAS.[1] By A. MACALISTER, M.D., LL.D., D.Sc., *Professor of Anatomy, University of Cambridge.*

THE Cambridge Anatomical Museum contains a large series of specimens illustrating the development and the variations of the atlas, and from these I have compiled the following notes:—

I. DEVELOPMENT.

At what precise time the cartilage of the atlas first assumes its characteristic form my specimens do not definitely show. In sections of a fœtus in the fifth week the ring of cartilage seems complete, and in one of the sixth week there is a sign of the beginning of ossification on each side of the posterior arch close to the lateral mass; the articular cavities between the lateral masses and the condyles are distinct, but no definite cavity appears between the odontoid process and the tissues around it.

In the third month the cartilaginous ring of the atlas is larger than that of any of the other vertebræ. The bony nucleus in the hinder arch now appears as a stumpy, slightly-curved rod, about 2 mm. long, extending from the base of the pedicle beneath the vertebral artery (whose lumen is easily seen), and forming a considerable element of the lamina.

In a four-month fœtus the atlas measures 8 mm. coronally by 3 sagittally, and the bony rod has become 3 mm. long, its anterior end invading the articular mass. In a specimen about a week older the gristly ring has become nearly 10 mm. in breadth.

Growth seems rapid at this stage, and within the first week of the beginning of the fifth month the several muscles attached to the posterior arch can be recognised in the sections. They have appeared before this date, but are not easily separable from each other. The ring now measures 11 mm. by 5.

About a week later the vertebra measures 13 mm. by 6, and the

[1] Read in abstract to the Anatomical Society, May 23, 1893.

rod of bone is nearly 4 mm. long. By this time—*i.e.*, the middle of the fifth month—the gristly odontoid process is distinct from its fibrous surroundings, and there is a clearly-marked fissure between it and the anterior arch of the atlas in front and the transverse ligament behind. The bony rod is club-shaped, slightly dilated at its hinder end, flattened beneath the artery and nerve, and swollen again anteriorly where it enters the cartilaginous lateral mass. The unossified interval between the two bony elements in the posterior arch is about 4 mm. At this period ossification extends outwards into the cartilage of the transverse process, in front of which the vertebral artery ascends, having a band of connective tissue anterior to it.

At the end of the fifth month the atlas measures 16 mm. by 9; the bony rod has grown to 6 mm. or 7 mm. in length: and as its outer end has extended into the transverse process, the outline of this rod is somewhat *f*-shaped. More than half the posterior arch is ossified, and nearly a third of the superior articular part of the lateral mass.

Early in the sixth month the vertebral ring measures from 18 to 20 mm. by 10 to 12. The bony lateral rod is now 9 mm. long, and the osseous element in the transverse process is swollen external to the vertebral artery. Nearly half of the lateral mass is now ossified.

In one specimen (No. 8) there is a small secondary centre of ossification close to the front end of the left bony rod, and on its inner side and from it the inner and anterior part of the left glenoid cavity is being ossified.

By the end of this month the ring has grown to 25 mm. coronally by 15 sagittally, and the bony rod is 10 mm. long; the posterior cartilaginous interval being about 6 mm. At this period the transverse ligament is distinct and fibrous, starting from the cartilage anterior and internal to the end of the bony part of the arch. There is fibrillar tissue on either side of the odontoid process, which is continuous into the sheath of the anterior arch on either side.

In the seventh month the whole area corresponding to the inferior articular surface and more than three-fourths of the posterior arch are ossified, and the bony growth in the lateral mass extends in front of the vertebral artery. The hinder lip

of the glenoid cavity, which rises in front of the third stage of the vertebral artery, is also bony. The ring now measures 26 mm. by 15; in one seven-months' atlas it was 28 by 16. The bony rod has now become 11 to 13 mm. long.

By the eighth month the ring is 32 mm. by 18, with a bony rod 13 mm. long. In one atlas of this age there is a post-glenoid cartilaginous process. At the end of this month the bone has become 14–15 mm. long, and at the end of the ninth month it is 16 mm. By the period of birth the atlas has become 32 mm. by 20, and the posterior unossified gap is 3 to 5 mm. long. The area from which the transverse ligament arises is still cartilaginous, and the front boundary of the arterial foramen is fibrous, with an axial mass of cartilage cells.

As early as the seventh month the outer margin of the glenoid cavity begins to show a prominent angle anteriorly at the place where the last-named fibrous tissue is attached. This has become a definite process in the costal angle of the glenoid cavity, by the ninth month.

In none of the thirty full-time fœtuses wherein I have examined the atlas have I found any trace of ossification in the anterior arch. Meckel found a round bony nucleus in the middle of this arch in one out of thirty skeletons which he examined. As it has thus occurred only once in sixty specimens, such premature ossification must be rare. On the other hand, I found the arch entirely cartilaginous, with no trace of bone, in an infant twenty months old, although the ossification of the glenoid cavity was largely advanced, and the costal angle was thick and strong. In this specimen the posterior lip of the glenoid cavity is prolonged to overlap the vertebral artery. In the neck of a Peruvian mummied infant of about one year of age the arch is also completely gristly.

In the atlas of a child eight months old (No. 57), ossification has begun in the front arch by the formation of an asymmetrical central nucleus, wider above than below, and extending from the upper to the lower border of the arch. This nucleus is 3 mm. wide.

In atlas No. 18, from a boy aged five months, the bony nucleus measures 6 mm. by 2. Its upper edge is trilobed, and its left end may have originated from a separate centre, but if so, the

two are united. The glenoid cavity is ossified for three-fourths of its extent, and its hinder edge is fairly prominent. The bony nucleus is as broad as the odontoid process, and the costal angle is prominent.

Sections of the anterior arch before it ossifies show that while its lateral portions which abut on the articular mass are made of hyaline cartilage, there is a median region in which the cartilage is invaded by the fibrous tissue which surrounds it, so that although its central core remains cartilaginous, it is surrounded by an area of fibro-cartilage, shading off into the superficial layer of fibrous tissue. The cartilage cells are smaller in this central region than in the lateral mass. A large vessel traverses the cartilage at the level where the arch merges into the lateral mass. In one section ossification appears about to begin in the superficial fibro-cartilaginous area, nearer to the ventral than to the dorsal side of the arch. Sir G. Humphry[1] describes the embryonic anterior arch as fibrous, but this statement requires to be modified in view of the present observations.

In an infant's atlas (No. 56, from a child fifteen months old), there are two bony centres, of which the left is the larger. They are separated by a deep notch above, and by a vertical linear interval in front, but they have united posteriorly where they abut on the odontoid process. The posterior arch in this atlas is widely open, and the anterior limb of the arterial foramen is unossified, although the costal angle of the glenoid cavity is distinct. The twin centres in the arch measure transversely, the right 4 mm., the left 7.

In No. 19, from a child three years old, there is a stout conical costal spur from the lip of the glenoid cavity, connected to the transverse process by a short fibro-cartilaginous band. The posterior gap of the arch is 6 mm. long. The single nucleus in the anterior arch is in shape like a very oblate patella, 10 mm. wide by 4 in vertical depth. There is a trace of a central anterior tubercle, but no sign that the centre was ever double.

In No. 22, from a boy of three and a half years, the anterior nucleus is also single, widely heart-shaped, 12 mm. wide, with a distinct median tubercle. This centre exceeded the width of

[1] *Human Skeleton*, p. 132.

the partly cartilaginous and partly bony odontoid process. There is a longer costal spur than in the last, and the posterior arch is still open.

In No. 23, from an Egyptian girl of about the same age, or perhaps rather older, probably nearly four, there is a much smaller costal process, but the anterior arch-nucleus is larger, measuring 12 by 4 mm. This atlas is singularly round, the ring measuring 49 mm. coronally by 39 sagittally. The posterior arch is as yet unclosed, but the two laminæ are practically in contact.

In the atlas from a child four years old (No. 24), there is a distinctly bilobed bony nucleus in the anterior arch. This specimen resembles in character that figured by Sir G. Humphry,[1] but the two parts are more closely united than in his specimen: in my example the left portion is 5 mm. coronally, while the right is 10. These proportions are the reverse of those shown in his figure. The original duality of the nucleus is still evident when viewed from above or from behind, but the two parts have perfectly fused below and in front. The attachment of the transverse ligament was in the interval between the lateral mass and the anterior arch. The hinder arch is not yet closed. The front end of the lateral bony arch is much lobed where it lies in the cartilage of the articular mass, and the costal process is still unossified at its junction with the transverse process.

In No. 59, from a boy aged four years and a half, the posterior arch is still open, but the laminæ are in contact. There was a thin layer of cartilage over the spinous area, overlapping the contiguous ends. The anterior arch-nucleus is still divided on a level a little on one side of the median line, the right ossicle being 9 mm., the left 7 in coronal breadth. In this case the separation is most clear behind and below. The costal processes have stretched out in front of the artery, but are still unossified to the transverse processes.

No. 25, from a girl of about the same age, shows a large central nucleus in the anterior arch, extending across the median line, and with a well-marked anterior tubercle. To the left of this is a second small ossicle 3 mm. transversely, which forms the anterior end of the left glenoid cavity. The larger bone is

[1] *Loc. cit.*, plate viii. fig. 2.

15 mm. in transverse width. The hinder arches are in contact, but not coalescent. The whole of the facet for the odontoid process is on the larger bone.

The atlas of an Egyptian boy of about five years of age (No. 26) shows a single central bone in the anterior arch, 27 mm. long, joined by a thin plane of cartilage to the primary lateral ossifications. The posterior arch is closed, and the anterior tubercle is large, and bears below an impression for the upper end of the anterior common vertebral ligament. The tubercle of the transverse process is beginning to differentiate, and the arterial foramen is nearly closed.

A specimen of about the same age shows a similar condition of the anterior arch, and a closed posterior arch, but the costal process is much smaller, leaving the arterial foramen widely open in front.

In the atlas of a boy aged five (No. 28),[1] the arch has synostosed to the lateral mass on the left, but the synchondrosis is still open on the right. Here the costal process is only separated from the transverse process by a thin layer of cartilage, and the hinder arch is closed. In a girl of six years (29), the synostosis is complete on the left, and nearly so on the right, an island of cartilage only being left. The lines of junction are marked by nearly vertical ridges. The transverse foramen is closed. This specimen shows also a trace of an ecto-glenoid sulcus. The arch is quite consolidated in a boy aged seven (No. 30), but the lines marking the synostosis are distinct. The arterial foramen is closed, but there is an apical vertical groove on the transverse process which was filled by cartilage. The sutural ridge has almost disappeared in the atlas of an Egyptian boy aged ten, and excepting a few strong vertical bars in the cancellous tissue at the site of the union, there is no sign of the original separation of the parts visible in the section of the bone.

The central arch-element is always wider along its upper border than along its lower, and forms scarcely any part of the atlanto-axial articular surface.

After birth the growth of the atlas is rapid: at the end of the

[1] Figured by Humphry (*loc. cit.*, viii. fig. 3.) The specimen figured in the same plate, fig. 2, is not in the Cambridge Museum.

first year it averages 36 mm. by 20, at the end of the second 42 by 20, at the end of the third 45 by 26, at the end of the fourth 52 by 30, at the end of the sixth 60 by 30, at the end of the eighth 63 by 47. From this onward, growth is slower. The adult male atlas averages 74 by 45; the average adult female 70 by 42. The largest male atlas in our collection is 90 by 52, the smallest adult atlas is 61 by 36.

Terminal epiphyses at the extremity of the transverse processes are rare. I have two specimens showing these, one being the atlas of an Australian aged about eighteen.

The variable process to which I shall again refer, which projects from the hinder lip of the glenoid cavity and overlaps the vertebral artery, and for which I propose the name *post-glenoid process*, occasionally presents a separate centre. In one specimen (No. 60), from a boy aged nine, this appears as a wheat-grain-like nucleus measuring 6 mm. by 3, from whose hinder border the oblique ligament stretches to the post-arterial ridge on the lamina.

Text-books differ somewhat in their accounts of the development of this bone. Bichat describes five centres—one for the anterior arch, two for the posterior, and two for the lateral masses. Cloquet assents to this as occasionally true, but says that more frequently there are only three or four—one or two for the anterior arch, and two for the rest of the bone.

Meckel describes the anterior arch as arising by one or several nuclei, these uniting together before they join the lateral masses. He also describes a rounded posterior ossicle as occurring in the middle of the posterior arch. Humphry's account in general accords with that of Meckel, but he describes the anterior arch as sometimes formed by an ingrowth from the lateral masses, with no independent centre. The evidence for this is apparently derived from the appearances presented in some anomalies and will be discussed later, but no specimen has yet been described in which the formation of an anterior arch by such ingrowths has been seen in progress.

Humphry speaks of the soft parts of the posterior arch in the child as fibrous; it is really cartilaginous. The uniting material of the infantile costal and transverse processes he speaks of as fibrous or cartilaginous. It is usually fibrous for

the most part at its middle or thinnest portion, but with a cartilaginous core.

The other authors mainly follow Humphry. Gray speaks of the anterior arch as usually completed by ingrowth from the lateral centres, which he calls neural processes, but that occasionally a separate nucleus exists for it which joins the neural processes in front of the pedicles, or there may be two which join into one. Henle adds to this, that the bony arch of the atlas is the last in the series to close. Quain follows Meckel in giving the date of the closure as three years, and states that the union is frequently preceded by the formation of a distinct spinal nucleus.

From the study of my specimens I deduce—

1. That ossification begins early in the seventh week by two centres, one at the root of each hinder arch, and spreads rapidly backwards into the arch, more slowly forwards into the articular mass, and outwards into the transverse process.

2. About the middle of the first year ossification begins ectosteally in the anterior arch; most commonly by two unequal but closely-approximated centres, which speedily unite, sometimes within a few months of their appearance.

3. The posterior arch closes late in the fourth year. The median nucleus, described and figured by Meckel, must be an element of rare occurrence: in twenty cases in which I have sought it, I have found no trace of its existence.

4. The anterior arch synostoses to the lateral mass late in the fifth year. The line of junction is at first marked by a ridge, but this disappears in two years.

5. The limbs of the arterial foramen are variable in their dates of closure. The hinder and outer boundaries and the outer edge of the anterior boundary are ossified from the transverse process, only the anterior and inner part is costal. Closure usually takes place in the sixth year.

II. Anomalies.

A. *Of the anterior arch.*

a. The inter-glenoid interval in one specimen (48) was 11 mm., in another (49) was 27 mm. These differences are due to the extent of the encroachment of the articular facets on the arch,

not to any real shortening. The inferior inter-articular interval is also variable within about the same limits.

b. In vertical height this arch ranges from 8 mm. (No. 50) to 17 mm. (51). Its thickness also varies in the centre, owing to the varying size of the anterior tubercle. In No. 52 this is large, and projects 8 mm. in front of the arch. In 53 it projects downwards in front of the axis. This latter condition is due to the extension of ossification into the attachment of the anterior ligament. This condition is well marked in several of my specimens.

On the other hand, the tubercle may be, but very rarely, obsolete, and the arch diminished to 5 mm. in thickness as in No. 54. The form of this tubercle also somewhat varies, and rarely shows some tripartition, the median part being for ligamentous, the lateral for muscular attachment.

c. In a few specimens (35, 36, 61) there is an upward extension of the tubercle, ossification extending along the middle slip of the atlanto-occipital ligament.

d. Upward prolongations of the arch, independent of the tubercle, are common in old subjects. These are due to deeper ossifications in the structures resting on the odontoid process. In 58[1] there is a *processus articularis atlantis* like that described by Halbertsma. This is a hood-like ossification of the tissues above the articular facet for the odontoid process, over the top of which it arches. Similar but smaller processes exist in 85 and 86. In 108, in which the arch is asymmetrical, there is a tubercle directed upwards at the inner end of the right glenoid cavity, which must have touched the basi-occipital bone, as it is flat-topped.

e. The intervals between the round or oval facet for the odontoid process and the margins of the arch are variable, as are the lengths of the spaces between this cavity and the glenoid cavities on each side. When these facets approximate, they overlap the meridian of the edge of the glenoid cavity. This approximation is described by Testut, and is shown in two of my specimens.[2]

f. A median vertical division of the anterior arch is shown in Nos. 34 and 35. In the former there is a slight interval between

[1] From a long barrow, Stoke, Wilts.

[2] *Anatomie*, i. p. 76.

the two halves of the arch, which was probably filled by fibro-cartilage. This is a young bone, from a boy of about sixteen years. The hinder arch is closed, but had a median pit, also probably filled by cartilage, and the costal processes have not joined the transverse. There is a slight post-glenoid process on each side. This specimen resembles that figured by Humphry,[1] but his specimen is not in the Cambridge Museum.

Humphry is of opinion that in these cases there has been no nucleus in the anterior arch, and that ossification has taken place by an inward extension from the lateral mass. There is, however, in this specimen a faint mark on the left side as of the union of an arch centre. If this be so, the anomaly is due to a want of median union of twin centres.

In 34 the arches, anterior and posterior, are both medially open. The division in the anterior passes through the middle of the odontoid facet. This large atlas is from a male adult lunatic, and has a remarkably large canal, whose lumen is 38 mm. in sagittal diameter. It is worthy of note that in one example of this anomaly, described by Dapping, the boy was an epileptic, liable to violent spasms when his head was forcibly rotated. This specimen is in the Museum of the Infirmary at Frankenthal.[2]

Humphry describes another example of this anomaly as in the Museum of Guy's Hospital.[3] Allen records two instances,[4] and others are described by Grawitz.[5] Allen quotes Humphry as describing an instance in which one of the lateral synchondroses remained open to adult life. I can find no such case recorded by him. The reference probably is to specimen No. 29, in which one side had united before the other in a boy aged seven. The only case of persistence of these sutures known to me is the one quoted by Humphry as in the Musée Orfila, in which both of these sutures persisted to adult life.

[1] *Loc. cit.*, pl. viii. fig. 4.

[2] *Moleschott, Untersuchungen zur Naturlehre des Menschen u. d. Thiere*, 1857, iii. p. 122; *New Sydenham Society's Translation of Kussmaul and Tenner on Convulsions*, 1859, p. 108.

[3] *Loc. cit.*, 133. A second specimen, described by him as in the Cambridge Museum, was not there when I took charge of the anatomical specimens.

[4] *Jour. of Anat.*, xiv., pl. ii. figs. 7 and 9.

[5] *Virchow's Archiv*, lxxx. p. 463.

g. Absence of the whole anterior arch in the adult has been described in one unique example by Professor Dwight.[1] The arch here was replaced by ligaments which tied the lateral masses to the odontoid process.

In No. 34, as in Allen's cases, the relations of the vertebral arteries were normal. In Dapping's instance there was no trace of a sulcus for the vessel on the left side.

h. An articular facet on the middle of the upper edge of the arch, for a third occipital condyle, is shown in No. 127. In No. 62 there is a pressure-facet on one side of the median line, where this arch articulated with a projection, probably a third condyle projecting from one side of the basion.

B. *The posterior arch.*

a. Median deficiency is shown in Nos. 36, 37, and 38. In 36 the laminæ are asymmetrically directed towards each other, with an intervening gap 6 mm. wide. This was from an old person. In 37 the laminæ are also asymmetrical, the right being swollen at its end as in one of the instances figured by Gräwitz.[2] In 38 this coexists with large post-glenoid processes, which articulated with the exoccipitals. This condition is present in anencephalous fœtuses. Most commonly they exist in the form described in one adult by Allen, the whole arch being absent. In No. 16 the bony parts of the atlas consisted of a curved bar on each side, the arch being entirely open behind; the transverse process is slender, and there is a stumpy bony spur on the base of the rudimental lamina, just under the place where the vertebral artery should have been, but was not.

b. Lateral deficiency, as shown in 39, is not so common. In this the left lamina is perfect, and bears the posterior tubercle, extending across the middle line; but the right is a rudiment barely perceptible at the back of the right articular mass. A case of this kind is described by Luschka, who notes that in it the transverse process juts from the side of the articular mass on that side: a similar instance is described by Allen.

In commenting on a specimen in which this and the anomaly A*f* coexisted, and in which the costal processes and the anterior tubercle were nearly in the same straight line, Allen proposes

[1] *Jour. of Anat.*, xxi. [2] *Loc. cit.*, pl. xiii. fig. 4.

the hypothesis that the deficiency is due to disjunction, owing to the forcing of the wide parts of the condyles into the approximated front parts of the glenoid cavities by a strong extension of the head, as in face presentation. In my instances, the angles formed by these three points are respectively 124°, 130°, 135°, 137°, and 127°—sufficiently near to the normal to show the inapplicability of the hypothesis. I have not been able in a normal atlas to cause any gaping by forcible extension of the head when the posterior arch is carefully cut. It is also noteworthy that in my specimens Nos. 64 and 68, in which the three named point form angles of 162° and 170° with each other, the posterior arch is normal.

c. No. 40 has the lamina attenuated to a thread on the right of the posterior tubercle. In this case the anterior coronal angle is 135°.

d. No. 41, from a young subject, aged about thirteen years, has a median posterior depression, which was filled with cartilage; this condition was also seen in No. 35.

e. The posterior arch is often very slender, with no posterior tubercle, as in 42 and 112. In 43 there is a very slight tubercle, with a depression on each side of it. This arch is also very slender for its whole extent.

f. No. 65 has also a very slight median posterior tubercle, margined by a depression on each side, shown also in 43. In 66 there is a distinct spur projecting forward on the concave side of the arch in the median line, as well as on the posterior side.

g. The posterior tubercle is long, extended into a spine in No. 67. This is single, and 9 mm. long, resembling that figured by Allen. No. 69 has a shorter spinous process, but it is bifid at its extremity.

h. The posterior tubercle is upturned towards the occiput in No. 100. In 70, 82, and others, the whole lamina thickens gradually towards the middle line, rising towards the skull. Allen conjectures that this median thickening may be due to the presence of the hypothetical posterior nucleus, but there is no evidence of this, and traces of uprising are to be seen even where the arches are unclosed, as in Nos. 20 and 22.

i. In Nos. 71, 72, 94, and 105 there are pressure-facets for articulation with the hinder edge of the occipital foramen.

Cases of this kind have been recorded by Allen and others. In one instance of this kind noticed in the dissecting-room, I found a distinct synovial cavity in this articulation.

j. The arterial sulcus varies much in its distinctness and circumscription. The two extremes are shown in Nos. 99 and 100. In the first it is deep, narrow, with a sharp *post-arterial ridge;* in the second, as in 101, it is shallow and wide, the post-arterial ridge being placed close to the origin of the posterior rectus capitis muscle. The increased space in this case has been due to the increased size of the veins, which here formed a plexus around and behind the vertebral artery. This I have determined by injection in three other cases.

The convex margin of the posterior arch may be an even continuous curve from one transverse process to the other, as in No. 101; or, on the other hand, the arterial sulcus may be so flattened and widened that there is a distinct angle at the outer extremity of the post-arterial ridge, as in 102. In some of these cases the hinder edge from one arterial sulcus to the other is nearly transverse, as in 111 and 112. In these cases the arch is usually slender. When it is thick and rounded, as in No. 109, the laminæ generally join at an angle medially. In some, the laminæ join at a sharp angle with no curvature, as in 114.

C. *The post-glenoid process.*

The post-glenoid process is a variable tongue-shaped outgrowth from the hinder and outer lip of the glenoid cavity. When large its upper surface comes in contact with the jugular ridge of the occipital bone. This condition is shown in No. 91, in which there was a considerable area of occipital contact outside the capsule of the true condylo-glenoid joint. A post-glenoid process is present in 21 per cent. of atlases in some degree, and as we have already seen, may have ossified from an independent centre. From its hinder edge there is usually a fibrous band, the oblique ligament, separable from the rest of the posterior atlanto-occipital ligament, and continued backwards to the post-arterial ridge on the lamina. This is shown in Nos. 90 and others. In 7·5 per cent. of bones this ligament is ossified, and forms a bridge over the vertebral artery and the sub-occipital nerve. The bridge is chiefly formed by the extension of ossifica-

tion into the ligament from the post-glenoid end, as can be seen in 92 and 60, where it is incomplete behind; sometimes it grows from the laminar end, as in 93, but this is rare, although, on theoretic grounds, one would have expected this to be the normal arrangement, as there is little doubt of the general accuracy of Cleland's theory that the post-arterial ridge is morphologically identical in position with the superior oblique processes of the other vertebræ.

Ossification of the oblique ligament is bilateral in 3·4 per cent. of adult bones. It is single and right in 2·4 per cent., single and left in 1·7 per cent. When this ossification coexists with an occipital articulation of the post-glenoid process, it exactly reproduces the conditions of a superior oblique process comparable with that of other vertebræ. This condition is seen in No. 95. This is a comparatively young bone: as the synostotic vertical ridges of the anterior arch have not yet disappeared.

D. *The inferior articular process.*

Owing to the mechanical relations of the atlas to the axis, the inferior articular process cannot be represented in its typical form. There is occasionally a line crossing the under side of the lamina behind the level of the exit of the second cervical nerve, which indicates its position. At the outer extremity of this line, which approximately corresponds to the outer end of the post-arterial line, there is often a small *infra-laminar spur* jutting downwards, outwards, and a little forwards, which may end in a point, or else is continued to the back of the transverse process, thus forming the hinder boundary of a *posterior lateral foramen.* The former condition is shown in 102, the latter in 103. The size of the foramen is very variable, as is also the thickness of the bridging spicule, which may be single or double. A posterior lateral foramen is present in 10 per cent. of bones. In 2·5 per cent. it is on both sides, in 4·2 per cent. on the left, in 3·3 per cent. on the right. When the opening is small, I have found a minute vein passing through it. In 103 it transmitted a much larger vein and a small branch of the vertebral artery. In another specimen found in 1887 in the dissecting-room, it transmitted the occipitalis major nerve, which then turned downwards to wind round the lower

border of the obliquus inferior, thus resembling the instance described by Schwegel.[1]

E. *The superior articular cavity.*

This cavity on each side for the occipital condyle is so unlike the other vertebral articulations, that it cannot be considered as in series with them, hence I propose to call it the *glenoid cavity of the atlas.* It participates in the characteristic variability of the bone. Its surface may be completely divided into two, as in 109 and 110. This I have found in 3 per cent. on both sides; in 2·7 per cent. on one side, as in No. 87. Partial division by a notch on the inner side, as in 105, is very much more commonly present. This is a mechanical, not a morphological division. We have seen that there is a certain part of the glenoid cavity ossified from the anterior arch, but this does not correspond with the anterior portion of a divided glenoid cavity, than which it is much smaller.

In a normal glenoid cavity the curvatures of the fore and hinder portions are such that the cavity may be conceived as formed by the apposition and continuity of two concave surfaces —an anterior, whose surface looks upwards, backwards, and inwards; and a posterior, whose surface looks upwards and inwards, often a little forwards as well. In these cases of division the interval is a non-articular area across the line of union of these two surfaces.

On the outer side of the glenoid cavity there is in 18 per cent. of atlases an *ecto-glenoid groove* for the attachment of the capsular ligament (as in 84). In some cases the articular lip of the glenoid cavity is bevelled towards this (as in 55 and 108), giving an additional surface for contact with the occiput. Internal to the glenoid cavity, and behind the tubercle for the transverse ligament, there is an *ento-glenoid fossa*, filled in the recent state by a minute Haversian body, enclosed in a loose villous fold of synovial membrane. This pit is sometimes very deep, and its fundus is bored with fine holes, through which diploic veins escape. Indeed this area, and the outer surface of the lateral mass towards the arterial foramen, are the two chief regions in which vessels enter and leave the bone. The Haversian

[1] *Zeitschrift für rationelle Medicin*, 3 Reihe, v. 311.

body is pressed backwards in flexion of the head, forwards in extension. The hinder limit of this ento-glenoid fossa is a strong ridge of very solid bone, which descends from the hinder extremity of the glenoid cavity to the innermost part of the inferior articular surface.

The curvatures of the glenoid cavities are very variable. Sometimes the anterior part has its aspect directed backwards and very little upwards, giving rise to a very deep cavity, as in 119; in others, as 114, the plane is very nearly horizontal. The curve of the hinder portion is much less variable than is that of the anterior.

The anterior extremities of the glenoid cavities in 100 atlases present the following varieties in the lengths of their intervals:—In 1 it was 10 mm.; in 2, 12 mm.: in 4, 14 mm.; in 9, 15 mm.; in 9, 16 mm.; in 10, 17 mm.; in 18, 18 mm.; in 10, 19 mm.; in 9, 20 mm.; in 9, 21 mm.; in 6, 22 mm.; in 5, 23 mm.; in 5, 24 mm.; in 2, 25 mm.; and in 1, 26 mm.

The intervals between the posterior extremities of these cavities, measured between their mid-points, are also subject to variation, and these are more erratic than those of the anterior, owing to the difficulty of discounting the post-glenoid processes. These distances are—

31 mm. in 1	35 mm. in 15	39 mm. in 7	43 mm. in 2
32 „ 2	36 „ 8	40 „ 13	44 „ 4
33 „ 3	37 „ 9	41 „ 7	48 „ 3
34 „ 2	38 „ 13	42 „ 9	50 „ 2

The axes of the glenoid cavities, measured from the foremost and inmost point to the middle of the hinder edge of the articular cavities, met when prolonged anteriorly at angles, which varied as follows:—

32° ... 1	42° ... 4	52° ... 3	60° ... 2
35° ... 2	45° ... 9	55° ... 3	62° ... 1
38° ... 4	47° ... 6	56° ... 5	63° ... 1
40° ... 3	50° ... 5	58° ... 2	

In those atlases whose hinder arches were unconsolidated, these angles were large—63°, 56°, and 53°. In No. 34, open in front and behind, the angle was the largest in the series—70°.

F. *The arterial foramen.*

This foramen remains open on both sides in ·2 per cent. of atlases; on one side in 1·6 per cent. This is due to the deficient development of the costal process. In 44 the vascular space is wide and the costal process small; in 45 the left is widely open, the right nearly closed; in 47 the right is closed, while the left is open; in 46 the left has closed, but the right is open, as it is also in 102 and 77.

Luschka, in speaking of this anomaly, states that one or other of the bony limbs of the transverse process may be absent or imperfect; but I have never seen any case in which the transverse process portion was unequivocally absent. In No. 147, which shows this condition, I suspect that the process, whose surviving piers are thread-like, was broken in cleaning the bone. In general, the transverse element is of much more compact bone than the costal, which, though often large, is usually soft and cancellous. The transverse process being ossified from the posterior and the terminal extremity, could scarcely have, under any condition, a primary attachment to the costal element, even though in some, as in No. 87, the costal portion may be double the thickness of the transverse process. In some, as 80 and 81, the root of the transverse process is reduced to a very slender narrow plate. In size the hole varies within wide limits.

G. *The transverse process.*

Genuine bifidity of the lateral process, comparable with that of the other vertebræ, is very rare. In No. 78 the true transverse process projects nearly horizontally from its root, its extremity being on a plane behind the foramen. The tip of the costal process here makes a small anterior projection, corresponding to its homologue in the lower vertebræ.

Spurious bifidity, involving only the transverse process element, is exemplified in 77 and 79, resembling the specimen figured by Allen. In No. 117 the end of the transverse process is 16 mm. wide. In these cases it is obvious that the anterior inferior tubercle has nothing costal in its nature.

H. *Gleno-transverse bony arch.*

In Nos. 82 and 83 a bony arch, from the posterior superior tubercle of the transverse process, stretches to the outer border

of the glenoid cavity, bridging the gap through which the anterior division of the sub-occipital nerve passes forwards between this arch and the costal process. This reproduces the condition seen in the ungulate atlas. I have occasionally found a slender fibrous cord (the *gleno-transverse ligament*) in this position where there was no such ossification, as in No. 146. In Nos. 61 and 84 only the outer end of this is ossified. In 87 the glenoid end is bony, and this process represents a variety of the post-glenoid process. The edge of this gleno-transverse bridge, like that of the ossified oblique ligament, occasionally presents a groove for some of the overlying veins of the sub-occipital plexus.

There is often a rough cavity on the back of the upper and outer tubercle, to which the obliquus inferior is attached, and from the tuberous end external to this the obliquus superior arises. The margin of this extremity is sometimes prolonged into a spur, as in No. 88.

Coexistence of ossification of the gleno-transverse ligament and of the oblique ligament are not common. This condition is shown in No. 83 on the right side. In 82 the former is ossified on the right, and the latter on the left. In 94 the two ossified ligaments start from the back of a post-glenoid process, from which the oblique runs backwards and the gleno-transverse forwards. In No. 64 the three bridges coexist—oblique, gleno-transverse, and posterior lateral. In this case the anterior branch of the sub-occipital nerve escapes under the first, the posterior under the second bridge.

III. Assimilation or Abnormal Attachment of the Atlas to the Base of the Skull.

A. *Atlanto-occipital fusion.*

Congenital fusion of the fœtal cartilage of the atlas to that of the occipital region. This has been described by Solger.[1] The specimen of this in the Cambridge Museum is one which was the subject of a meningocele. This condition is excessively rare, as even in cases of anencephalia the bones and

[1] "Ueber abnorme Verschmelzung knorpeliger Skelettheile beim Fötus," *Centralblatt f. allgemeine Pathologie u. patholog. Anatomie*, 1890, p. 124.

cartilages of the occiput and atlas are usually distinct, even though those of the other cervical vertebræ may be fused (as in the specimen No. 2013 in our Pathological Museum).

B. The whole ring of the atlas may become inseparably united to the edge of the foramen magnum. An instance of this form is recorded by Schiffner.[1] In this case only half the skull is preserved, and the transverse process alone is free. The bony union is remarkably perfect, as shown in the figures of pl. x.

In one Cambridge specimen which is comparable with this (*Path.*, 1893) there is perfect fusion of the right side of the anterior arch, of the articular processes, of the true transverse process, and of the posterior arch with the contiguous part of the occipital bone, so that were this only a half specimen, fusion would be as complete as in Schiffner's case; indeed, the transverse process and the paroccipital are so far blended into a single process that it juts down from the skull and apparently touched the transverse process of the axis, for which it has a facet. The costal process of the right side alone is free and unattached to the transverse. The costal process on the left side is rudimentary. There had been a vertebral artery on the left side, but none on the right; and there can have been no sub-occipital nerve on this side.

C. The articular process and posterior arch, or part of it, may be fused with the contiguous parts of the occiput, while the central part of the anterior arch is separated from the basi-occipital by a small interspace. There is an example of this in the Cambridge Museum (No. 125), from the Romano-British cemetery at Hampden Hill, Somerset.

In this specimen the anterior arch is complete, but has an immature appearance, being swollen in the centre, but slender on each side where it joins the lateral mass. The facet for the odontoid process is very small; but that process ascended behind the arch and on each side abuts on a projecting process from the inner border of the occipital condyle, the ossified lateral occipito-odontoid ligaments. These processes present flat articular faces where they touched the odontoid. These surfaces are so directed as to converge upwards and forwards, but they do not unite. Posteriorly each of these occipito-odontoid

[1] *Virchow's Archiv*, lxxiv. p. 320, 1878.

process continues backwards as a ridge which extends to the inner and posterior border of the inferior articular facet, in front of the place of exit of the second cervical nerve. The interval between the anterior arch and the basi-occipital is a narrow transverse slit. The condyles of the occipital bone and the superior articular processes are perfectly united, and the anterior condylar foramen for the hypoglossal nerve appears between the front border of the atlantic border and the edge of the jugular process.

The arterial canal on the right side is open, as the costal process ends in a slight knob, which articulates with the paroccipital process. Between this costal process and the paroccipital there is a canal for the passage of the anterior branch of the sub-occipital nerve. The true transverse process articulates by its extremity with the exoccipital behind the jugular foramen, but the canal for the vertebral artery intervenes, and passes, as usual, behind the ankylosed condyle, opening by a distinct round hole internally, like that figured in Schiffner's plate.[1]

The posterior arch is complete, and ankylosed to the hinder lip of the foramen magnum. There is a posterior condylar foramen on each side, and a second venous foramen through the bony junction between the contiguous lips.

On the left there is no interruption in the fusion of the posterior arch and the occipital bone. The posterior element of the transverse process is on this side ankylosed with the occipital behind the paroccipital process, and stretches out to impinge on the paramastoid of the temporal by a convex surface. There is a paracondylar canal[2] from the posterior condylar foramen forward. The vertebral artery on this side must have been small, and must have ended here, as there is no continuation of the canal between the atlantic lamina and the occipital bone, and no perforation. The left sub-occipital nerve, if present, must have come out with the 2nd cervical, unless it escaped through the posterior condylar foramen. The costal process is slender, and its extremity is joined to the transverse process by a very fine bony spicule.

[1] "Ueber die Architectur des Schädelgrunds in der Norm, und bei Assimilation des Atlas," *Virchow's Archiv*, lxxiv., 1878, pl. x. fig. 2.

[2] Grünbaum, *Jour. of Anat.*, vol. xx., 1892.

The skull belonged to a young male adult, about 20. The basilar suture is unclosed, but the wisdom-teeth are newly cut, and the molars are very slightly worn.

In many respects this resembles one of the three instances recorded by Boxhammer,[1] in which condylar fusion had occurred in the skull of an adolescent aged 17. There was a round atlanto-occipital opening above the anterior arch in this case, and the left transverse process was free, while the right was ankylosed to the skull. In a similar case, described by Luschka,[2] the upper edge of the anterior arch was also adherent, but the posterior arch was only present for its left half, which was fused to the occipital bone, while the right half was quite undeveloped behind the level of the sinus atlantis. In this case the articular fusion was not complete on the left side.

A corresponding want of development was present in the case described by Sommer.[3] In this instance the atlas was rudimental; the posterior arch only represented by its roots behind the articular mass.

In one of the specimens from the Berlin Museum, figured by Grawitz,[4] the posterior arch is fused as in the Cambridge instance, but the transverse process seems free (No. 10,605). In another example, from a young child, the posterior arch is completed by a fibrous cord. In another, as in Luschka's case, the posterior arch was ununited behind, but the two laminæ were both developed. In a fourth example the posterior arch is adherent, but the anterior arch is medially interrupted.

The specimen described by Langerhans,[5] from a boy five years of age, was interesting, as one of very early union. The posterior arch had ankylosed to the edges of the foramen magnum on the left side, while yet the synchondrosis between the anterior arch and the lateral portion was unossified.

D. The articular processes may be ankylosed to the occipital

[1] "Die angebornen Synostosen den Enden der beweglichen Wirbelsäule," *Zeitschrift für rationelle Medicin*, iii. Reihe, Bd. 15, p. 1.

[2] *Anatomie*, i. 36.

[3] "Zur casuistik der Atlas synostosen," *Virchow's Archiv*, xciv. p. 1.

[4] "Beitrag zur Lehre von der basilaren Impression des Schädels," *Virchow's Archiv*, lxxx. p. 463.

[5] *Virchow's Archiv*, cxxi., 1890, p. 373.

condyles while the arches and transverse processes are free. This, the commonest condition, is an acquired pathological condition due to osteitic or arthritic inflammation. An example occurs in our Museum, in which there is also atlanto-axial ankylosis (*Path.*, 1894), and a rudimentary left costal process. In another specimen (No. 126), the skull of an ancient Peruvian from Cerro del Oro, this ankylosis is complete. There is a wide atlanto-occipital gap anteriorly, and the four condylar foramina are normal. The oblique and check ligaments were unossified, and the paroccipital processes are small. There are a few bony spicules around the ankylosed surfaces, but few other traces of disease. The upper edge of the posterior arch is thick and upturned, extending towards the wide foramen magnum. The whole atlas appears to have slipped a little forward, so that the anterior arch appears in norma basilaris to lie on a plane in front of the anterior lip of the foramen, and the plane of the foramen magnum extends behind the prominent posterior tubercle of the atlas. This skull was that of a middle-aged man.

Cases of this kind are far from rare. Lombroso records finding such ankyloses in 0·84 per cent. of the skulls in the Beinhaus at the battlefield of Solferino, and Legge found 5 cases out of 780 in a graveyard at the city of Camerino.[1] Lombroso also records finding this condition in 4 out of 51 criminal skulls, while De Paoli found it in 2 out of 4 criminals. In our Cambridge collection the percentage is 0·14.

Other cases of ankylosis are recorded by Casprzig;[2] Serger;[3] Sommer[4] gives three cases, including the one described by Casprzig, in the Museum of the Allenberg Asylum. There are also older cases, one described by Gurlt, referred to by Realde Columbus,[5] and another described by Morgagni.[6]

This, the first case recorded in detail, was noticed in the autopsy of a stiff-necked Paduan.

Ankylosis is also described by Schwegel (*Zeitschrift für rationelle Medecin*, xi. p. 290); Solberg (*Allgemeine Zeitschr. für Psychiatrie*, 1867, xxiv. p. 1); Bogstra and Boogaard (*De Schedel met ingedrukte Basis*, Akad. Proefschrift, Leiden, 1864, and *Nederlandsch Tijdschrift voor Geneeskunde*, Amst., 1865, 2de Reeks, i. 91). See also Virchow,

[1] *Archivio di Psichiatria*, 1883, iv. p. 384.
[2] Inaugural Dissertation, Greifswald, 1874.
[3] Inaugural Dissertation, Halle, 1888.
[4] *Virchow's Archiv*, lxxxix. p. 423, and *ibid.*, 119, p. 362.
[5] *De re Anatomica*, i. 15.
[6] De hedibus ca Morborum Epist. 79.

"*Beiträgen zur physischen Anthropologie der Deutschen*" *Berlin Akad.*, 1876, p. 340.

E. Another method whereby fixity of the atlas to the skull may be produced is by the attachment of the transverse process to the jugular process of the occipital bone. This may take place in one of three ways:—

1. By the meeting of a down-growing paroccipital process of the skull, with an up-growing spur from the atlas: a case of this kind is described by Allen (*Journal of Anatomy*, vol. xiv.). In this instance the processes had ankylosed at their place of meeting. In my specimen No. 74 the two portions are separate.

2. The processus paroccipitalis may be a down-growing column from the occiput, starting close to the outer edge of the exoccipital next to the occipito-mastoid suture, and touching the upper surface of the transverse process of the atlas, which is not raised to meet it, either articulating with it by a flat surface or ankylosed to it.

In the skull of an Egyptian (No. 127), this paroccipital process is a thick styliform column, 20 mm. long by 11 mm. thick, which ends in a flat facet that articulates with a similar facet on the transverse process of the atlas.

A similar process, 24 × 13 mm. in length, is shown in another specimen (occip. No. 16), from an English skull, and there are several paroccipital processes of lesser size in our Museum.

Examples of this mode of union are figured by Sandifort (*Mus. Anat.*, II. xiv. 31, and *Exercitationes Academiæ*, i. p. 10); Meckel ("*de Duplicitate Monstrosa*," *Archiv f. Physiol.* i. p. 644, pl. vi. fig. 37; also *Anat. u Physiol. Beobachtungen und Untersuchungen*, p. 178); Tesmer (*Rudolphi, Obs. Osteolog., Berlin*, 1812); Knape (*Schupte, de luxatione spontanea atlantis et epistrophei, Berol.*, 1816.

3. The up-growth of a styliform process in the form of a pillar-like elongation form the posterior superior angle of the transverse process of the atlas, to articulate or to ankylose with a normal paroccipital process, is a third method of union.

Examples of this are shown in specimens Nos. 73 and 74 in our Museum, and cases are recorded by Leveling (*Observ. Anat. rar.*, p. 134, pl. v. fig. 1), by Sandifort (*loc. cit.*, fig. 3), and by Allen (*loc. cit.*, p. 5, pl. ii. fig. 2).

These cases are due to ossification in the ligamentous apparatus between the transverse process and the jugular pro-

cess, and are extensions outwards of the ossification which forms the gleno-transverse bridge, with which they may be continuous. In No. 60 the pillar from the transverse process turns inwards towards, but does not quite touch the outer edge of the glenoid cavity.

Atlanto-axial ankylosis and ossifications in the transverse ligament shown in several specimens in our Museum, such as 1896 (*Path.*), are always the results of disease.

ON THE MAMMALIAN PELVIS, WITH ESPECIAL REFERENCE TO THE YOUNG OF *ORNITHORHYNCHUS ANATINUS*. By G. B. HOWES, F.L.S., F.Z.S., *Assistant Professor of Zoology, Royal College of Science, South Kensington.*[1] (PLATE XXVIII.)

THE facts contained in this communication have come to hand during a recent inquiry into the general morphology of the mammalian pelvis, necessitated by other work on hand; and it is a little remarkable that those among them which involve the adult anatomy of the Monotremes and Insectivora should not have been hitherto recorded. Such, however, is apparently the case, as I find no mention of them either in the classical treatises of Pander and D'Alton,[2] Meckel,[3] Owen,[4] de Blainville,[5] Gervais,[6] and others, or in the most recent ones of Coues,[7] Mivart,[8] Dobson,[9] Leche,[10] and Brühl;[11] to say nothing of less special ones, of text-books, and other encyclopedia articles.

I. THE SACRUM.

The sacrum of Ornithorhynchus is everywhere stated to consist of two vertebræ; but, so far as I am aware, the simple fact that there is about it a character of an order altogether unique among mammals has escaped notice. I refer to the presence of a wide

[1] Read before the Anatomical Society of Great Britain and Ireland, May 23, 1893.

[2] "Vergleichd. Osteologie," *Die Skelete d. Zahnlosen Thiere*, Bonn, 1825.

[3] *Beiträge z. vergl. Anat.*, Bd. i. Hf. ii. p. 64, 1809; and *Ornithorhynchi paradoxi descriptio anatomica*, Lipsiæ, 1826.

[4] Art. "Monotremata," *Todd's Cyclopedia of Anat. and Phys.*, vol. iii. p. 366, 1839–1847.

[5] *Ostéographie d. Mammifères*, Paris, 1839–64.

[6] *Ostéographie d. Monotremes vivants et fossiles*, Paris, 1877–78.

[7] *Proc. Essex Institute*, vol. vi. p. 127, 1871.

[8] Papers on the Osteology of the Insectivora, This *Journal*, vol. i. p. 281; vol. ii. p. 117; and *P. Z. S.*, 1871, p. 58.

[9] *A Monograph of the Insectivora*, London, 1883.

[10] "Zur Anat. der Beckenregion bei Insectivora," *Kgl. Svenska Vet.-Akad. Handl.* (Stockholm), Bd. xx. No. 4, pp. 1–106.

[11] *Zootomie aller Thierklassen*, Bd. i. Lf. 1–10, Wien, 1877.

passage, bounded above and below by the outstanding processes of the first sacral vertebra, and externally by the ilium, which (fig. 1, *ar.*) I propose to term the *sacral arcade*. On examination of the adult pelvis, the constituent parts of the sacrum being fully co-ossified and the heads of the expanded ilia well-nigh immovably ankylosed with them, the conditions forcibly recall those familiar in the neck of the Echidna and those Sauropsida in which the vestigial cervical ribs remain distinct and bound the vertebrarterial canal ventro-externally; and they suggest that of the two outstanding processes the upper one might alone represent the transverse process, and the lower the sacral rib, as ordinarily understood. One outcome of this comparison, if substantiated, would necessarily be the association of the sacral arcade of Ornithorhynchus with the vertebrarterial canal and the interspace between the head of the thoracic rib and its related vertebræ—a welcome addition to the series of structural resemblances between the cervical and sacral vertebræ first clearly appreciated by Gegenbaur and Frenkel.[1]

With the foregoing thoughts in my mind, I eagerly availed myself of the kindness of my friends Professors W. N. Parker and Charles Stewart, to whom I stand indebted for the loan of young Duck-Bills. Professor Parker's specimen (of approximately 220 mm. total length) is that from the head of which calcified teeth were first described,[2] and Professor Stewart's (a male of 316 mm.) is that in which he discovered[3] the third tooth of the mandibular series, and which has yielded him the exquisite preparations which adorn the shelves of the Royal College of Surgeons Museum. To these gentlemen I tender my sincere thanks.

The sacrum of the younger specimen showed no trace of distinct ossification to form a pleurosteal or rib-like element; the corresponding area (* of fig. 3) was of small extent, and entirely cartilaginous. On turning to the older specimen, I failed to find definite traces of the desired rib, as the component parts were fully formed and co-ossified (fig. 2). A

[1] *Cf. Frenkel, Jenaische Zeitschr.*, Bd. vii. p. 391.

[2] Poulton, *Qu. Jour. Micr. Sci.*, vol. xxix. (N.S.) p. 9. I have already been accorded the privilege of describing its shoulder-girdle and sternum (This *Journal*, vol. xxi. p. 196).

[3] *Qu. Jour. Micr. Sci.*, vol. xxxiii. (N.S.) p. 229.

possible indication of the existence of a sacral rib was, however, forthcoming on the under surface of the first sacral vertebra, in the form of an apparent demarcation-line extending through half its length, postero-anteriorly, suggesting that the sacral rib (which, if present, must have had a comparatively short duration as an independent element) lay caudad of the transverse process, instead of in superposition beneath it. Such a condition is approximately represented in Man himself,[1] and I find it so marked in a young Peba Armadillo (*Tatusia novemcincta*, fig. 11), that the transverse process (*tr*.i.) and rib (*r.s*.i.), when viewed *in situ* from beneath, are seen to lie in almost the same horizontal plane, and to occupy wellnigh corresponding areas. On comparison of other mammals, I am convinced that this will be found to be a by no means uncommon disposition throughout the class.

Further examination of the younger specimen showed that the neurosteal centres (fig. 3, *a.n.*) had already encroached upon the supposed pleurosteal or rib-forming areas, and that they had already enclosed the sacral arcades below. With this, the conception of structural repetition between the sacral and cervico-thoracic segments appeared to break down; but the fact that in some mammals the cervical transverse process completely encloses the vertebrarterial canal, as has been so definitely proved by Albrecht for the Hippopotamus,[2] shows that up to this point the sacral and cervical vertebræ may be modified in common.

Proceeding now to the more detailed consideration of the Ornithorhynchus' sacrum, it will be observed that that portion of the transverse process of its first vertebra which immediately bounds the sacral arcade below (fig. 3) is the serial homologue of the sacral transverse process as ordinarily described in the young mammal before ankylosis, and that the special conditions met

[1] *Cf.* Frenkel, *loc. cit.*, pl. xxi. fig. 2.

[2] *Bull. Mus. Roy. Hist. Nat.*, Belg., T. i. p. 2, 1882. Sir W. Turner has directed my attention to his having described (This *Journal*, vol. xvii. p. 255, xviii. p. 223) a first thoracic vertebra (homo) with a perforated pedicle. His conclusion, that the perforation "cannot be regarded as homologous with the vertebrarterial foramen in a cervical vertebra," is perfectly sound so far as Man is concerned; but comparison may, nevertheless, be instituted between the thoracic vertebra in question and a cervical one of the type figured by Albrecht.

with in this animal are due to an overgrowth of the region adjacent to the pre-zygapophysis (*zy.*, figs. 1–2), *i.e.* to the complete development of a sacral metapophysis.[1] It is thus clear that the sacral arcade can have nothing to do with the vertebrarterial canal; and that notwithstanding my failure to definitely detect the presence of a sacral rib in Ornithorhynchus, the (first) sacral vertebra of that animal brings that of the more familiar mammals, in which the metapophysis is at best but feebly developed, into a closer structural relationship with the lumbar vertebra in its most highly differentiated form. It therein lends welcome testimony to the belief in the structural uniformity of the segments of the mammalian vertebral column; and it remains now to determine the rationale of its structural peculiarity, and to inquire whether the Monotreme stands alone in having realised that.

Comparison of figs. 3, 2, and 1, which, in the order enumerated, represent stages in the growth of the Ornithorhynchus' sacrum, shows that the full extension of the sacral metapophysis (*mp.*) is acquired late. The connection between it and the crista ilii is first established after the full differentiation of the ordinary iliac articulation: with advancing age it increases, at first in a degree proportionate to the growth and lateral extension of the head of the ilium (*il'*), until in old individuals (ex. fig. 1) its area of attachment falls little short of

[1] The elongation, and in many instances the first indication, of the mammalian metapophysis is unmistakably to be associated with the reduction of the tubercle of the rib. It arises by a *partial* subdivision of the transverse process, which becomes completed in a degree proportionate to the greater reduction of the structure named; it is thus an ascending product of division of the transverse process, and it is either absent or rudimentary except where the rib is either partially or wholly suppressed. The application to it of the term "metapophysis," with the accompanying restriction of the term "transverse process" to the corresponding descending product of the division, is misleading, as it conveys the impression that the two outgrowths are, *sui generis*, distinct. As a teacher, I have long felt the difficulty arising out of this confusion, and I would propose to restrict the term "transverse process" to the undivided form of that structure. In its divided condition it might be termed a *bitransverse process*, its metapophysis the *processus ascendens*, and its lower cornu (the so-called transverse process of current terminology) the *processus descendens* (for, although this does not always descend obliquely among the muscles, its point of origin from the arch does so in proportion as the tail is reached). The anapophysis, on account of its great variability and frequent absence, might be termed the *processus accessorius*.

that of the articulation named. On laying bare the sacral arcade from the side, this is seen to stand in definite relationship to the flexor caudæ muscle. The most recent description of the latter is that of Coues, who defines its head[1] as "the uninterrupted prolongation of the longissimus . . . filling the deep groove between the ilium and vertebral spines," and I know of no one more detailed.

If, however, the ilium be removed, care being taken to leave the main mass of the muscle in question which arises from that bone (fig. 4, *l.cd''.*), *in situ*, it will be seen that the sacral arcade lodges a couple of slips which contribute to its formation, viz., an outer one which passes through the arcade and blends with the periosteum cephalad of it, and a smaller inner one, which arises within its area (*l.cd'''.*). Whether this definite interruption in the series of the dorsal episkeletal muscles is anything but an effect of the osteological peculiarity under consideration, further inquiry in comparative morphology must show; judged, however, from the standpoint furnished by the facts before us, the latter would appear to be a cenogenetic character, such as might well be independently acquired in distinct orders of mammals, if in no other higher amniota.

In the pursuit of this line of the inquiry, one naturally turns first to the Echidna. The sacrum of that animal is usually said to consist of three vertebræ, all of which enter into the iliac articulation, but Brühl has figured and described[2] an example possessed of four such elements.

[1] *Loc. cit.*, p. 134.

[2] *Loc. cit.*, pl. xvii. figs. 14, 16, and 19, and accompanying description. He regards the supernumerary vertebra as a derivative of the caudal series, apparently for the sole reason that 11 free caudals are present instead of 12, as is most usual. Owen accorded the genus 13 caudal vertebræ (*loc. cit.*, p. 375). I append the vertebral formulæ of two exceptional specimens (β, γ) which have come under my notice, each possessed of a sacrum of four vertebræ.

	Cv.	Th.	Lb.	Sc.	Cd.
α. Ordinary, . .	7	16	3	3	12
β. Exceptional, . .	7	16	2	4	11
γ. ,, . .	7	15	3	4	11

It will be observed that in both cases the number of pre-caudal vertebræ is that of the less aberrant individual (γ), viz., 29, and that notwithstanding that but 11 caudals are present. That the extra sacral vertebra is in each case beyond doubt derivative of the lumbar series is proved, by the fact that its metapophyses are remote from the ilia and erect; and it is instructive to note that in one

The first sacral vertebra of Echidna is somewhat exceptional among that of the Mammalia generally for the great depth of its transverse process and the direct apposition of its metapophysial border with the crista ilii; indeed, the relationships which the vertebra bears to the hip-girdle are such as would result in Ornithorhynchus from the occlusion of the sacral arcade. The metapophyses of the two succeeding vertebræ (which in Ornithorhynchus are remote from the ilia, and in no way specially modified) are markedly expanded antero-posteriorly, and so modified that they, one or both, abut against the dorso-internal iliac border, inclosing a shallow depression within which the levator caudæ muscle in part arises; and this peculiarity appears to become more marked with age, as is definitely the case with that which I have described for the first sacral of Ornithorhynchus. These characters may be associated with the backwardly rotated condition of the hip-girdle in this animal, but they are such as would result from a backward extension of the peculiarities of the first sacral vertebra of Ornithorhynchus, with accompanying occlusion of the sacral arcade in front. On these grounds, it seems to me by no means unlikely that in Orni-

example (γ) a corresponding numerical reduction of the thoracics has been effected. These facts point very strongly to the conclusion that the caudal vertebræ of Echidna are, like those of most average tailed mammals, variable in number in different individuals. In consideration of this, and on comparison of Brühl's drawings with the specimens formulated above, there seems to me little doubt that his extra sacral vertebra is in reality a modified lumbar one.

The advisability of distinguishing between vertebræ which ordinarily constitute a given region of the vertebral column, and others which, while they do not belong to it morphologically, are occasionally and secondarily drawn into it, appears to me highly desirable; and it cannot be better done than by a combination of terms, such as Mivart has employed in deciphering the complexities of the avian backbone (*Trans. Zool. Soc.*, vol. x. pp. 1–52). Assuming that Brühl's observation is correct, the differences between his specimen and my own (γ) might, for example, be expressed as follows:—

Brühl, . .		Sc. 3.	Sc. Cd. 1.	Cd. 11	−15.
Howes, . .	Lb. Sc. 1.	Sc. 3.		Cd. 11	

On examination of the skeleton of *Proechidna Bruijnii* in the Natural History Museum, I find the vertebral formula to be Cv. 7, Th. 16, Lb. 4, Sc. 4, Thomas gives Th. 17, Lb. 4, Sc. 3 (*Brit. Mus. Cat.*, "Marsupialia and Monotremata," p. 383). The numerical increase of the thoraco-lumbar vertebræ in this animal is of interest, as it nullifies the familiar statement that "the monotremata agree with the marsupialia in the total number of trunk vertebræ," and furnishes a powerful argument for the retention of the genus (*cf.* Thomas, *op. cit.*).

thorhynchus we may be dealing with a condition of the sacrum through which the Echidnidæ have passed. I have been unable to find traces of the ornithorhynchoid type of sacrum in any marsupial, but my search among the Placentalia has been rewarded with the following success:—In Hippopotamus and the New Zealand Fur Seal (*Arctocephalus cinereus*) there is a kindred overgrowth of the pre-zygapophysis of the first sacral vertebra, but no complete arcade formation. In the Pichey (*Dasypus minutus*) and the Tanrec (*Centetes ecaudatus*) a complete arcade may exist. In the skeleton of the latter in my own teaching collection ([1]) (fig. 8) a sacral metapophysis almost as massive as that of all but old individuals of Ornithorhynchus is present; and the chief difference between the two animals lies in the greater growth forwards of this process in the placental form, whereby it has come to lie in front of the processus descendens instead of immediately above it.

Comparison of my own specimen of *Dasypus minutus* with that in the Natural History Museum has shown that the sacral metapophysis is in this creature less symmetrical than that of the animals afore dealt with. The conditions suggest that it may be here a product of ossification of the ilio-sacral ligament, which is certainly not the case in Ornithorhynchus at least (*cf.* fig. 3); and they consequently raise the question if the overgrowth to enclose the sacral arcade is in all cases homologous.

In working out from this standpoint, I have succeeded in detecting an arcade in two other placentalia, viz., the Hedgehog and Piping Hare (*Lagomys microtis*). In the former it may be either completely enclosed in bone on both sides, or ligamentous on one only, as in fig. 9. In the specimen of the latter in my possession, I find it (fig. 10) to be still more remarkably asymmetrical; for while on the left side it is roofed in by mutual apposition of the sacral metapophysis, with the iliac epiphysis (*il″.*), on the right it involves the latter and the post-zygapophysis of the last lumbar vertebra.

On examining the Centetes skeletons in the Natural History Museum, I find that a sacral arcade is present in but two of the

[1] In this specimen, but two of the three sacral vertebræ furnish the iliac articulation, in contradistinction to Leche's, in which all three do so (*cf.* Leche, *loc. cit.*, p. 12).

four which my friend Mr Oldfield Thomas has kindly placed at my disposal. Its absence is due, in one case, to the sacral metapophysis having outrun the head of the ilium in its growth forwards, and in the other (a young individual) to a non-elongation of the metapophysis, which, at the same time, seems to indicate that the outward extension of that in this animal, as in Ornithorhynchus (*ante*, p. 546), is acquired late.

The foregoing facts testify to the independent development of a sacral arcade in four great orders of Mammalia, and to a tendency towards its formation among remotely related members of the class. Although its boundary-walls are not strictly homologous in all cases, its existence furnishes us with a distinct type of sacrum, for the adequate expression of which a term may be conveniently employed. I would suggest that of *supersacrum*, the presence of a sacral arcade being its chief character, as distinguished from the simple *sacrum*, in which that passage is undeveloped.

In Ornithorhynchus at least, the structural change undergone in the formation of the supersacrum is most nearly comparable to that hitherto recognised only in birds[1] and certain Dinosauria.[2]

II. The Pelvic Girdle.

The older conception of the mammalian pelvis has been much modified in recent years by the study of the cotyloid bone, or os acetabuli. Leche has, in particular, paid special attention to this structure, and recorded[3] its more remarkable variations. Conspicuous among its leading types is that met with in the common rabbit,[4] in which animal it forms a squarish bone, arising outside the acetabular border, and completely shutting out the pubis from any share in the articular cavity. During ankylosis it in this animal first unites with the pubic element.

[1] Sacrum proper. *Cf.* T. J. Parker, *Phil. Trans.*, 1891, B., pp. 76 *et seq.*

[2] Ceratosaurus, Triceratops, and some other Theropoda. Marsh, *Amer. Jour. Sci.*, vol. xli. p. 173, 1891.

[3] *Loc. cit.*, pp. 25–37, and Bronn's Klass. und Ordnung. d. Thier-Reichs, Bd. 6, Abth. v., pp. 576–9.

[4] *Cf.* W. N. Parker, *Proc. Zool. Soc.*, 1882, p. 777, and fig.

Wiedersheim has recently shown[1] that the pubis of Ornithorhynchus ossifies from two centres, which are at first coequal in extent, and disposed in a dorso-ventral parallelism throughout the antero-pubic region. It will be convenient to speak of them as *ventro- and dorso-pubic centres* (*pb'*. and *pb''*. of fig. 5), in accordance with their relative positions.

The existence of a cotyloid bone in Monotremata has been doubted.[2]

In the younger of my two Duck-Bills the pubic centres were in the act of blending along the inner face of the antero-pubic tract, throughout which they had extended. The most interesting feature about them, however, is that, as compared with the younger specimen examined by Wiedersheim, they showed an inequality of growth; for, while the ventro-pubic one (*p.b'* fig. 5), except for its inward extension, had advanced but little in other directions, the dorso-pubic one (*p.b''*) had become considerably enlarged in the direction of the acetabulum, giving rise to a squarish head (* of fig.) which blocked the way of its fellow towards that cavity, and, in correlation of growth with the iliac base, would almost certainly have excluded it therefrom. The relations borne by this said "head" to the adjacent osseous centres are very suggestive of those of the Leporine os acetabuli when first it appears; and they accordingly raise the broader question whether that bone, so variable among the higher Mammalia, may not be the reduced representative of an originally more extensive structure.

The epipubes of both my Duck-Bills were ossified (those of the older one completely so, and those of the younger partially so) from a single centre in each,[3] which had extended most rapidly in an inward direction, and had replaced all but its outer border and opposite extremities. The customary articulation for the

[1] *Zeitsch. f. Wiss. Zool.*, Bd. 53, Suppl. p. 55, and pl. vi. fig. 11. My friend informs me, by letter, that in his specimen the pubic centres were "distinct and independent, and in no way united on the inner side." He also asserts, in answer to a query of my own, that the "suture" marked *a* in his figure, which he took to represent the demarcation-line between ischium and pubis (and which, if present, would imply a part articulation of the epipubis upon the ischium), is "a mistake," the cartilage "having broken down" at that point.

[2] *Cf.* Leche, *op. cit.*, p. 33, and Flower's *Osteology of the Mammalia*, ed. 3, p. 314.

[3] From the nature and extent of this, I doubt Wiedersheim's surmise that the epipubis of his example would have been completely cartilaginous, if forthcoming.

epipubis was fully differentiated in the younger animal (*ar.* fig. 5), but the oblique disposition of the base of this element across the pre-pubic border,[1] obvious enough in the adult, is, at this young stage, very much more marked. Not only so, but at this period the dorso-pubic centre (*p.b''*) furnishes it with a direct fulcrum of support. The ventro-pubic centre (*pb.'*) at this stage, as at the preceding one described by Wiedersheim, stops short of the epipubic articulation (*ar.*); and the conditions are such that the dorso-pubic element must be directly, if not exclusively, functional in receiving the upward thrust upon the epipubis resulting from the weight of the superposed viscera. There is thus good reason for associating the elongated development of the dorso-pubic centre with the physiological requirements of the epipubis; and, if I am right in homologising the former with the os acetabuli of the higher Mammalia,[2] and the ventro-pubic centre of the Ornithorhynchus with their pubic one as ordinarily defined, an inverse development of the parts in the two great divisions, so far as at present studied, is demonstrated. In the Ornithorhynchus, in which the epipubis is fully formed and at its maximum of expansion for all known mammals, the presumed cotyloid element is dominant; while in the Placentalia, in which the epipubis has disappeared, this becomes subservient to its fellow, altogether vestigial in nature, and variable in its manner of ankylosis with the other pelvic elements.[3]

Leche, working along lines laid down by Hoffmann and Huxley, has attempted to homologise the mammalian cotyloid bone with the cotyloid cartilage of Crocodiles, and with the so-called calcified portion of the pubic cartilage of Amphibians;[4] but the proof appears to me insufficient in at least the latter case. The hypothesis which I have put forward, if correct, renders it more

[1] Indicated by the line $\alpha - \beta$ of fig. 5.

[2] The most weighty objection to be raised against this is Mehnert's discovery (*Morph. Jahrb.*, Bd. xv. p. 95) that the cartilaginous pubis of mammals does not enter into the composition of the acetabular cavity. But this conclusion, in strictness, applies only to one of the forms (*Lepus*) which he investigated.

[3] Even within the limits of an individual order. *Cf.* Leche, *Kgl. Svenska Vet.-Akad. Handl.*, Bd. *cit.*, pp. 32, 33. It need hardly be added that if my view is correct, Leche's conclusion that the cotyloid bone was differentiated later than the other pelvic elements will require to be reconsidered.

[4] *Op. cit.*, pp. 35–37.

probable that the double ossification of the pubis and the possession of an osseous cotyloid element, are exclusively mammalian characters. It appears to me to more satisfactorily account for the relationships of the cotyloid bone, and for that peculiar squareness which it occasionally exhibits. Whatever is to be said for it, it need hardly be pointed out that while the facts furnish us with a possible clue to the origin of the cotyloid bone, they invest the further study of the mammalian pubis, and especially of its development in the Marsupialia, with a fresh interest.

My beloved Master, Prof. Huxley, in his important monograph upon the mammalian pelvis,[1] has laid especial stress upon the wide angle of inclination of the hip-girdle to the sacrum in Ornithorhynchus. Having defined the "sacral axis" as "a longitudinal line traversing the centre of the sacral vertebræ," and the "iliac axis" as one "drawn along the ilium dorso-ventrally, through the middle of the sacral articulation and the centre of the acetabulum," and surveyed the variations undergone by the pelvis of certain Mammalia and Sauropsida in relation to these axes, he remarks (*loc. cit.*, p. 400):—

"The 'Pro-mammalia' antecedent to the Monotremes may be expected to have the iliac and obturator axes perpendicular to the sacral axis . . . something, in short, between the pelvis of an *Ornithorhynchus* and that of a land tortoise." He proceeds, "We are led to the construction of a common type of pelvis, whence all the modifications known to occur in the Sauropsida and in the Mammalia may have diverged;" and concludes, urging his belief in the amphibian ancestry of the Mammalia, that (*loc. cit.*, p. 403) "in such a pelvis as that of *Salamandra*, we have an adequate representation of the type from which all the different modifications which we find in the higher vertebrata may have taken their origin," with the correlative that the Mammalia appear to "have been connected with the Amphibia by some unknown 'pro-mammalian' group, and not by any of the known forms of Sauropsida."

With these words ringing in my ears, I was not a little surprised to find that in the younger Ornithorhynchus herein dealt with the angle of pelvic inclination was approximately that of Echidna and the higher Mammalia. It is represented at i. in fig. 7, as related to the sacral axis α—β. This figure is a faithful tracing of the iliac and sacral axes of four specimens of advancing ages: ii. being that of Prof. Stewart's example so

[1] *Proc. Roy. Soc.*, Lond., vol. xxviii. p. 395.

often referred to; iii. that of a sexually mature male not fully grown; and iv. that of a very old male in my teaching collection; and it testifies to the fact that the forward rotation of the Ornithorhynchus hip-girdle upon its sacrum is a secondary character, acquired ontogenetically.[1] The ilium undergoes during life a forward rotation of 45°; and it is thus proved that the Ornithorhynchus' pelvis arrives at its approximately reptilian condition through the more typically mammalian one met with in Echidna.

Careful examination has shown that the backward rotation in the Echidna may be slightly in excess of that of the young Ornithorhynchus; and in this there may perhaps lie the rationale of its occasional possession of four sacral vertebræ (*cf. ante*, p. 547). On the other hand, comparison of the pelvis of an immature *Echidna aculeata*, var. *setosa*, in my collection with such older skeletons of this and the allied Echidnidæ as I have examined, shows that in this genus there is a distinct forward rotation undergone during late growth, and that the depth of the spina posterior ilii may be perhaps an index of the degree of the same. While, in respect to the extent of its true sacrum, the Echidna is as highly modified as any living mammal, the discovery that Ornithorhynchus starts with a backwardly rotated pelvis, and that in both it and the Echidna a forward rotation is effected, lends considerable support to Fräulein Westling's conclusion[2] that the living Monotremes, although extremely specialised in the direction of pure adaptation, are genetically intimately related forms.[3]

Discoveries made since the Huxleyean passages above quoted were written, having reference more especially to the constitution of the occiput in the Amniota and Amphibia,[4] to the

[1] As I believe to be true of the flatness of the head of this animal.

[2] Based upon the discovery of the common possession by the two genera of nerve-muscle relationships of a unique order.—*Bihang till K. Vet. Akad. Handl.* (Stockholm), Bd. xv. p. 61.

[3] The presence of an accessory iliac facet on the right side of the oldest Ornithorhynchus examined (*a.a.*, fig. 1) may be appropriately recorded here. It presupposes the existence of a powerful lumbar articulation, but unfortunately the thoraco-lumbar vertebræ were not forthcoming. It was accompanied by a greater extension backwards of the second sacral transverse process of the left side.

[4] *Cf. Proc. Zool. Soc.*, 1890, p. 358, and 1893, p. 273. That these investigations and the known facts of variation of the occipital condyle show that structure to be

morphology of the sternum,[1] phalanges,[2] and diaphragm,[3] to the question of hair and scale formation,[4] and, above all, to the skeleton of the Anomodont Reptiles, have profoundly modified our views upon the ancestry of the Mammalia; and we to-day turn to the Anomodontia,[5] as those creatures most likely to yield the clue to that which in the longrun has been our own primary origin.

Professor Seeley, in one of his recent and most valuable monographs upon the Anomodontia, has tabulated[6] the mammalian resemblances of their pelvis, and of these there is no one more conspicuous than the backward rotation. The facts which he summarises, together with those which I have herein recorded, go far to prove that the characteristic backward rotation of the mammalian pelvis had been effected prior to the evolution of the class, within the limits of the order ancestral to it. Judged from this standpoint, the hip-girdle of Ornithorhynchus may be looked upon as, in its disposition, the most, rather than the least, modified of that of all living Mammalia. A minor feature, perhaps not without significance in this connection, is the small size of the obturator foramen in the young Duck-Bill (fig. 5), and its close resemblance to that of *Platypodosaurus* among Anomodonts.[7]

valueless as a guide to affinity will, I think, be now generally admitted; and the presence in the lower Sauropsida of symmetrically paired aortic arches of the Amphibian type greatly diminishes the force of the argument deduced from the study of those vessels.

[1] *Cf. Nature*, vol. xliii. p. 269, and Wiedersheim, *Das Gliedmassenskelet d. Wirbelth*, Jena, 1892, pp. 193–8 and p. 216.

[2] This *Journal*, vol. xxvi. pp. 401–3.

[3] *Proc. Zool. Soc.*, 1887, pp. 462–4 and p. 471.

[4] *Cf.* especially the work of Max Weber and his pupils, as recently reported by him in the *Anat. Anzeiger*, 1893, p. 413.

[5] *Cf.* Lydekker in *Proc. Zool. Soc.*, 1893, p. 172.

[6] *Phil. Trans.*, 1888, B., pp. 106–8.

[7] Owen, *Jour. Geol. Soc.*, Lond., vol. 37, p. 269. My thanks are due to Mr A. S. Woodward for the reference to this paper.

There appears to me little cause for the late Professor Owen's doubts concerning the homology of this perforation which I have adopted. And it may not be without interest to remark that in the golden mole (*Chrysochloris*) a much smaller, but an undoubted, obturator foramen occurs, presumably as the result of secondary occlusion. (*Cf.* Dobson, *loc. cit.*, vol. ii. p. 116, and pl. xiii. fig. 7, and Leche's description of the pelvis in *Crocidura* and other Mammalia (*K. vet. Akad. Handl.*, p. 16, Taf i. figs. 15 and 20.)

DESCRIPTION OF PLATE XXVIII.

Reference letters.—*a.a.*, Accessory (lumbar) articulation. *ac.*, Acetabulum. *a.n.*, Ossific neural arch (neurosteite). *ar.* (figs. 1 and 3), Sacral arcade. *ar.* (figs 5 and 6), Articular facet for epipubis. *a.s.*, Arch of sacral vertebra. *b.v.*, Ossifying centrum (centrosteite). *gl.*, Depression formed by gluteus medius. *il'.*, Ilium. *il''.*, Iliac epiphysis. *is.*, Ischium. *l.cd'.*, Levator caudæ muscle, body. *l.cd''.*, The same, iliac head. *l.cd'''.*, The same, slips arising within sacral arcade. *lg.*, Ilio-sacral ligament. *mp.*, Sacral metapophysis. *pb'.*, Ventro-pubic element. *pb''.*, Dorso-pubic (? cotyloid) element. *pr'.*, Ilio-pectineal process. *pr''.*, Met-ischial process. *r.s.*, Sacral rib. *sy.*, Pelvic symphysis. *tr.*, Transverse process. *zy.*, Pre-zygapophysis. The remainder are referred to in the text.

Fig. 1. *Ornithorhynchus anatinus.* Sacrum of an old ♀ viewed from the front. Natural size.

Fig. 2. *The same.* Young ♂ of 316 mm. total length; right half in median section, for comparison with fig. 3.

Fig. 3. *The same.* Young ♀ of 220 mm. total length, in median transverse section. Figs. 2 and 3 slightly enlarged.

Fig. 4. *The same.* Adult ♂, dissection of the levator caudæ muscle of the left side, to show its relationships to the ilium and sacral arcade. Natural size.

Fig. 5. *The same.* Left half of the hip-girdle of the 220 mm. example. × 2.

Fig. 6. *The same.* Hip-girdle of the 316 mm. example, viewed from the left side *in situ*, in relation to the sacral axis α—β. Natural size.

Fig. 7. *The same.* Copy of a tracing on gelatine, denoting the axis of inclination of the hip-girdle to the vertebral column at four successive stages in growth. α—β denotes the sacral axis, and the length of the oblique line *i.e.*, in each case, that of the entire ilium. i. ♀ 220 mm. total length; ii. ♂ 360 mm.; iii. ♂ 470 mm.; iv. old ♂, length undeterminable. Natural size.

Fig. 8. *Centetes ecaudatus.* Front view of sacrum and hip-girdle. Natural size.

Fig. 9. *Erinaceus europæus.* The same. Natural size.

Fig. 10. *Lagomys microtis.* The same. Slightly enlarged, for better comparison with figs. 8 and 9.

Fig. 11. *Tatusia novemcincta.* Ventral view of young sacrum. Natural size.

The specimen which furnished figs. 2 and 6 is in the Museum of the Royal College of Surgeons.

TWO CASES OF SUBDIVISION OF THE POUCH OF DOUGLAS IN THE FEMALE INTO THREE FOSSÆ. By O. J. KAUFFMANN.

THE condition consists in the division of the utero-rectal pouch into three fossæ, the deep middle fossa presenting the appearance of a diverticulum from the peritoneal cavity, and extending in a downward direction between the rectum and the vagina. Viewed from above, this middle pouch is evidently nearer to the rectum than to the vagina, and appears as though prolonged on to the former viscus. It is conical in shape, with the apex directed downwards, and the base of the cone is at the junction with the general peritoneal cavity, the commencement of the diverticulum being, however, distinctly demarcated. The base of the diverticulum-like middle fossa measures about 1½ inch across, and its depth is the same; the apex corresponds with a point in the vagina about 1½ inch below the external os uteri. The sac is lined with glistening peritoneum. Projecting partly across the base of the pouch from its right edge is a triangular thin membranous fold of peritoneum, the free border of which reaches not quite half-way across the mouth of the sac. On the left side of the base of the pouch are a few tags of membrane, seeming to indicate that an analogous membranous formation existed or was attempted on that side, and that it either was destroyed or remained abortive.

The membrane and pouch are very evidently not the result of any inflammatory process, there being no trace of thickening, and the glistening serous covering being very distinct.

The specimen was removed from the body of a woman aged 36, who died as a result of an operation for the relief of an abdominal extra-uterine gestation.

Another case of very similar nature has occurred to me in the body of a girl aged 17, who was under-developed in every respect, and who had, in addition, a congenital heart-lesion. Death in this instance was due to pericarditis. The pouch here was not conical, but almost spherical in shape, and was delimited from

the general peritoneal cavity by a sharp, thin, projecting membranous rim of peritoneum, perfectly symmetrical, which left a circular opening of communication with the peritoneal cavity about ½ inch across. This sac, too, was lined with glistening peritoneum.

As regards the mode of production of these evidently congenital middle pouches, their site and character have suggested to me that they are remnants of that part of the embryonic body-cavity which belonged to the primitive hind-gut, or that part of the alimentary canal which, after the invagination of the anus, becomes the post-anal gut.

Whether the transverse membrane in the first case and the diaphragm-like membrane in the second may be taken as showing that this part of the cœlom is habitually closed off by a transverse ingrowth of the peritoneum I will not venture to say, but the appearances described are suggestive of such a process.

The first patient had previously been several times normally pregnant, and the thought that her extra-uterine gestation may have been favoured by a mal-development of the ovary cannot therefore be entertained.

DIVERTICULUM (MECKEL'S) OF SMALL INTESTINE.

By A. M. BUCHANAN, M.D., *Professor of Anatomy, Anderson's College, Glasgow.*

THIS case presented features of so great interest and importance (both medically and surgically) as to justify a record being made of it.

It occurred in a male subject æt. 42 years (cause of death pneumonia), and was observed in the month of January 1893.

On opening the abdomen, attention was first drawn to the very large size of the stomach.

This organ, when moderately distended, had the following measurements:—

Length from left side of cardiac orifice to pyloric orifice (along greater curvature) . . .	64½	centimetres.
Lesser curvature	23½	"
Length from fundus to pylorus	48	"
Circumference opposite cardiac orifice . . .	48	"
Circumference midway between cardiac and pyloric orifices	40	"
Circumference at 6 centimetres from pyloric orifice	18	"
Circumference immediately to left of pyloric orifice	11	"

On separating the coils of the small intestine a well-marked diverticulum was discovered. It lay quite free amongst the convolutions of the gut, and had not the slightest trace of a mesentery. It projected to the right of the middle line, and had an inclination downwards or away from the stomach, so that foreign or other matter could easily have entered its cavity. It was situated on the free border of the ileum, exactly opposite the line of attachment of the mesentery.

These points having been noted, the intestinal canal (small and large) was then carefully removed, with the exception of the rectum. The total length, exclusive of rectum, was 32 feet.

The diverticulum was situated exactly 4 feet from the termination of the ileum in the large intestine.

The axis of the diverticulum was not at right angles to the immediately adjacent portion of ileum, but inclined downwards,

as well as to the right. Its form was, with slight modification, conical. Its base or attached end was comparatively constricted. It then expanded into a body which subsequently became very distinctly constricted, and, finally expanding slightly, terminated in a somewhat pointed extremity.

Its opening of communication with the ileum was very distinct and patent, circular in shape, and without the very slightest



FIG. 1.

trace of any valvular arrangement, so that the natural contents of the bowel, foreign matter, intestinal worms, &c., had easy access to the nest which it afforded them.

Circular and longitudinal muscular fibres could be seen, but they were exceedingly sparse.

There was no trace (visible from without) of valvulæ conniventes, and it cannot be said whether villi were present or not. It was highly vascular, more so proportionately than the part of the ileum with which it was connected, and, as will be seen from the illustration, a well-sized and well-injected artery (branching out freely) extended from base to apex on the anterior surface.

The following are the measurements:—

Length	9	centimetres.
Circumference at base	11	,,
Circumference at widest part (3½ centimetres from base)	12	,,
Circumference 4 centimetres from apex	10	,,
Circumference below apex	5	,,

Circumference of apex = (½ circumference of point of ordinary little finger).

Twenty-six centimetres of bowel (measured along the mesenteric border) above the diverticulum are shown in the illustration. This portion presented along the same border five distinct constrictions, with four intervening dilatations, the lowest and deepest constriction being situated opposite centre of base of diverticulum.

The following measurements of the ileum above and below the diverticulum were taken:—

(1) *Above*—

Circumference immediately above	10½	centimetres.
Do. 26 centimetres above	11½	,,

(2) *Below*—

Circumference immediately below	12	,,
Do. 23 centimetres below	10	,,

The diverticulum was patent throughout, even to its apex.

It lay over the immediately subjacent coil of ileum, which it might thus have injuriously compressed.

Cæcum and Vermiform Appendix.

THE cæcum and vermiform appendix in the subject in which the diverticulum was met with were so peculiar and interesting as to call for the following notes being made in regard to them.

Only a very small part of the cæcum at its commencement lay in the upper part of the right iliac fossa. The greater part of it extended upwards and to the left, behind the terminal portion of the ileum, into the hypogastric region, reaching nearly

FIG. 2.

as high as the umbilicus. In this course it extended to the left of the left border of the termination of the ileum for 5 centimetres.

The dimensions of it were as follows:—

Length along convex border	24½	centimetres.
Circumference at end	23½	"
Circumference at widest part (opposite centre of entrance of ileum)	27½	"

The only part of the cæcum which had a mesentery was that portion which lay in the upper part of the right iliac fossa.

The vermiform appendix was remarkable for its length and

its relation to the lower part of the ileum. Its measurements were as follows:—

Length	13½	centimetres.
Circumference at attached end, and for 4 centimetres beyond that	3	"
Circumference elsewhere	2½	"

The exact attachment was to the junction of the anterior wall with the mesial and blind end of the cæcum, and midway between its superior and inferior borders. Its direction was upwards and forwards behind the lower part of the ileum, over one of the coils of which it rested.

It might thus have easily strangulated this portion of bowel. The part of the appendix immediately adjacent to the cæcum had a small mesentery. The whole appendix was pervious throughout, and presented one very marked curve where it lay over the ileum.

The circumference of the commencement of the ascending colon was 27 centimetres.

Notices of New Books.

Annual of the Universal Medical Sciences. Edited by C. E. Sajous, M.D. Davis & Co., Philadelphia, 1892.

Dr Sajous and his associate editors have produced, with their customary alertness and thoroughness, their annual report on the progress of the medical sciences. The five volumes now before us furnish an admirable record of medical literature for the year preceding their publication. The last volume contains abstracts of a number of important papers on anatomy, teratology, and physiology.

Die Morphologie des Stirnlappens und der Insel der Anthropomorphen. By Professor D. Marchand. Gustav Fischer, Jena, 1893.

This memoir contains a carefully written account of the frontal lobe in the chimpanzee, gorilla, and orang, from specimens examined by the author. The insula is also described in the brains of man, apes, and lemurs, and the morphology of this division of the brain is discussed. Professor Marchand reviews the facts stated and the opinions expressed by previous writers on these parts of cerebral anatomy.

Die Epiglottis—vergleichendanatomische studie, von Carl Gegenbaur. Leipzig: Engelmann, 1892.

Professor Gegenbaur dedicates this monograph on the epiglottis to Professor von Kölliker, in recognition of the attainment by the latter of the fiftieth anniversary of his medical doctorate. In a graceful introduction, he refers to Kölliker's activity as a teacher and investigator. He dwells upon the great range of the original work which Kölliker has done in all branches of biology from the time when, under the impulse of Johannes Müller the greatest teacher of anatomy and physiology which this century has produced, he began his observations on the structure of lower organisms. Gegenbaur himself is a remarkable example of width and grasp in the investigation of structure, and in the consideration of biological problems. In writing this monograph on the epiglottis, he has studied it from the point of

view of the comparative anatomist, and has brought together a quantity of interesting material on its structure, position, and phylogenetic relations.

Crania Ethnica Americana, herausgegeben von Rudolf Virchow. Berlin: Asher & Co., 1892.

In memory of Christopher Columbus, and the discovery of the New World 400 years ago, Professor Virchow has issued an atlas of a number of crania of American aborigines preserved in the Museums in Berlin. The atlas contains twenty-six folio plates, and in each plate are five figures of a skull, depicting it in the following aspects: norma facialis, occipitalis, lateralis, verticalis, and inferior. A description of each skull is given, and the whole is preceded by a chapter on American craniography.

Dissections Illustrated: a graphic Handbook for Students of Human Anatomy. By C. Gordon Brodie, F.R.C.S., with Plates by Percy Highley. Whitaker & Co., London.

Part I. of these illustrations of human anatomy contains a series of plates, seventeen in number, representing dissections of the most important regions in the human upper limb. The plates are printed in colours, so that the eye can at once recognise muscles, fascia, arteries, veins, and nerves. Each plate is accompanied by two pages of descriptive letterpress. The work, when completed, will be useful to the student as a supplement to, but not as a substitute for, his regular courses of dissection.

Nuevo Concepto de la Histologia de Los Centros Nerviosos. Por el Dr D. S. Ramón y Cajal. Barcelona, 1893.

This work is a summary in pamphlet form of the papers which Ramón y Cajal has published on the minute anatomy of the central nervous system during the past few years. Abstracts of his papers, as well as those of Golgi, von Kölliker, and van Gehuchten, working with similar methods, have from time to time appeared in this *Journal*. Without entering into any detail upon the novel anatomical facts which the methods of Golgi and Ramón y Cajal have brought to light, a summary of the conclusions formed by the latter investigator in the monograph before us is here given.

1. The nerve cell, including its protoplasmic and axis-cylinder processes, constitutes a nervous unit.

2. Nerve cells communicate with each other, not necessarily through continuity of structure, but by contiguity or contact. This occurs both at the "end tuft" of the collaterals of axis-cylinder processes, as well as between protoplasmic arborisations.

3. The direction of the nervous impulse in these structures is probably *afferent* to the cell-body through the protoplasmic processes, *efferent* through the axis-cylinder and its collaterals.

4. In bipolar cells, such as are seen in the ganglia of the posterior spinal roots, the peripheral expansion is regarded as of protoplasmic nature, and hence is afferent in function.

5. Golgi's view, that the protoplasmic processes chiefly served as the nutritive apparatus of the cell, has not been entirely confirmed by subsequent observation.

INDEX.

ABDOMEN, Regions of, 257, 285.
Acromion, 245.
Adductors of Thumb and Great Toe, 408.
Aged Persons, Testicles of, 474.
Allen, F. J., Urethral Bulb, 235.
Anencephalous Fœtus, 348.
Anthropoid Apes, Grooves in Integument, 112; Vertebræ of, 131.
Annual of Universal Medical Sciences, 564.
Arrow Poison, 402.
Atlas, Development and Variations, 519.
Articulations, Costo-Sternal, 1; Costo-Vertebral, 131, 252.
Arteries, Middle Sacral, 184; Arch of Aorta, 189; of Limbs, 377.

BICEPS Flexor Cruris, 282.
Birmingham, Ambrose, Heart, Anomaly of, 139.
Brain, of George Grote, 21; Cerebral Commissures in, 69.
Buchanan, A. M., Diverticulum Ilei, 559.

CARLIER, E. W., Histology of Hedgehog, 85, 169, 354, 508.
Cartilages, Supernumerary Nasal, 181.
Carwardine, T., Suprasternal Bones, 232.
Cetacea, Hind Limb in, 291.
Charles, R. H., Craniology of Panjab Tribes, 5.
Clarke, J. J., Temporal Bone, 411.
Collinge, W. E., Reproductive Organs in Molluscs, 237.
Colloid of Thyroid Gland, 161.
Commissures, Cerebral, 69.
Costo-Sternal Articulations, 1.
Costo-Vertebral Joint, 131, 252.
Crania Ethnica Americana, by Professor Virchow, 565.
Craniology of Panjab Tribes, 5.
Craniometry of Panjab Tribes, 5.
Crocodilus porosus, Jacobson's Organ in, 151.
Cullingworth, C. J., on Hymen, 343.
Cunningham, D. J., Regions of Abdomen, 257.
Cystic Degeneration, 454.

Das Central-nerven-system von Protopterus annectens, by R. Burckhardt, 290.
Degeneration, 454.
Delimitation of Regions of Abdomen, 257, 285.
Die Vergleichende Anatomie des Gehirns, by L. Edinger, 290.
Die Epiglottis, by Professor Gegenbaur, 564.
Dissections Illustrated, by C. Gordon Brodie, 565.
Diverticulum Ilei, 559.
Dog, Testicles of, 483.
Douglas, Pouch of, 557.
Downie, W., Supernumerary Nasal Cartilages, 181.
Dura Mater, 179.

Eléments d'Anatomie Comparée, by R. Perrier, 429.
Eichholz, A., Morphology of Limb Arteries, 377.
Embryo, Malformations of, 348, 436.
Erinaceus europæus, 85, 169, 354, 508.

FAWCETT, E., Dura Mater and Lower Jaw Joint, 179.

GASTRIC Digestion, 195.
Gillespie, A. L., Gastric Digestion, 195.
Griffiths, Joseph, Testicles of Old Men, 474; of Dog, 483.
Grote, Brain of George, 21.
Gulland, G. L., Placenta of *Macacus rhesus*, 361.
Gorilla, Vertebræ of, 131; Hand of, 112.

HAIRS, Nerve Endings on, 224.
Hart, D. B., Placenta of *Macacus rhesus*, 361.
Hepburn, David, Integumentary Grooves, 112; Biceps Flexor Cruris, 282; Adductor Muscles, 408.
Hermaphrodite Molluscs, 237.
Heart, Anomaly of, 139, 464; Degeneration of, 454.
Hedgehog, Histology of, 85, 169, 354, 508.
Histology, 85, 169, 354, 508.
Hoggan, G. and F. E., Nerve Endings on Hairs, 224.
Horne, R. M., Colloid of Thyroid Gland, 161.
Horsley, Victor, *Cranio-Cerebral Topography*, 228; *Structure and Function of Brain and Spinal Cord*, 289.
Howes, G. B., Mammalian Pelvis, 543.
Human Embryology, C. S. Minot, 429.
Hymen, 343.

Ichthyornis, 336.
Interosseous Nerve, Anterior, 192.
Integument, Grooves in, 112.

JACOBSON's Organ, 151.

KAUFFMANN, O. J., Pouch of Douglas, 557.

LARYNX in Voice Production, 431.
Limbs, Hind, in Cetacea, 291; Morphology of Arteries of, 377.

Macacus rhesus, Placenta of, 361.
Macalister, Alex., Acromion, 245; First Costo-Vertebral Joint, 252; Atlas, 519.
Malformations, 348, 415, 436, 464.
Marshall, John, Brain of George Grote, 21.
Marsupialia, Cerebral Commissures in, 69.
Meckel's Diverticulum, 559.
Median Nerve, 192.
Meek, A., Jacobson's Organ, 151.
Meigs, A. V., Cystic Degeneration, 454.
Meningeal Artery, 279.
Monotremata, Cerebral Commissures in, 69; Pelvis in, 543.
Molluscs, Hermaphrodite, 237.
Morphologie des Sternlappens und der Insel, by Prof. D. Marchand, 564.
Muscular System, Psoas Parvus, 187; Biceps Flexor Cruris, 282; Adductors of Thumb and Great Toe, 408; Sternalis Muscle, 505.
Musgrove, Jas., Costo-sternal Articulations, 1; Ophthalmic Artery, 279.

Nerve Tracts in Mid and Hind Brain, and Cranial Nerves arising therefrom, by Alex. Bruce, 286.
Nervous System, Brain of George Grote, 21; Cerebral Commissures, 69; Median and Ulnar Nerves, 192; Nerve Endings, 224; Phrenic Nerve, 427.
Nose, Development of, 151; Cartilages of, 181.

OPHTHALMIC Artery, 279.
Ornithorhynchus, Pelvis of, 543.
Osseous System, Suprasternal Bones, 232; Absence of Ulnæ, 239; Acromion, 245; Ichthyornis, 336; Temporal Bone, 411; Parietal Bone, 501; Atlas, 519.

PALM, Grooves in, 112.
Parietal Bone, Depressions in, 501.
Parsons, F. G., Musculus Sternalis, 505.
Panjab Tribes, Craniology of, 5.
Pelvis, Mammalian, 543.
Peritoneum in Pelvis, 557.
Phrenic Nerve, 427.
Placenta of *Macacus rhesus*, 361.
Poison, Arrow, 402.
Précis de Teratologie, by L. Guinard, 428.
Pringle, J. H., Absence of Ulna, 239.
Proteids, Gastric Digestion of, 195.
Psoas parvus, 187.

SACRAL Artery, Middle, 184.
Sanders, Gordon, Malformation of Heart and Great Vessels, 464.
Shepherd, F. J., Depressions in Parietal Bone, 501.
Shufeldt, R. W., On Ichthyornis, 336.
Smith, W. W., Regions of Abdomen, 285.
Sole, Grooves in, 112.
Sternalis Muscle, 505.
Strings, Vibration of, 431.
Struthers, John, Vertebræ of Man and Gorilla, 131; Hind Limb of Fin Whale, 291.
Suprasternal Bones, 232.
Surface Anatomy of Cerebral Hemispheres, by D. J. Cunningham, 288.
Symington, Johnson, On Cerebral Commissures, 69.

TEMPORAL Bone, 411.
Temporo-Maxillary Joint, 179.
Teratology, 139, 237, 239, 348, 415, 436, 464.
Testicles of Old Men, 474; of Dog, 483.
Thomson, Arthur, Report of Collective Investigation Committee, 183.
Thyroid Gland, Colloid of, 161.
Tillie, Joseph, Arrow Poison, 402.
Transposition of Great Vessels, 464.
Turner, Sir W., Phrenic Nerve, 427.

ULNA, Congenital Absence of, 239.
Ulnar Nerve, 192.
Urethral Bulb, 235.

VASCULAR System, Anomaly of, 139, 464; Middle Sacral Artery, 184; Branches of Arch, 189; Ophthalmic Artery, 279; Limb Arteries, 377.

WHALES, Hind Limb in, 291.
Windle, B. C. A., Anencephalous Fœtus, 348; Report on Teratological Literature, 415; Malformations of Embryo, 436.
Woods, R. H., Vibration of Strings, 431.

PROCEEDINGS OF THE

ANATOMICAL SOCIETY OF GREAT BRITAIN AND IRELAND.

AUGUST 1892.

THE Fourth Quarterly Meeting of the Session was held on August 2 at Edinburgh, in the Anatomical Theatre of the New Buildings of the University, the President, Sir William Turner, in the chair. Present—Thirteen members and visitors.

The minutes of the previous meeting were read and confirmed.

The Secretary reported that the members nominated to serve on the Committee to consider the methods of delimitation of the regions of the abdomen had consented to act.

A letter was read from the Executive of the XI. International Medical Congress, to be held in Rome in September 1893, inviting the co-operation of the members of the Society at the Congress.

The following gentlemen were nominated for election at the next meeting:—H. J. Waring, M.B., B.S., F.R.C.S., Assistant Demonstrator of Anatomy at St Bartholomew's Hospital, London, proposed by C. B. Lockwood, W. P. Herringham, G. H. Makins; and F. C. Kempson, B.A., Demonstrator of Anatomy at St George's Hospital, proposed by T. Pickering Pick, W. H. Bennett, H. D. Rolleston.

Professor Sir W. TURNER, F.R.S. (President), exhibited the following specimens:—

a. The *Antlers of a Roe-deer* referred to by him at the last meeting of the Society in the discussion on Mr Bland Sutton's paper on the sebaceous glands present in the velvety covering of the antlers of that animal.

b. Some splendid specimens of *tattooed Skin* from an Irish American, æt. 29. He had been operated on by his brother when a boy from four to seven years of age, and the process of tattooing had occupied nearly three years. The whole surface of the skin except the face, hands, soles of feet, and front of pelvis was covered with most artistically executed designs in red and black, in which several Irish and American emblems were introduced. The man died of phthisis. The specimen was presented to the Museum of the University of Edinburgh by Dr J. Biggam.

c. A specimen showing *complete transposition of the viscera of the abdomen and thorax*, from the body of an old woman. The specimen was presented to the Museum of the University of Edinburgh by Dr Littlejohn.

Dr SYMINGTON showed *a horizontal section through the abdomen of a man aged 57 years, made at the level of the umbilicus and the disc between the 4th and 5th lumbar vertebræ.* The subject was very thin, and the anterior abdominal wall was depressed so that it came into close relation with the lower part of the abdominal aorta. The interest of the specimen was due to the fact that the large intestines were divided at the level of the ileo-cæcal orifice, which was closed by the distension of the cæcum with fæces and gas. As will be seen from the figure, the orifice was in the form of a nearly vertical slit,

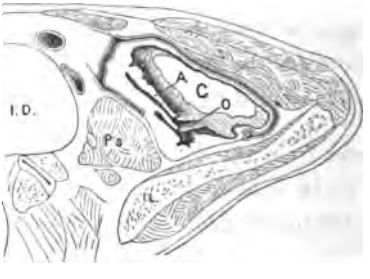

I.D, Intervertebral disc between the 4th and 5th lumbar vertebræ. *C*, Cæcum. *A*, Anterior flap of ileo-cæcal valve. *O*, Posterior flap of ileo-cæcal valve. *Ps*, Psoas muscle. *IL*, Ileum.

bounded by two flaps, anterior and posterior. The anterior flap did not reach quite so far to the right side as the posterior one. The latter lay against the posterior wall of the cæcum. From this case it appears probable that the passage of material from the large into the

small intestines is prevented by the two flaps at the ileo-cæcal orifice being pressed against one another, and against the posterior wall of the large intestines by the contents of the cæcum. The passage from the small to the large intestines therefore presents some resemblance to the oblique entrance of the ureters into the bladder, and the valvular action is of the same nature.

Dr SYMINGTON also exhibited *a Heart in which the anterior papillary muscle of the right ventricle presented an unusual arrangement.* The muscle, instead of ending where it gave off its chordæ tendineæ, was continued upwards on to the ventricular surface of the tricuspid valve, and its muscular fibres could be seen extending into the base of the valve. In this specimen there were also several distinct bundles of the columnæ carneæ passing directly to the ventricular surface of the valve near its base.

Professor STRUTHERS showed the following preparations:—

1. *Two Knee-Joints having a complete septum in the femoro-tibial part of the joint.*—(*a*) In an adolescent subject. The free anterior border of the septum is in the usual position of the ligamentum mucosum, passing to the fore part of the intercondylar notch of the femur. Posteriorly, the septum reaches to the crucial ligaments, over which the two layers of synovial membrane that form the septum spread. There is but slight thickening of the anterior border. At the middle of the septum, on a level with the lower part of the attached base of the alar fatty mass, the septum contains a thickened bundle of tissue, above and below which the septum is translucent. Measurements of septum, vertically 1 inch, antero-posteriorly about the same, but the anterior third occupied by fat.—(*b*) An adult subject. The same arrangement. There is the same thickened bundle of tissue about the middle, interrupting the translucency of the septum. Measurements of the septum, vertically, $\frac{3}{4}$ inch behind, 1 inch in front; antero-posteriorly, $1\frac{1}{4}$ inch; no fat between the layers. Both of these were the knee-joint of the right side. The left joints were not preserved.

Following the existing nomenclature of the so-called ligament, the septum may be termed the *septum mucosum.* This variety may be regarded simply as a vestige of an early median septum between the two femoro-tibial joints, more complete than that remaining usually as the ligamentum mucosum. That so-called ligament, with the so-called ligamenta alaria, as Mr Bland Sutton remarks, is but a vestige of the septum which divided the knee-joint into three joints, the two femoro-tibial joints below and the femoro-patellar joint above, a condition persisting through life in some mammals. It appears uncertain whether the broad expansion of the synovial membrane above the patella should be regarded as derived from the primitive femoro-patellar sac or from the primitive bursa beneath the tendon of the rectus muscle.

2. Two specimens of *variation in the arrangement of the long flexor tendons in the sole of the foot.* (*a*) One, of the very rare condition in which the tendon of the flexor longus hallucis goes entirely to the great toe. (*b*) The other, of the condition in which, besides the usual tendon from the flexor longus hallucis to the neighbouring toes, the flexor longus digitorum gives a tendon to the great toe. The arrangement in the second of these specimens corresponds to that seen among the Quadrumana, in which the long common flexor of the quadruped is variously differentiated into two flexors more or less connected. In the first specimen the differentiation is completed, as in the normal condition in the human hand. The author referred to his remarks "On the error of regarding the 'flexor longus pollicis' pedis muscle of Man as, normally, a flexor of the great toe only" (*Edin. Med. Journ.*, 1863, p. 85). The present nomenclature tended to perpetuate the erroneous idea. As the internal one at the foot is external at the leg, the too common muscles cannot be named internal and external. They might be distinguished as "tibialis" and "fibularis," or the internal one at the foot might be termed "flexor longus hallucis et digitorum."

3. Preparation, showing the *Left Vertebral Artery arising from the arch of the aorta, and entering at the foramen of the fifth cervical vertebra.* Length of the artery before entering the foramen, 5 inches. Right vertebral artery arises normally, and enters normally at the foramen of the sixth vertebra. The author referred to a like case noted in his paper "On Variation of the Vertebræ and Ribs in Man" (*Jour. of Anat. and Phys.*, 1874, p. 26, Case 3), and showed two preparations, also there noted—one, in which the right vertebral artery entered first at the fourth vertebra, the foramen in the fifth and sixth being well formed (Case 4); the other (Case 2), in which the right vertebral artery arose last from the arch of the aorta, passed behind the œsophagus, and entered the foramen of the seventh vertebra. Besides that case, and another there noted (Case 1), in which the left vertebral arose from the subclavian nearly an inch earlier than usual and entered at the seventh foramen, the author could not in all his long experience recall any other instance in which he had seen a vertebral artery enter the foramen of the seventh cervical vertebra. Thus, although it is quite common to see the vertebral artery arising lower than usual, that of the left side homologically from the arch of the aorta, it is, notwithstanding, very rare to see it enter at the foramen of the seventh vertebra.

4. *Series of Preparations, showing Varieties of the Branches of the Abdominal Aorta.*

(*a*) Two specimens of very large anastomosis between the pancreatico-duodenal branch of the hepatic artery and the pancreatic branch of the superior mesenteric. In one, the anastomosing arteries form a large tortuous vessel, about 8 inches in length, nearly the size of a goose-quill, the hepatic end of the circle the larger. In the other specimen the anastomosing vessel is about a third less in diameter,

about 6 inches in length, the hepatic end of the circle also the larger. With the aorta and roots of the cœliac axis and superior mesenteric, a circle is formed in both specimens through which the closed hand could be passed.

(*b*) Preparation, from a large male subject, showing several varieties —(1) the *hepatic artery* arose entirely from the superior mesenteric; (2) a long tortuous *splenic artery*, about 9 inches in length before it divides; (3) the *coronary artery* arises from the splenic about half an inch after the origin of the latter from the aorta, their common trunk representing the cœliac axis.

(*c*) Preparation, showing several varieties—(1) the *coronary artery* arises directly from the aorta, ¾ inch above the cœliac axis; (2) the *superior mesenteric* arises entirely from the cœliac axis; (3) the *left spermatic artery* arises from the renal, ¾ inch out; the left renal arises ¼ inch further down than the right.

(*d*) Preparation, showing several varieties—(1) *two hepatic arteries*, of about equal size; one arises from the superior mesenteric, the other from the cœliac axis; (2) the latter, after a course of 1½ inches, gives off the *coronary artery;* (3) the *gastroduodenal* arises from the cœliac axis, at the point of breaking up of the axis; (4) entire absence of the left *renal artery;* there was no left kidney.

(*e*) Variety in the *mode of branching of the superior mesenteric artery.* The earlier branches to the small intestine are large, and form wide primary arches, resembling the primary arches formed by its branches to the large intestine. There is an interval of 1½ inches between the origin of the 4th and 5th branch to the small intestine, and after the origin of the 4th branch the trunk of the mesenteric is not larger than any of the three preceding branches to the small intestine. After the 5th, seven small branches are given to the small intestine.

(*f*) *Variety of the renal arteries.* The preparation shows, on the left side, two renal arteries arising close together, the lower about half the size of the upper, both entering the kidney by the hilum. On the right side, opposite to those of the left side, also two renal arteries, arising quite close together, of nearly equal size, one of them dividing unequally after a course of ⅓ inch. A third right renal artery, of the same size as each of the two upper, arises 3 inches further down at about ¾ inch from the bifurcation of the aorta, passes up behind the ureter and enters the kidney below the hilum. Along with this the author showed one of the two specimens already noted by him (*Edin. Med. Journ.*, 1863, p. 759), in which a renal artery arose from the middle sacral. In the preparation now shown, each kidney has a supplementary artery, the right arising from the middle sacral, the left from the commencement of the common iliac, both passing to the lower part of their kidney behind the ureter. Three to four inches further up there are—for the left kidney, two arteries of unequal size, and close together; for the right kidney, one artery arising ½ inch lower down than the two for the left kidney.

(*g*) *The arteries in two preparations of horse-shoe kidney.*—(1) In one there are two arteries for each lateral lobe, and a median artery for the isthmus part. The isthmus is formed simply by the running together of the lateral lobes, giving the figure V, and is the thickest part of the kidney. The median artery arises near the isthmus, and enters it in front. The arteries for the right lateral lobe arise two inches higher, close together, the upper one small. Of those for the left lateral lobe, one arises on the same level as those for the right kidney; the other, larger, arises an inch further down. (2) In this specimen the isthmus is narrow and long. The arteries, incompletely preserved, have been somewhat as in the last case, two for each lateral lobe, arising high up and close together, on nearly the same level on the two sides; and an artery is seen to enter the isthmus on the right side. The ureters, as usual, pass down in front of the isthmus in both the specimens.

5. *Three specimens of Double Ureter.*—(1) In one, the ureter is double in its upper third only. The arteries at the hilum lie mostly between the two ureters. (2) In the second, the ureters, of about equal diameter, are distinct until they are about to pierce the bladder, when they become united. At the hilum, the arteries are partly between the two ureters, partly in front of the anterior ureter. (3) In the third specimen, the ureters of both sides are preserved and fully injected. The right ureter is normal. On the left side there are two ureters, of about equal diameter, distinct throughout, entering the bladder by distinct apertures, close together. Each kidney has one artery, the left renal arising a little lower than the right, and larger than the right, as the left kidney also is. The divisions of the left artery enter the kidney partly in front, partly behind both ureters or pelves. On the right side the arteries enter partly behind the pelvis. In this specimen all of the three ureters show the decided dilatation on their last two to three inches, till close to the bladder.

6. *Transposition of the Common Iliac Veins and Vena Cava Inferior.*—In this specimen the common iliac veins cross behind the left common iliac artery; the vena cava lies to the left side of the aorta, and crosses obliquely in front of the aorta, below the root of the superior mesenteric artery, to gain the right side.

7. *Communications between the Vena Portæ and the Vena Cava in the Horse.*—In regard to this disputed question, Chauveau (*Comp. Anat. of the Domesticated Animals*, 2nd English ed., 1891) adheres to the opinion that the two systems do not communicate in the adult otherwise than by the capillaries; and that if any other communications exist, they must be extremely small. In this preparation, from an adult horse, the trunks of the vena portæ and posterior vena cava are seen to communicate directly by a transverse commissural vein, an inch in length and $\frac{1}{8}$ to $\frac{1}{6}$ inch in diameter, and by four antero-posterior veins, as large as a crow-quill, two from that com-

missural vein, two directly from the trunk of the vena portæ, to join a large tributary of the vena cava. The preparation was made for the author by the late Professor Barlow of the Edinburgh Veterinary School, a careful and thoughtful anatomist, and is submitted to the Society with the view of suggesting further research.

Professor A. M. Buchanan showed the *Kidneys, exhibiting well-marked lobulation, from a healthy woman* aged 26. The kidneys were shown not as coming under Meckel's statement, "that the lobulated structure has been sometimes carried so far as the point of giving a resemblance to several separate kidneys," but as apparently an advance on Henle's statement that "exceptionally the kidney is traversed by shallow furrows, which indicate a division into lobes which existed in an earlier stage of development. It is in the adult still betrayed by the internal structure of the organ."

The following note of the weights and measurements was appended:—

Right Kidney.	*Left Kidney.*
Weight, 4 oz. 1 drm.	Weight, 3 oz. 6 drms. 49 grs.

Difference, 1 drm. 11 grs.

Length, . . .	$5\frac{3}{8}$ inches.	$5\frac{1}{8}$ inches.
Breadth at upper end, .	$2\frac{3}{8}$ "	$2\frac{1}{4}$ "
" lower end, .	2 "	$2\frac{3}{4}$ "
" centre of hilus in front, .	$2\frac{3}{8}$ "	2 "
" centre of hilus behind, .	$1\frac{3}{8}$ "	2 "
" upper part of hilus, .	$1\frac{1}{4}$ "	$2\frac{1}{4}$ "
" lower part of hilus, .	$1\frac{3}{8}$ "	$1\frac{1}{4}$ "
Length of hilus in front,	$2\frac{5}{8}$ "	$1\frac{1}{8}$ "
" " behind,	$2\frac{1}{8}$ "	$1\frac{1}{2}$ "

There was nothing abnormal as to the renal vessels. The adrenals were not noted.

The sulci which the kidneys present have in certain instances been rendered deeper than they actually were owing to the renal tissue having been somewhat torn on removing the capsule. This was done with great care under a gentle stream of water, but where the tearing took place the sulci were occupied by fat, and the capsule was unusually adherent.

Professor A. M. Buchanan also exhibited a specimen of the *Glass Bottles* he employs for the preservation of *Preparations*. The stopper

is ground, and consequently air-tight; it is provided with a glass hook on the under surface, which affords a simple mode of suspension. Specimens can easily, if necessary, be extracted from it, and the glass stopper may be made removable, if fixed, by placing a cloth wrung out in hot water around the neck.

Professor CLELAND, F.R.S., communicated *A Contribution to the Comparative Anatomy of the Ankle-Joint.*

Dr Cleland pointed out in the hind limb of the Vulpine Phalanger the presence at the ankle of a tibial and fibular joint distinct one from the other; the tibial joint articulating with the upper surface of the astragalus, and continuous with the astragalo-calcaneal joint at its posterior and outer part, while the fibula was separated from this joint by a strong fibrous structure, which, followed downwards, was inserted into the outer side of the calcaneum, and might correspond with the middle band of the external lateral ligament of the ankle-joint in Man. Followed upwards, it was continued between tibia and fibula into a deep muscle belonging to the back of the leg, and whose fibres for the most part took a downward and inward direction from the fibula. Serial correspondence of this muscle with the pronator quadratus of human anatomy, and of the tendon between the joints with the triangular fibro-plate below the ulna, seemed possible. He showed the presence of a similar arrangement in Phascogale. Also, he demonstrated that in Ornithorhynchus the fibula was completely cut off from the astragalo-tibial articulation by a double fold of synovial membrane, and that a similar fold from behind existed in Echidna, but did not reach forward to the front. Dr Cleland regarded his communication as a preliminary notice of a larger investigation.

Professor BIRMINGHAM exhibited a *Specimen of Spina Bifida of the Cervical Vertebræ*, which was associated with an enormous enlargement of the foramen magnum, a cleft palate, and a para-occipital process, which projected downwards from the jugular process of the occipital, and articulated movably with the front of the transverse process of the atlas. A median suture existed, traversing the tabular portion of the occipital bone sagittally. The foramen magnum measured nearly 3 inches in the antero-posterior diameter. The enlargement was due entirely to a deficiency of the portion of the occipital bone which lies on the postero-lateral and posterior aspect of the foramen magnum, namely, its supra-occipital segment. Professor Birmingham was of opinion that the condition of the foramen magnum might be explained as an extension of the spina bifida (which was most complete above) to the first modified vertebra of the skull; and it might be considered as a bit of evidence in favour of the vertebrate theory of the skull.

Dr MUSGROVE gave a lantern demonstration of the arrangement of

the *blood-vessels and lymphatics of the retina* (see paper in the *Jour. of Anat. and Phys.*, vol. xxvi. p. 239).

Dr DAVID HEPBURN gave a microscopic demonstration of sections, illustrating the *development of diarthrodial joints.*

Professor BIRMINGHAM read a paper on a specimen of *Extreme Anomaly of the Heart, with history*, which will be found *in extenso* in the present number of the *Journal of Anatomy and Physiology*, p. 139.

Dr MUSGROVE read a paper *On the Costo-Sternal Articulations*, which will be found *in extenso* in the present number of the *Journal of Anatomy and Physiology*, p. 1.

Professor STRUTHERS asked whether Dr Musgrove had noted any special characteristics dependent on the sex and age of the subjects examined, and Dr Musgrove said that sex and age had apparently no influence on the number of perfect joints existent.

Professor A. M. BUCHANAN communicated a paper on *The Use of Peroxide of Hydrogen for Cleaning Bones.*

Peroxide of hydrogen (H_2O_2), which was discovered in the year 1818 by Thenard, is a colourless, perfectly transparent liquid, having a strong bitter taste. It occurs sometimes in the atmosphere, in rain, in dew, and in snow.

The commercial kind is liable to contain, amongst other acids, hydrochloric acid. Its effect upon the skin is to whiten it. It may even produce a blister, accompanied by itching. It is a remarkable oxidising agent, and is particularly valuable for bleaching ostrich feathers, hair, ivory, silk, wool, teeth, &c. It is also antiseptic and disinfectant.

When a bone is placed in this liquid, what appears to be effervescence takes place. The bone soon becomes covered with bubbles of oxygen, and subsequently a film gathers upon the surface. It is advisable to remove this film carefully with a knife, because it is of a greasy nature; and after its removal the peroxide of hydrogen is allowed to take a grip of the bone. The bone being now replaced in the liquid, is allowed to remain until the requisite degree of whiteness is attained. In some cases, a few days will suffice (as in young bones); in other cases, three or four weeks may be required. Its ultimate effect is to render the bones perfectly free from smell, and of a pleasing white colour. It does not eat into the bone in the way that chloride of lime does. The liquid should never be raised to the boiling-point of water, becauses it then decomposes, with explosive violence, into oxygen and water. Young bones prepared in this way make beautiful preparations when subsequently mounted in a weak mixture of methylated spirits and water.

The cost of peroxide of hydrogen varies at different periods of the year. I have found it to be dearest about the pantomime season,

when it is largely used by theatricals for whitening their hair. It then costs 7s. 6d. per gallon. At present the cost is 5s. 6d.

When the bones are very greasy, the addition of a little dilute ammonia to the peroxide of hydrogen favours the cleaning process.

In illustration of the effects of this agent, I show the following specimens:—(1) mounted young radius; (2) interesting specimens of ossifying sternum; (3) a dried young humerus and ulna, in a glass jar; (4) lower end of adult fibula; (5) lumbar vertebra of hare.

PROCEEDINGS OF THE

ANATOMICAL SOCIETY OF GREAT BRITAIN AND IRELAND.

NOVEMBER 1892.

THE Sixth Annual General Meeting was held on Monday, November 21st, in the Court-Room of Guy's Hospital. Present—Sir W. TURNER, F.R.S., in the chair, and forty-three members and visitors.

The minutes of the previous meeting were read and confirmed. The following gentlemen were elected officers for the ensuing year:—*President*—Sir W. Turner, F.R.S. *Vice-Presidents*—John Curnow, M.D.; Alexander Macalister, F.R.S.; H. St John Brooks. *Treasurer*—G. B. Howes. *Secretaries*—Ambrose Birmingham, M.D. (Ireland); A. M. Paterson (Scotland); George Henry Makins (England). *Council*—Wm. Anderson; Stanley Boyd; D. J. Cunningham, F.R.S.; John Cleland, F.R.S.; L. A. Dunn, M.B.; Percy Flemming; Wardrop Griffith, M.D.; W. P. Herringham, M.D.; Alexander Hill, M.D.; Robert Howden, M.B.; C. B. Lockwood; R. Clement Lucas, M.S.; T. H. Openshaw, M.B., M.S.; R. W. Reid, M.D.; Arthur Robinson, M.D.; H. D. Rolleston, M.D.; J. Bland Sutton; Johnson Symington, M.D.; Arthur Thomson, M.B.; Bertram Windle.

Messrs H. J. WARING, M.B., B.S., F.R.C.S., and F. C. KEMPSON, B.A., were elected Members of the Society.

The following gentlemen were nominated for election at the next meeting:—James Musgrove, M.D., Demonstrator of Anatomy, University of Edinburgh, proposed by Sir W. Turner, F.R.S., W. Anderson, G. H. Makins; G. F. Blacker, M.B., B.S., F.R.C.S., Demonstrator of Anatomy, University College, London, proposed by G. D. Thane, Percy Flemming, T. W. P. Lawrence; E. Barclay Smith, M.B., proposed by A. Macalister, F.R.S., W. Anderson, G. H. Makins; A. F. Dixon, B.A., Demonstrator of Anatomy, University of Dublin,

proposed by D. J. Cunningham, F.R.S., H. St John Brooks, G. H. Makins; H. W. Lewis, M.R.C.S., L.R.C.P., House-Surgeon, Westminster Hospital, proposed by P. Macleod Yearsley, H. C. De Renzi, G. H. Makins; A. Keith, M.B., proposed by G. D. Thane, Percy Flemming, T. W. P. Lawrence; J. H. Targett, M.S., F.R.C.S., Pathological Curator, Hunterian Museum, proposed by C. Stewart, R. Clement Lucas, G. H. Makins.

The Treasurer's Report, showing a balance of £43, 0s. 9d. in favour of the Society, was adopted.

The Treasurer, in presenting his Annual Report, made the following remarks thereon. The actual sum received in subscriptions for the current year was £24, against an expenditure of £54, there being a considerable number of subscriptions yet to come in. The increased expenditure for the year was chiefly incurred in the better illustration of published papers, rendered possible by the recovery of subscriptions in arrear. Allowing for doubtful cases, the roll yielded a list of 110–115 reliable members, whose annual subscriptions promised an income of say £60. Adding this to the £43 in hand, he estimated the total income for the current year at £103. Of this sum, £40 would be required for the preparation of the manuscript index to the first twenty volumes of the *Journal of Anatomy and Physiology* which the Society had sanctioned, and which was now in an advanced stage towards completion for publication, leaving an available balance of £60, as opposed to an estimated ordinary expenditure of from £50 to £55. Assuming the non-diminution of members in the future, and the progressive recovery of subscriptions in arrear, the Society ought to be able to amply illustrate its forthcoming publications, and, he hoped, to accumulate a small amount for disposal as might be thought best. The preparation of farther indices to each of the volumes of the *Journal of Anatomy and Physiology*, subject to arrangement with its editors, had been already suggested as a possible undertaking.

Dr Curnow showed a *Divided left Parietal Bone* with a well-marked horizontal suture running from before backwards throughout its whole extent. The suture was dentated, and corresponded very nearly to the upper line of the temporal ridge. The various vertical measurements of the bone at the anterior and posterior edges, and at two intermediate points, were from before backwards, 5¼, 5¼, 5, and 4¼ inches from the extremity of the temporo-sphenoidal and parietal suture to the interparietal suture at equidistant parts of the bone, and the unusual suture was 2½, 2, 2½, and 2½ inches from its extreme lower edge. A wormian bone at the apex of the parieto-occipital fissure measured 1½ inches in breadth by ¾ of an inch in length. The other parietal bone showed no unusual variation. The two parietal bones and the occipital evidently belonged to the same skull, but no other bones could be obtained, as they were found in a casual collection.

Mr J. Bland Sutton exhibited a *Rudimentary Supernumerary Pollex.* A boy seven years old came under my notice with a small congenital prominence near the base of the metacarpal bone of the right pollex. It was about 2 cm. high, conical, and surmounted by a small nail. It was clear that this represented a suppressed supernumerary digit. The true pollex resembled a finger rather than a thumb, see figure 1. On removing the accessory thumb, I found it

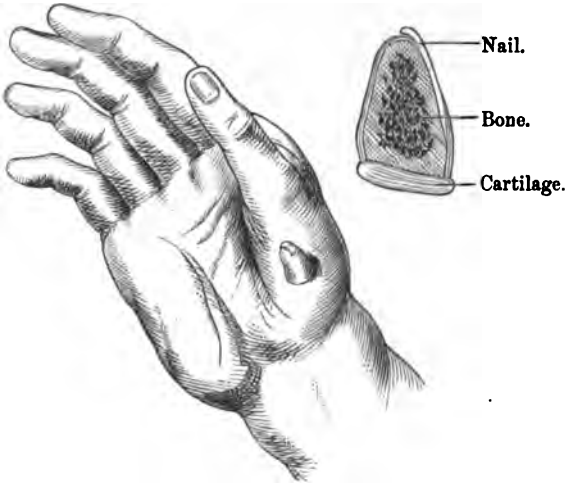

Fig. 1.

connected to the cartilage at the base of the first metacarpal; it also had a facet by which it articulated with the trapezium. On section this digit contained a conical piece of bone, with a broad basal epiphysial cartilage, whilst its summit was in relation with a nail.

The specimen is interesting, as it serves to show the uselessness of speculations regarding the supposed missing segment of the pollex, for in this case we have a supernumerary digit consisting of only one segment, which from its position, and especially its relation to the trapezium, must be regarded as a metacarpal, whilst its basal epiphysis and the terminal nail give it the characters of an ungual phalanx.

Professor Howes said this observation of Mr Sutton's was interesting, as a similar bone was found in a small flattened claw projecting from the inner side of the hallux in the tree porcupines.

Mr F. G. Parsons exhibited a specimen of an *Abnormal Rib in Hystrix cristata.* The shaft of the last rib on both sides was converted into a fibrous band, the head and cartilage at the extremity remaining normal. The bones were rickety, but several pathologists whose opinion had been taken agreed that rickets could not have produced this conversion of bone into fibrous tissue. The skeleton of another porcupine suffering from rickets was shown, in which the last rib presented the same change as the ones in front of it. As

Hystrix cristata has fifteen ribs, and, like other animals with a large number, is sometimes found with a rib short of its full complement, Mr Parsons thought that this specimen might show a stage in the process of losing a rib.

Mr T. W. P. LAWRENCE exhibited three *Human Fœtal Monsters*. The first is a double monster, presenting an incomplete division of the cranio-vertebral axis by posterior dichotomy (*duplicitas posterior*). The partially separated individuals have undergone equal development; they are both males (fig. 2). The monster has a single face, but

FIG. 2.

the back part of the head shows a commencing division, so that in addition to the right and left ears corresponding to the face when looked at from the front, an additional pair of ears, partly fused together, is present in the middle line behind. There is a single short, thick neck, the chin is very undeveloped and nearly on a level with the upper part of the thorax, and the structures lying in the anterior part of the neck have undergone much compression. The thoracic cavity is single, but composed of the parietes of two thoraces placed ventrally towards each other, and opened out along the median line of their sterna. There are four distinct upper limbs, each individual having one arm attached anteriorly and one posteriorly. The abdominal cavity is single as far down as the umbilical cord (which is single), but below that the cavity bifurcates in correspondence with the complete separation of the individuals below the level of the umbilicus. There are four well-developed lower limbs. The thoracic

organs are doubled (with the exception of the œsophagus), there being an anterior heart with apex to the left, and a posterior with apex to the right, and two pairs of lungs, both very small and undeveloped. The stomach is single and semilunar in shape, the concave border being upwards, and receiving in its middle the undivided œsophagus, the horns of the crescent corresponding to a right and a left fundus, and an undivided duodenum passing off from the middle of the convex border. The small intestine is single as far as the point of attachment of a small Meckel's diverticulum, below which the bowel bifurcates in correspondence with the bifurcation of the lower part of the trunk. There are two livers and two spleens. The vertebral column is doubled throughout its length, so that the internal base of the common cranial cavity presents two occipital fossæ and two foramina magna, from which two basilar grooves pass forward each to a corresponding dorsum sellæ. Beyond this point the cranial base is undivided, the pituitary and anterior fossæ being single. The brain has not been preserved. The deformity is rendered intelligible upon the supposition that the epiblastic axis of the medullary groove of the embryonic area has undergone division from behind forwards as far as the anterior extremity of the notochord,

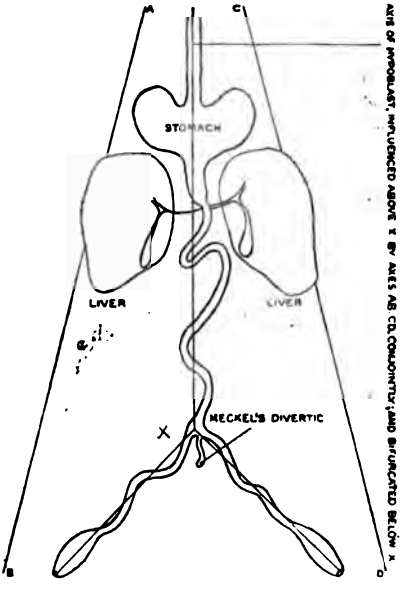

FIG. 3.

remaining single anterior to that point. Upon closure of the medullary laminæ, there will thus have been formed a simple anterior portion of cranial cavity, a compound posterior portion, and two distinct and separate spinal canals. Further, as the epiblast at the two caudal poles of the embryo became folded round for the formation

of the intestinal tube, in consequence of this folding taking place round two axes, the intermediate part of the subjacent hypoblast has been divided as far forwards as the process of folding has extended, viz., to the insertion of the vitelline duct. Anterior to this point the intestine is single; but the two axes (ab. cd. fig. 3) of the embryo have exercised their own proper and distinct formative influence on this part of the alimentary tract, so that a bilaterally symmetrical arrangement has resulted, and while those parts which are already median and symmetrical (*e.g.*, the small bowel and œsophagus) appear to be unmodified, those which are asymmetrical and more or less laterally placed (*e.g.*, the fundus of the stomach, the liver and the lungs) have been brought into symmetry by duplication.

The second monster (a female of about the sixth month) is an example of *agnathia*, with the same external appearance as the case figured in Förster's *Die Missbildungen des Menschen*, Taf. xiii. The lower part of the face formed by the prominence of the chin and the base of the jaw is absent, the buccal cavity being closed in below by a smooth surface of skin continuous with the cheeks, and lying close up against the hard palate. The mouth is a vertical slit one-fourth of an inch in length, bounded almost entirely by the folding round of the upper lip. Owing to the defective development of the lower jaw, the lower part of the ears have fallen towards each other in the middle line, so that there is not more than an inch between the external meatuses (*synotia*). Water can be injected through the meatus into the buccal cavity, showing that the membranous septum which, as it is now thought, closes the first visceral cleft, is absent in this case. A slight groove between the meatuses runs across the front of the neck in the apex of the retiring angle formed by the anterior surface of the neck and what would normally be the under surface of the chin; this angle is higher up in the neck than usual, and its apex marks the position of a small bony arch lying deeply against the cervical vertebræ. This represents the lower jaw; its thickness is about 2 millimetres, its length about 12 mm., and it is arched with the convexity forwards. Behind it is the alimentary tube, stenosed, but not obliterated; and lying attached to the interior wall of the tube below the inferior maxilla is the tongue, with its long axis vertical, and its tip a quarter of an inch below the bone. Below the tongue, and rather more than an inch below the inferior maxilla, is a fairly well-developed hyoid bone. The soft palate and uvula are cleft, the hard palate is complete. In addition to these deformities, the fœtus presents complete transposition of the thoracic and abdominal viscera; a duct of Cuvier is present on each side through persistence of the proximal parts of the left primitive jugular and cardinal veins; and the apex of the heart is slightly bifid.

The condition present is, therefore, an arrested development of the first visceral arch of the embryo. This may be described as due to partial agenesia; but the association of transposition of viscera, with the agnathous condition, suggests another explanation. The former abnormality is admitted to arise through duplication of the embryo;

d if such a case as the double monster before described be con-
lered, it will be evident that, supposing the posterior dichotomy
be more complete than in that case, the final point of adhesion of the
tuses will be in the region of the upper or anterior part of the
egut. If at the same time the two embryos develop equally,
ere will be much compression of the parts in this region (as in the
st described specimen), and the development of the chin and parts
out it may be permanently retarded. Upon this view an agnathous
tus may be regarded as sometimes due to a posterior dichotomy,
ich has ultimately become a complete separation, and in which
e two fœtuses have developed equally during a considerable part of
tra-uterine life.

The third specimen presented typical abnormal fissures about the
e and palate, due to amniotic adhesions.

A short discussion took place, in which Professor THANE concurred
the view that the first and second branchial clefts were open at
me period of development.

Mr BLAND SUTTON said the clefts were certainly open at some
riod, and stated that he had seen milk swallowed by an infant
cape by a branchial fistula in the neck.

Mr STANLEY BOYD quoted the following observation of Professor
ueter:[1]—"The fistula may end blindly at its inner extremity or
ay open into the pharynx, as may be shown by escape of coloured
uids swallowed, and by the discharge of mucus when pharyngitis
curs. In a young fellow who wished to become a trumpeter, I
ssected out one of these fistulous tracks, following it between the
o carotids to the pharyngeal cavity.

Professor MACALISTER, F.R.S., read papers on the *Acromion Process*,
d on the *First Costovertebral Joint*, which will be found *in extenso*
the body of the *Journal of Anatomy and Physiology*, pp. 245–251.

Mr ARTHUR THOMSON made a preliminary communication *in regard
the Development of the Epidermic Layers of the Skin.* He contro-
rted the accepted view with regard to the regeneration of these
yers, and maintained that the stratum granulosum and stratum
cidum were the germinal layers, the lucidum developing into the
rny layer on the one hand, the granulosum into the mucous on
e other, a mode of growth precisely analogous to the growth the
rk-cambium. Mr Thomson supported his views by a reference to—
) the evidence of cell division in the stratum granulosum; (2) em-
yological evidence; (3) healing of ulcers; (4) skin grafting; (5)
thological evidence. The reader of the paper then dwelt on the
plication of his view to the question of pigmentation, showing how,
cepting his view to be correct, it was no longer necessary to explain
e disappearance of the pigment in the superficial layers of the
idermis as due to some chemical change, for, according to Mr
homson's view, the cells which contain the pigment in the deeper

[1] Hüter, *Grundriss der Chirurgie*, vol. ii. p. 328, 1st edit., 1882.

layers of the mucosum are the oldest cells of that layer, and do advance towards the surface.

He also demonstrated the application of his views to hair gro showing how the cells containing the pigment in the hair were d whilst the corresponding pigmented cells in the rete mucosum remai and in this way offered a ready explanation of how it is that in negro the hair may become colourless, whilst the skin still retai characteristic tint.

A paper on the *Delimitation of the Regions of the Abdomen* Prof. D. J. CUNNINGHAM, F.R.S., was referred to the Committee considering the subject, and will be found *in extenso* in the bo the *Journal of Anatomy and Physiology*, p. 257.

Mr THOS. CARWARDINE read a paper on the *Suprasternal Bo Man*, which is printed *in extenso* at p. 232 of the *Journal of Ana and Physiology*.

PROCEEDINGS OF THE

ANATOMICAL SOCIETY OF GREAT BRITAIN AND IRELAND.

FEBRUARY 1893.

THE Second Quarterly Meeting of the Session was held on Monday, February 27th, in the Library of Charing Cross Hospital Medical School. Present—Sir W. TURNER, F.R.S., in the chair, and thirty-eight members and visitors.

The minutes of the previous meeting were read and confirmed.

Messrs JAMES MUSGROVE, M.D.; G. F. BLACKER, M.B., B.S., F.R.C.S.; E. BARCLAY SMITH, M.B.; H. W. LEWIS, M.R.C.S., L.R.C.P.; A. KEITH, M.B.; A. F. DIXON, B.A.; and J. H. TARGETT, M.S., were elected Members of the Society.

The following candidates were nominated for election at the next meeting:—C. P. White, B.A., St Bartholomew's Hospital, proposed by W. H. Jessop, W. P. Herringham, and C. B. Lockwood; W. Macadam Eccles, M.B., B.S., F.R.C.S., Assistant Demonstrator of Anatomy, St Bartholomew's Hospital, proposed by C. B. Lockwood, W. P. Herringham, and G. H. Makins.

Sir WILLIAM TURNER exhibited a *Human Heart with Moderator Bands in the left ventricle.* On opening the *left* ventricle the inner surface was seen to be almost uniformly smooth. The carneæ columnæ were limited to the apex and to a narrow strip near the border of the septum, where, however, they were only faint elevations. A distinct though slender moderator band 55 mm. long arose from the septum 11 mm. distant from its left border, and 67 mm. from the apex. It possessed a major and two subsidiary attachments to the septum, and then passing across the cavity, ended in the posterior wall of the ventricle about midway between the base and apex. A second band 31 mm. long arose 20 mm. lower down from the septal wall, and lying in contact with, but distinct from, that wall, it fused with the posterior wall of the ventricle close to where it joined the right border of the septum. This second band was connected with the one first described by an oblique intermediate communication. The widest part of these

bands was not more than 2 mm., but each band obviously consisted of muscular fibres surrounded by endo-cardium. A third band, not thicker than a piece of silk thread, and apparently consisting only of endo-cardium, was attached by one end to the septal wall 17 mm. above the band first described, and by the other end to the posterior wall in line with but 11 mm. above the place of attachment of the second band. The interior of the cavity of the *right* ventricle showed a similar smoothness and absence of carneæ columnæ to that described on the left side. A large papillary muscle arose from the anterior ventricular wall, and a moderator band 26 mm. long and 3 mm. thick passed across the ventricle from the base of the anterior papillary muscle to the septal wall.

Mr STANLEY BOYD showed a *Case of left Superior Cava without transposition of viscera.* This abnormality is shown on account of its rarity. Professor Thane has given me a list of six references—all with which he is acquainted; and I append it to this description.

The specimen was found by Mr Percy Flemming in a fœtus which was being dissected in the Anatomical Room at the London School for Women. Unfortunately, before the peculiarity was noticed a good deal of dissection of the neck, axilla, and thorax had been

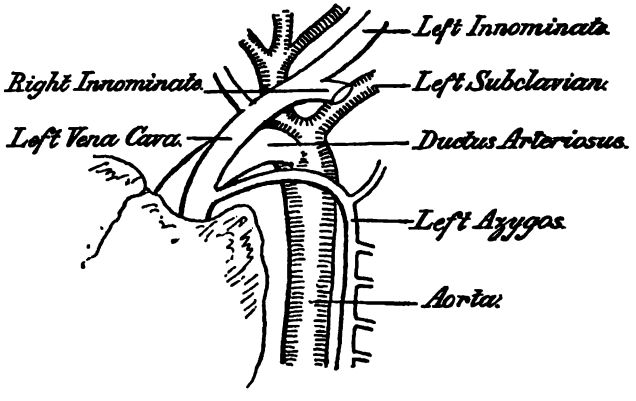

FIG. 1.

carried out, with the result that wounds and divisions of the tributary veins were so numerous as to render examination difficult and injection impossible.

Starting from the heart, we find that the opening of the coronary sinus is very large—the largest opening into the auricle. There is little sign of a Thebesian valve. There is no opening or trace of one where the V. cava superior usually enters. The other openings are normal.

The *left cava* runs obliquely up and to the left between the left auricle and ventricle and the left auricle and the root of the lung;

it ascends in front of the ductus arteriosus and aortic arch, and there divides into right and left innominate veins. The *left innominate vein* is short, almost vertical, and is formed by a large *left internal jugular* and *left subclavian;* on this side no *external jugular* was found, but it may have been completely cut away; a *posterior external jugular* is present. The *right innominate vein* is long, and takes an oblique course down and to the left behind the manubrium. It is formed by a small *internal jugular* uniting with the *right subclavian* at the usual

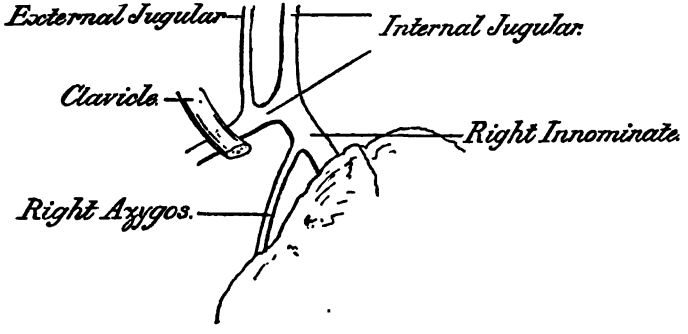

FIG. 2.

place; and on this side a well-developed *external jugular* descends beneath the omohyoid to join the subclavian outside the sternomastoid.

The *right innominate* receives the *R. inferior thyroid vein;* but the *left inferior thyroid* opens quite high into the *internal jugular.*

As to the *azygos veins*—they are of about equal size on the two sides. The *right azygos* opens into the right innominate not far from its commencement. The *left azygos* opens into the left cava immediately above the root of the left lung.

No trace of *right superior cava* or *duct of Cuvier* was found.

Left Superior Vena Cava.

1. Halbertsma, in a Dutch Journal, 1862 (?).
2. W. S. Greenfield, *Path. Trans.*, xxvii., 1876.
3. W. Gruber, *Virchow's Archiv.*, lxxxi., 1880.
4. Weigert, *Virchow's Archiv.*, lxxxiv., 1881.
5. J. J. Charles, *Jour. Anat.*, xxiii., 1889.
6. Bédard, *Bull. Soc. d'Anthropologie de Paris*, 1892.

Mr STANLEY BOYD showed *a Right Parietal Bone with a Horizontal Suture in it.* The parietal bones were from an adult male skull. The right one had on its outer surface a groove, starting behind about half an inch above the articulation with the lateral angle of the occipital running upwards and forwards—at first close to and then rising above the temporal line. Well-marked behind, the grooves gradually died away an inch from the anterior border, slightly above

the middle. Irregularities in the floor show that a suture existed along this groove. On the inner surface, corresponding to the posterior inch of the groove, is a fine fissure.

Professor WINDLE showed an example of an *Elongated and Bifid Clitoris.*

This specimen was taken from the body of a dissecting-room subject which presented no other noticeable characteristics. The clitoris, which is cleft to its base, is much longer than usual, measuring about 5 cm. The right half is somewhat less than half the thickness of the left, and this disparity is particularly noticeable in the antero-posterior direction, since the left portion extends further towards the vestibulum than the right. Both portions emerge from under the preputium clitoridis, to the sides of which they are connected, and both terminate in enlargements like a glans. Both were connected with the corpora cavernosa.

Bifid clitoris is known as existing in connection with epispadias, but it is unusal independent of this condition. It is not mentioned by either Förster or Ahlfeld. St Hilaire says that he was only acquainted with one case described by Arnauld. Another is given by Henle, who speaks of it as very rare, where the clitoris was bifid, the halves joining the nymphæ on either side.

Professor A. M. PATERSON showed some *Anomalies in the Skeleton of a Negro.*

In the skeleton of an American Negro sailor, aged 20, the following abnormalities occur :—

(1) In the right carpus there are only seven bones, the semilunar and cuneiform being fused. There is no indication of inflammatory

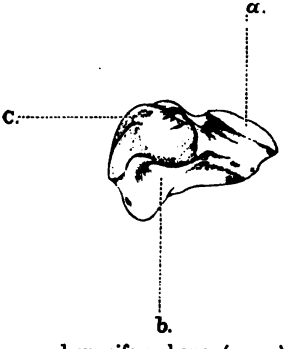

FIG. 1.—Fusion of semilunar and cuneiform bones (negro). *a.* Facet for pisiform; *b.* Surface for os magnum and unciform ; *c.* Surface for scaphoid.

action, and the bones of the left carpus are normal in character and arrangement. Humphry [1] states that in the Museum of the Jardin

[1] *Human Skeleton* (note, p. 397).

des Plantes is a negro skeleton showing a similar fusion of the same carpal bones.

(2) The manubrium of the sternum is elongated, and articulates with the mesosternum at the level of the third costal cartilages. The ensiform cartilage is almost completely ossified. The length of the manubrium is equal to that of the mesosternum (two and a half inches). The ribs are normal in number and arrangement, except in relation to the sternum. There are seven sternal ribs on each side, of which two and a half articulate with the first piece, four and a half with the second piece of the sternum.

The cause of this condition is to a certain extent obscure. It is not unfrequent. It is apparently the normal condition in the Gibbon,

FIG. 1.—Sternum of Negro.

and Dr Keith informs me that he has found it in six out of twelve sterna of the Gorilla examined by him, but more rarely in the Orang and Chimpanzee.

(3) The sacrum is remarkably asymmetrical. The first sacral vertebra, which is not fused with the second, is lumbo-sacral in character: it possesses a free and separate transverse process on the right side. The ala on the left side is adherent to the second vertebra, and was closely adherent to the ilium also, by fibrous attachment. The sixth sacral vertebra is sacro-coccygeal: sacral on the right, coccygeal on the *left side*. The other portions of the vertebral column

are normal; there being 7 cervical, 12 thoracic, 5 lumbar, and 4 coccygeal vertebræ; in all, 34 vertebræ.

The interest of this case arises from the existence of two anomalies in one and the same sacrum. Out of 266 sacra recently examined, it is the only one possessing at the same time a lumbo-sacral and a sacro-coccygeal vertebra. Its interest is enhanced on account of the concomitant variation in the arrangement of the lumbo-sacral plexus.

Normally the *N. furcalis* in Man is the fourth lumbar, the twenty-fourth spinal nerve; and as in females generally, the last lumbar nerve but one.

In this instance the *N. furcalis* is the fifth lumbar nerve (twenty-fifth spinal nerve) on both sides, limiting the junction of lumbar and sacral portions of the plexus. The *N. bigeminus* was on the right side the second, on the left the third sacral nerve, in both cases the twenty-eighth spinal nerve; it bounded the lower end of the great sciatic (internal popliteal) nerve.

The double variation in the right side, and the abnormal position of the iliac attachment and of the N. furcalis, have caused the plexus-arrangement to assume an apparently normal relation to the bones,—so that the N. furcalis becomes the last lumbar nerve but one.

This sacrum may thus be regarded as an illustration of an "ancestral" condition (Rosenberg), or (I think more probably) of "individual variation," owing to the development of the lower limb-form, and its adhesion to vertebral segments being more postaxial than usual.

Mr E. Barclay Smith showed some *Muscular Anomalies, with notes on the Origin and Function of the Ligamentum Posticum Winslowii.*

Within a short period there have been three remarkable cases of muscular anomaly noted in the Cambridge University Dissecting-room, all of which, I think, are of sufficient rarity to be placed on record.

The first case, which was noted by Professor Macalister, was one of complete absence of the extensor indicis. The record of the anomalies of this small muscle show that it is a remarkably constant one, and is more subject to anomaly in excess than in deficiency, often sending tendinous slips to adjacent digits. In this case there was no trace whatever of the muscle; the lower end of the ulna and interosseous membrane for a distance of 4·5 cm. below the origin of the extensor longus pollicis (ext. sec. internod.) being completely free from muscular attachment. The neighbouring muscles showed no variations, the thumb extensors being well marked, the index finger tendon of the extensor communis was distinct from the rest of the muscle, about 6 cm. above the post. annular ligament, and was inserted normally.

The absence of this muscle has, according to Macalister, been noted by Cheselden in two instances (*Cheselden's Anat.*, 2nd ed., 1722, p. 84), and also by Moser. It has been recorded by Luschka, and Testut has found it in a tendinous condition throughout.

The next case, which was noted by myself on the same day, was one of complete absence of the semi-membranosus. On reference to Macalister's work on *Muscular Anomalies*, I find that this condition has been placed on record by Loschge, *Abhandlungen der Phys. Med. Soc. Erlangen*, and by De Louza, *Gazette Medicale de Paris*, 1885. In vol. xviii. of the *Journal of Anatomy and Physiology*, Symington has recorded a remarkable case where this muscle was absent on both sides in a woman, and he notes that Loschge's case was not one of complete absence, but a rudimentary condition of the muscle represented by a tendinous band from the tuber ischii to the int. tuberosity (condyle?) of the femur, containing a small muscle belly (*Luschka Die Anat. der Glieden des Menschen*, p. 412). W. Turner, in the same volume of *the Journal*, records a case where it was replaced by a thin tendon from the tuber to the int. condyle on both sides in an old woman.

From the above it appears that the complete absence of the muscle is an exceedingly rare condition.

In my own case, the limb had unfortunately been severed from the trunk, the hamstrings having been cut *en masse*, about 10 cm. from their origin. On carefully examining the short tags attached to the tuber ischii, I found that the biceps and semi-tendinosus were disposed in their usual manner, but on their deep aspect was a fine tendinous cord about 8 cm. long, 1 cm. broad, and ·15 cm. thick, apparently attached to the upper and outer part of the tuber, from which it passed very obliquely downwards and inwards, and its fibres eventually spread out and became lost in the fascia on the posterior surface of the adductor magnus. There was no vestige of any muscular fibres in connection with it. This small band may possibly have been the representative of the absent muscle. The two hamstring muscles present were normally disposed, the semi-tendinosus perhaps being of a rather larger size than usual, in comparison with the other muscles in the limb.

One of the chief points of interest in such an anomaly is the condition of the ligamentous structures on the posterior aspect of the knee joint. These were carefully dissected, and the ligamentum posticum Winslowii was found to be as strong and as well defined a structure as if the muscle had been present. The fibres were continuous with the posterior edge of the int. lateral ligament, being attached below to the int. tuberosity of the tibia, from which they passed upwards and outwards to the ext. condyle. In the case of double absence of the SM. recorded by Symington, that observer also found that the ligamentum posticum was normally disposed.

This oblique band has hitherto been considered as being solely a derivative of the tendon of the semi-membranosus, the external condyle being presumed to be one of the bony points of insertion of the muscle. It has consequently been quoted as one of the large class of "Accessory Ligaments" to a capsule, which in some instances, as in the case of the vasti on the front of the joint, are derived from tendinous expansions; the true capsule being supposed to be repre-

sented posteriorly by a few scattered vertical fibres found on a deeper plane. But from the muscular conditions in this instance, it may be justifiable to draw the conclusion that the ligamentum posticum may have some other origin.

I should venture to suggest the following possible sources of origin of this band.

Firstly. That it represents an original tendon of insertion of the semi-membranosus into the external condyle; this I think may be at once dismissed as an untenable supposition, on the following grounds. On examining the history of the muscle and its condition in lower animals, the semi-membranosus is remarkable for the internal disposition which it maintains, being closely associated with, and often with difficulty separable from, the adductor magnus. Also the presence of the oblique band in a well-marked condition in the complete absence of the muscle, would serve to disassociate it as an integral part of the semi-membranosus.

Secondly. That it is the degraded remnant of some muscle, now rendered functionless. On examining a knee joint a few days ago with reference to this particular ligament, I was surprised to find a muscular band occupying its usual position, arising by a rounded

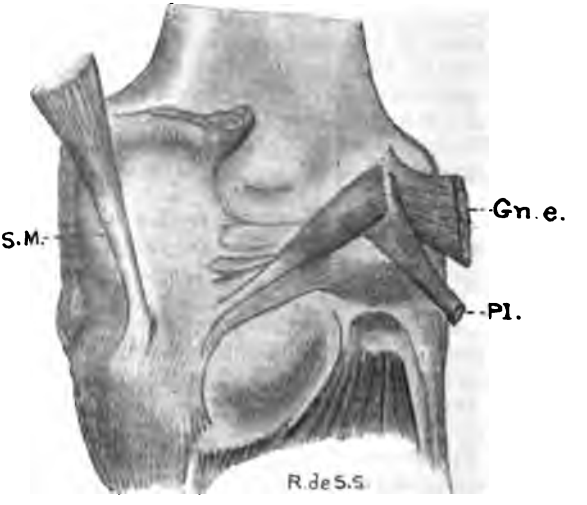

FIG. 1.—Abnormal muscle overlying the Ligamentum Posticum Winslowii.

S.M. Tendon of Semi-membranosus. | *Pl.* Plantaris.
Gn. e. Ext. head of Gastrocnemius.

tendon from the ext. condyle, close to the inner side of the plantaris, which expanded into a well-defined muscle belly, and inserted by a tendon which blended with the vertical band of the semi-membranosus tendon, and was inserted with it on to the tibia (fig. 1). This

must be an exceedingly rare muscle. Macalister has only once seen it, more than twenty-two years ago, and I have found no other record of it. It is of interest, as from its attachments it may have some possible homological relationship to the pronator radii teres in the upper limb.

On lifting this muscle from its bed, the glistening fibres of the ligamentum posticum were found to be apparently normally disposed, it thus being evident that they were not replaced by the muscle.

Thirdly. That it is a part of the true capsule of the knee joint, whose fibres have suffered an alteration in direction from a relative displacement in position of the external condyle and the inner part of the upper end of the tibia, and which has in some way become connected with the tendon of the semi-membranosus.

Fourthly. That it is an acquired attachment of the semi-membranosus, due to the dragging off of a part of the connective tissue sheath of the muscle, which at one period in its history was in close relation to the external condyle, but which, from a displacement in position of the bony parts, has now become separated from it by a considerable interval; and has acquired a new attachment in the same way as the rectus femoris has to the ant. inf. spine of the ilium.

Fifthly. That it is due to the thickening of a fascial layer directly continuous with the sheath of the semi-membranosus, and lying super

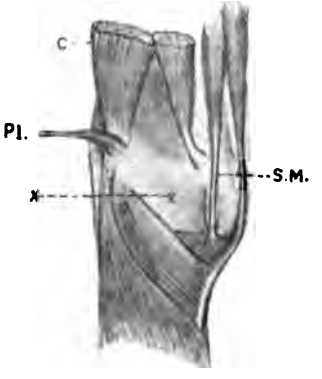

FIG. 2.—Dissection of the Posterior aspect of a Fœtal Knee.

G. Gastrocnemius cut and reflected upwards.
Pl. Plantaris ditto.
S.M. Semi-membranosus tendon lying within its bed of lax tissue.
x. Loose tissue at the back of the Joint.

ficially to the true capsule, which for some reason has become especially strong, and has had an obliquity given to its fibres.

I am inclined to support this last supposition on the following grounds:—

On examining the condition of the structures at the back of the knee in several fœtal joints, I failed to find any definite evidence of well-

marked oblique fibres. A soft, lax tissue underlies and partially embeds the popliteal vessels and the plantaris muscle, which is relatively large at this early stage; and this lax tissue appears to ensheathe the semi-membranosus tendon, which has a very definite inner margin; and no fibres appear to pass from the tendon itself towards the external condyle (fig. 2).

I have dissected an adult joint in which the ligamentum posticum is rather a weaker structure than is usually the case, and most of its fibres are not directly continuous with those of the tendon of the

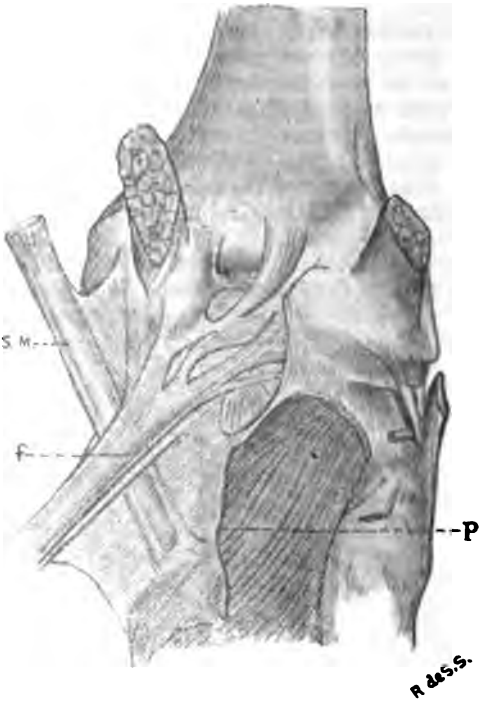

FIG. 3.—Dissection of an Adult Knee, showing the fibres of the Ligamentum Posticum sweeping superficially to the tendon of the Semi-membranosus, and blending with aspect of fascia on the further side.

S.M. Semi-membranosus Tendon.
F. Fibres of Ligamentum Posticum superficial to S.M. tendon.
P. Cut edge of Fascia covering Popliteus.

semi-membranosus, but are separable from them, crossing their direction obliquely, and blending into a single sheet on the other side of the tendon (fig. 3).

The sheet of fibres forming the ligamentum posticum is directly

ntinuous with, and merges into, the fascia covering the popliteus, hich I should suggest is additional evidence in favour of its fascial rigin.

The causes which have brought about the great strengthening and ie oblique arrangement of such a fascial layer may be thus ummarised.

The ligamentum posticum has attained its greatest development nd strength in Man: it becomes progressively more marked as the ipedal position is assumed, and is thus correlated with the erect ttitude.

The bones about the knee joint have undergone a considerable ateral expansion in assuming the bipedal position, the joint in the uadrupeds having a much greater antero-posterior diameter in omparison with the Anthropoids. This lateral expansion would end to diminish the efficacy of the posterior part of the capsule, nd an accessory ligament has become a necessity in order to sup-ort it.

Another reason for its great strength in the human knee is that Man lone of all the animal series has a perfectly extended knee joint,—in ll other animals the joint is in a position of some degree of flexion. With an increase in the amount of extension, there will be a corre-pondingly increasing need for strong ligamentous structures on the osterior aspect of the joint. Further, in the fully extended position, he line of the body-weight falling in front of the axis of movement at he knee joint, it will tend to over-extend the joint, and a strong igamentum posticum will help to resist this tendency.

In examining the position of the lower limb in the fœtus, it is seen hat there is a considerable flexion at the knee joint with inversion of he foot, the tibia being in a position of inward rotation upon the emur: this position, like so many other fœtal characteristics, showing a resemblance to an animal type.

If the bones are placed in this position it will be seen that the external condyle and the inner part of the upper end of the tibia are relatively close to each other, and will be about in the same horizontal plane. When the limb is extended it is accompanied by an outward rotation of the tibia, and there will be thus an inward and downward displacement of the upper cord of the tibia, relatively to the external condyle, which will drag the fascial fibres in the same direction.

The relation of the ligamentum posticum to the semi-membranosus will perhaps partially account for the present position of that muscle. It is remarkable that the chief part of the fibres of its tendon curve forwards at their insertion to the groove on the tibia. This I take to be evidence that there has been a mutual dragging between the ligamentum posticum and the semi-membranosus, whereby the muscle has been dragged away from the adductor magnus with which it was originally so closely associated.

Functions of the Ligamentum Posticum.—From the direction of the fibres of the ligamentum posticum, it could almost be presumed that

it would help to limit external rotation of the tibia, or internal rotation of the femur, respectively.

I have investigated the subject by first noticing the amount of external rotation of the leg upon the thigh, which can be obtained when the thigh is firmly fixed and the joint is in a position of semi-flexion, and then repeating the experiment after the ligamentum posticum had been cut through, leaving the other ligaments about the joint intact. In the second case I was certainly able to obtain a greater degree of rotation than in the first.

This has led me to the conclusion that the ligamentum posticum has more importance than is usually assigned to it, and that its function chiefly comes into play when the knee is extended in assuming the erect attitude.

During the later stages of this movement the femur is rotating inwards on the tibia, and the ligamentum posticum will help both to limit the extension and the rotation, bringing them to a stop at the same time.

I beg to thank Professor Macalister for his kind suggestions and criticism, and Mr R. de S. Stawell, who was dissecting the leg on which the abnormal muscle was found, for his excellent drawings.

Mr W. S. Melsome showed cases of *Variation of the Sigmoid Flexure of the Colon.*

During the Michaelmas term of 1892, four remarkable variations of the descending and sigmoid portions of the colon were met with, which illustrate the limits of variation in different directions of this viscus.

1. In one instance the descending colon passed downwards in a deep recess posterior and external to the kidney, and becoming narrow as it crossed the brim of the pelvis, passed into that cavity, there being no well-marked loose fold in the left iliac fossa, and consequently no true sigmoid flexure. In this case there was a close contact of the back of the colon, for its whole extent, with the abdominal wall. In no place did the peritoneum cover more than three-quarters of the circumference of the intestine, and there was no intersigmoid pouch.

2. In a second instance the intersigmoid pouch was of very large size, the omega-loop of the colon being very large and thin.

3. The third example is one in which the omega-loop is much longer than is usual; a portion of it is situated in the right iliac fossa, extending into the place usually occupied by the cæcum, causing an upward displacement of the latter.

The terminal 4 cm. of the ileum lies behind the cæcum, and is flattened by the pressure of the latter. The length of the cæcum is about 4 cm.; the appendix is short, about 35 mm. long, and lies in the second commonest position (behind the ascending colon).

Owing to this rightward displacement of the lowest part of the sigmoid colon, the commencement of the rectum is in relation to the right instead of the left pelvic wall. There is a mesentery for this

upper portion as far as the lower border of the first sacral vertebra. The cause of this displacement is probably the enormous expansion of the sigmoid flexure. The intersigmoid pouch is not present as a special arrangement.

The fourth, and in some respects the most remarkable form, is one in which the sigmoid flexure was a very long double loop, the portion of whose omega-loop ascended as high as the re-entrant side of the splenic flexure. The transverse colon is short, but in its normal place, as far as the hepatic flexure; the ascending colon is directed from above downwards and to the left, the cæcum being placed to the left of the middle line, in contact with the lower limb of the omega-loop. This portion of the large intestine lay in the transverse mesocolon and crossed the duodenum. The jejunum and ileum project to the right of the cæcum, and the last coil of ileum passes into the cæcum below and to the right side. The cause of this seems to be some fœtal pathological adhesion between the cæcum and the lower end of the omega-loop.

Dr H. D. Rolleston showed *specimens of Livers with Anomalies in their lobulation.*

Fig. 1 represents a liver in which the right lobe is quite small, while the left is large, the normal relations of size between them being

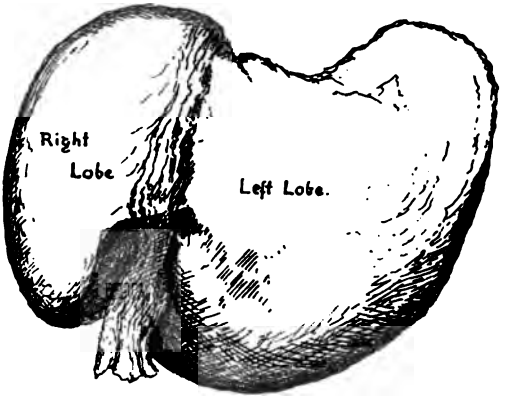

Fig. 1.

transposed. The gall-bladder was on the under surface of the right lobe, quite close to the right lateral border of the liver; the quadrate lobe was absolutely large, and was three times the size of the remainder of the under surface of the right lobe of the liver.

The relation of the hepatic artery, portal vein, and bile-duct in the lesser omentum was not determined before the liver was removed from the body.

The liver was in the normal position in the body, and there was no transposition of any of the viscera.

Figs. 2 and 3 are taken from two livers in which the left lobe was extremely small. The left lateral ligament was atrophied to a corresponding degree.

In both the gall-bladder is visible from the front, and projects from the left lateral margin of the liver.

In No. 3 the quadrate lobe was above the gall-bladder instead of being to the left of that structure; while the gall-bladder, instead of being in the long axis of the body, was at right angles to it. The whole

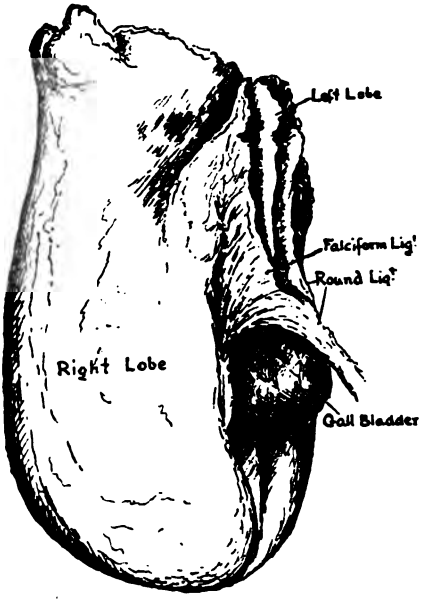

G.H.G. del.

FIG. 2.

of the left border of the liver seemed to have become shrivelled up and contracted towards the diaphragm. (The under surface is not shown in the figure.)

In No. 2 the gall-bladder was in the long axis of the body and the quadrate lobe was rudimentary, being represented by a small slip of liver tissue only.

The left division of the portal vein was of a fair size in No. 3, but in No. 2 it was very short, and soon became impervious to a medium-sized

probe. In neither of these two livers was there any gross pathological lesion to account for the abnormal condition of the left lobe, though

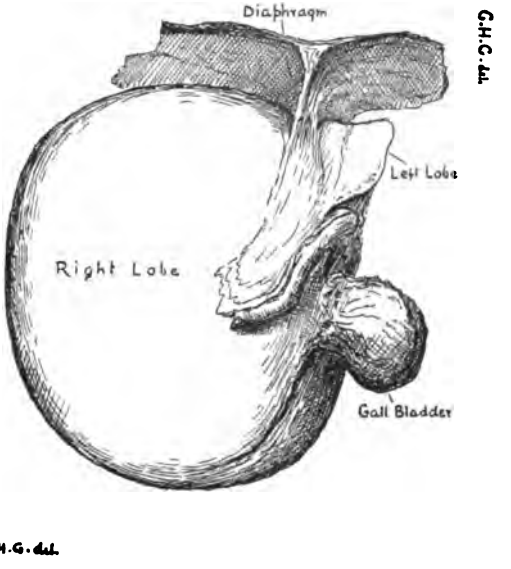

FIG. 3.

it is probable that some error in the vascular supply in fœtal life was the cause of the condition described.

For the accompanying drawings I am indebted to the skill of my friend Dr G. H. Goldsmith.

Mr HERBERT WATERHOUSE showed an *Atlas Vertebra with anomalous ossification*, taken from a male subject aged 75 years, in which the bone was in two symmetrical halves, united both in front and behind by ligamentous union. There was free movement allowed between the two halves of the bone. The anterior arch was deeper than usual, and the two segments of this arch were united by a strong ligamentous capsule, within which was a thin disc of fibro-cartilage. The union between the two halves of the bone posteriorly was more slender, there being only a narrow band of fibrous tissue connecting the two somewhat pointed bony ends. The axis and the occipital bone in the same subject were quite normal, and the only other noticeable point in the skeleton was that the larger joints manifested chronic rheumatic arthritic changes in a marked degree. Allusion was made to the developmental interpretation of this specimen, and it was considered that in this case the lateral mass and the half of the posterior arch of each side had been developed normally from the primary centre; that

there had been in addition two centres for the anterior arch, one for each half (the normal condition), but that the occasional separate centre for the rudimentary spine had been absent. The two halves of the anterior arch had failed to unite, and a similar non-union had occurred in the case of the segments of the posterior arch.

Professor MACALISTER remarked that he had two such specimens, one from an epileptic, and one from an epileptic lunatic; in the latter, movements of the head induced fits.

Mr ALFRED EICHHOLZ read a paper on the *Morphology of Lingual Arteries*, printed *in extenso* in *Journal of Anat. and Phys.*, April 1893, p. 377.

Mr J. JACKSON CLARKE read a paper on *The Temporal Bone, chiefly in Childhood*, printed *in extenso* in *Journal of Anat. and Phys.* April 1893, p. 411.

PROCEEDINGS OF THE

ANATOMICAL SOCIETY OF GREAT BRITAIN AND IRELAND.

MAY 1893.

THE Third Quarterly Meeting of the Session was held on Tuesday, May 23rd, at Westminster Hospital Medical School. Present—Sir W. TURNER, President, and twenty members and visitors.

The minutes of the previous meeting were read and confirmed.

The manuscript index to the first twenty volumes of the *Journal of Anatomy and Physiology* was presented to the meeting, and the Secretary was directed to deliver the same to the Editors of the *Journal*.

On the motion of Mr A. Thomson, seconded by Mr Bruce Clarke, a vote of thanks was unanimously accorded to the Honorary Treasurer, Professor Howes, for his exertions in arranging for the preparation of the index.

Messrs C. P. WHITE, B.A., and W. M'ADAM ECCLES, M.B., B.S., F.R.C.S., were elected members of the Society.

Mr C. GORDON BRODIE exhibited a specimen of *Misplaced Kidney, with Abnormal Arterial Supply.*

The accompanying specimen of kidney was taken from a dissecting-room subject early last winter. It is a right kidney, which, instead of occupying its normal position in the loin, was situated within the boundaries of the false pelvis; it rested upon the right psoas muscle, slightly overlapping it externally. Its upper edge was a little above the bifurcation of the aorta, and on a level with the crest of the ilium, the lower edge reaching down as far as the division of the common into internal and external iliacs. The lower part of its internal border was closely applied to the common iliac vessels.

The organ is slightly smaller than that on the left, and is irregular in shape, being more or less subdivided into lobes by slight sulci. This is most noticeable in front, where the surface is much broken up. There is no hilum, the ureter coming off from the anterior surface by five calices, which unite at the lower end of the organ to form the pelvis.

The arrangement of the vascular system was peculiar, there being three arteries entering and two veins leaving the kidney.

The arterial supply was derived—

1. By a large branch from the right side of the aorta, about three-quarters of an inch above its bifurcation, below the level of the inferior mesenteric, which passes down across the vena cava, and is distributed by three branches to the upper and back parts of the kidney, one branch running nearly to the centre in front before entering the kidney-substance.
2. By a branch which arose from the right common iliac just below the bifurcation of the aorta, and which, running diagonally across the posterior surface of the kidney, which it grooved, was distributed to the outer side of the organ.
3. By a branch which arose by the side of the middle sacral, and running over the left common iliac vein and right common iliac artery, was distributed to the lower and front portion of the kidney (its inner border).

The *two veins* had the following arrangement :—

1. The smaller of the two followed the course of the artery from the middle sacral, and emptied into the left common iliac vein.
2. The principal vein arose by three tributaries from the front of the organ and one from the outer side, and passed upwards to empty into the vena cava.

Remarks.—It is not uncommon to find two, three, or even more arteries coming off from the aorta and passing to a normal kidney, but it is unusual to find an artery arising from the common iliac artery, and running upwards to supply the lower part of the kidney-substance. During the past few years I have met with it about six or seven times, of which four were situated on the right, and two or three on the left,—in all cases the artery was a large one, and must have been a great accessory to the renal artery. In all the cases this abnormal vessel was given off just below the origin of the common iliacs, much in the same way as the second artery in the specimen.

The branch which arises with the middle sacral is, however, a far rarer one. This is the first specimen I have met with, and Professor Macalister, writing in 1883, states he had then only seen one example, although parallel instances are quoted by Otto, including one in which the middle sacral artery sent two branches, one to each kidney. In the same paper he also describes the arterial supply of a kidney which had six different arterial supplies—

One from just below the capsular artery.
„ the normal position.
„ below the origin of the inferior mesenteric.
„ the front and a little to the right of the bifurcation.
„ the sacra media.
„ the internal iliac.

"thus combining three of the rarest forms."

Mr E. Barclay Smith exhibited some *Examples of Separation of the Os styloideum of the 3rd Metacarpal*, from the Anatomical Museum of the University of Cambridge.

The metacarpal bone of the middle finger presents a remarkable contrast to the other bones of the same series in possessing a conical projection on the radial side of the dorsal aspect of the shaft, which fits into a retiring angle formed by the os magnum, trapezoid, and base of the metacarpal bone of the index finger. Owing to the occasional separation of this process of bone from the middle metacarpal, it has received the name of the Os styloideum. This occasional separation was investigated by the late Professor Gruber, and out of the 2589 hands which he examined he only found 19 cases (about ·7 per cent.), proving that it is by no means a common occurrence.

The separation from the metacarpal may be incomplete. The first specimen (fig. 1) exhibits a deep groove at base of the styloid process on the articular aspect of the bone, nearly completely separating its articular surface from the articular surface of the base of the metacarpal common to the os magnum and 2nd metacarpal.

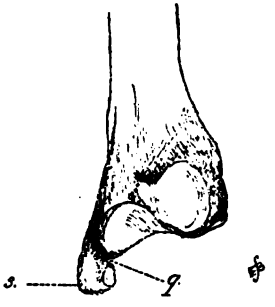

Fig. 1.—*s*, styloid process; *g*, groove.

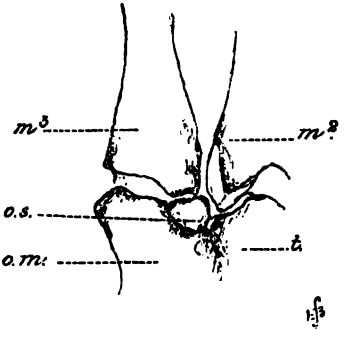

Fig. 2.—*o.s*, os styloideum; *o.m*, os magnum; *t*, trapezoid; m^2, second metacarpal; m^3, third metacarpal.

The articular surface of the styloid itself is divided into three distinct facets, one looking inwards for the os magnum, and two looking outwards, one for the base of the 2nd metacarpal, and one for the trapezoid. The articulation of the styloid process with the trapezoid, I believe, is more common than is usually thought to be the case.

When complete separation of the os styloideum from the metacarpal is met with, the separated bone may either form a new element in the carpus or it may fuse with the os magnum, the trapezoid, or the 2nd metacarpal.

Of the three latter cases fusion with the os magnum is by far the most common, and I have brought five examples.

The first example, which I found in an articulated hand sent to me by Eger of Vienna, is an exceedingly good one, to show how the os styloideum may become completely separated from the metacarpal

and only partially fuse with the magnum (fig. 2). The little nodule of bone which surmounts the magnum is marked by a deep groove at its base all the way round, and it would be difficult to say whether there was a real osseous union between them or not. The nodule exhibits three facets for articulating with the trapezoid, 2nd metacarpal, and 3rd metacarpal respectively, the latter being rough, so that this surface, which may be called the surface of separation, was probably bound to the 3rd metacarpal by firm fibrous bands.

The other four cases are examples of complete fusion with the os magnum, though in some of them there is a slight grooving at the line of attachment. One of these deserves particular interest, as it belongs to the hand of a native Australian, the condition being symmetrical on the two sides.

Examples of fusion with the trapezoid are of much rarer occurrence, and there is only one specimen of this condition in our Museum, which was found in a dissecting-room subject in 1890. The fusion in this case is a very complete one, and the process exhibits three facets for the os magnum, 2nd metacarpal, and 3rd metacarpal respectively, the latter as in the case above, and probably for the same reason.

Fusion of the os styloideum with the 2nd metacarpal must be of exceedingly rare occurrence, there only being one case on record. This unique specimen is now in the Strasburg Museum, and has been described by Professor Pfitzner.

The morphological value of this errant piece of bone is very obscure. Professor Leboucq of Gand has examined forty-five fœtal hands, and in four cases found a separate cartilaginous nodule in the usual situation of the os styloideum, so he considers that its occasional separation from the 3rd metacarpal is the persistence of an embryonic condition.

Mr Bland Sutton, in Morris' *Anatomy*, states that the 3rd metacarpal bone occasionally has an additional centre of ossification for the styloid process. In about twelve young hands which were examined by Professor Macalister and myself no trace of this additional centre could be found, so that its appearance is not a common one.

Mr Barclay Smith read for Professor Macalister an abstract of a paper on *The Development and Varieties of the Atlas*. The communication will be found *in extenso* in the body of the *Journal of Anatomy and Physiology*, p. 519.

Professor Howes read a paper *On the Pelvis of the Mammalia, with especial reference to that of a young Ornithorhynchus*. The paper will be found in the body of the *Journal of Anatomy and Physiology*, p. 543.

A wood block in illustration of Mr Stanley Boyd's *Case of Left Superior Cava without Transposition of the Viscera*, communicated to the February meeting of the Anatomical Society, which was received too late to be inserted in its place in the description published in the

April number of the *Journal of Anatomy and Physiology*, is now appended to the report of the *Proceedings* in the present number (see February *Proceedings*, p. xx).

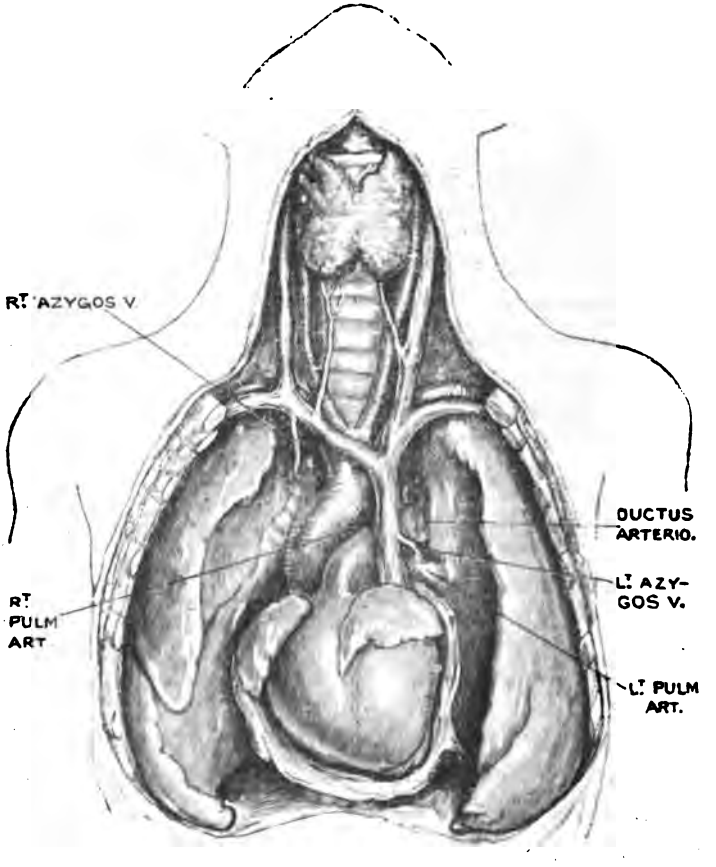

FIG. 3.

The following candidate was proposed for election at the next General Meeting:—H. W. M. Tims, M.D., C.M., Lecturer on Biology in the Westminster Hospital Medical School, nominated by James Black, Arthur Thomson, and G. H. Makins.

INDEX OF PROCEEDINGS OF ANATOMICAL SOCIETY.

ANKLE JOINT, viii.
Arteries, Left Vertebral, iv; Aorta, Branches of Abdominal, iv; of Limbs, xxxiv; Abnormal Renal, xxxvi.
Atlas Vertebra, xxxiii, xxxviii.

BIRMINGHAM, AMBROSE, Spina Bifida, viii; Heart, ix.
Bottles for Preparations, vii.
Boyd, Stanley, Left Superior Cava, xx, xxviii; Divided Parietal Bone, xxi.
Brodie, C. G., Misplaced Kidney, xxxv.
Buchanan, A. M., Lobulated Kidneys, vii; Glass Bottles for Preparations, vii; Peroxide of Hydrogen for Cleaning Bones, ix.

CARWARDINE, THOMAS, Suprasternal Bones, xviii.
Clarke, J. J., Temporal Bone, xxxiv.
Cleland, John, Ankle Joint, viii.
Clitoris Divided, xxii.
Cunningham, D. J., Regions of Abdomen, xviii.
Curnow, John, Divided Parietal Bone, xii.

EICHHOLZ, A., Limb Arteries, xxxiv.
Epidermis, xvii.

HEPBURN, DAVID, Diarthrodial Joints, ix.
Howes, G. B., Pelvis of Mammals, xxxviii.
Hydrogen, Peroxide of, ix.
Hystrix Cristata, Rib in, xiii.

ILEO-CÆCAL VALVE, ii.

KIDNEYS, Lobulated, vii.
Kidney, Misplaced, xxxv.
Knee Joint, iii., xxv.

LAWRENCE, T. W. P., Human Monsters, xiv.
Liver, Anomalies of, xxxi.

MACALISTER, ALEXANDER, Acromion Process, xvii; Costo-vertebral Joint, xvii; Atlas, xxxviii.
Metacarpal, Third, xxxvii.
Melsome, W. S., Sigmoid Flexure, xxx.
Muscular Anomalies, xxiv.
Moderator Bands, xix.
Monsters, Human, xiv.
Musgrove, James, Lantern Demonstration of Retina, viii; Costo-sternal Joints, ix.

NEGRO, Skeleton of, xxii.

OS STYLOIDEUM, xxxvii.

PAPILLARY MUSCLE, iii.
Parsons, F. G., Abnormal Rib, xiii.
Parietal Bone, Divided, xii, xxi.
Paterson, A. M., Carpus, xxii; Sternum, xxiii; Sacrum, xxiii.
Pollex, Supernumerary, xiii.

RIB, Abnormal, xiii.
Roedeer, Antlers of, ii.
Rolleston, H. D., Liver, Anomalies of, xxxi.

SIGMOID FLEXURE, Variation of, xxx.
Skin, Epidermic Layer of, xviii.
Smith, E. Barclay, Knee Joint and Muscular Anomalies, xxiv; Os Styloideum, xxxvii.
Spina Bifida, viii.
Struthers, John, Knee Joint, iii; Long Flexors of Toes, iv; Left Vertebral Artery, iv; Branches of Abdominal Aorta, iv; Double Ureter, vi; Common Iliac Veins and Inferior Cava, vi; Vena Porta and Vena Cava, vi.
Sutton, J. Bland, Supernumerary Pollex, xiii.
Symington, J., Ileo-Cæcal Valve, ii; Anterior Papillary Muscle, iii.

TATTOOED SKIN, ii.
Thomson, Arthur, Epidermic Layers, xvii.
Toes, Long Flexors of, iv.
Turner, Sir W., Antlers of Roedeer, ii; Tattooed Skin, ii; Transposition of Viscera, ii; Moderator Bands in Left Ventricle, xix.

URETER, Double, vi.

VEINS, Common Iliac, vi; Inferior Cava, vi; Vena Porta, vi; Left Superior Cava, xx.
Viscera, Transposition of, ii.

WATERHOUSE, HERBERT, Atlas Vertebra, xxxiii.
Windle, B. C. A., Divided Clitoris, xxii.

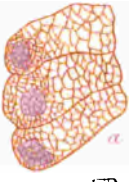

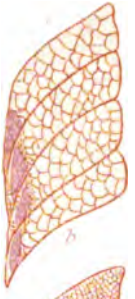

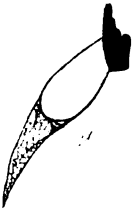

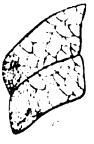

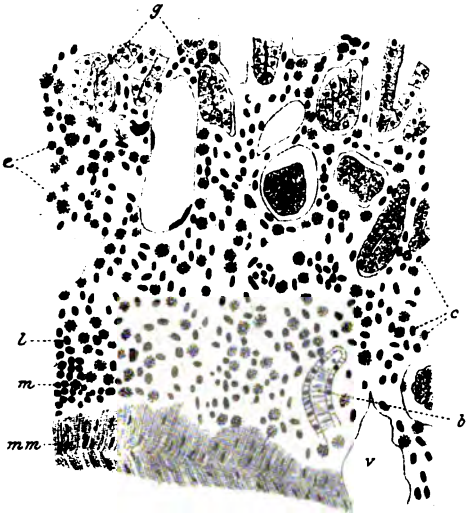

Fig. 3.

Fig. 1.

Fig. 2.

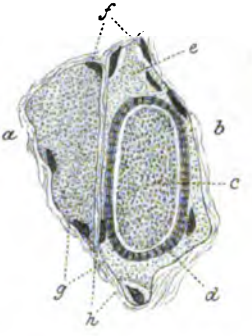

Fig. 4.

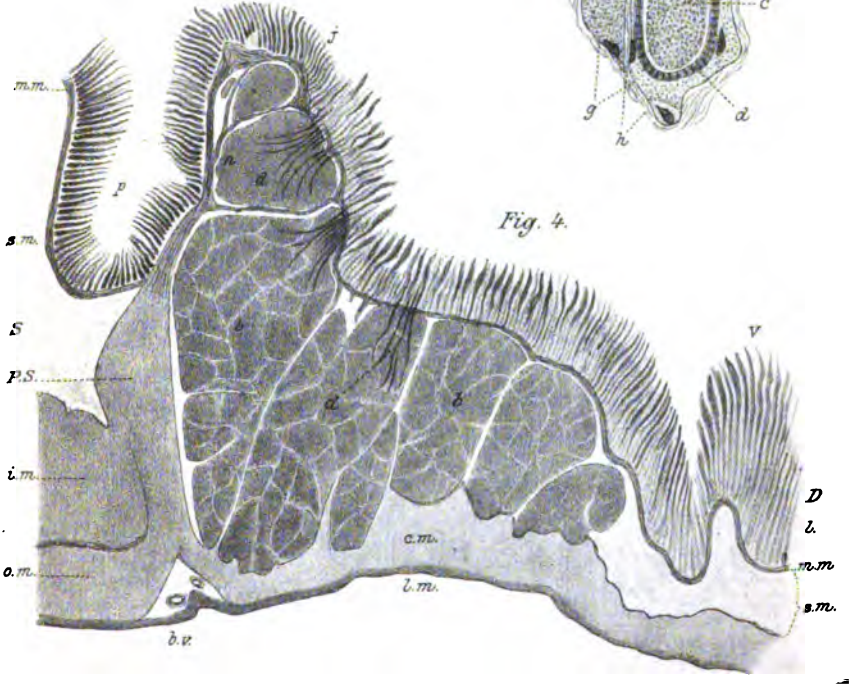

J. T. Murray del.

F Huth, Lith^r E

Fig. 2.

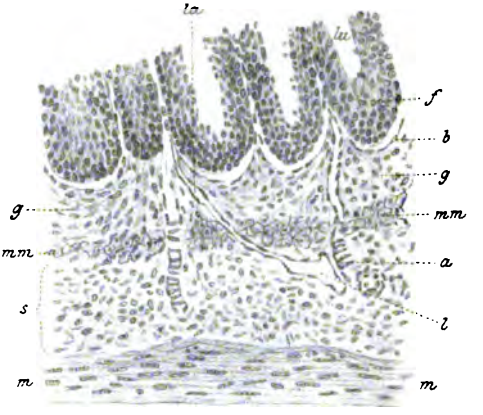

Fig. 1.

Fig. 3.

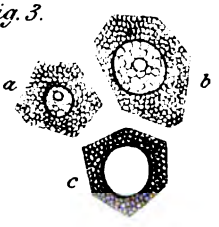

Fig. 4.

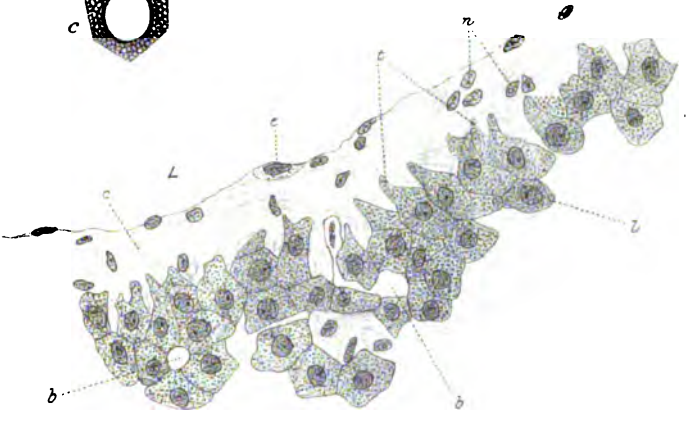

Fig. 5.



Fig. 1.

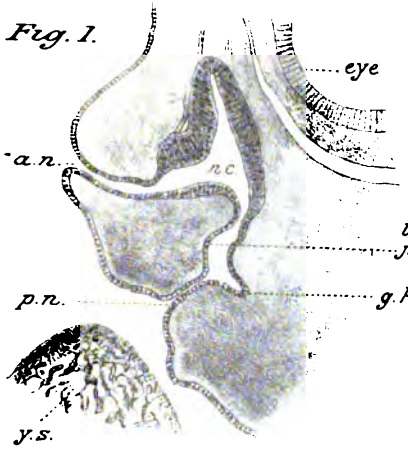

Fig. 2.

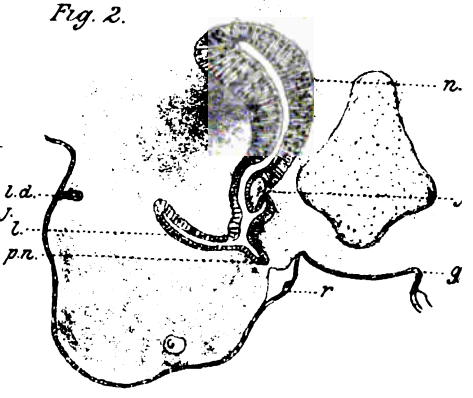

Fig. 3.

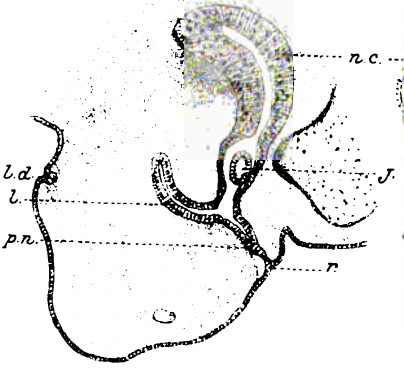

Fig. 5.

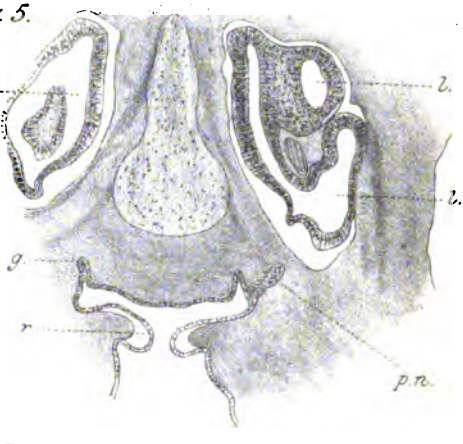

Fig. 4.

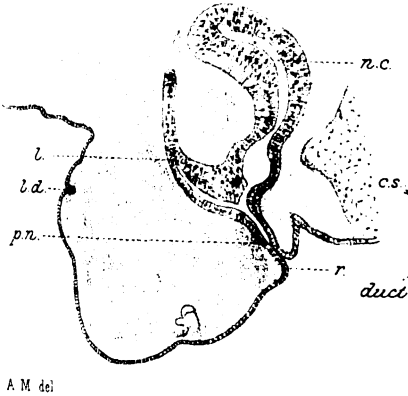

Fig. 6.

A M del

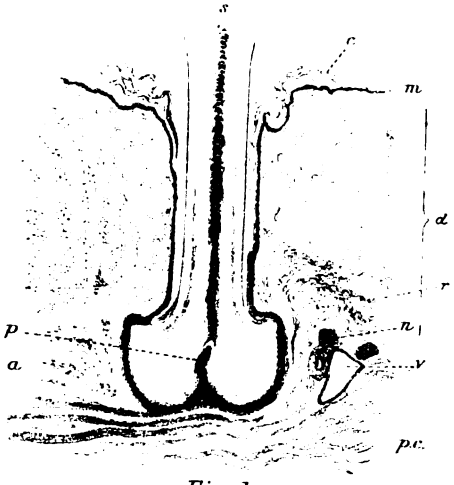

Fig. 1.

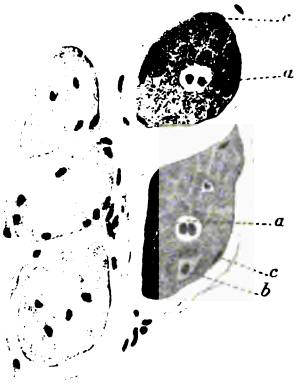

Fig. 2.



Fig. 3.

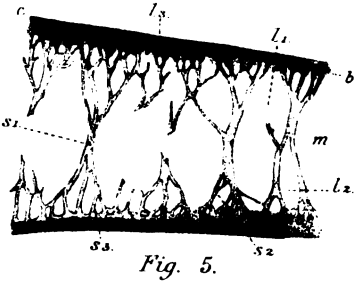

Fig. 5.



Fig. 4.

Fig. 8.

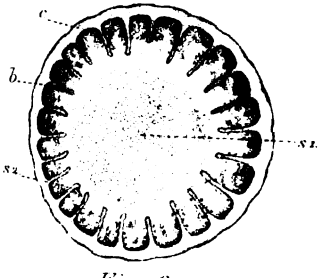

Fig. 6.

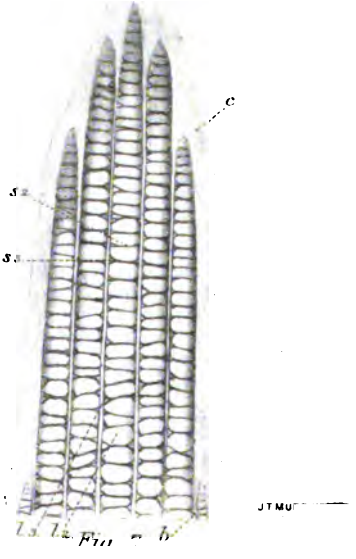

Fig. 7. b

Fig. 1.

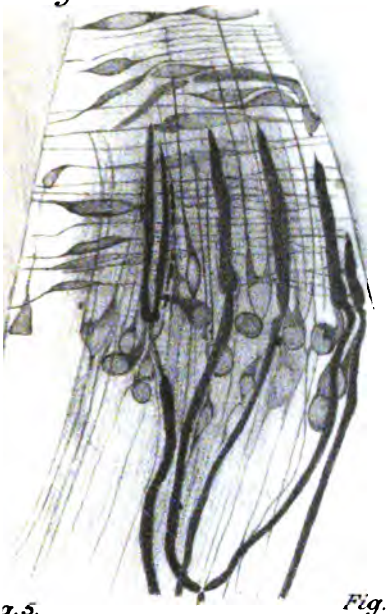

Fig. 2.

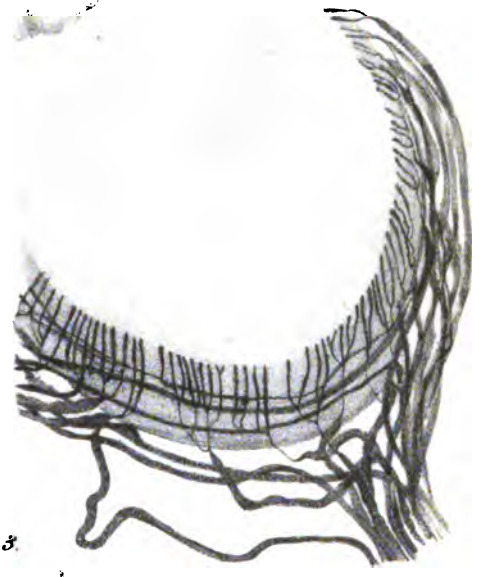

Fig. 5.

Fig. 3.

Fig. 6.

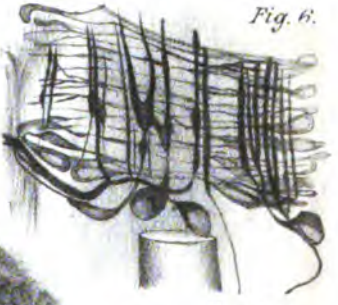

Fig. 9.

Fig. 7.



Fig. 8.

Fig. 4.

Geo Hoggan del.

F Huth, Lith.r Edin.r



Fig. 1.

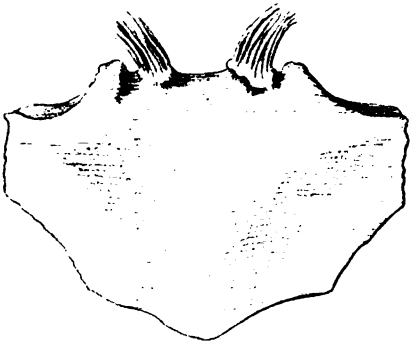

Fig. 2.

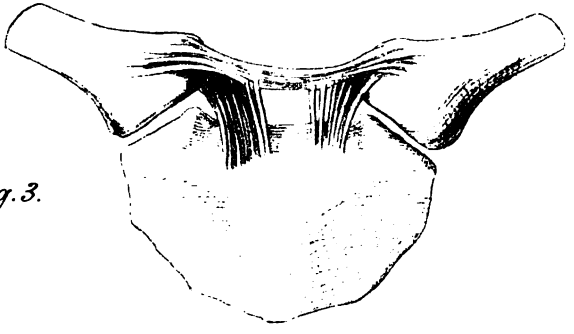

Fig. 3.

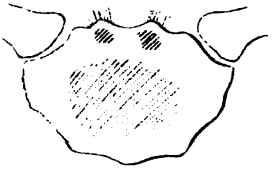

Fig. 4.

Thos Carwardine del. F Huth, Lithx Edinx

SUPRA-STERNAL BONES.

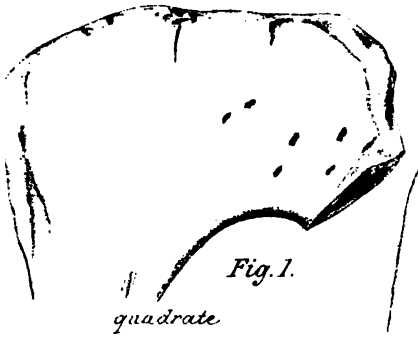

Fig. 1.



Fig. 2.

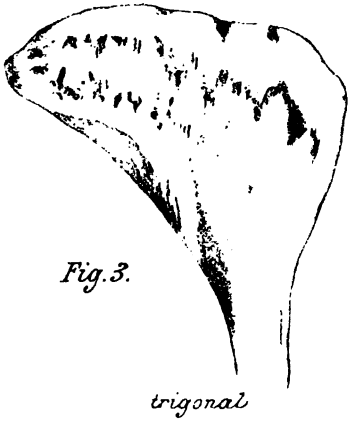

Fig. 3.

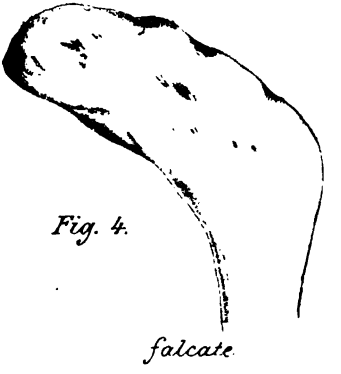

Fig. 4.

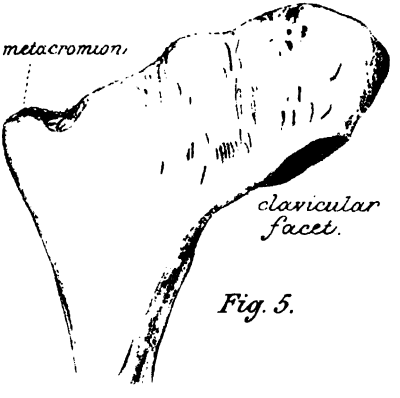

Fig. 5.

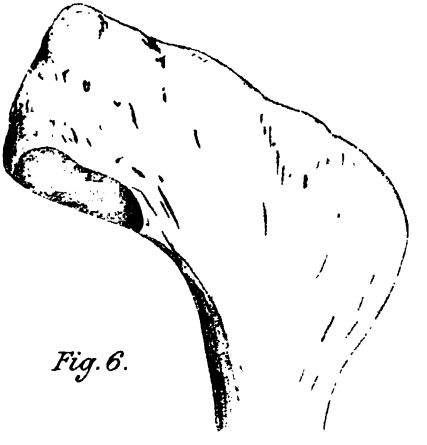

Fig. 6.

Alex. Macalister del. F. Huth, Lith.

TYPES OF ACROMION PROCESSES

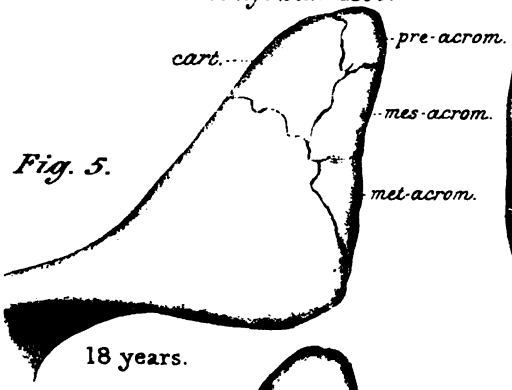

Fig. 5.

18 years.

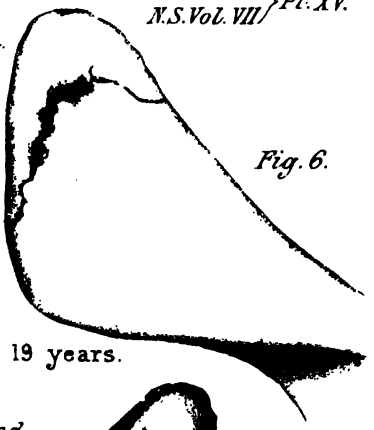

Fig. 6.

19 years.

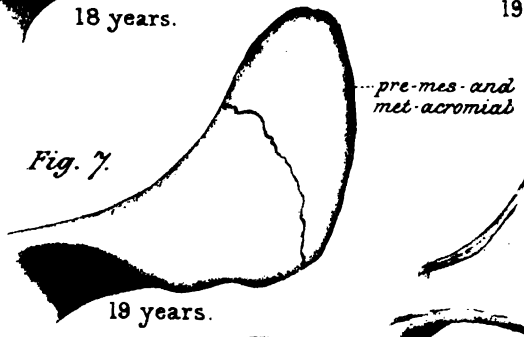

Fig. 7.

19 years.

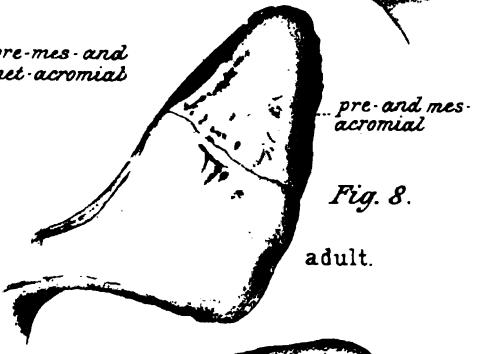

Fig. 8.

adult.



4 years.

Fig. 1.

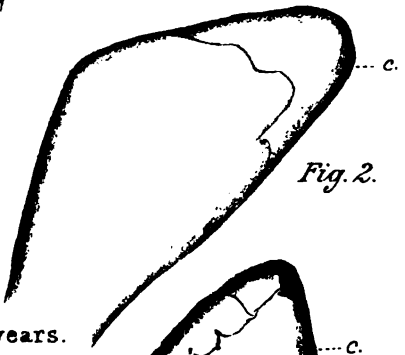

Fig. 2.

14 years.

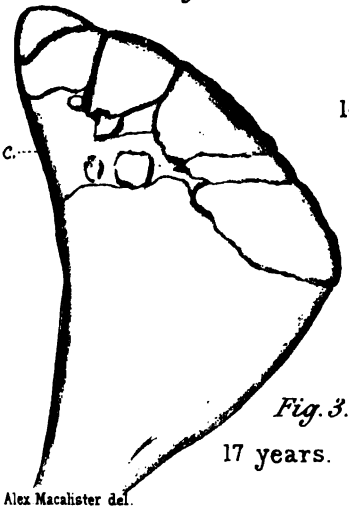

Fig. 3.

17 years.

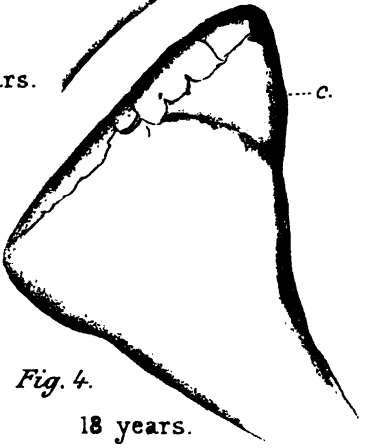

Fig. 4.

18 years.

Alex Macalister del.

F. Huth, Lith.

Fig. 1.

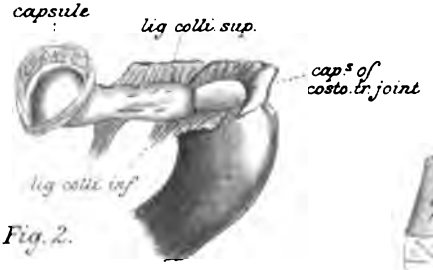

Fig. 2.

First Rib.

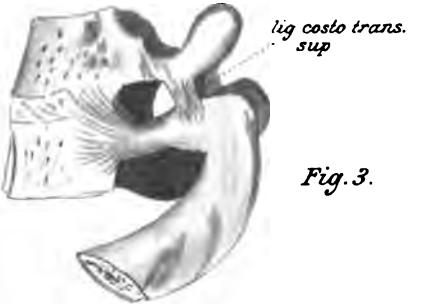

Fig. 3.

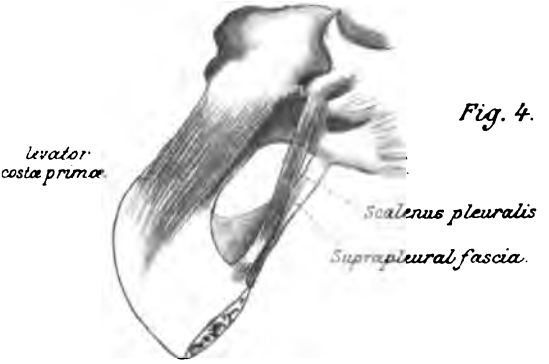

Fig. 4.

A Macalister del F. Huth. Lithr Edinr

COSTO-VERTEBRAL JOINTS.

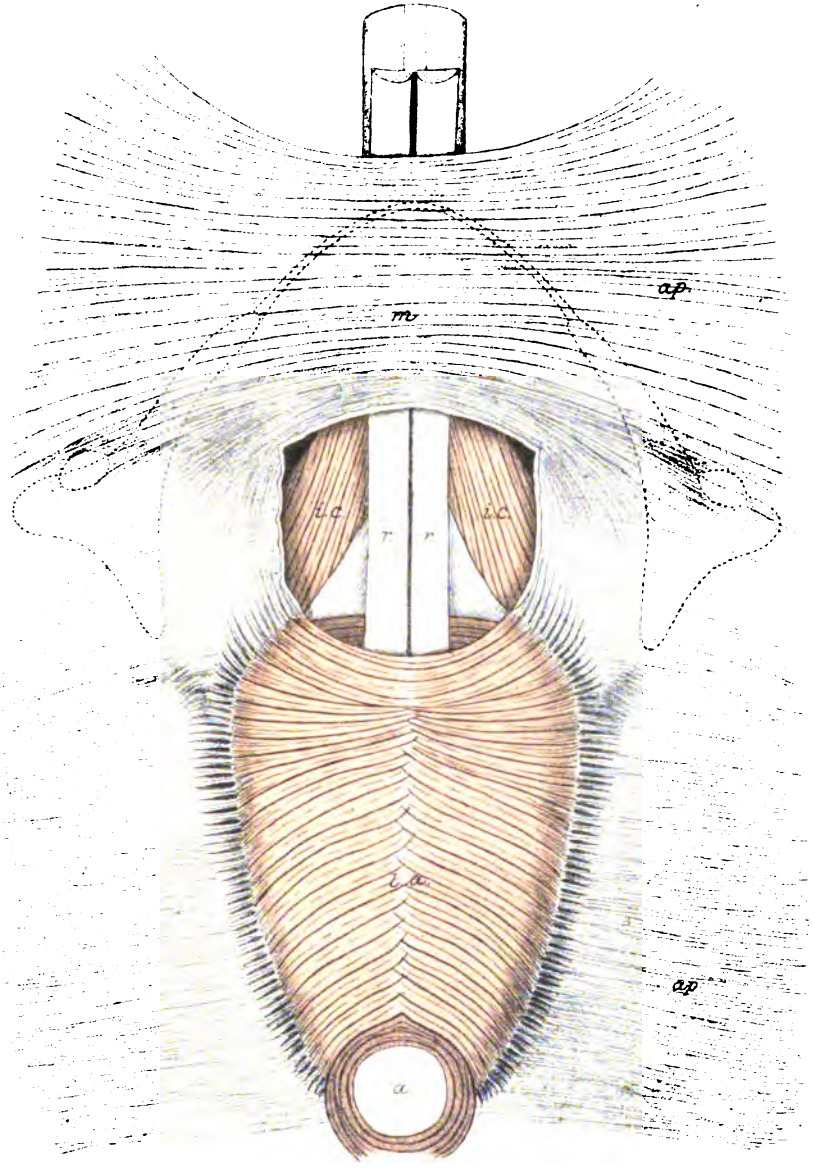

Fig. 1.

John Struthers del. F Huth, Lith^r Ed^r

RUDIMENTARY HIND-LIMB OF BALÆNOPTERA MUSCULUS.

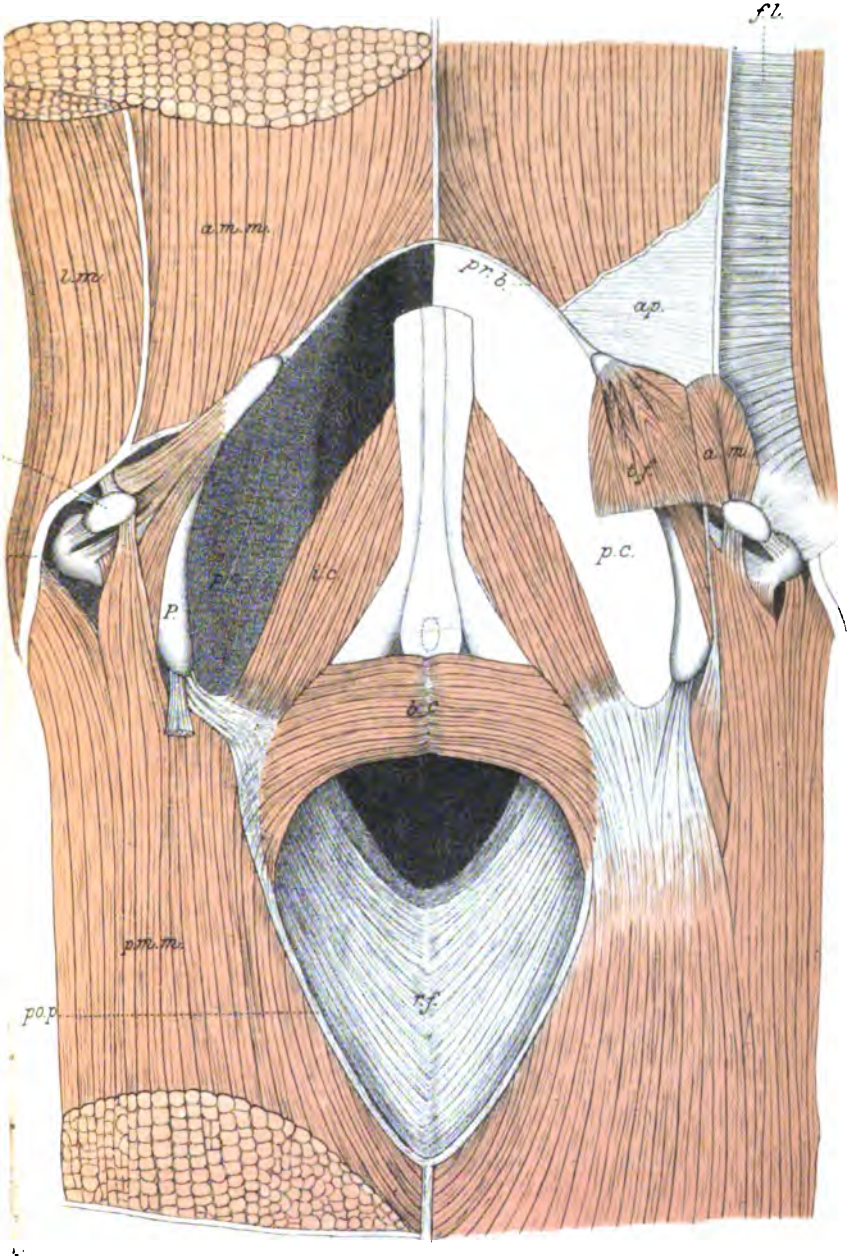

Fig. 2.

John Struthers del. F Huth, Lith.

RUDIMENTARY HIND-LIMB OF BALÆNOPTERA MUSCULUS

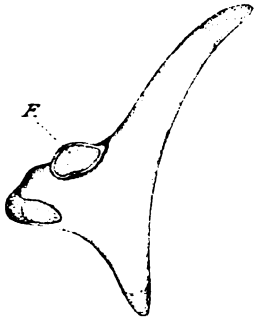

Fig. 4.

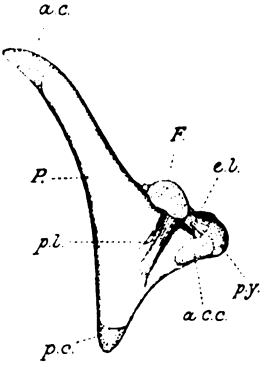

Fig. 5.

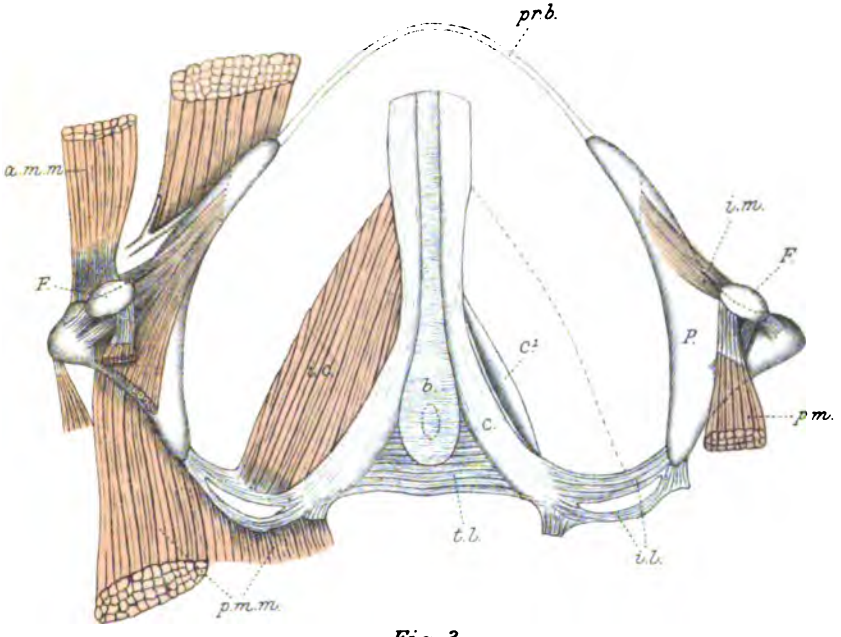

Fig. 3.

John Struthers del.

F. Huth, Lt

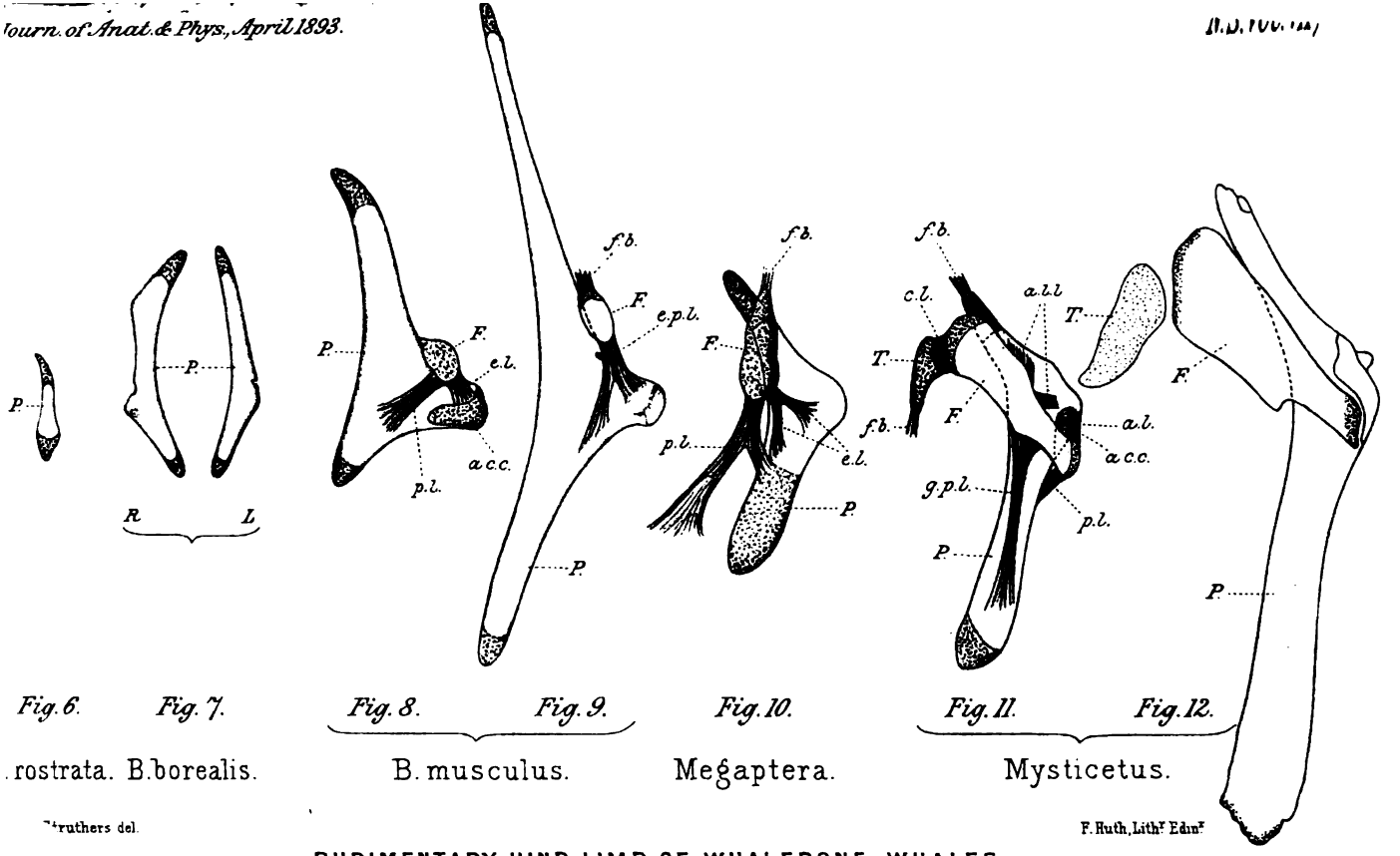

Fig. 6. Fig. 7. Fig. 8. Fig. 9. Fig. 10. Fig. 11. Fig. 12.

.rostrata. B. borealis. B. musculus. Megaptera. Mysticetus.

Struthers del. F. Huth, Lith. Edin.

RUDIMENTARY HIND-LIMB OF WHALEBONE WHALES.



Fig. 1.

Fig. 2.

Fig. 3.

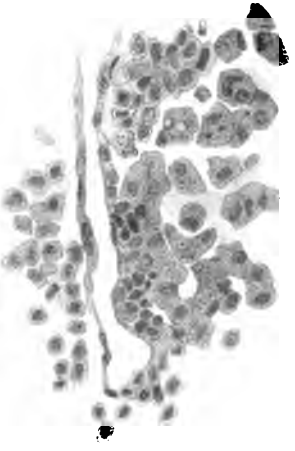

Fig. 4.

Fig. 5.

Fig. 6.



J. T. Murray del.

F. Huth, Lith.

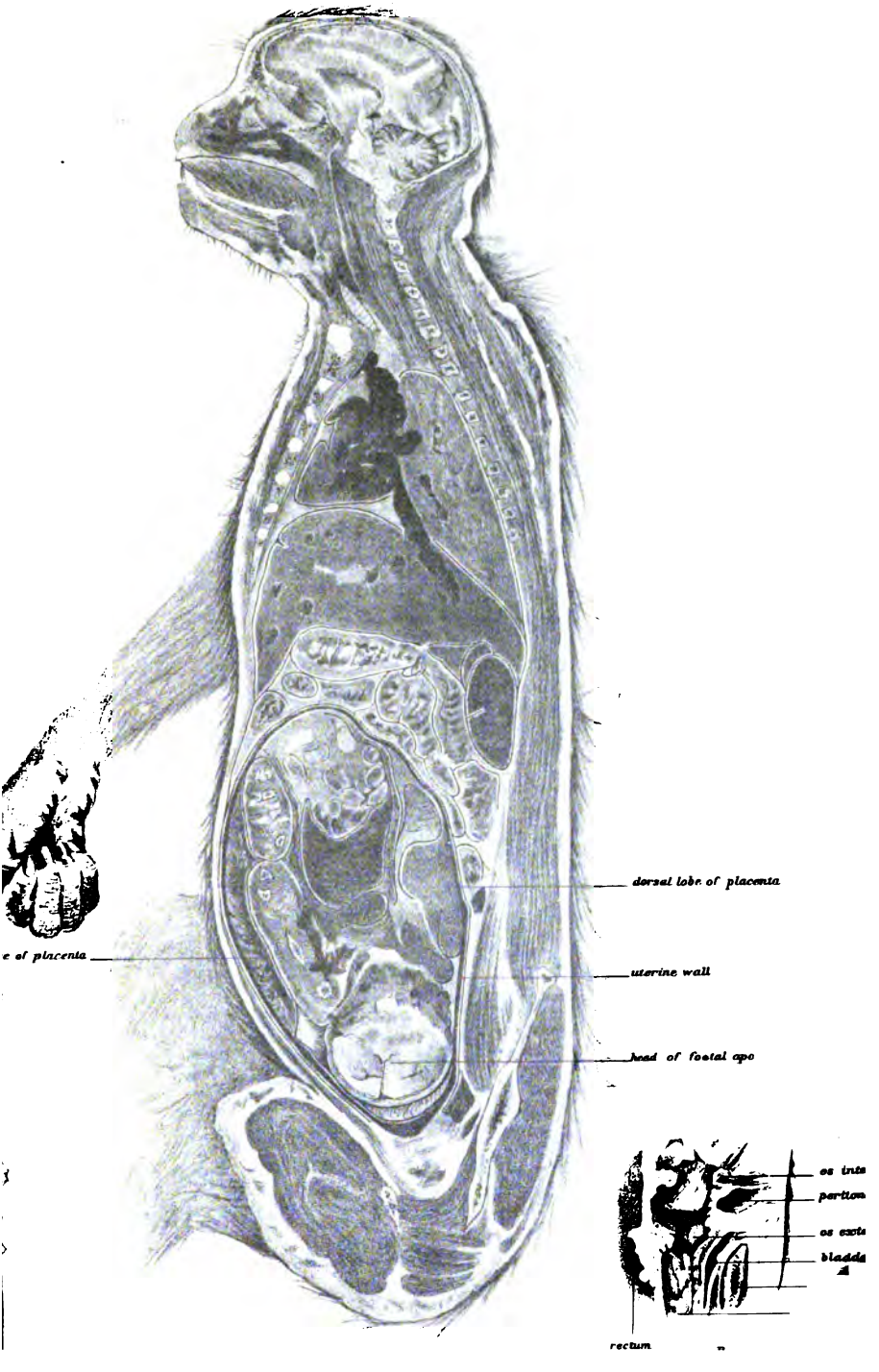
dorsal lobe of placenta
e of placenta
uterine wall
head of foetal ape
os inte
portion
os exte
bladde
rectum



Fig. 1.

Fig. 2.

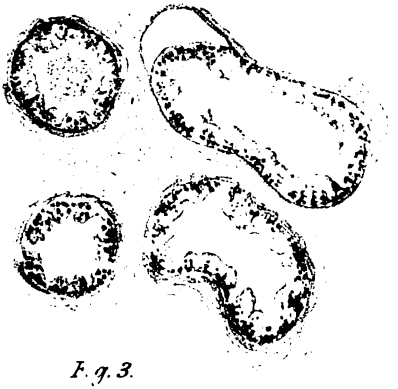

Fig. 3.

Fig. 4.



Fig. 6.

Fig. 5.



Fig. 7.

J. Griffith del. F. Huth, Lith.

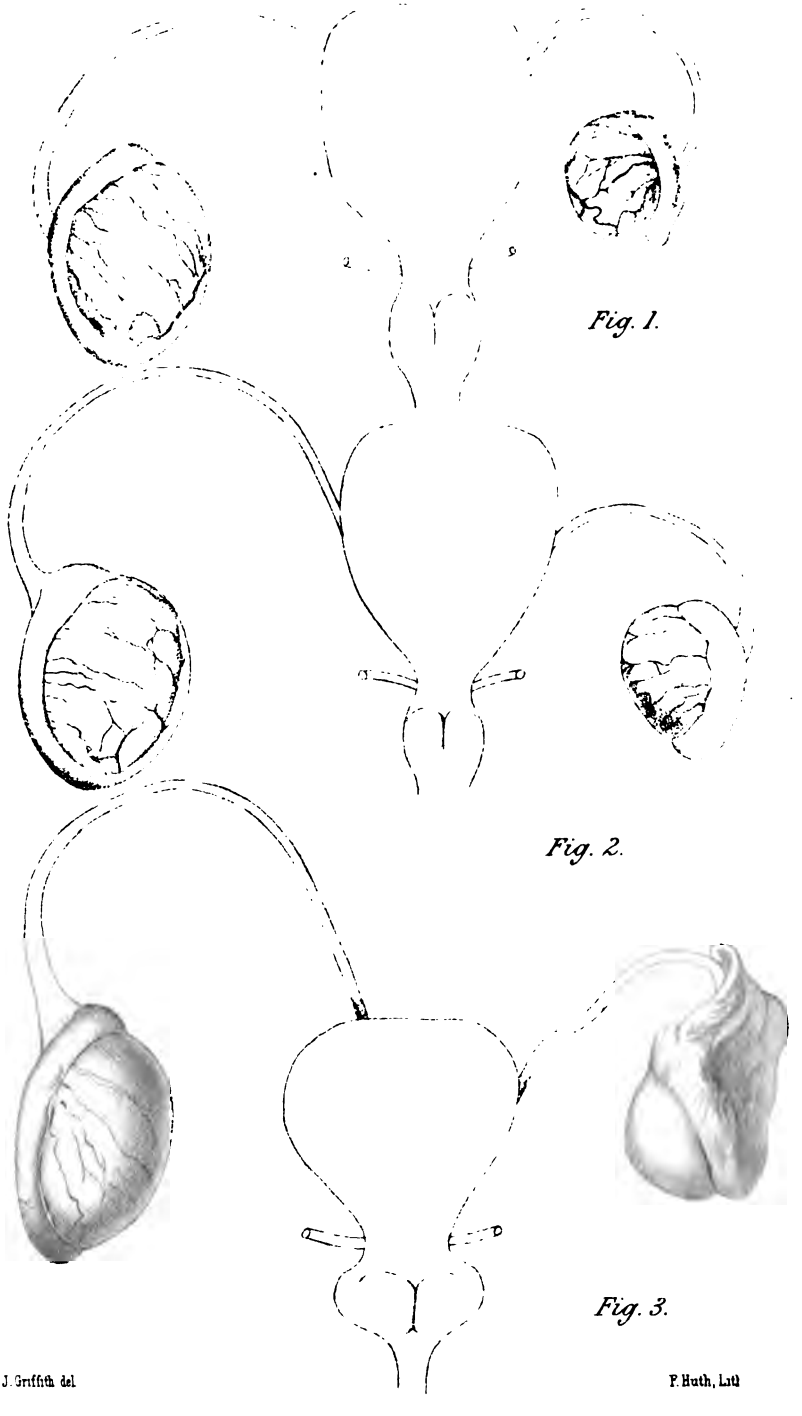

Fig. 1.

Fig. 2.

Fig. 3.

J. Griffith del. P. Huth, Lith.

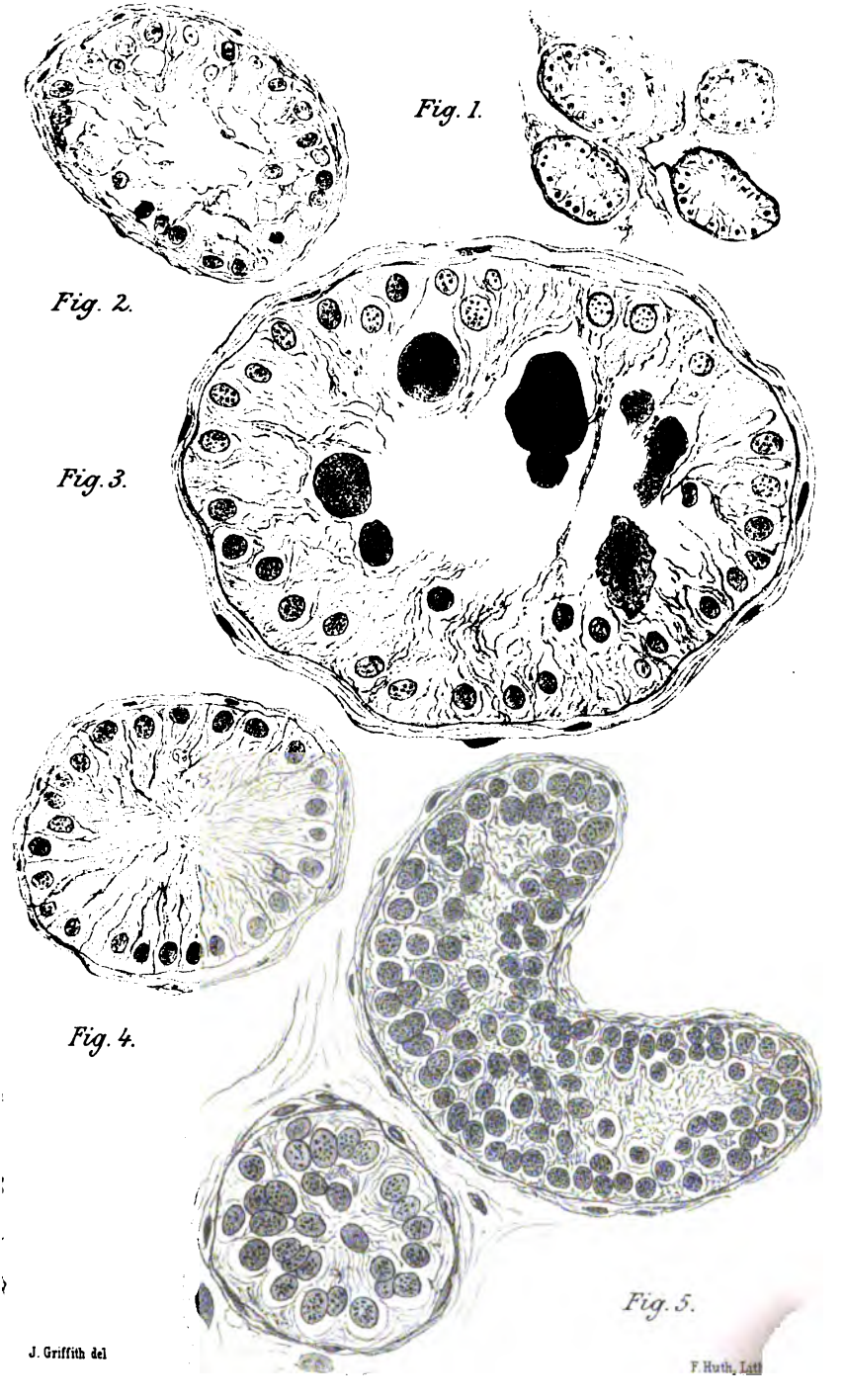

J. Griffith del

F. Huth, Lith

Fig. 1.

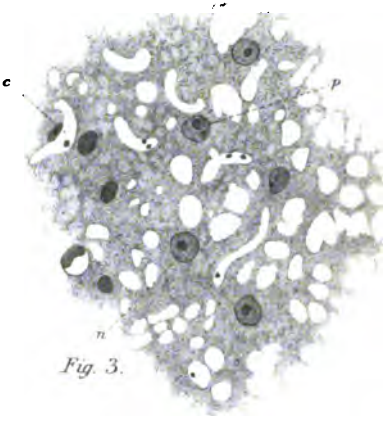

Fig. 3.

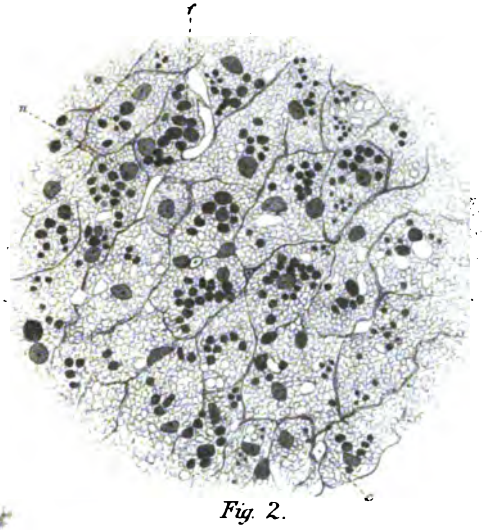

Fig. 2.

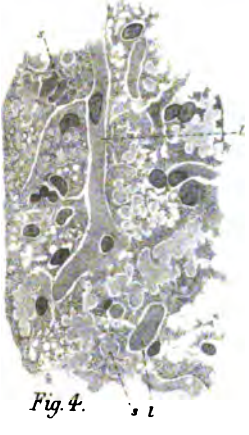

Fig. 4.

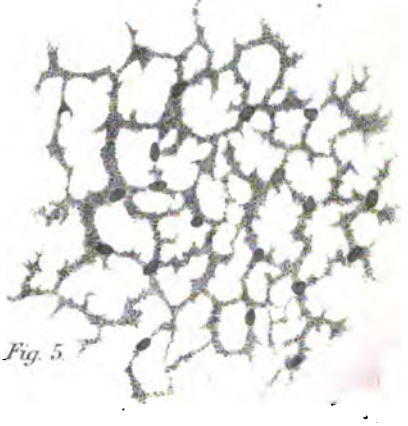

Fig. 5.

Fig. 1.

Fig. 2.

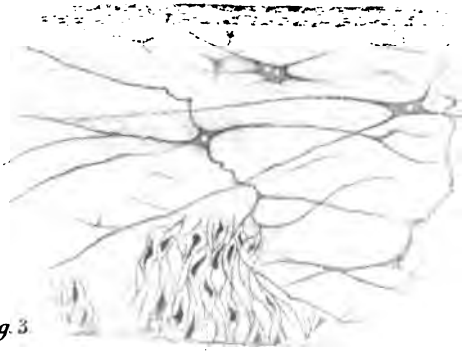

Fig. 3.

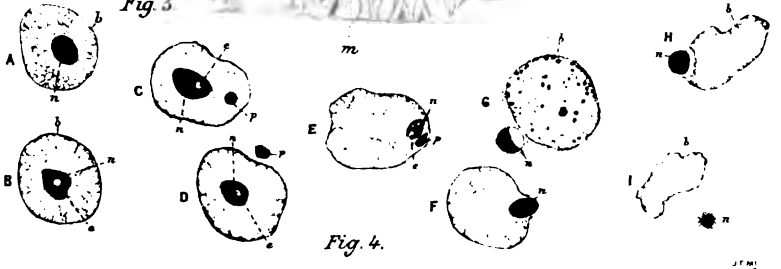

Fig. 4.

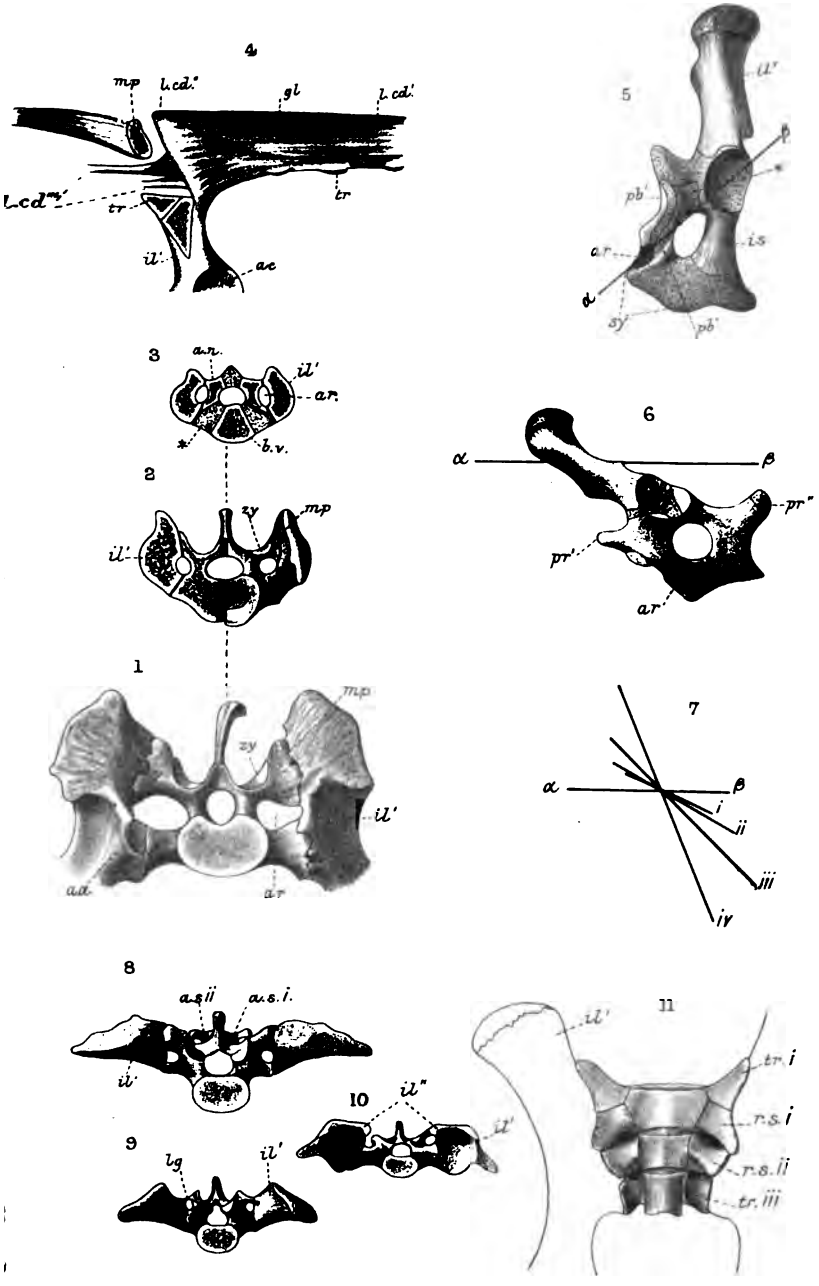
4
mp
l.cd.'
gl
l.cd.'
l.cd.m.'
tr
tr
il.'
ac
5
il.'
β
pb.'
is
a.r.
α
sy.'
pb.'
3
a.r.
il.'
a.r.
b.v.
2
zy
mp
il.'
6
α
β
pr.''
pr.'
a.r.
1
mp
zy
il.'
a.d.
a.r.
7
α
β
i
ii
iii
iv
8
a.s.ii
a.s.i.
il.'
10
il.''
il.'
9
lg
il.'
11
il.'
tr.i
r.s.i
r.s.ii
tr.iii

G.B.H. del.

MAR 1970

BY

MAR 1970

LIBRARY